Innovative dental implant solutions

Through innovation and creativity, Anthogyr offers a complete range of implants, instruments and digital solutions to support dental health professionals in restoring their patients' smiles. Dr Albert Chou and Dr Sebrina Malik share how these solutions have allowed them to deliver effective and predictable implant treatments in their daily practice.

First experience with Anthogyr Axiom® TL implant

By Dr Albert Chou

The dental profession has been helping patients restore their chewing functions and aesthetics using modern dental implants since the 60s. There are a variety of designs and shapes of implants produced since then. Macroscopically, the most distinctive feature of a modern dental implant is either a soft tissue level implant or a bone level implant.

However, any attempts to justify which implant design is superior will probably end up with a non-conclusive agreement between different dentists as the decision to choose one design over the other can be due to the operator's training and experience. What is crucial to know is that both bone level and tissue level implant offer good implant survival rate[1].

CLINICAL CASE

A 46-year-old female without any pertinent medical issues wanted to have her missing lower right first molar (tooth 46) replaced. During the first consultation, her dentition presented a moderate amount of attrition. Abfraction was also noted, and she mentioned that she did brux at night from time to time.

Her lower left second molar (tooth 47) was replaced with a Straumann Tissue level implant some years ago and it had served her well without any issues. It was then proposed to her to have Anthogyr Axiom® TL implant with simultaneous guided bone


Fig. 1

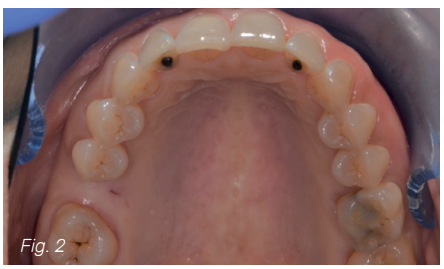
Fig. 2


Fig. 3


Fig. 4


Fig. 5


Fig. 6


Fig. 7


Fig. 8

regeneration on the lower right first molar site (Figs. 1-8).

Upon detailed examination of the CBCT (cone beam computed tomography) image, a radiolucent area was noted at the distal aspect of the root and the bone of the lower right second premolar (tooth 45) (Figs. 9a-c).

The patient was referred to see the endodontist to assess if the tooth was restorable. Unfortunately, the tooth was deemed untreatable and would need to be extracted. The tooth was then extracted carefully and with as little trauma as possible (Fig. 10). Upon inspection of the extracted tooth, a perforation at the coronal third of the root at the distal aspect of the tooth was observed (Figs. 11-12).

Theoretically, it was possible to place an implant at the tooth 46 site and perform immediate implant placement at tooth 45 with simultaneous bone graft procedure, but doing so would be challenging. Since bone graft was already planned, it was decided to wait for 12 to 16 weeks (Type 3C – early placement with partial bone healing plus conventional loading) of healing before the implant placement to have a higher degree of survival rate[2].

SURGICAL PLANNING

CBCT was taken to check the location of the inferior alveolar nerve. For implant viewing and planning, both Dentsply Sirona Gallileos and Dental Wings coDiagnostiX were used (Figs. 13-14). From the CBCT scan, it was noted that bone agumentation on the buccal side of the two proposed implants was needed. For implant planning purpose, Anthogyr Axiom® TL PX R2 4.0mmX8mm was used (Fig. 15). At tooth 46, Anthogyr Axiom® TL PX R2 4.6mmX6.5mm was used for surgical planning (Fig. 16).

On the day of surgery, a surgical stent was used to aid the implant placement (Fig. 17). Two Anthogyr Axiom® TL were placed following manufacturer's surgical protocol (Fig. 18).

After the two implants were placed with good primary stability, guided bone regeneration procedure was carried out (Figs. 19-20). Two

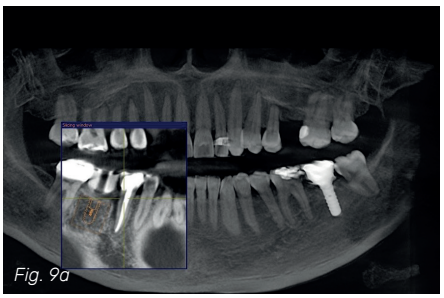
Fig. 9a

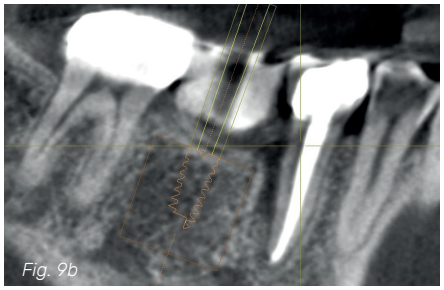
Fig. 9b

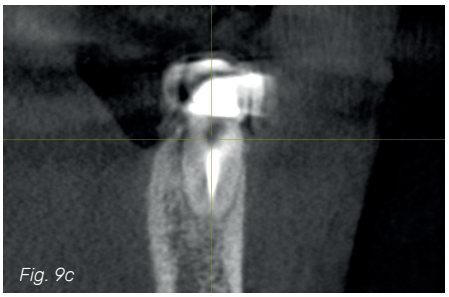
Fig. 9c

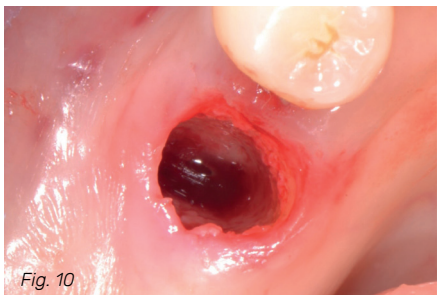
Fig. 10

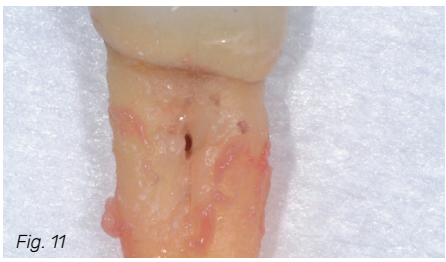
Fig. 11


Fig. 12

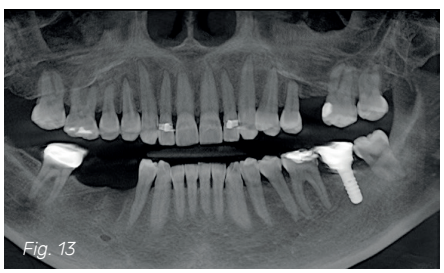
Fig. 13

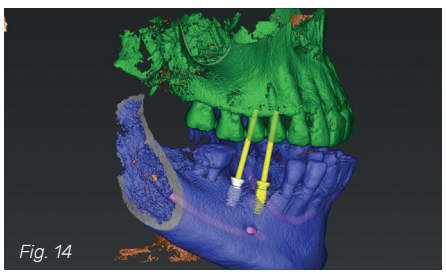
Fig. 14

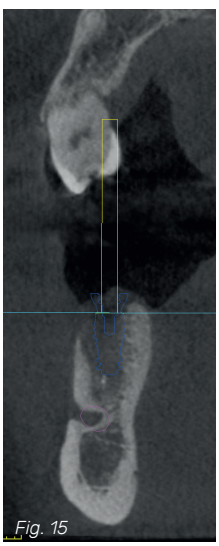
Fig. 15

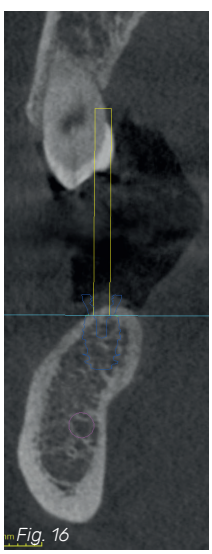
Fig. 16


Fig. 17

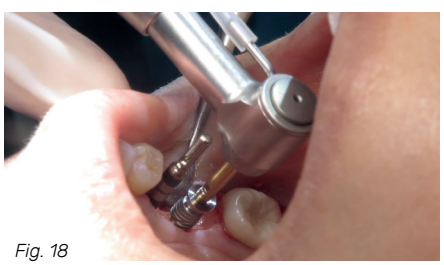
Fig. 18

implants placed were Anthogyr Axiom® TL PX 4.6X6.5mm with R2.5 at tooth 46 and Anthogyr Axiom® TL PX 4.0X8mm with R2.5 at tooth 45. Cover screws were used for both implants at the end of the surgery. Geistlich Bio-Oss 0.25g was used as the bone graft material with Geistlich Bio-Gide 13X25mm for membrane.

Primary closure was achieved at the tooth 46 site but it was not possible at the tooth 45 site. Flap was closed with non-absorbable monofilament 5/0 Prolene by Ethicon and absorbale glyconate monofilament 5/0 Monosyn by B. Braun (Fig. 21).

When the implants were placed in March 2021 in Singapore, the only collar height for the Anthogyr Axiom® TL was R2.5. Hence, it was different from what was planned when using the coDiagnostiX. The healing phase for the patient was uneventful and after the suture removal, she was seen again two months after the surgery. The soft tissue was healing well but the metal collar at 45 implant was exposed (Figs. 22-23).

Implants at 45 and 46 were left to heal for three months before the stage two surgery was carried out (Fig. 24). The healing abutment used at 45 was 2mm in height and 4.8mm in diameter. At 46, it was 4mm in height and 4.8mm in diameter.

Digital implant impression was utilised and two Anthogyr Axiom® TL scan bodies were used (Figs. 25-26). The data was acquired using Medit i500 scanner (Figs. 27-29).

The patient preferred to have a tooth-coloured restoration, with monolithic zirconia crown as the material of choice. It was also decided that it will be beneficial to splint the two crowns together due to the shorter implant used at 46. The abutment used for both 45 and 46 was non-engaging Flexibase TL R plural (Figs. 30-34).

CONCLUSION

In dentistry, one may face an unplanned situation. In this case, tooth 45 was not supposed to be replaced by a dental implant. Using Anthogyr implant system has made day-to-day clinical practice more flexible and straightforward when dealing with unexpected changes.

Regrettably, the soft tissue height at 45 was not ideal. However, Anthogyr Axiom® TL implant demonstrated excellent tissue response around the gingival soft tissue. In hindsight,


Fig. 19


Fig. 20

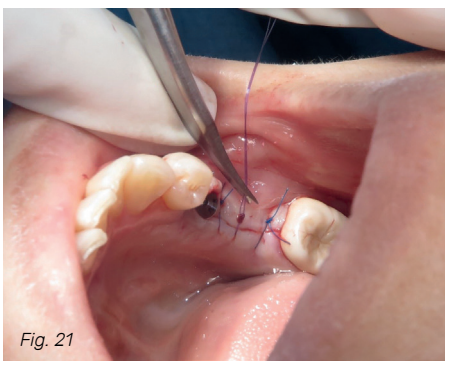
Fig. 21


Fig. 22

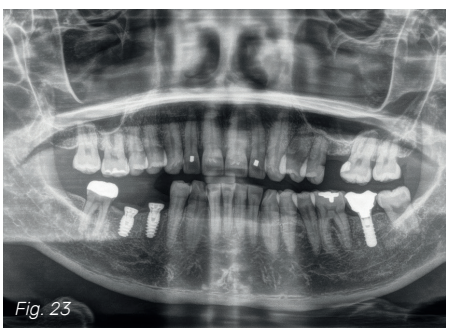
Fig. 23


Fig. 24

Fig. 25


Fig. 26

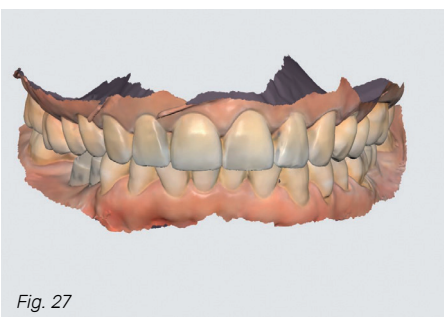
Fig. 27


Fig. 28


Fig. 29


Fig. 30


Fig. 31


Fig. 32


Fig. 33

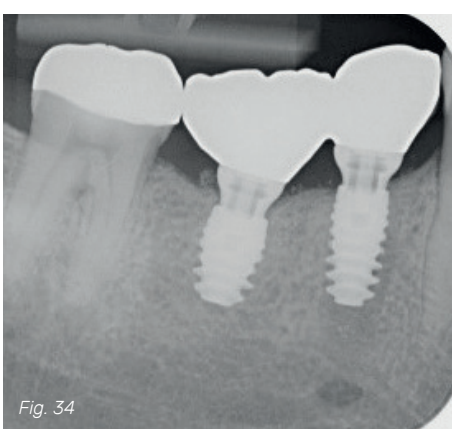
Fig. 34

implant 45 could have been placed a bit deeper or if there was preferably an option to use a shorter collar height. Unfortunately, a shorter collar height was unavailable in Singapore when the surgery was done. Nevertheless, it will be of great interest to monitor and observe the longevity of this implant system for the years to come. **DA**

ACKNOWLEDGEMENT

The author would like to extend his gratitude to Patrick Dental Lab for their prosthetic work and support.

REFERENCES

[1] Vouros, Ioannis D.; Kalpidis, Christos D. R.; Horvath, Attila; Petrie, Aviva; Donos, Nikolaos. Systematic Assessment of Clinical Outcomes in Bone-Level and Tissue-Level Endosseous Dental Implants. International Journal of Oral & Maxillofacial Implants. 2012, Vol. 27 Issue 6, p1359-1374

[2] German O. Gallucci; Adam Hamilton; Weniji Zhou; Daniel Buser; Stephen Chen. Implant placement and loading protocols in partially edentulous patients: A systematic review. Clin Oral Impl Res 2018:29 (Suupl. 16): 106-134

About the author



Dr Albert Chou obtained his Bachelor of Dental Surgery from the University of Otago, New Zealand, in 2004, and completed his Graduate Diploma in Dental Implantology with the National University of Singapore in 2013. He was the president for the NUS Graduate Diploma in Dental Implantology from 2018 to 2020 and now serves as an executive committee in the Alumni. A partner at Canaan Dental Surgery, he has always been involved in the private practice. He is a member of the International Team for Implantology (ITI) and the Asia Pacific Society of Osseointegration.