

Using excellent primary stability to avoid multiple surgeries

Ben White describes how he used excellent primary stability to allow simultaneous sinus graft and implant placement

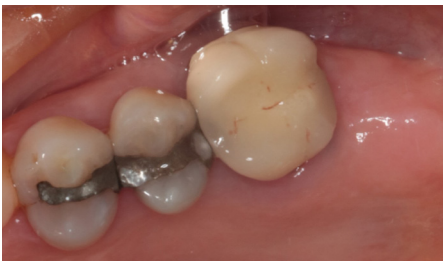

Figure 1: Initial presentation prior to removal of UL6

A 57-year-old female was referred to White Dental for the replacement of her missing upper left first and second molar teeth (UL6 and UL7) with dental implants. The patient had lost the UL7 several years previously and the UL6 a few months ago (Figure 1). She had not been wearing a partial denture and was struggling to eat on her left side. She was medically fit and well.

We discussed the possibility of a partial denture; however, the patient was keen to have a fixed replacement.

Treatment planning

A detailed clinical examination was undertaken. The patient presented with a moderately restored dentition and healthy periodontal status. There was some buccal bone loss present at the UL7 site (Figure 1).

A cone beam computed tomography (CBCT) scan was taken of the upper left posterior region,

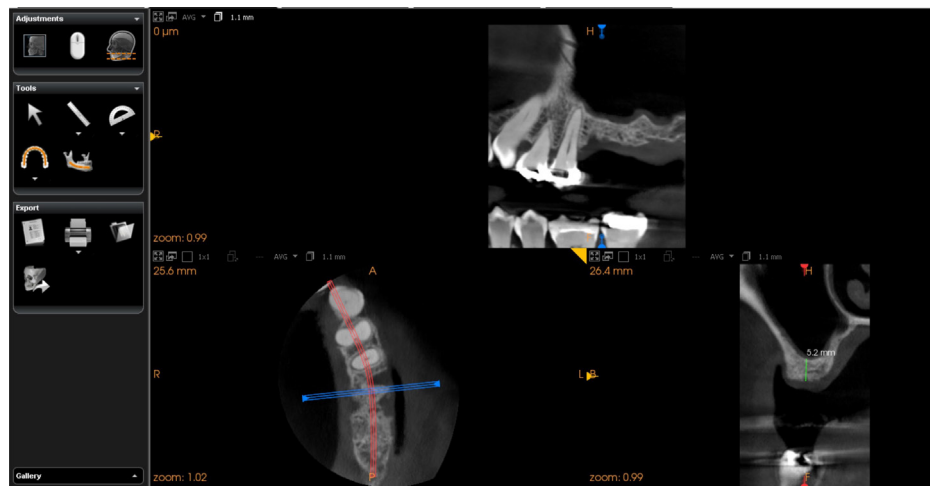


Figure 2: CBCT scan

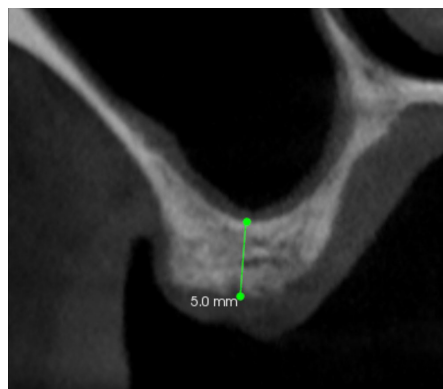


Figure 3: CBCT cross-section UL6 site

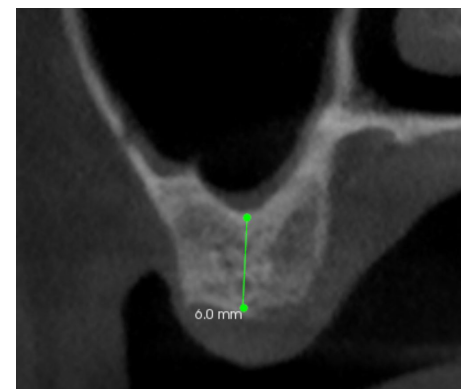


Figure 4: CBCT cross-section UL7 site

to accurately assess the bone height and width, and the anatomy and position of the maxillary sinus (Figures 2 to 4).

The scan revealed good bone width, but loss of height due to pneumatization of the sinus. The bone height was measured as 5mm at the UL6 site and 6mm at the UL7 site. Following discussion with the patient, she opted for a simultaneous sinus graft (open) and implant placement. A diagnostic wax-up was prepared and a surgical guide constructed.

Simultaneous sinus graft and implant placement

A buccal flap was reflected, and buccal window prepared using piezosurgery. The sinus lining was then elevated. Once elevated, the implant sites were prepared using the Axiom PX protocol, which results in minimum bone trauma and excellent primary stability, due to the thread design.

Prior to placement of the implants, a Biogide membrane was placed into the sinus ▶



Ben White MSc Imp Dent (Bristol) BDS qualified from the University of Bristol in 1997, opening his own practice in 2000. He started placing implants in 2002 and has carried out extensive postgraduate training. In 2012 he passed his MSc in Dental Implantology, with distinction. His practice in Hamble is one of the few accredited Anthogyr Campus Education centres on the south coast.

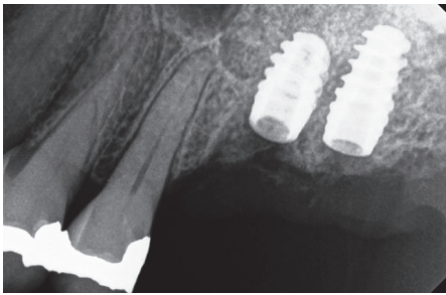


Figure 5: Postoperative radiograph

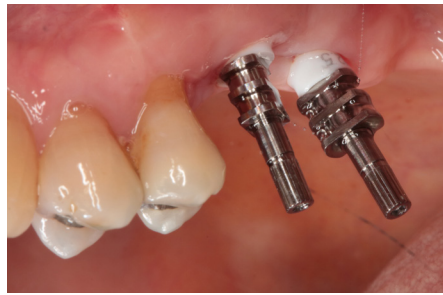

Figure 6: Conventional impressions

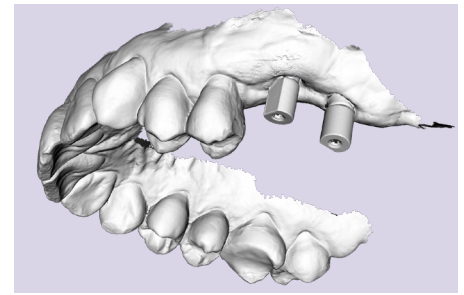


Figure 7: Digital impression using Carestream CS3600

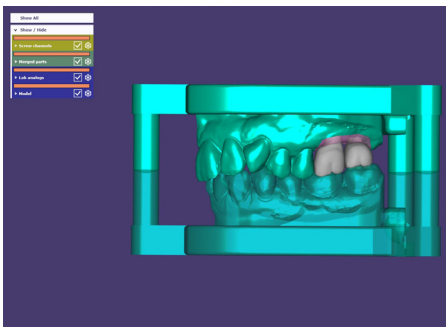


Figure 8: Crown design using Exocad

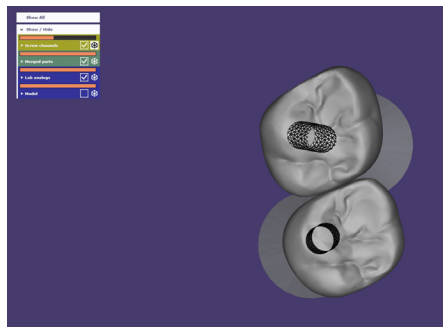


Figure 9: Crown design using Exocad

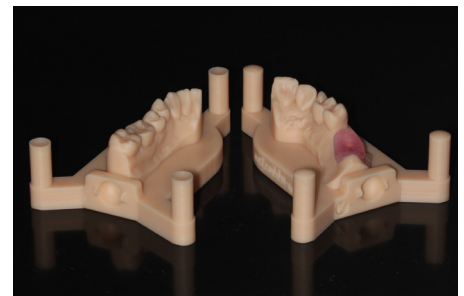


Figure 10: 3D-printed models from Simedica with integral implant analogue

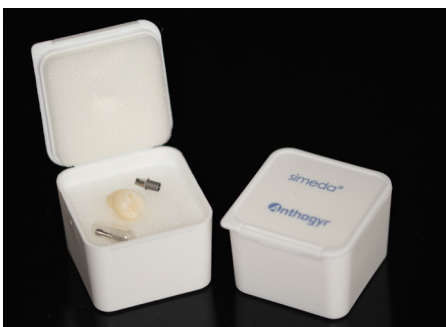

Figure 11: Delivery from Simedica

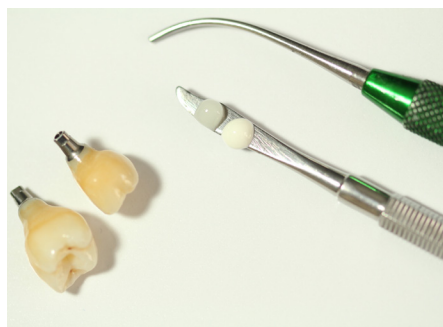

Figure 12: Final finishing and polishing by Jon Dolding

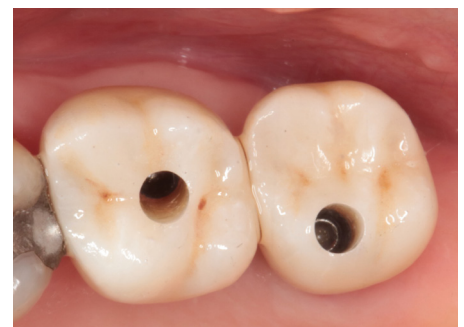

Figure 13: Final crowns prior to filling access channel

One advantage of zirconia is that the access channel is almost invisible once filled with composite

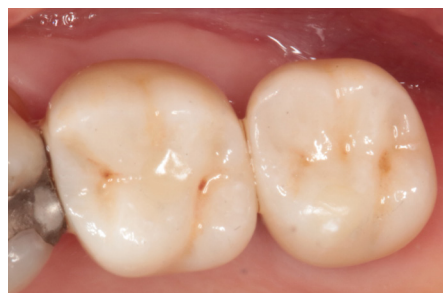

Figure 14: Final crowns with access channel filled

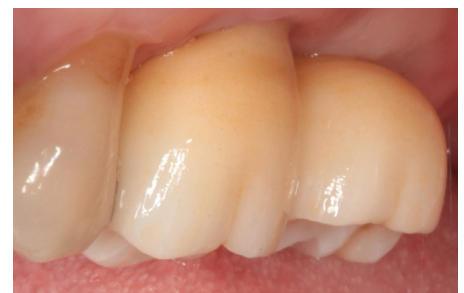

Figure 15: Final crowns

and the cavity infilled with a 50/50 mix of small and large-granule Biooss.

Two Axiom PX BL (bone-level) implants were then placed (Figure 5) – a 4.6mm x 8mm at the UL6 site and a 4.6mm x 10mm implant at the UL7 site. I opted for bone-level implants in this case as it allowed the implants to be fully submerged during the healing phase.

Following a four-month healing period, the implants were exposed and two 3mm healing abutments placed. Two weeks later, both conventional and digital impressions were taken, as it was part of a clinical follow up (Figures 6 and 7).

The case was transmitted to Jon Dolding from Ceramic Designs for construction of the final crowns (Figures 8 to 12).

Laboratory stages

Jon opted for two 4mm x 1.5mm flexi bases using models printed by Simedica with an integral analogue (Figure 10). The design was sent to Anthogyr's CAD/CAM team for production of full contour zirconia crowns.

Following a rapid turnaround, the crowns were returned to Jon for final finishing and polishing (Figure 12).

Two weeks later, the healing abutments

were removed, the crowns fitted and the definitive screws tightened to 25Ncm using the hexagonal wrench (Figure 13). The occlusion was checked, PTFE tape placed into the access channel, then filled with flowable composite.

One advantage of zirconia is that the access channel is almost invisible once filled with composite (Figures 14 and 15).

The patient was very happy with the final result and is now able to chew food on the left-hand side. She reported her preference for the digital impression over the conventional impression. **IDT**