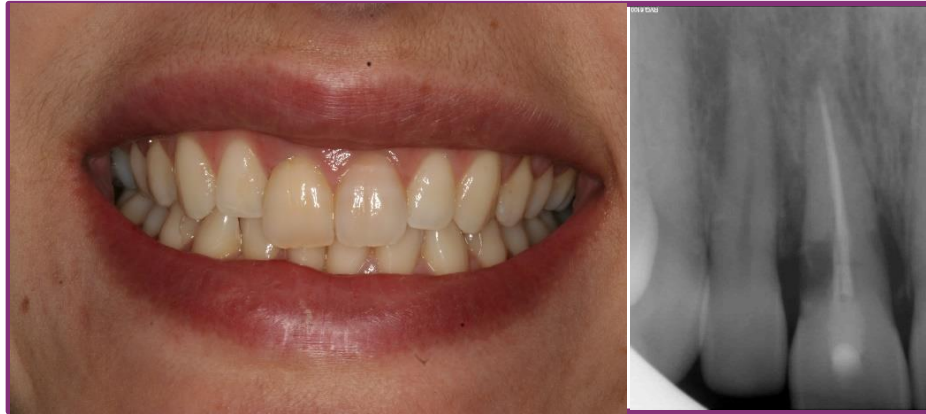

Clinical Case



CM Alvim NeoPoros



Initial Situation



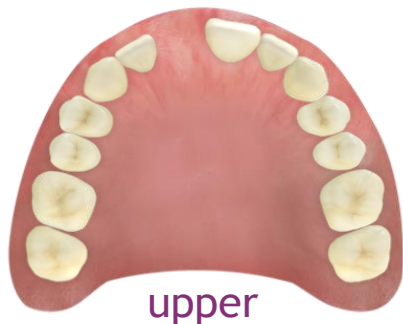Dr. Pedro Gomes

- Portugal
- Master em cirurgia oral e implantologia pela universidade Paul Sebatier de Toulouse
- Pos Graduação teorica e pratica em implantologia RBI Neodent
- Pos Graduação em restaurações estéticas aderidas pela shape dentistry academy

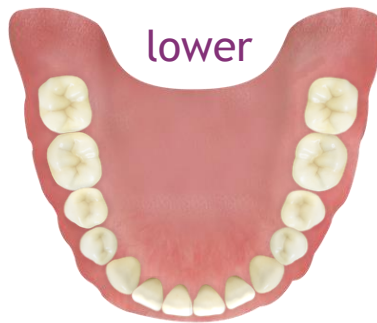

Dr. Miguel Braga Pinto

- Portugal
- Mestre em Implantodontia pela Faculdade CPO São Leopoldo Mandic Campinas - SP - Brasil
- Especialista em Periodontia HGeR Recife - PE - Brasil
- Mestre em Reabilitação Oral ISCSN- Portugal



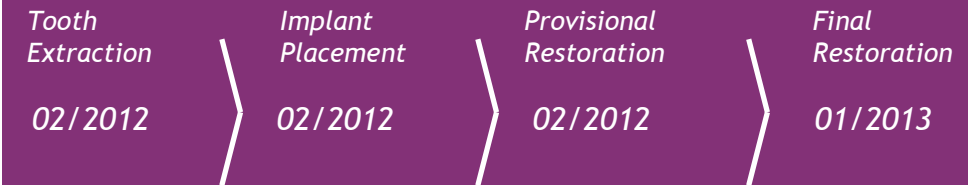upper



lower

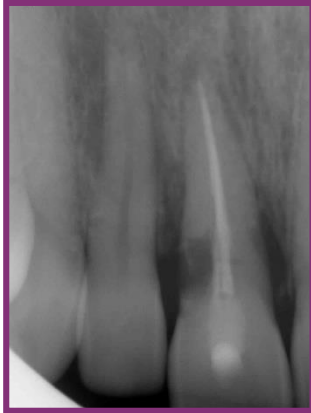Surgical products	Prosthetic products
CM Alvim NeoPoros	CM Universal abutment Exact
4.3 X 16mm	3.3 X 4 X 3.5mm
Xenograft	

- Profile: C. S.
Female 32 years old
Porto, Portugal
- Clinical Situation:
Internal resorption of tooth 11
- Restorative Solution:
Extraction, followed by immediate implant placement, immediate loading with a provisional crown on a universal abutment and bone substitute material. The case used “one-abutment-one-time” concept and finalized with a metal-ceramic crown.

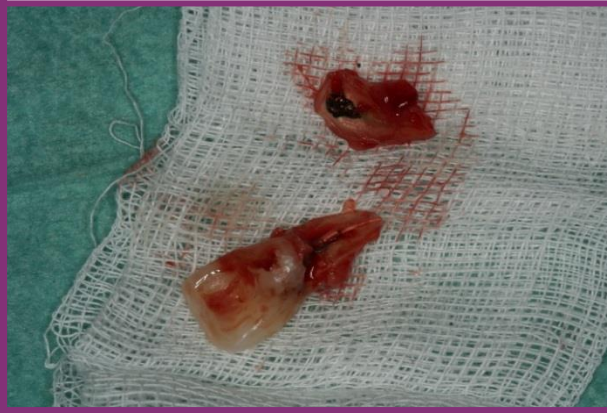

Summary	Immediate loading protocol	
Surgical Description	Maxilla	Anterior
	1 Implants	Conventional
Restorative Solution	Conventional	Metal - ceramic

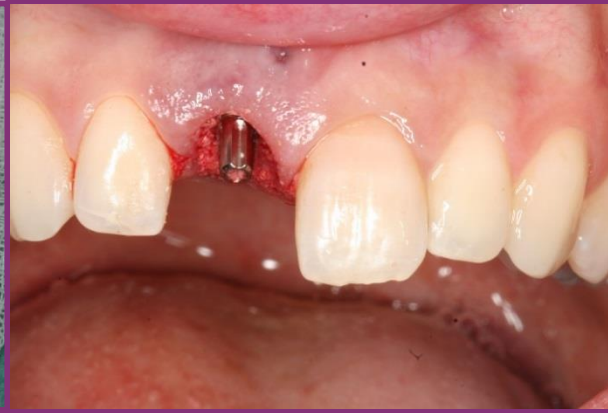Clinical Case



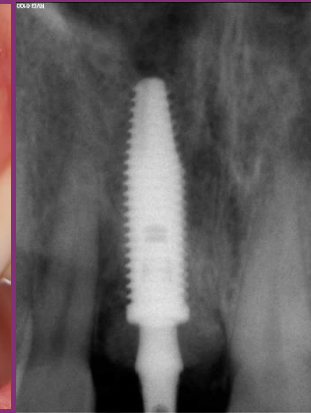
Pre-operative X-ray



Tooth extraction



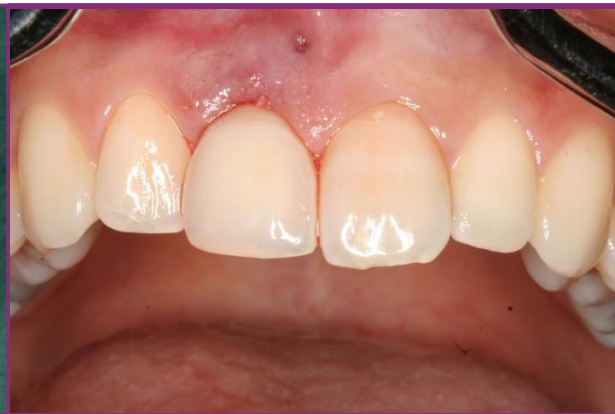Implant and abutment in place



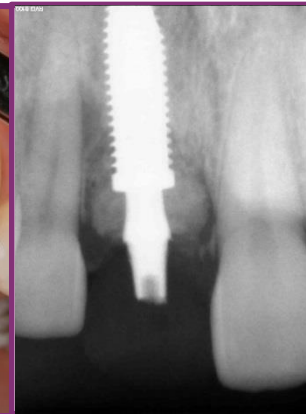
Post-operative X-ray



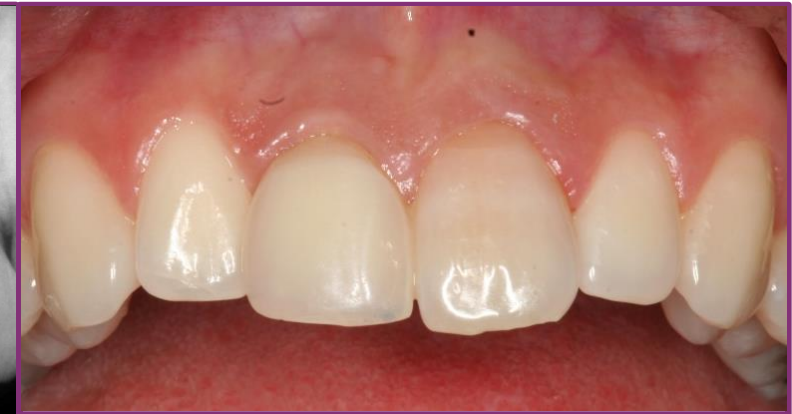Xenograft material (Xenograft)



Immediate provisional restoration in place

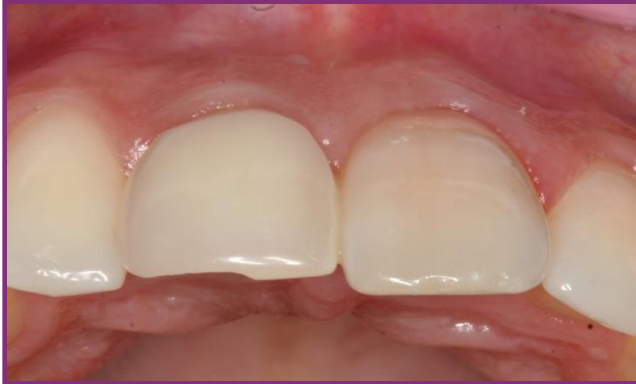

Post provisional restoration X-ray

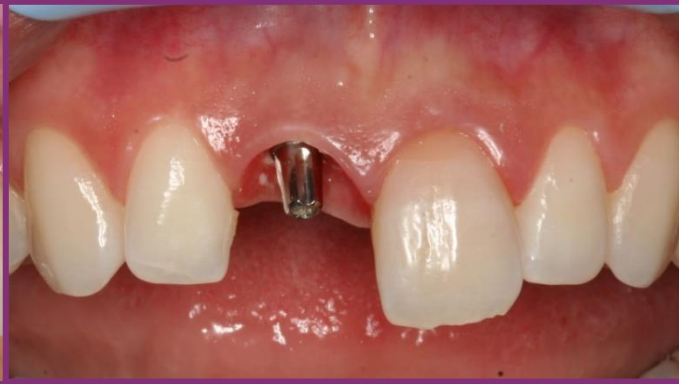

Provisional restoration 6-month after surgery

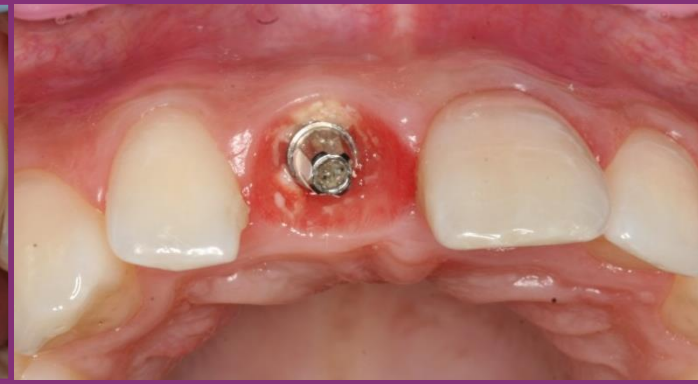Clinical Case



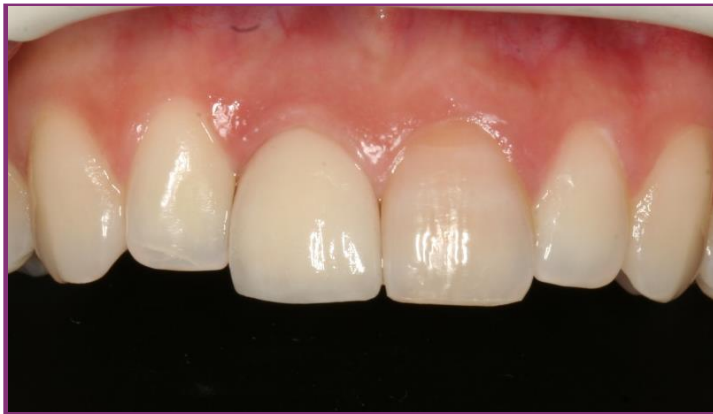*Provisional restoration 6-month after surgery
occlusal view*



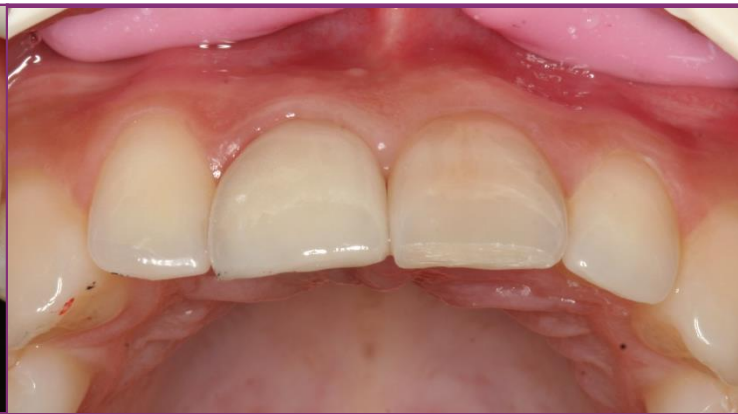*Stable soft tissue contour
6 months after surgery*



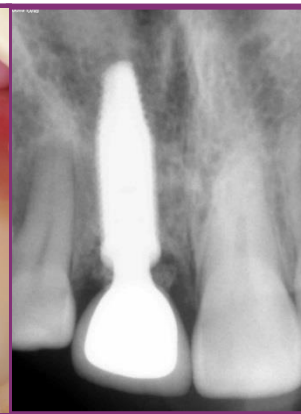
*Great emergence profile
6-month after surgery*



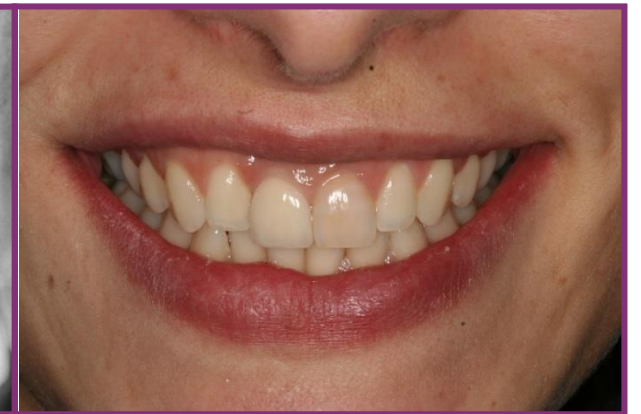Final restoration 11 months after surgery



Final restoration

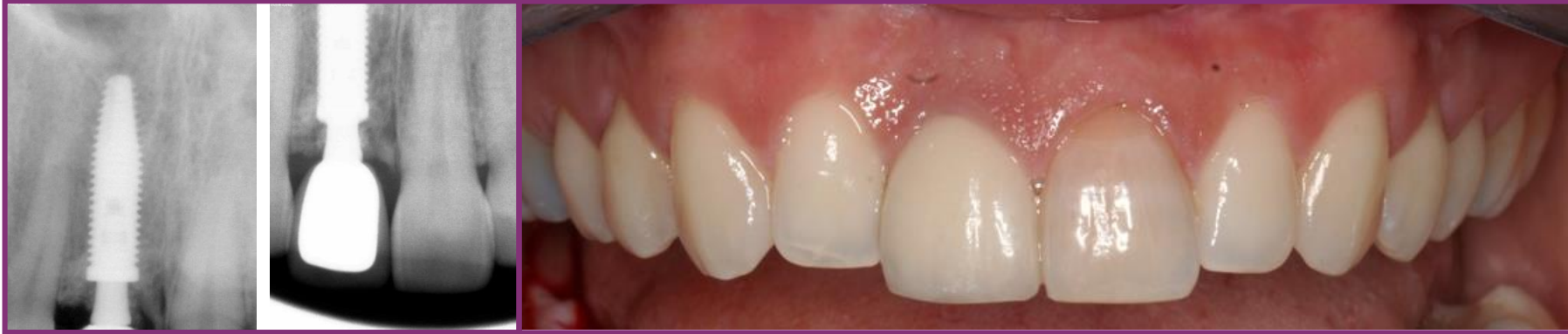

*Final restoration
X-ray*



Extra oral frontal view

Clinical Case



4-year follow-up X-ray

4-year follow up - intraoral frontal view