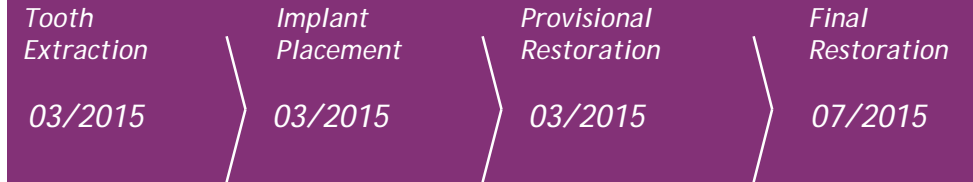


Clinical Case

- Profile: R. M.
- Female, 28 years old
Brasília, Brazil

- Clinical Situation:
Tooth 12 presenting extensive root decay with peri-apical infection

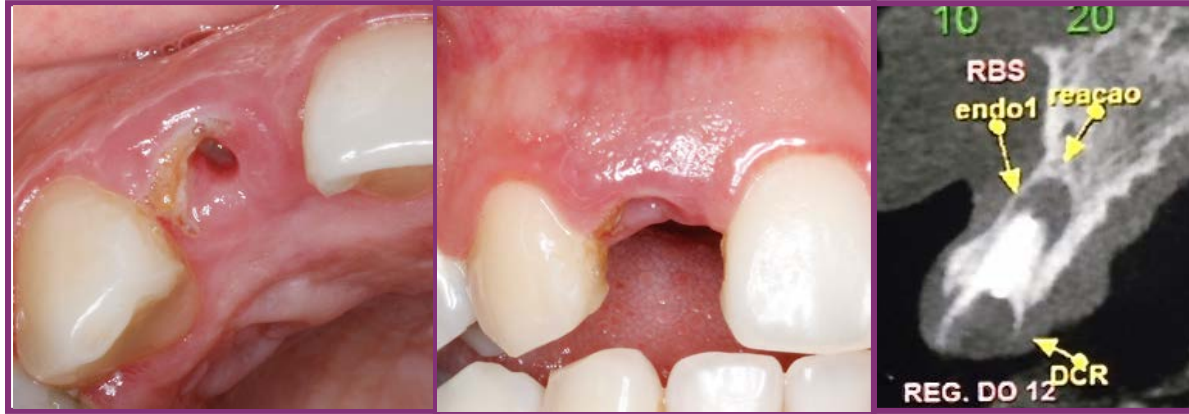- Restorative Solution:
Extraction, followed by immediate implant placement, immediate loading, provisional crown on a universal abutment with "one-abutment-one-time" concept, and finalized with a ceramic crown



Summary	Immediate loading protocol	
Surgical Description	Maxilla	Anterior
	1 Implant	Non guided surgery
Restorative Solution	Conventional + Digital	Porcelain applied to Zirconia coping



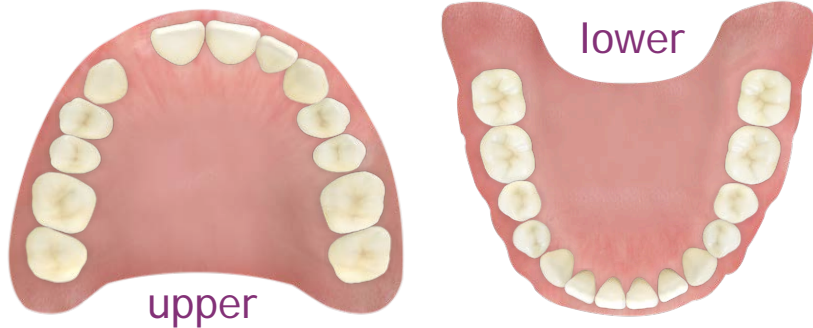CM Drive Acqua



Initial Situation

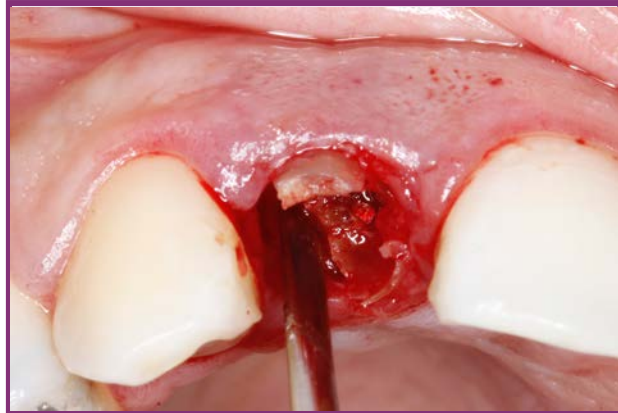

Dr. Christian Jarry
- Brasília, Brazil
- Oral Surgeon, Periodontist - D.D.S., M.Sc., Ph.D

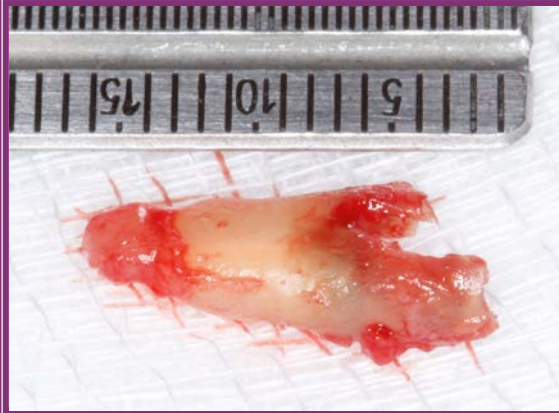


Surgical products	Prosthetic products
CM Drive Acqua 3.5 x 13mm	CM Universal Abutment 3.3 x 6 x 2.5mm

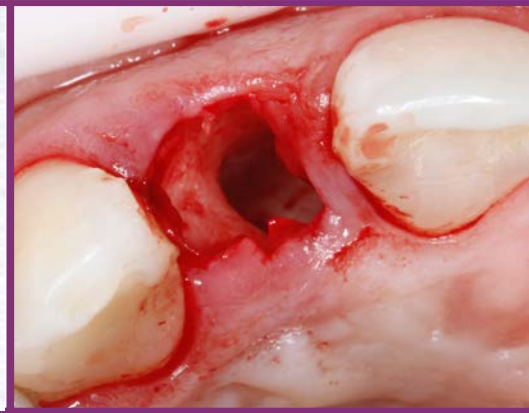Clinical Case



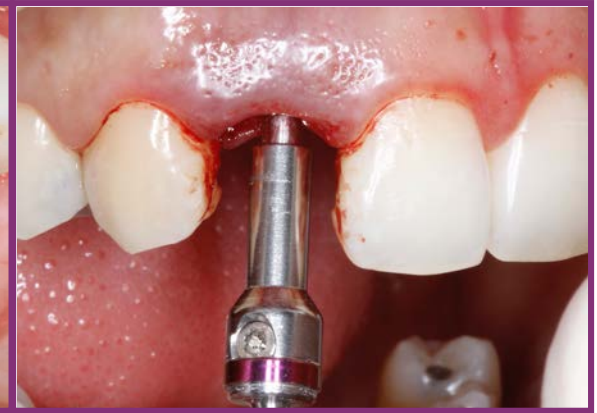*Minimally traumatic extraction
with periosteal*



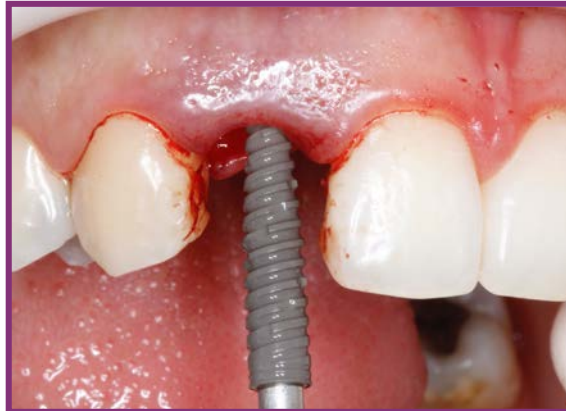Extracted root



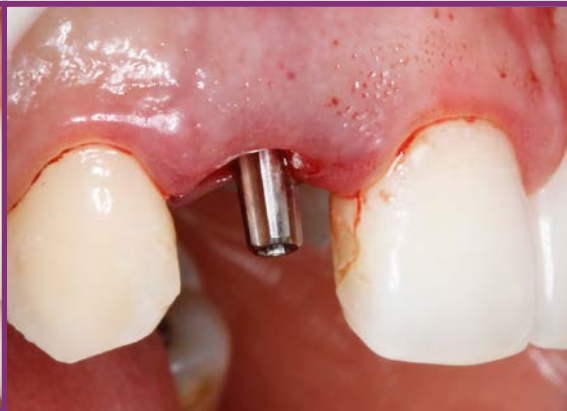*Extraction site
- mesially oriented*



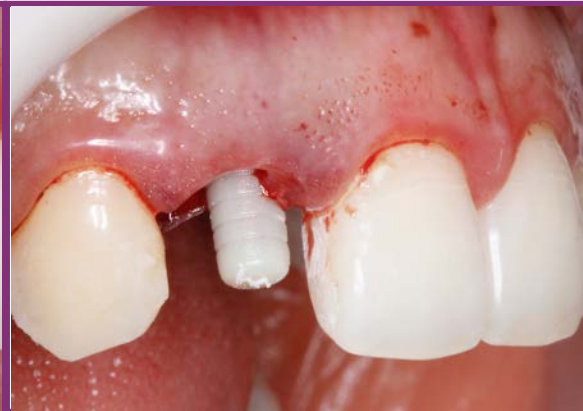*Implant bed preparation
- drill extension*



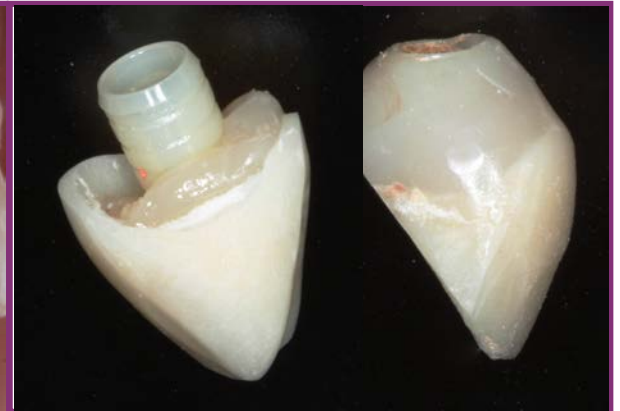Implant placement



Abutment in place

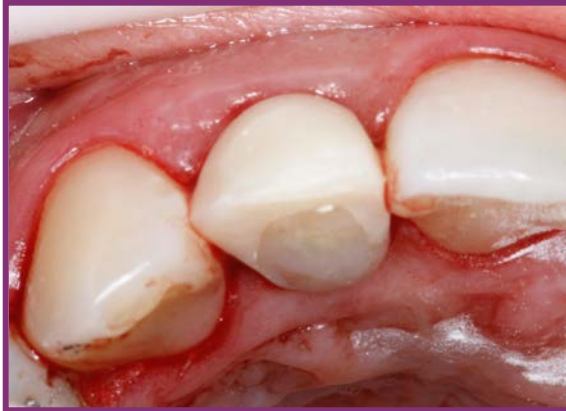

Universal Abutment provisional coping in place

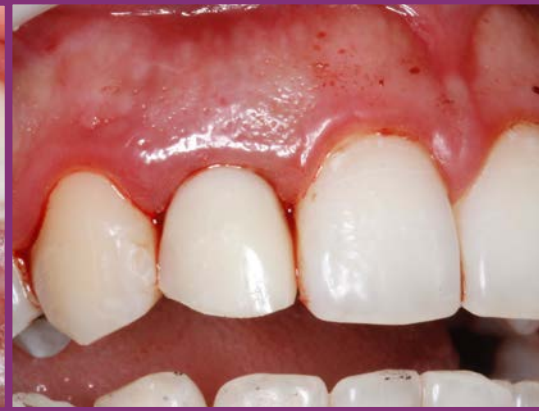

*Provisional universal abutment coping
captured into prefabricated crown shell*

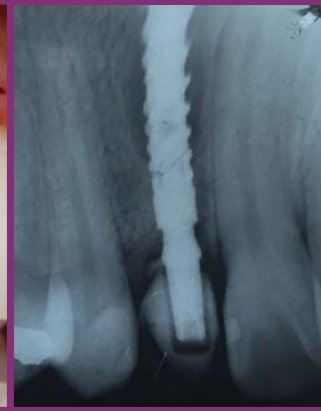Clinical Case



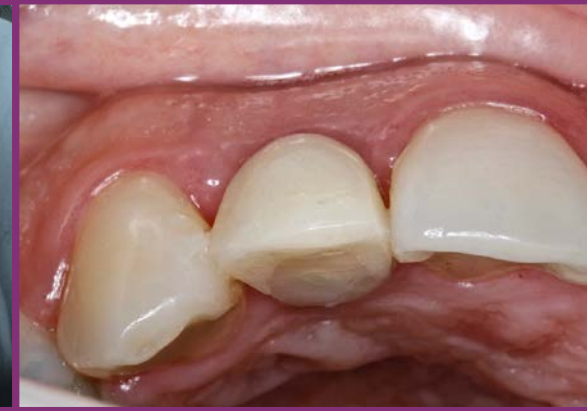*Provisional restoration in place
- occlusal view*



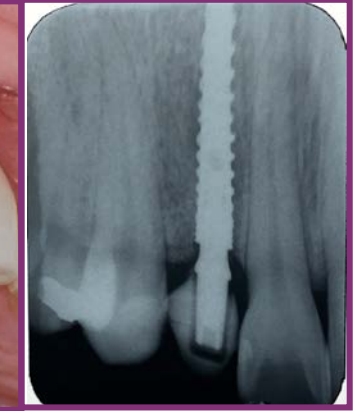*Provisional restoration in place
- labial view*



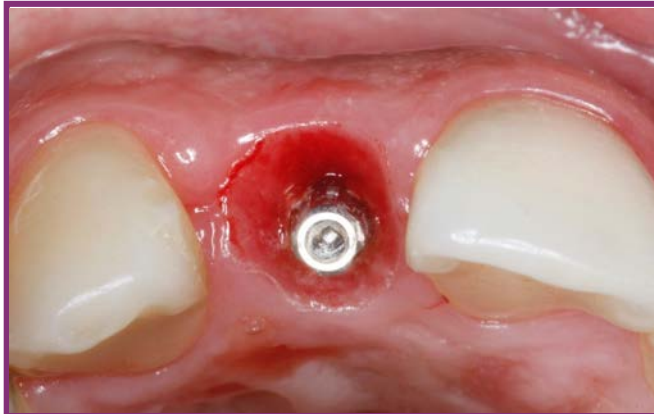Immediate post op. x-ray



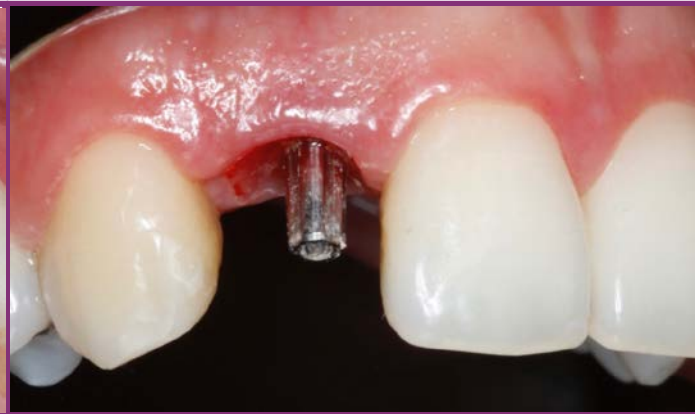*Provisional restoration occlusal view
4 months after surgery*



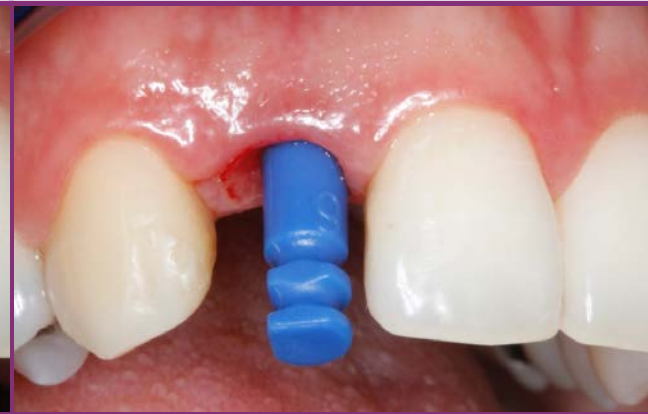*3 month post provisional
restoration X-ray*



Great emergence profile 4 months after surgery

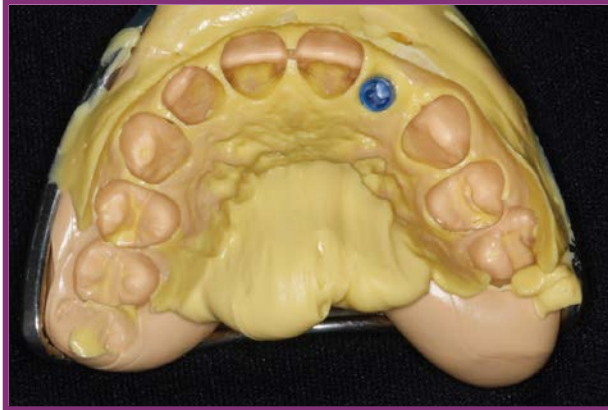

Stable soft-tissue contour 4 months after surgery

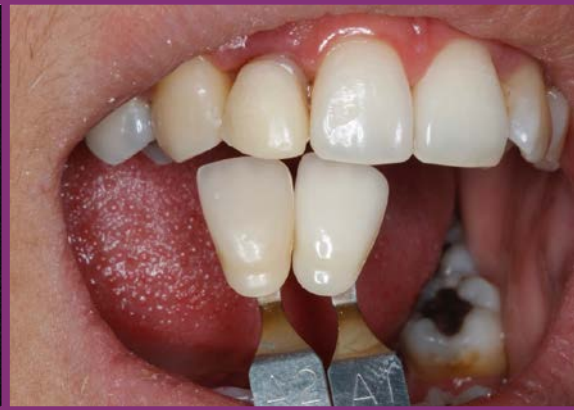

Universal abutment impression coping in place

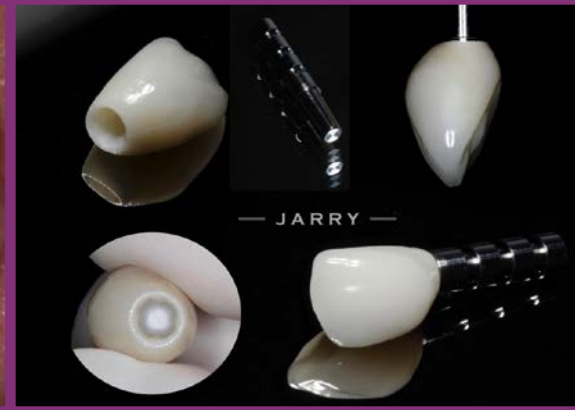Clinical Case



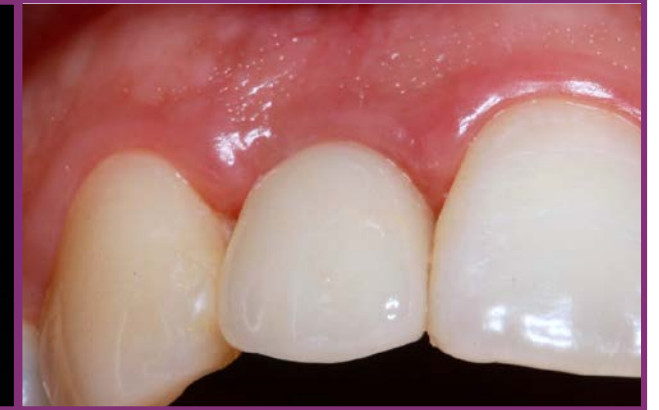Impression taken



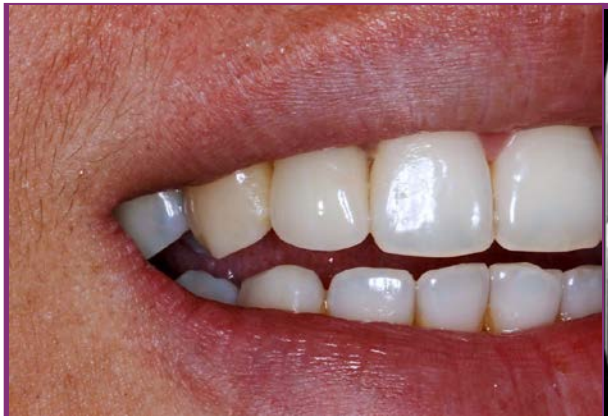Shade selection



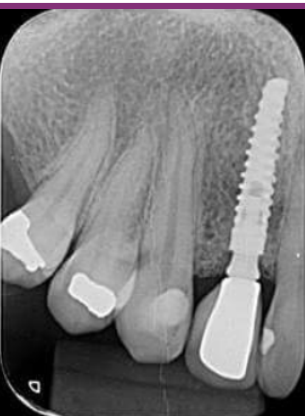Porcelain applied to Zirconia coping



*Final restoration in place
Close-up*



*Final restoration
Extra-oral lateral view*



2-year follow-up X-ray