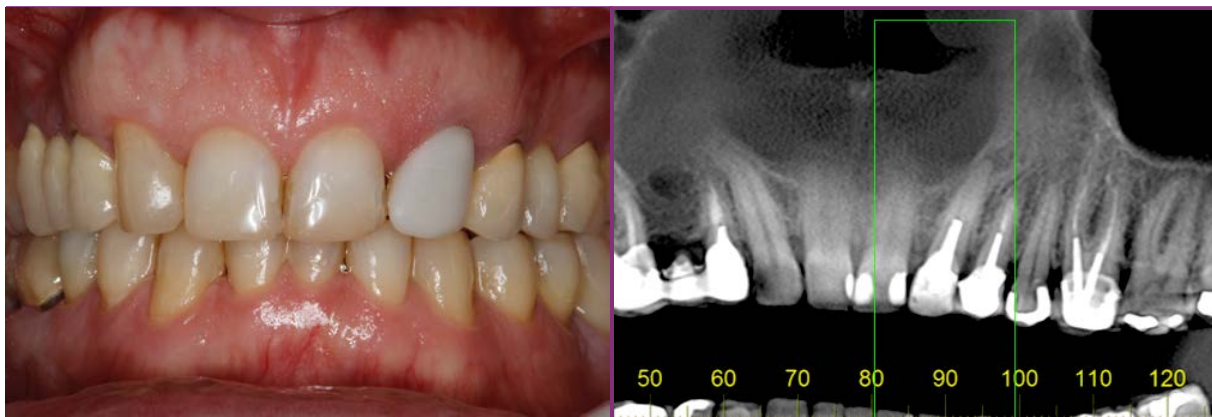


Clinical Case



CM Drive NeoPoros



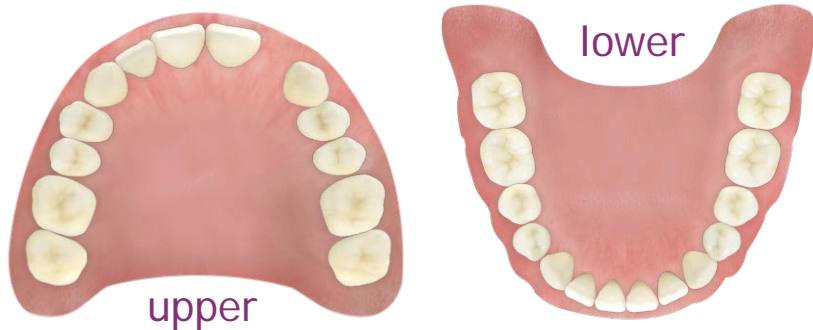Initial Situation

Dr. Christian Jarry
 - Brasília, Brazil
 - Oral Surgeon, Periodontist - D.D.S., M.Sc., Ph.D



- Profile: V.B.
Male, 37 years old
Brasília, Brazil
- Clinical Situation:
Tooth 23 at the position of #22 presenting peri-apical infection and root fracture
- Restorative Solution:
Extraction followed by immediate implant placement and immediate loading, provisional crown on universal abutment with "one-abutment-one-time" concept, finalized with a Porcelain-fused-to-metal crown (PFM) crown

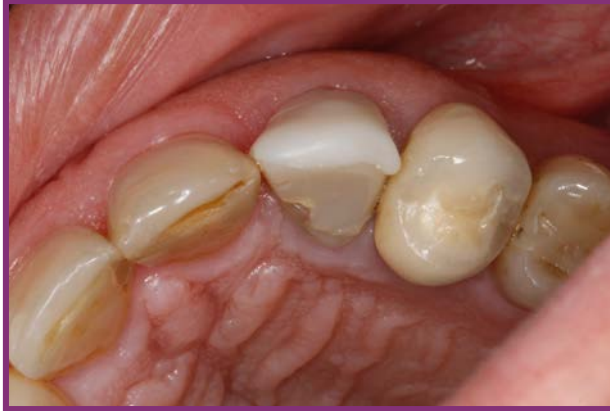Tooth Extraction	Implant Placement	Provisional Restoration	Final Restoration
06/2015	06/2015	06/2015	09/2015



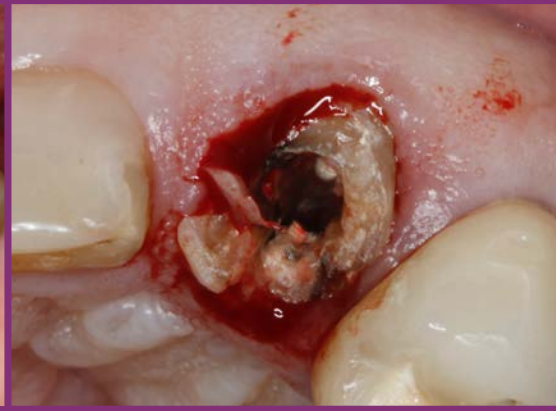Surgical products	Prosthetic products
CM Drive NeoPoros 4.3 X 13mm	CM Universal abutment non-exact 3.3 X 6 X 2.5mm

Summary	Immediate loading protocol	
Surgical Description	Maxilla	Anterior
	1 Implant	Non guided surgery
Restorative Solution	Conventional	PFM

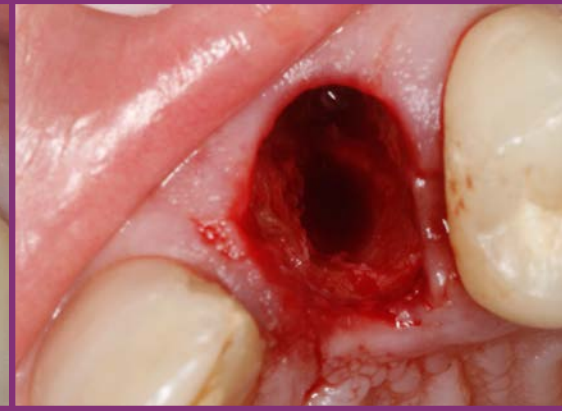Clinical Case



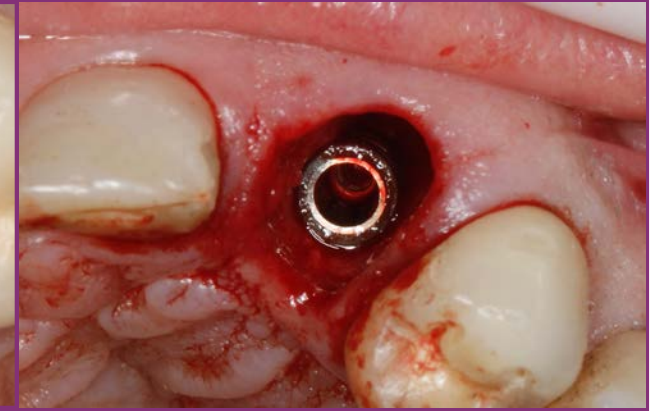
Pre-operative occlusal view



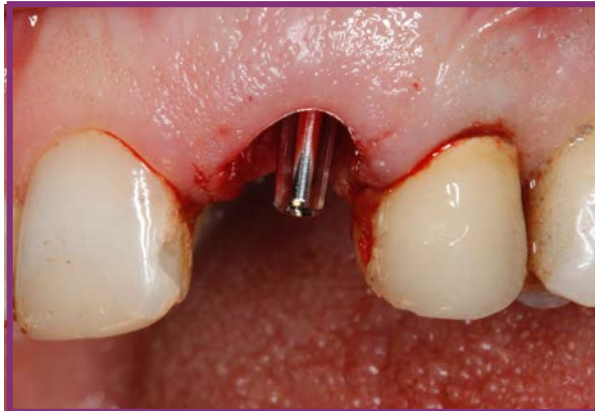Crown removal - visible fracture



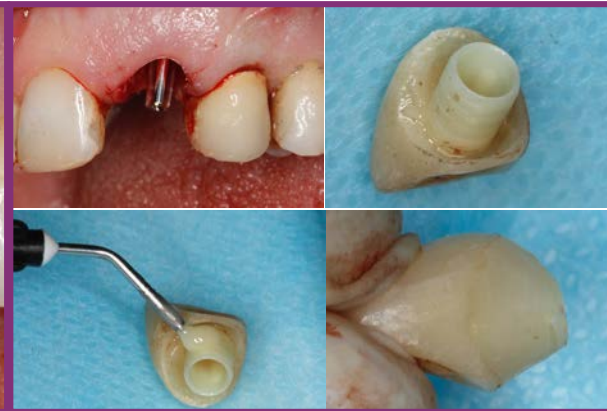
Implant bed preparation



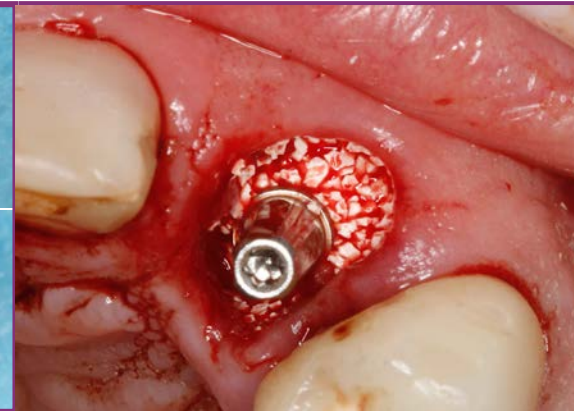
Implant in place allowing adequate gap management



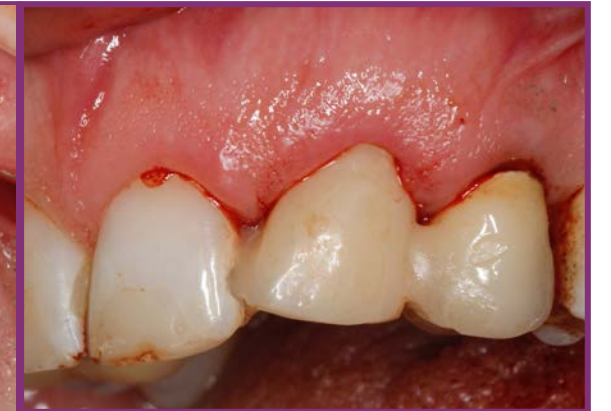Abutment in place



Provisional universal abutment coping captured into prefabricated crown shell

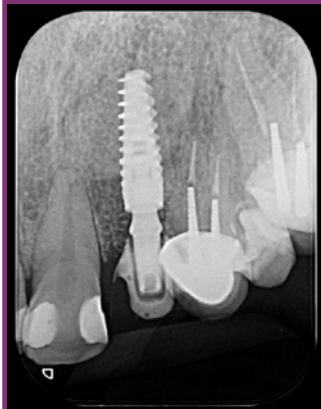

Gap management with synthetic bone substitute

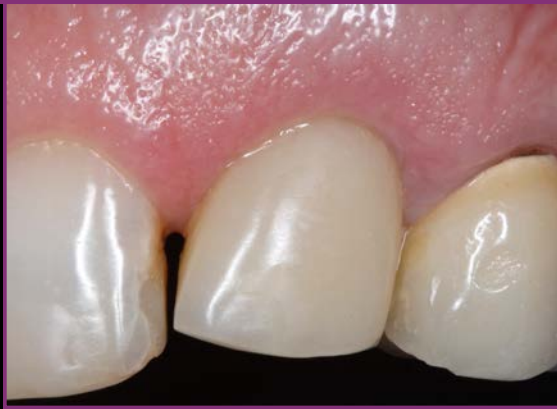

Provisional crown in place together with splinting to adjacent teeth

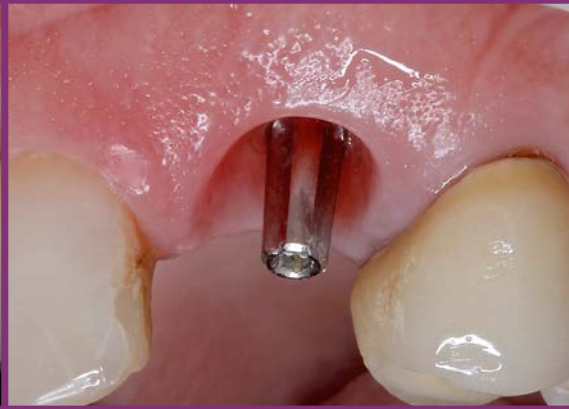Clinical Case



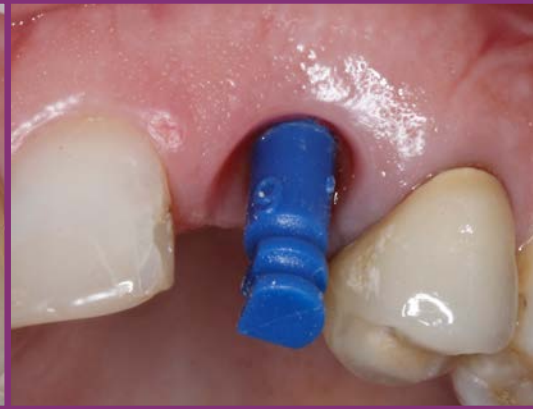*Immediate post-operative
X-ray*



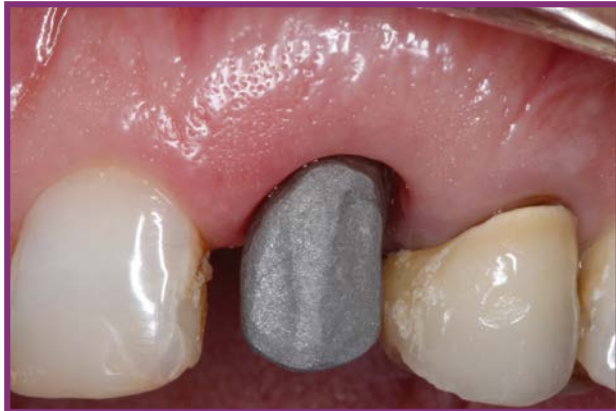*Stable soft tissue contour
40 days after surgery*



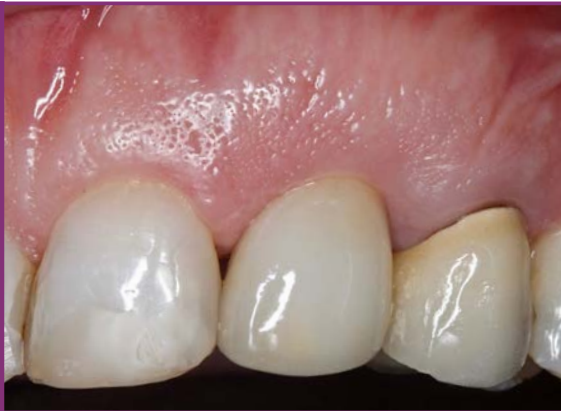*Great emergence profile
3 months after surgery*



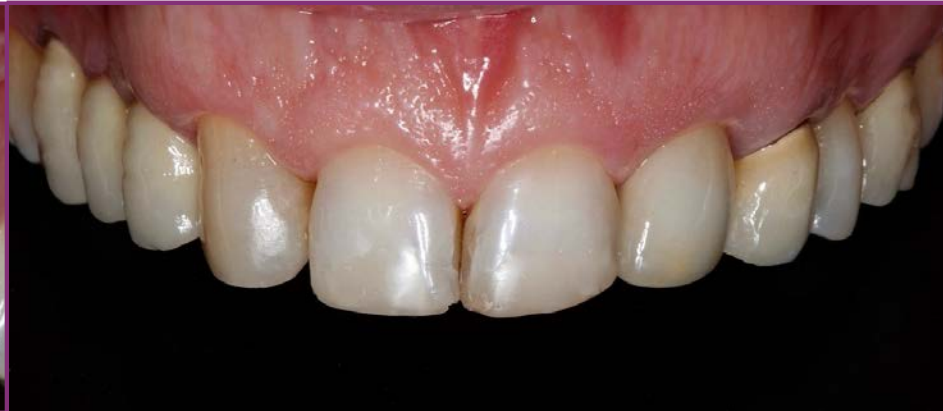*Universal abutment impression coping
in place*



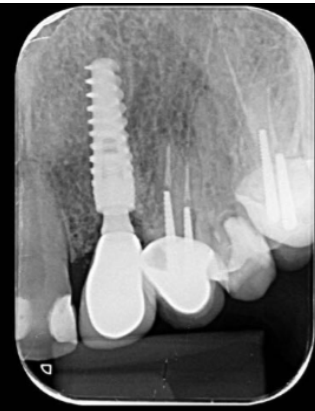Alloy coping try in



*Final restoration in place
Close-up*



*Final restoration
intraoral frontal view*



*2-year follow-up
X-ray*