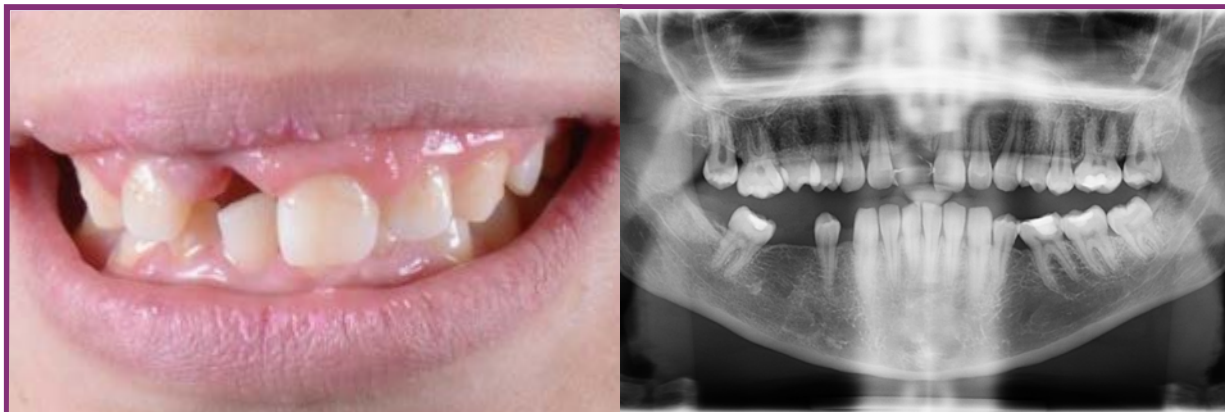

Clinical Case



CM Drive Acqua

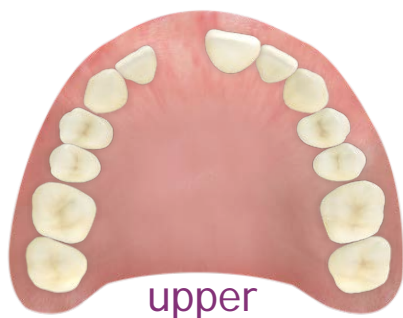

Initial Situation

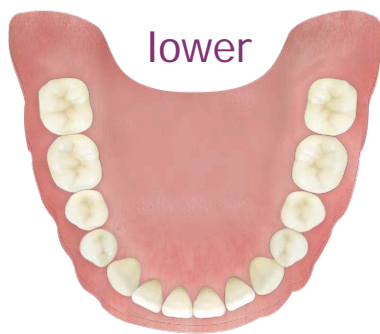

Dr. Angelo Marangini

- Graduated in dentistry, University of Naples Federico II in 1988
- Contributor to the evolution of the cone metric connection in the Mac System in 1999
- Specialized with Lode in Laser Therapy, University of Genova in 2005
- Tutor at the Institute of Anatomy of Liège in 2010
- Lecturer of bone grafting techniques in 2014 ~2016



upper



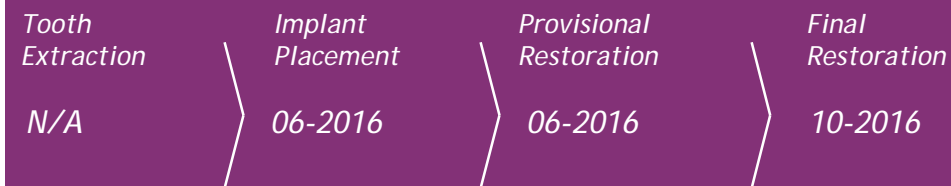lower

Surgical products	Prosthetic products
CM Drive Acqua	CM Titanium Base Abutment
4.3 X 11.5mm	

- Profile: M.V.
Female, 25 years old
Naples, Italy

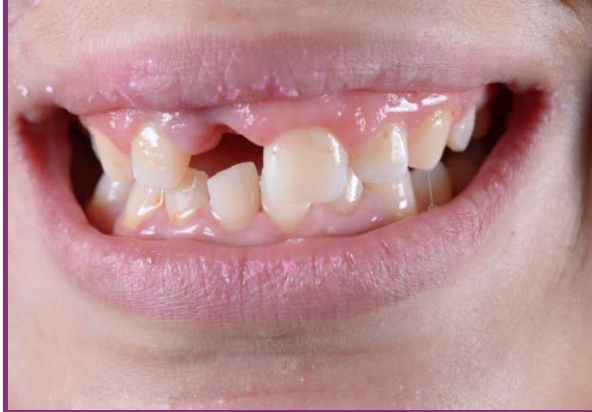- Clinical Situation:
Traumatic avulsion of tooth 11 due to a road-traffic accident which also let to the 21 incisal edge fracture. Tooth 11 was not found.
An implant-supported prosthetic restoration was chosen.
The patient presented to our dental practice the day after the accident demanding an immediate solution the obliged us to operate her within a few hours.

- Restorative Solution:
Implant placement in support to an immediate zirconia/ceramic provisional crown, considering the esthetic needs of the patient and the short time available to produce it in laboratory

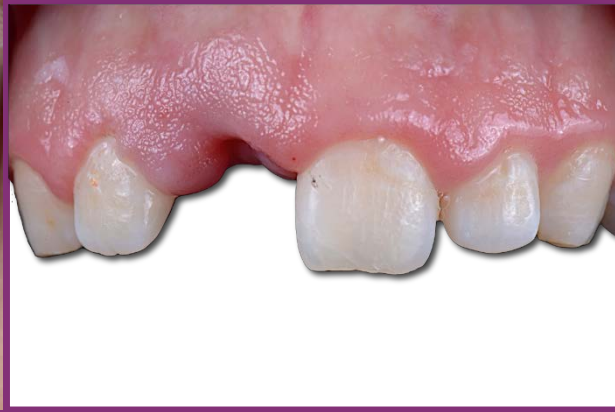

Summary	Immediate Loading Protocol	
Surgical Description	Maxilla	Anterior
	1 implant	Conventional
Restorative Solution	Conventional	Zirconia / Ceramic

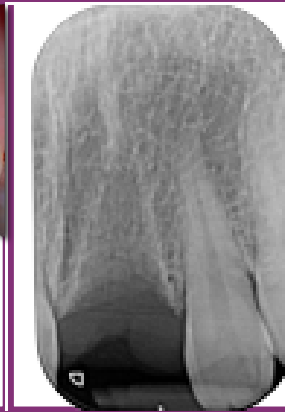Clinical Case



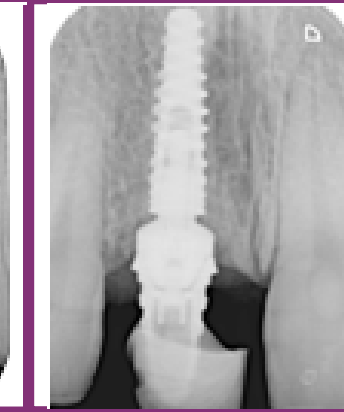
Pre-operative extra oral frontal view



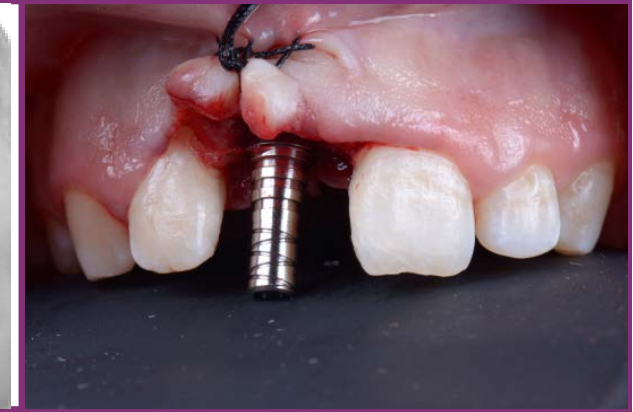Pre-operative intra oral frontal view



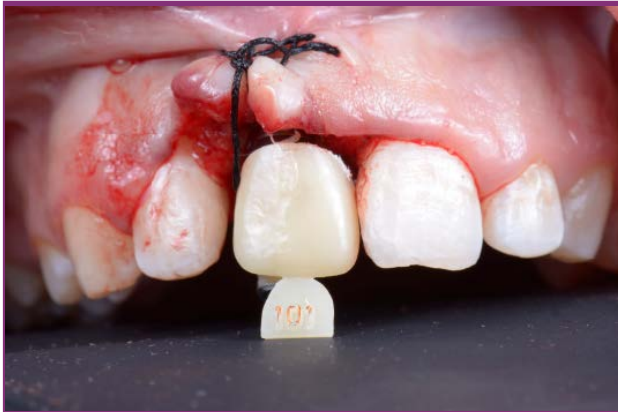
Pre-operative X-ray



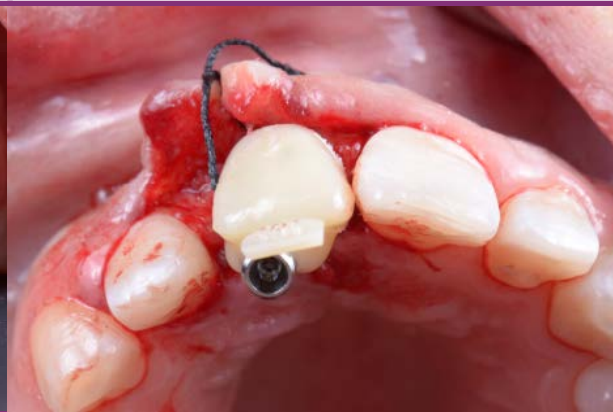
Post-operative X-ray



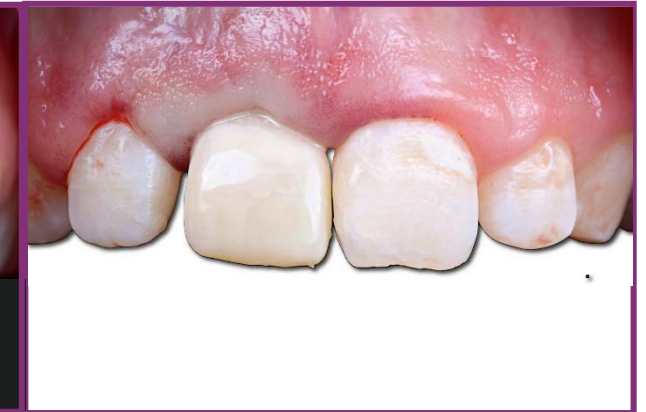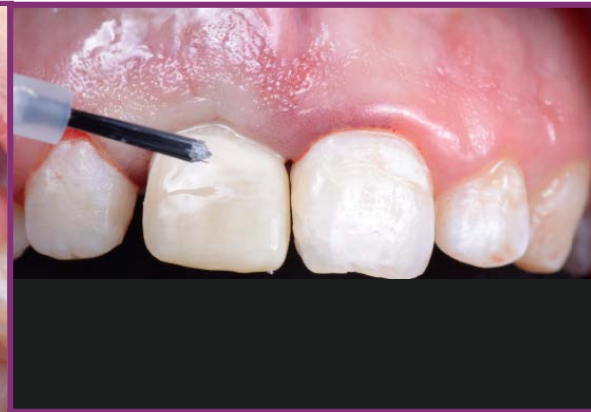
Abutment coping in place



Immediate provisional restoration in place

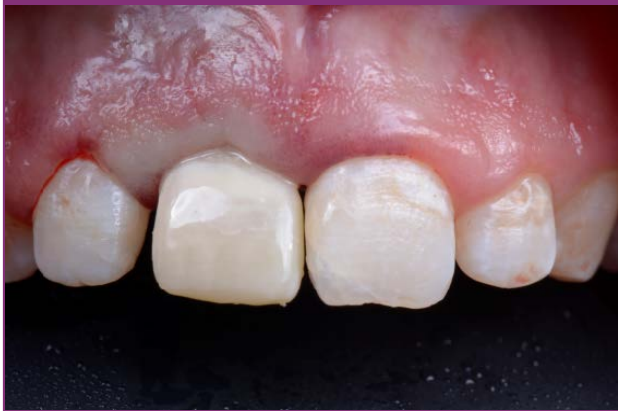

Immediate provisional crown on to the abutment coping - occlusal view

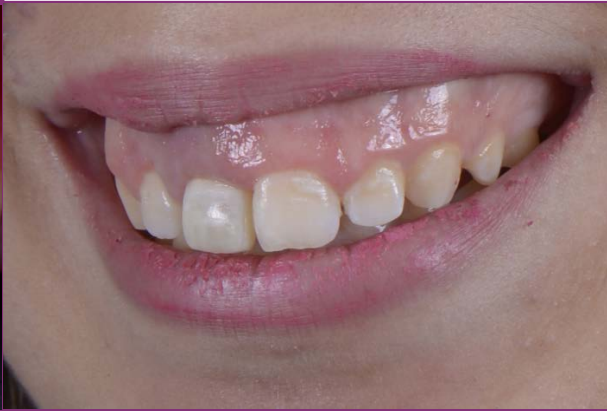

To improve the appearance of the provisional, super-colors and transparent paints were used directly at the chairside

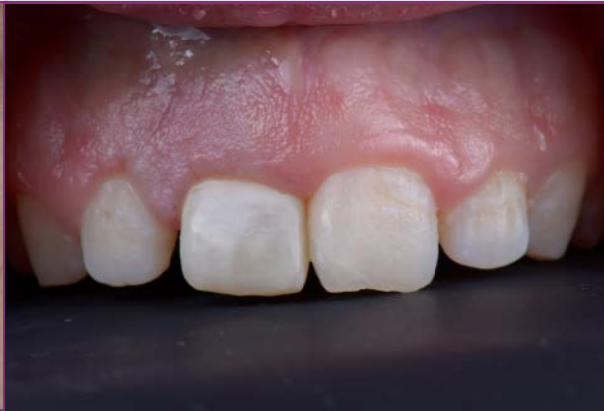Clinical Case



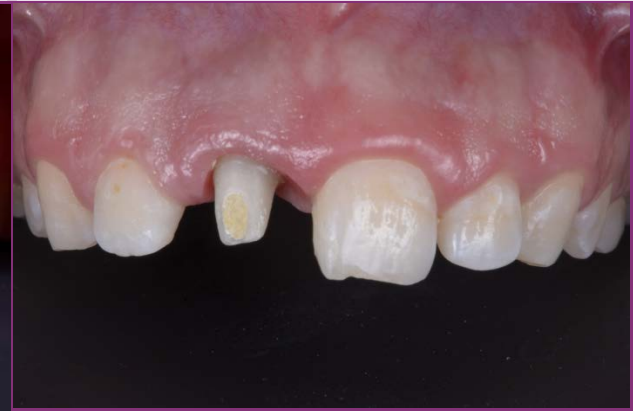*Screw-retained provisional crown in position
Palatal suturing technique was performed to
avoid visible suturing knots in the buccal side.*



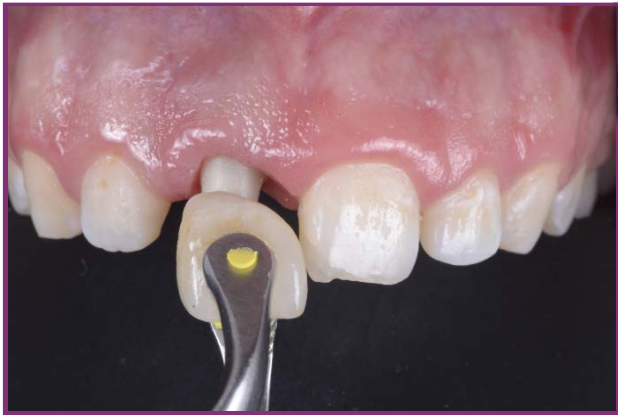*Immediate post-operative
extra oral frontal view*



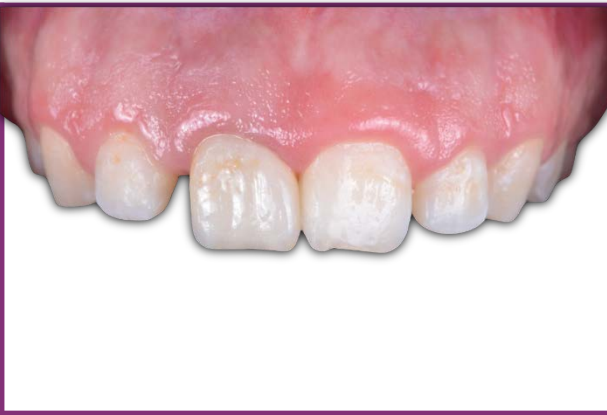*Good soft-tissue healing
one month after surgery*



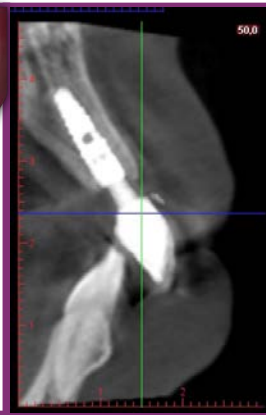
Zirconia coping on CM titanium base abutment



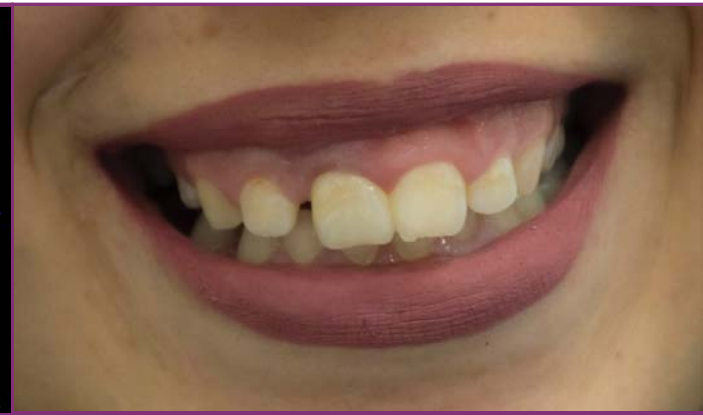Crown seating



Final restoration 4 months after surgery



*1-year follow-up
X-ray*



*1-year follow up
extra oral frontal view*