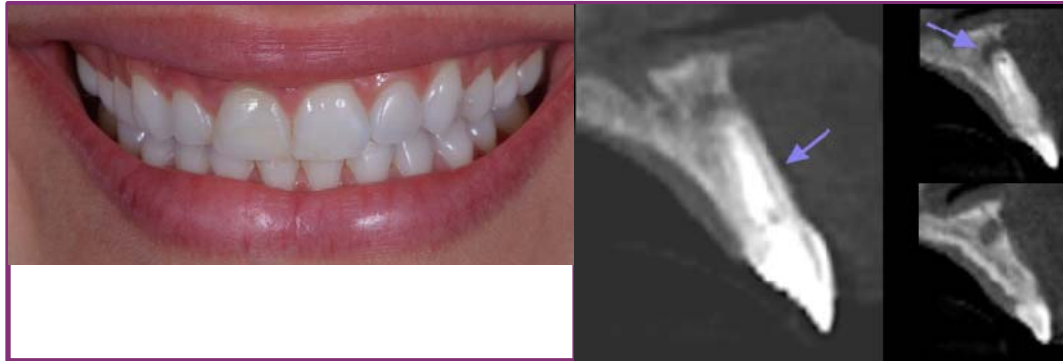



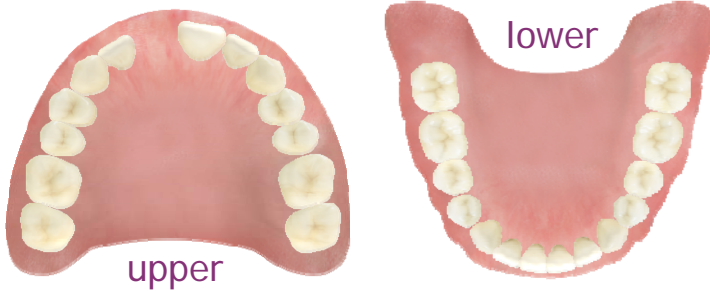CM Drive Acqua



Initial Situation



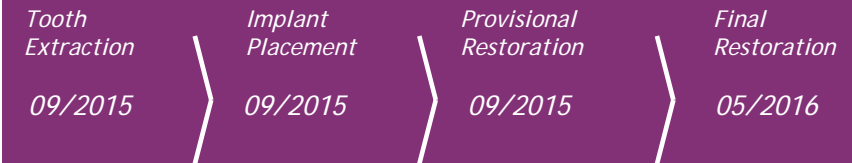Dr. Marcos Motta  
- Rio de Janeiro- Brasil  
- Periodontics/ Aesthetics & Prosthodontics



Surgical products	Prosthetic products
CM Drive Acqua 3.5 X 16mm	CM Universal Abutment Exact 3.3 X 6 X 2.5mm

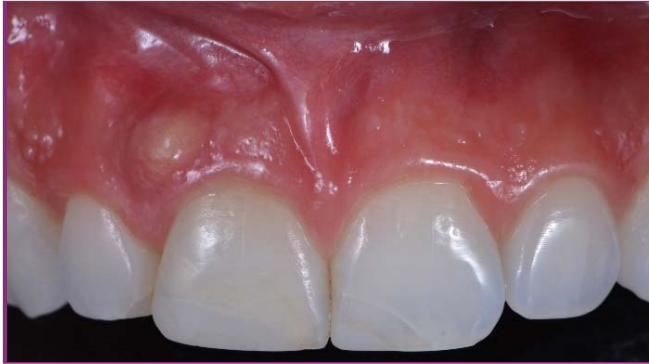# Clinical Case

- Profile: S.M.  
Female, 27 years old  
Rio de Janeiro, Brazil
- Clinical Situation:  
Fractured right central incisor with a critical buccal bone defect
- Restorative Solution:  
Extraction, followed by immediate implant placement, immediate loading, provisional crown on universal abutment with "one-abutment-one-time" concept, finalized with a ceramic crown

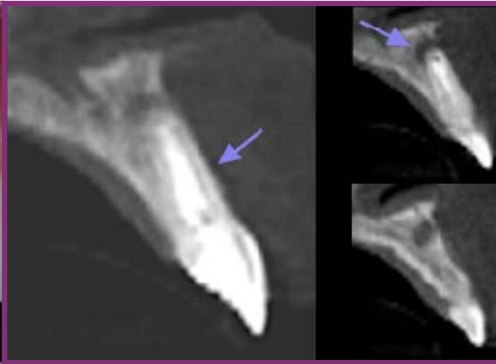


Summary	Immediate loading protocol	
Surgical Description	Maxilla	Anterior
	1 implant	Conventional
Restorative Solution	CAD/CAM	Zirconia ceramic crown

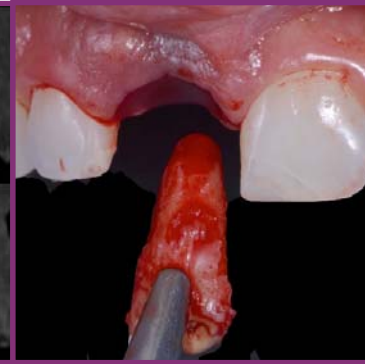# Clinical Case



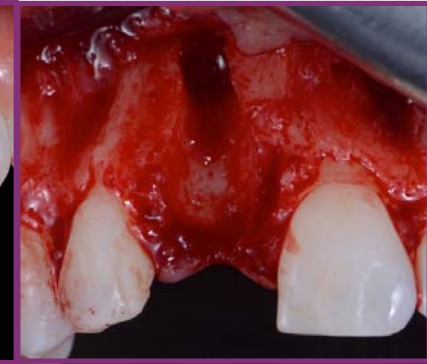*Pre-operative intraoral frontal view*



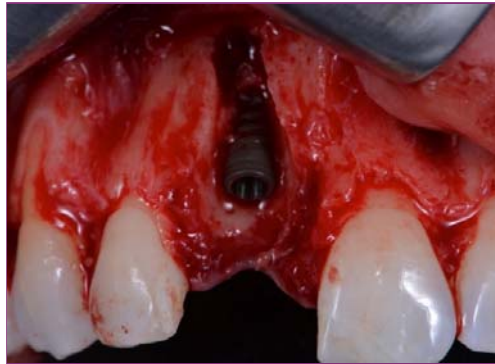
*Pre-operative CBCT*



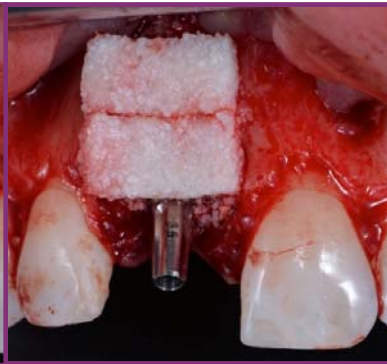*Tooth extraction*



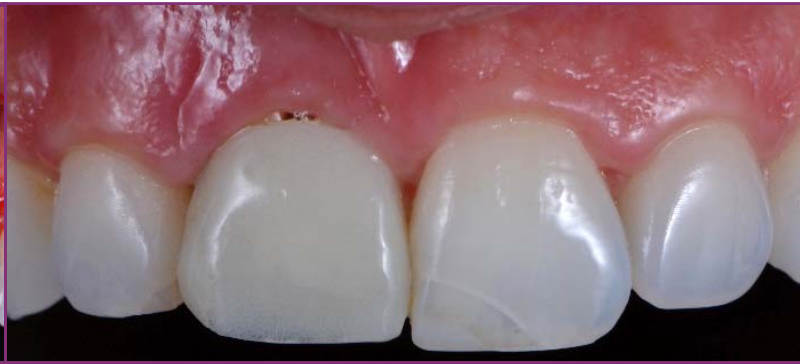*Bone defect*



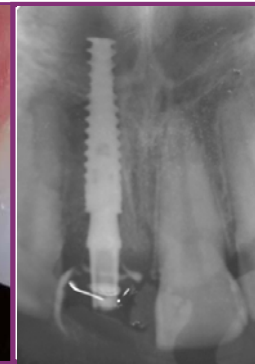
*Implant in place*



*Abutment in place  
Guided bone regeneration:  
Bovine+ Collagen Graft*

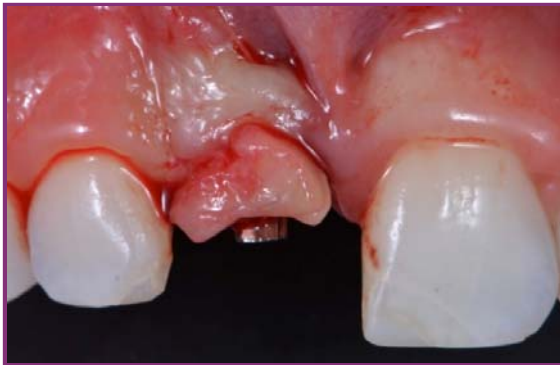

*Provisional restoration in place  
2 weeks after surgery*

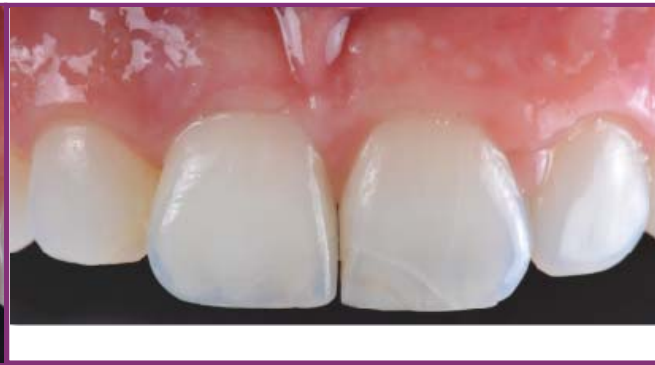

*Post provisional  
restoration X-ray*

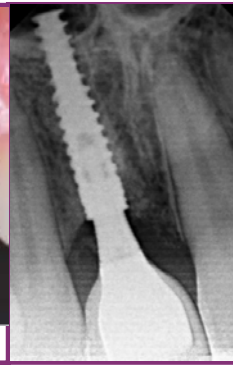
# Clinical Case



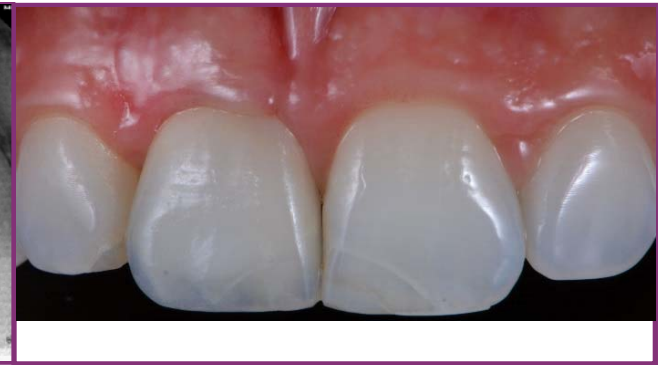*Connective tissue grafting  
4 months after implant placement*



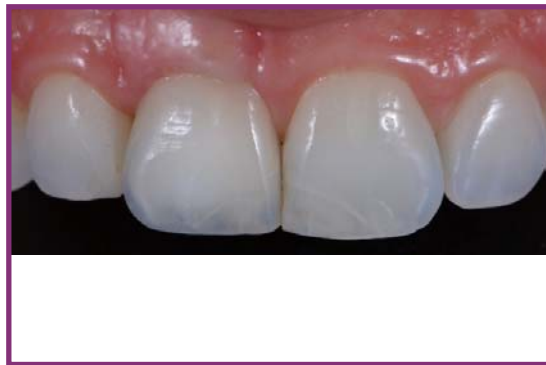*Final Restoration*



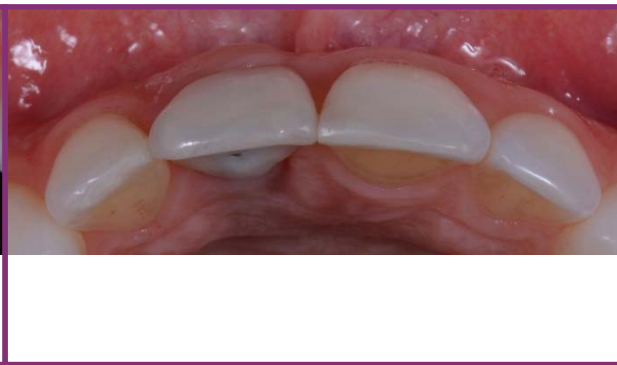*Final restoration  
X-ray*



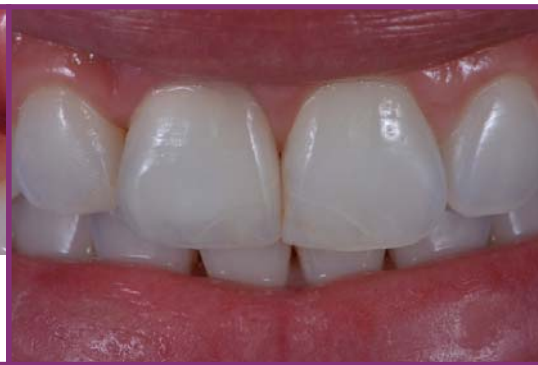*6-month follow up*



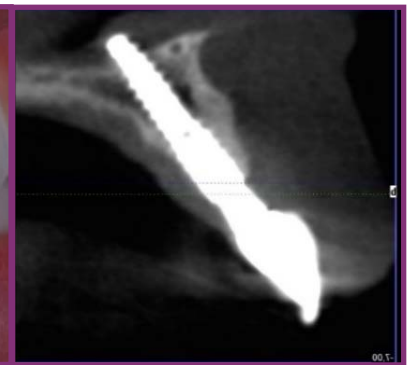*1-year follow up - intraoral frontal view*



*1-year follow up - occlusal view*



*1-year follow up - extra oral frontal view*



*13-month follow-up CBCT*