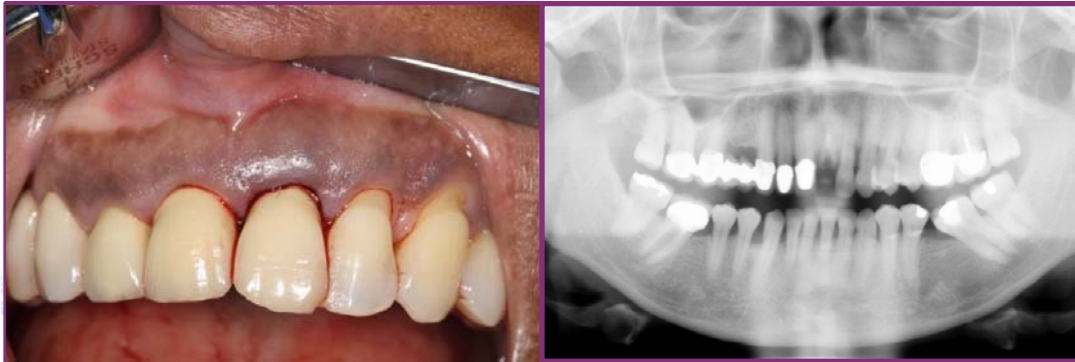



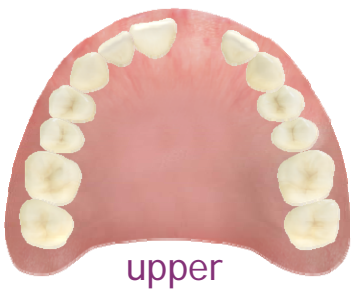CM Alvim NeoPoros



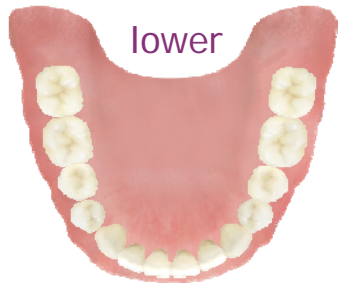Initial Situation



Dr. Sérgio Pereira
Albufeira, Portugal
Oral Surgeon
Aesthetics & Prosthodontics



upper

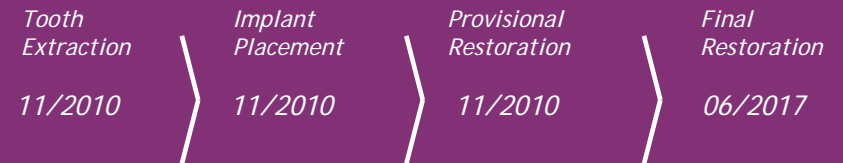

lower

Surgical products	Prosthetic products
CM Alvim NeoPoros 3.5 X 16mm	CM Universal abutment 4.5 X 4 X 5.5

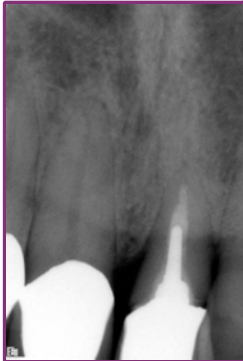Clinical Case

- Profile: M. F.
Female, 62 years old
Albufeira, Portugal
- Clinical Situation:
Left central incisor with a fractured root
- Restorative Solution:
Extraction, followed by immediate implant placement, bone grafting, immediate loading, provisional crown on a universal abutment with "one-abutment-one-time" concept, finalized with a ceramic crown

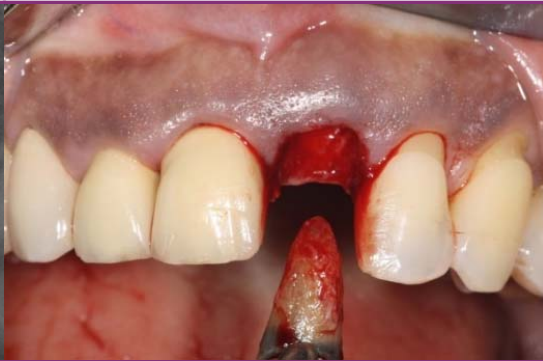

Summary	Immediate loading protocol	
	Surgical Description	Maxilla
Restorative Solution	1 Implant	Conventional
	Conventional	Ceramic crown

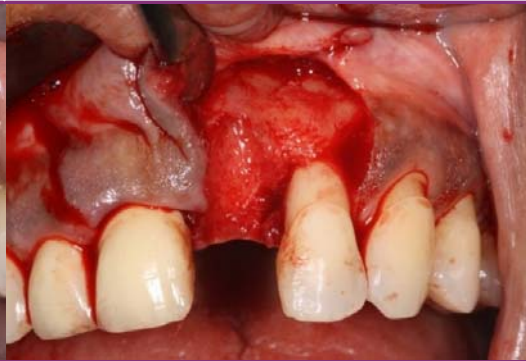Clinical Case



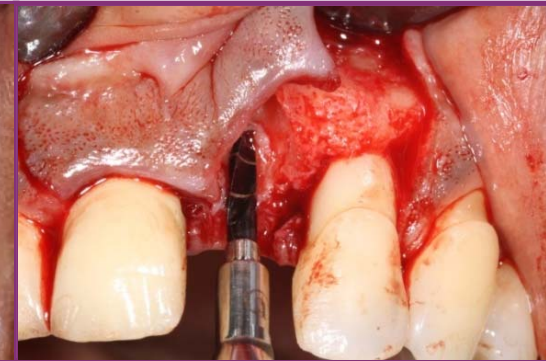
*Pre-operative
X-ray*



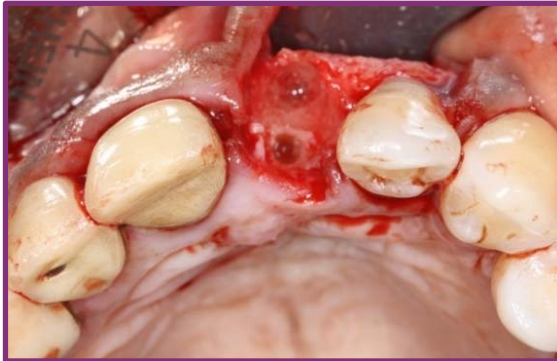Tooth extraction



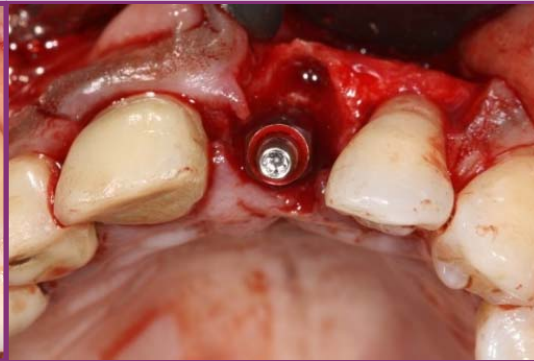
Flap procedure



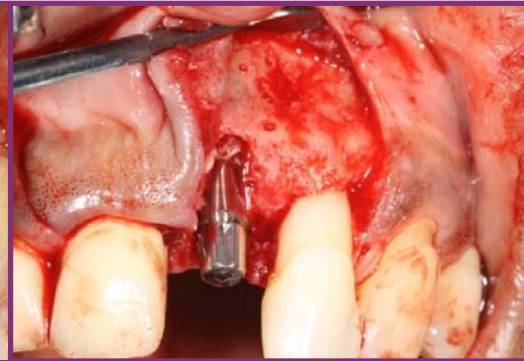
Implant bed preparation



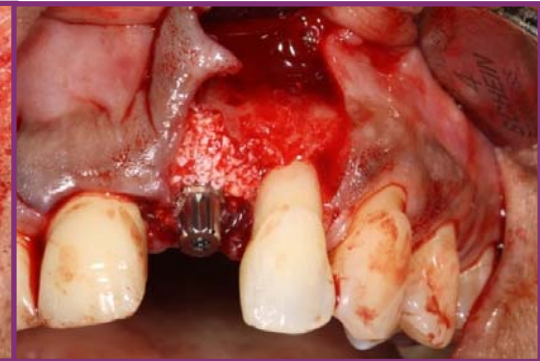
*Extraction site plus initial implant bed
preparation*



Implant and abutment in place

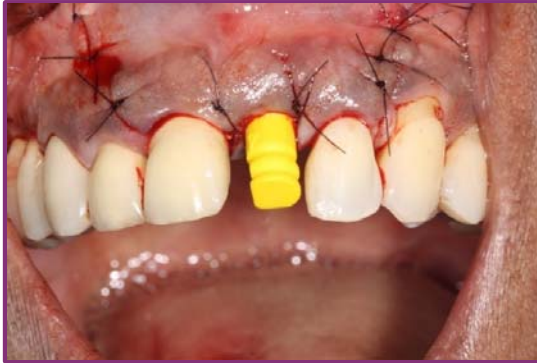

Full flap for bone grafting

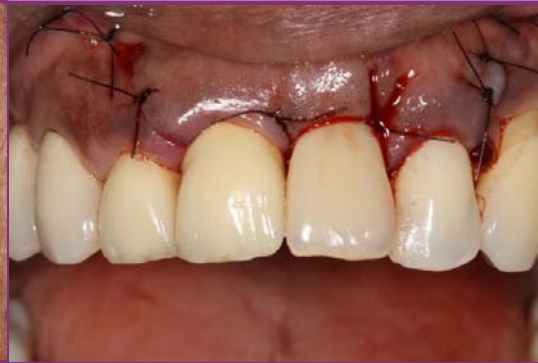

*Bone grafting covering the implant neck and
the abutment neck*

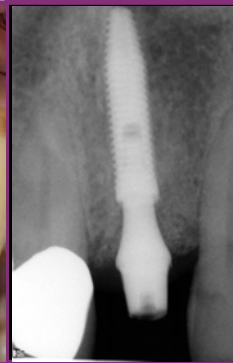
Clinical Case



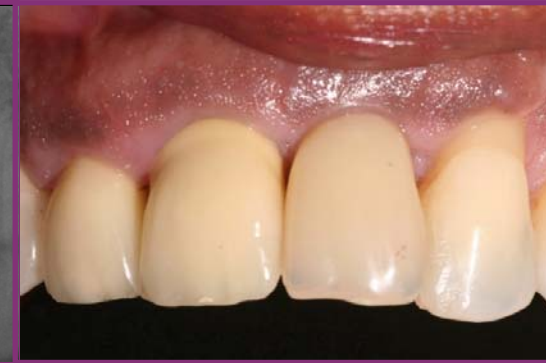Sutures and universal abutment impression coping in place



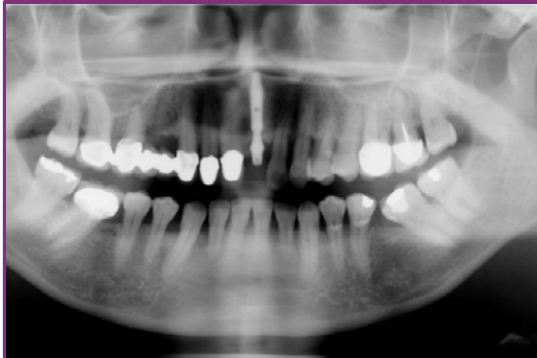Immediate provisional restoration in place



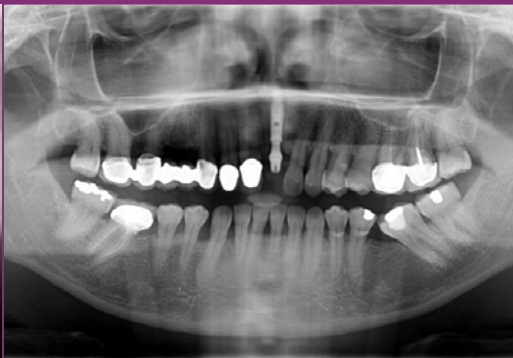Post-operative X-ray



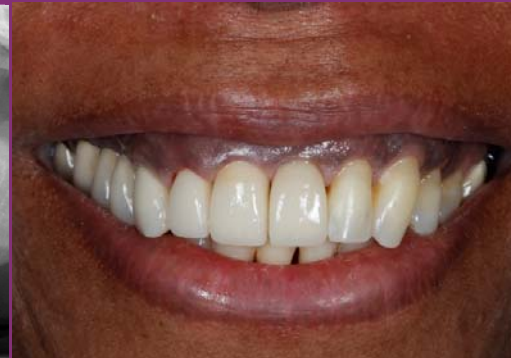6-month follow up - intraoral frontal view



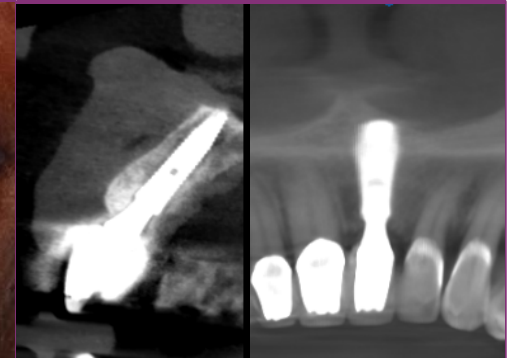
1-year follow-up X-ray



5-year follow up X-ray



Final restoration 6 years and 7 months after surgery



7-years follow-up CBCT