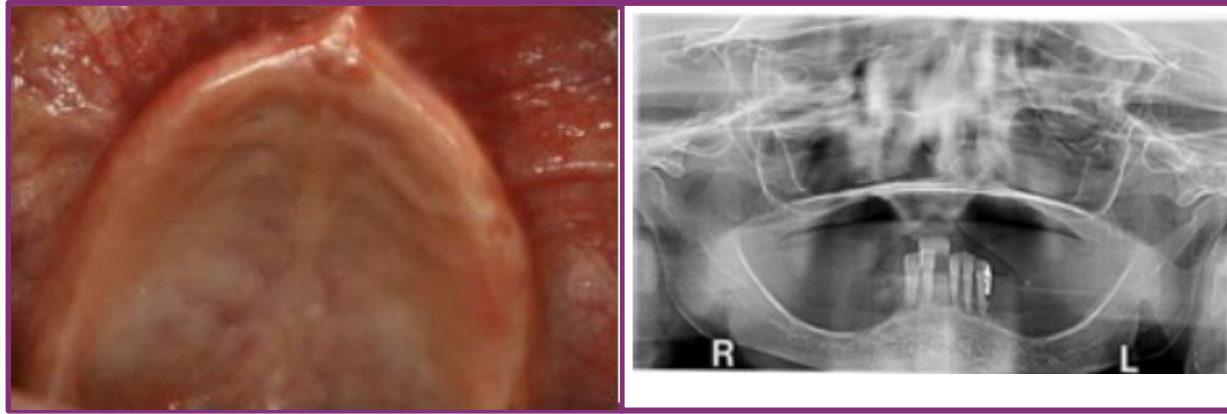


Clinical Case



HE Zygomatic

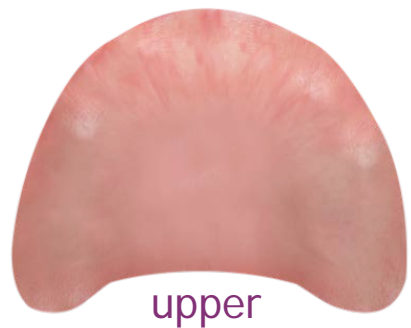

Initial Situation

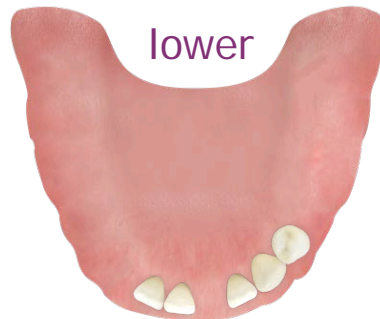

Dr. Enric Pintado

- Barcelona, Spain
- Private practice in Manresa, Barcelona and Andorra
- Graduated in dentistry in Universidad Odontologica Dominicana
- Master in Implatology and Prosthodontics by NYU and Loma Linda University



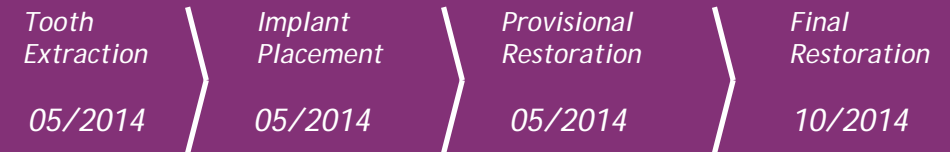upper



lower

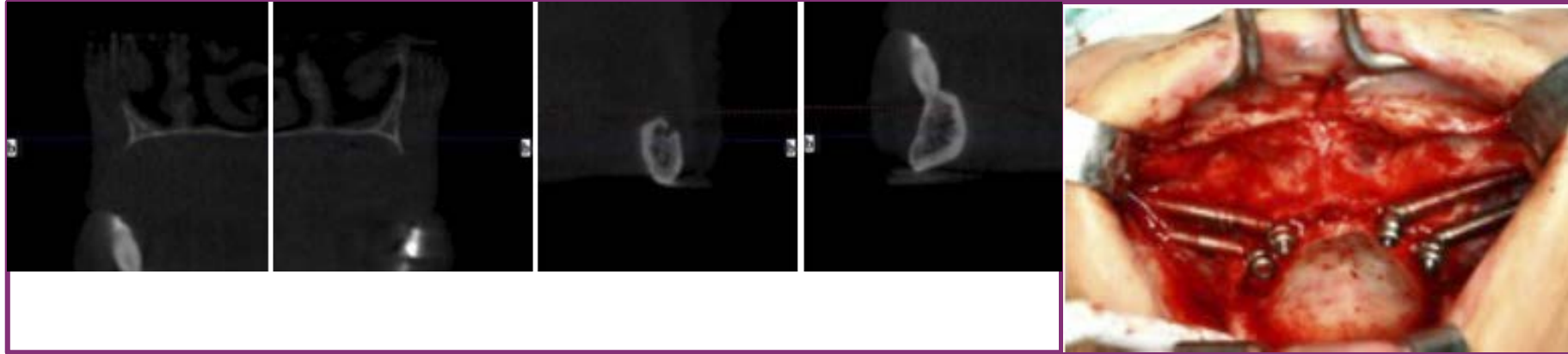
Surgical products
HE Zygomatic 52.5mm 45mm 40mm 47.5mm

- Profile: R. C.
Female, 83 years old
Berga, Spain
- Clinical Situation:
Severe bone resorption in the maxilla and partially edentulous with periodontal disease in the mandible
- Restorative Solution:
4 zygomatic implants in the maxilla. Fixed full arch temporary restorations on the same day of the surgery. Final restoration with metal-resin hybrid fixed prostheses.



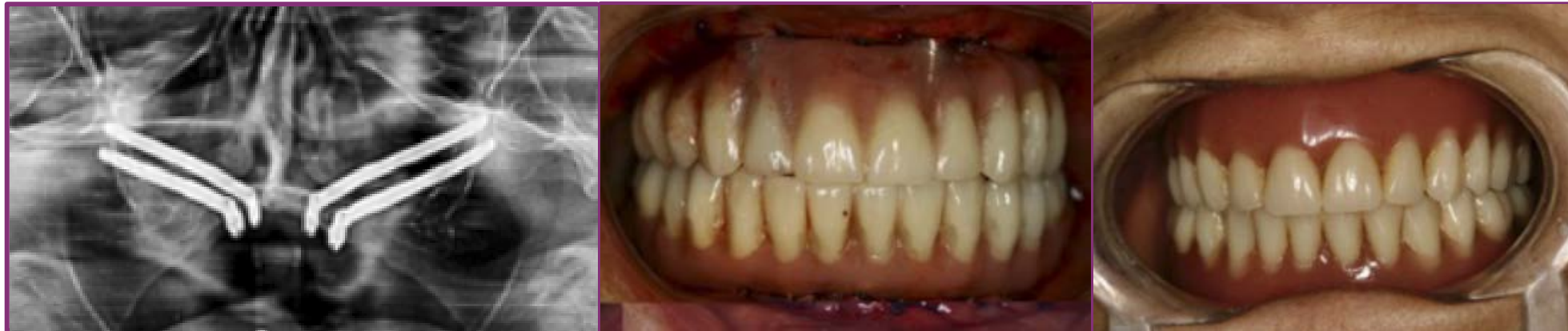Summary	Immediate Loading Protocol	
Surgical Description	Maxilla	Anterior
	4 Zygomatic implants (Maxilla)	Non guided surgery
Restorative Solution	CAD/CAM	Cobalt-chromium bar Resin restoration

Clinical Case



Pre-operative CBCT of tooth 11

4 zygomatic implants in place

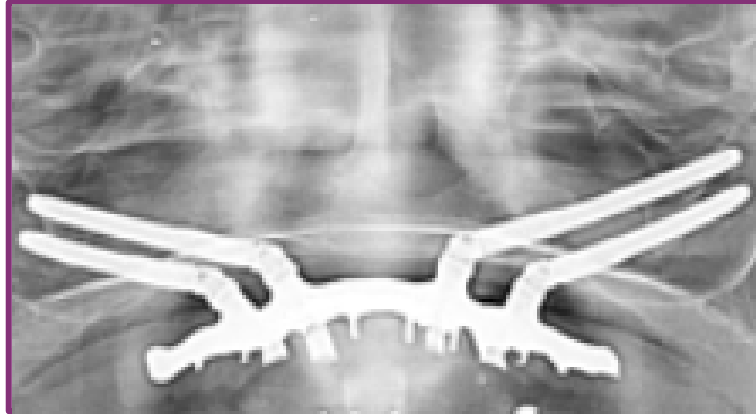


Immediate post-operative X-ray

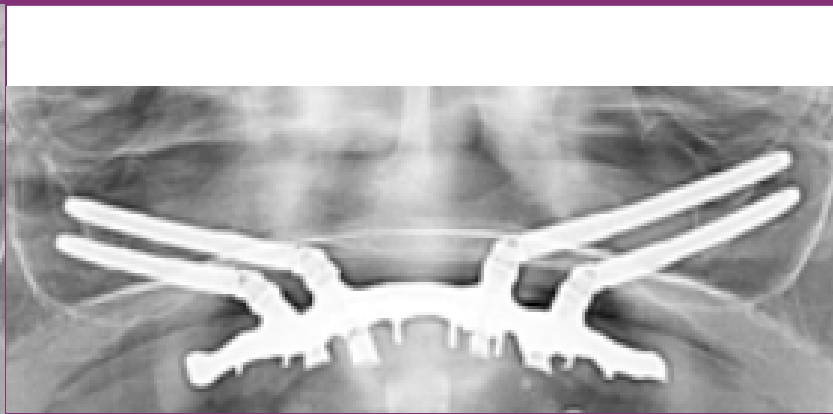
Immediate provisional restoration in place

*Final restoration
- frontal view*

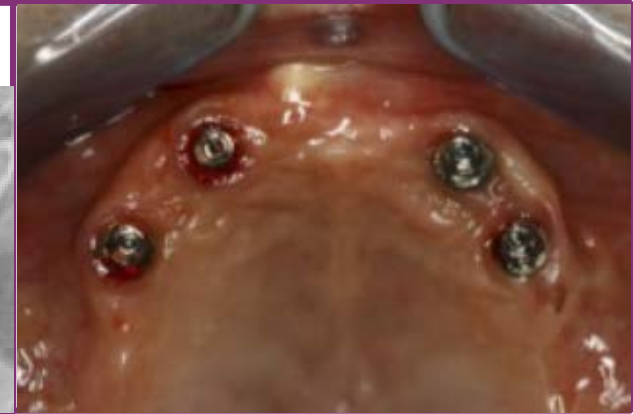Clinical Case



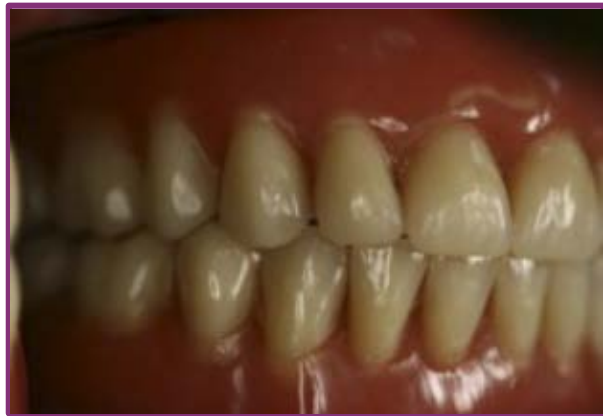Final restoration X-ray



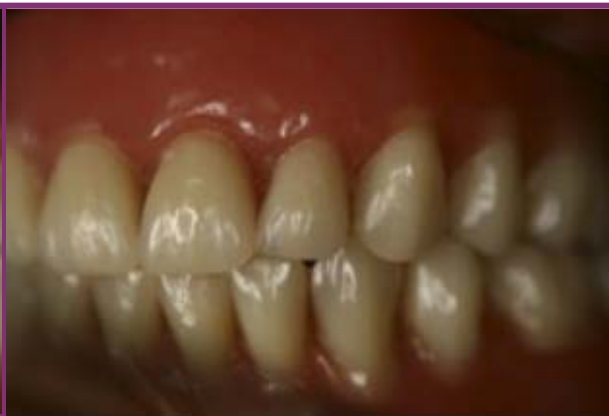1-year follow-up X-ray



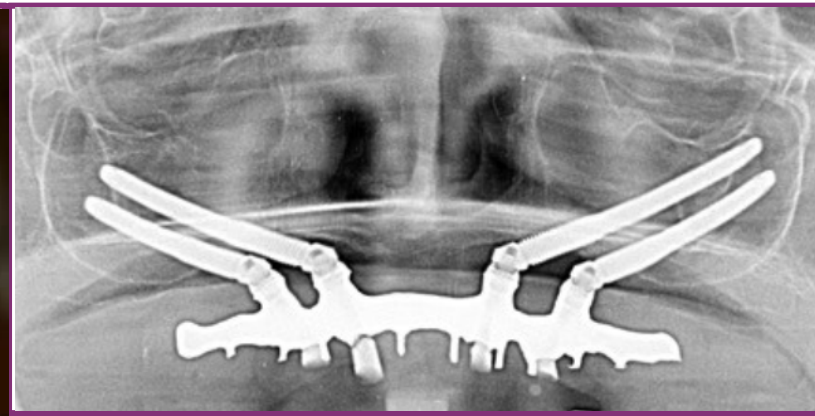1-year follow up - occlusal view



1-year follow up - intraoral right-side



1-year follow up - intraoral left-side



3-year follow-up X-ray