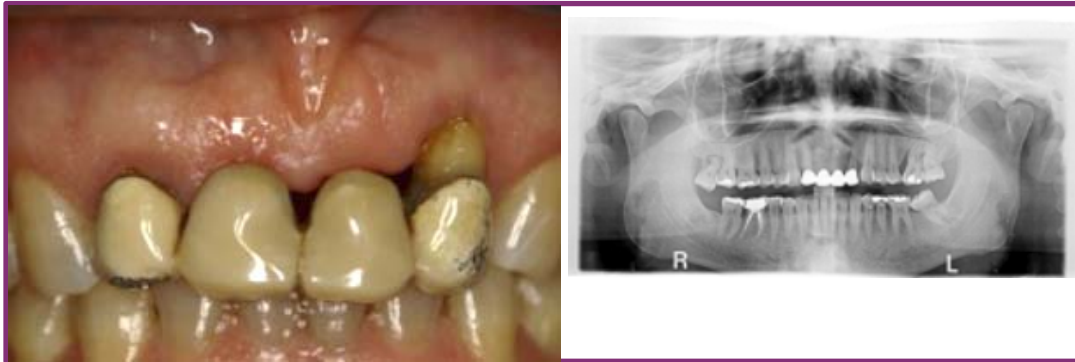



CM Drive NeoPoros

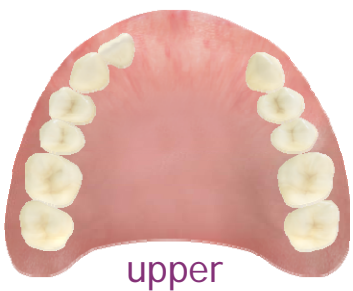

Initial Situation

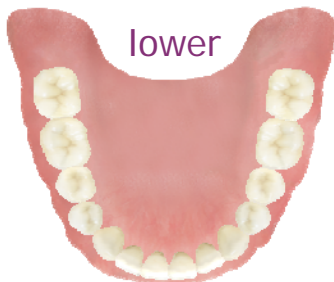

Dr. Enric Pintado

- Barcelona, Spain
- Private practice in Manresa, Barcelona and Andorra
- Graduated in dentistry in Universidad Odontologica Dominicana
- Master in Implatology and Prosthodontics by NYU and Loma Linda University



upper



lower

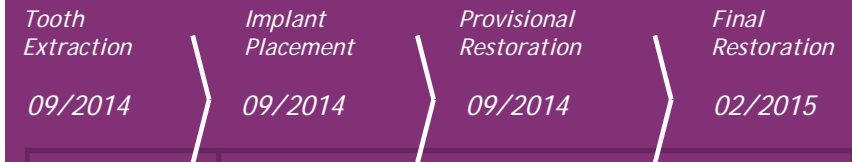
Surgical products	Prosthetic products
CM Drive NeoPoros 4.3 X 10 mm	CM Universal abutment exact 4.5 X 4 X 2.5mm

# Clinical Case

- Profile: A. P.  
Male, 63 years old  
Barcelona, Spain

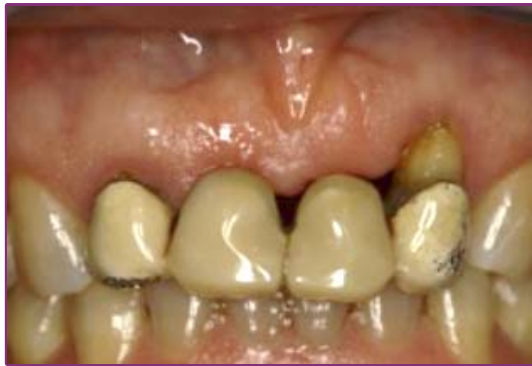- Clinical Situation:  
Periodontal disease with bone loss and soft tissue retraction in anterior maxilla, teeth 12, 11, and 22.

- Restorative Solution:  
Extraction of tooth 12, 11 and 22, followed by immediate implant placement in tooth 11. GBR and soft tissue grating are performed on the same day. Immediate temporization and final zirconia ceramic bridge 6 months after surgery.

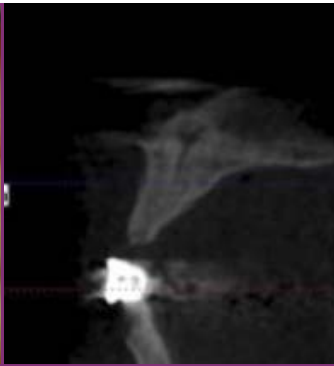


Summary	Immediate Loading Protocol	
Surgical Description	Maxilla	Anterior
	1 Implants	Guided or
Restorative Solution	CAD/CAM	Titanium abutments / zirconia ceramic bridge

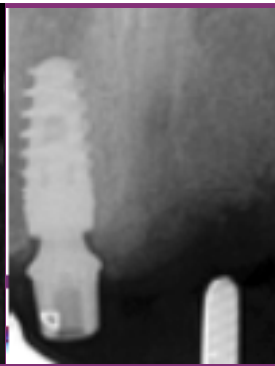# Clinical Case



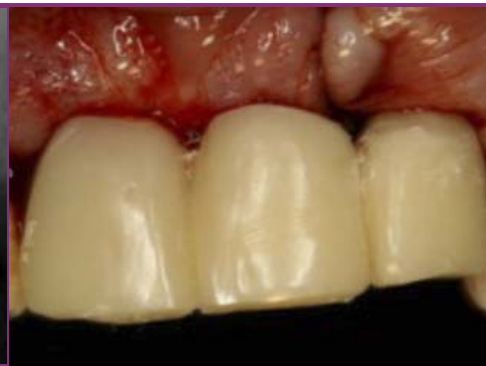*Pre-operative intraoral frontal view*



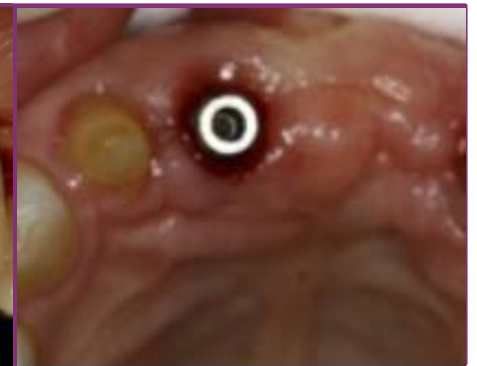*Pre-operative CBCT*



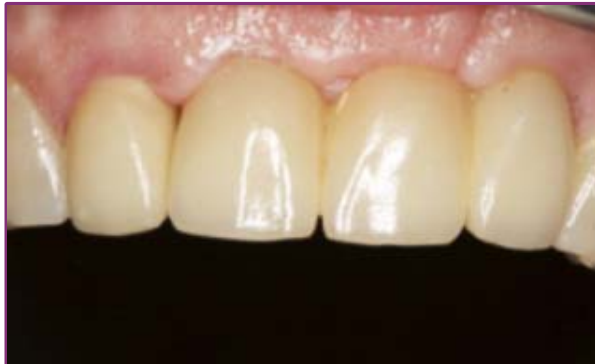*Post-operative X-ray*



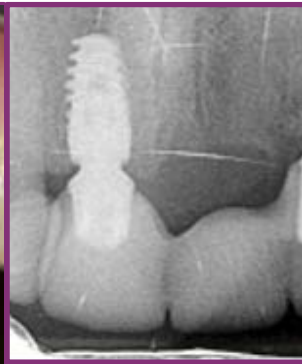*Immediate provisional bridge in place*



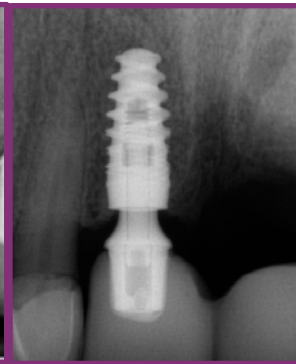
*Good soft-tissue healing  
5 month after surgery*



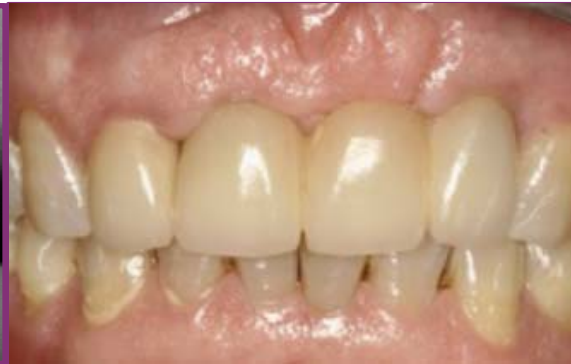*Final restoration 5 months after surgery*



*Final restoration X-ray*



*1-year follow up X-ray*



*1-year follow up - intraoral frontal view*