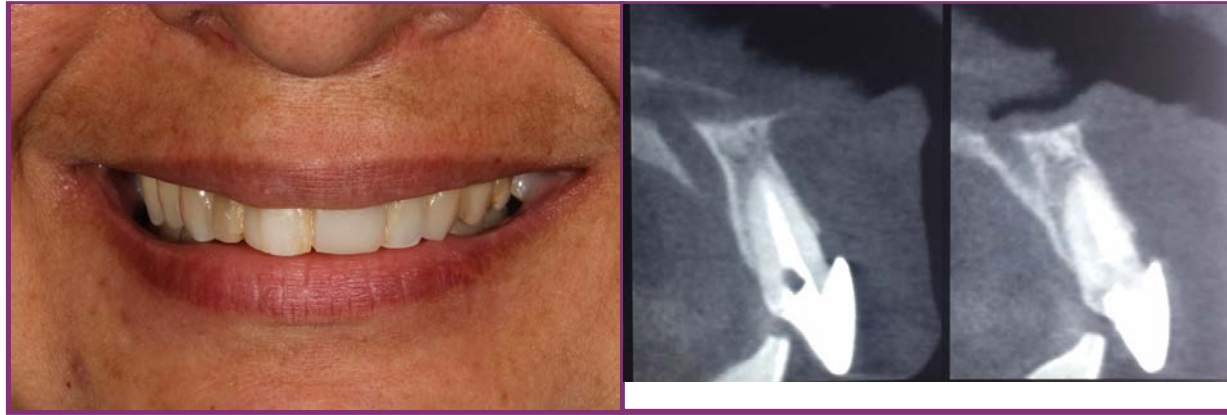

Clinical Case



CM Alvim NeoPoros



Initial Situation

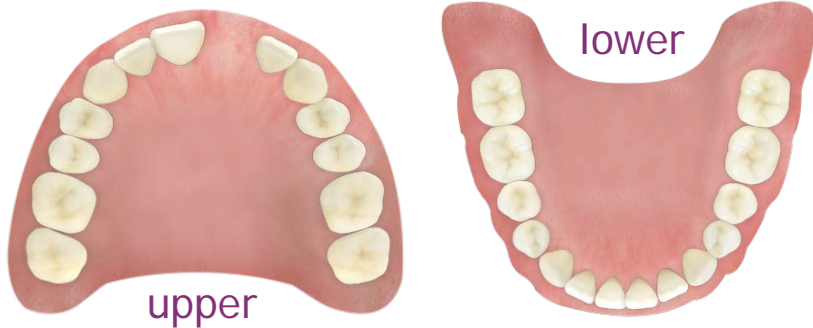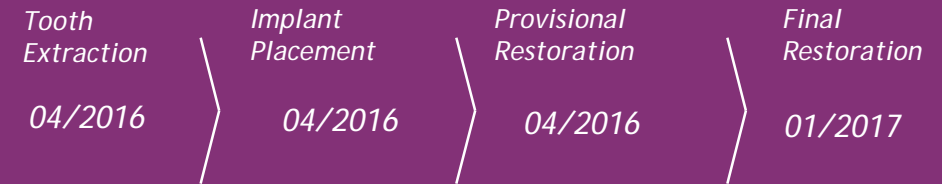- Profile: C.S.
Female, 44 years old
Recife, Brazil

- Clinical Situation: Root resorption in tooth 21

- Restorative Solution:
Extraction, followed by immediate implant placement, immediate loading, a provisional crown on a universal abutment, and finalized with a titanium base abutment and a zirconia ceramic crown



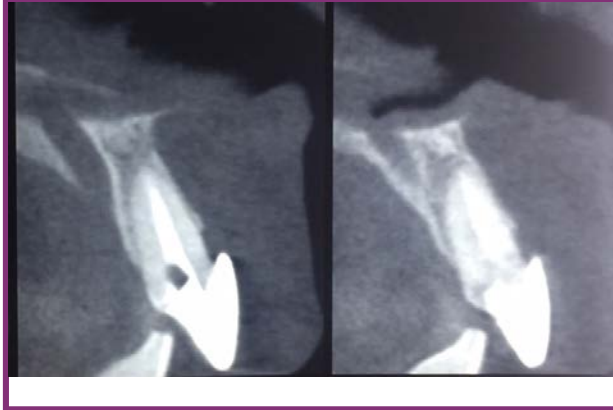Dr. Rafael Siqueira, Recife, Brazil
Dr. Reinaldo Siqueira, Recife, Brazil
Dr. Miguel Braga Pinto, Porto, Portugal
Dr. Paulo Santos, Recife, Brazil
Dr. Bruno Cabral, Recife, Brazil
Mr. Junior Lima, Recife, Brazil



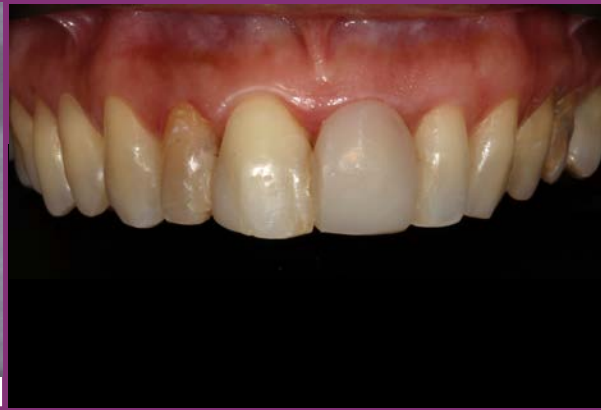Surgical products	Prosthetic products
CM Alvim NeoPoros 3.5 X 13mm	CM Titanium Base 3.5 X 4 X 1.5
	Titanium base with zirconia

Summary	Immediate loading protocol	
Surgical Description	Maxilla	Anterior
	1 Implant	Conventional
Restorative Solution	CAD/CAM	Zirconia ceramic crown

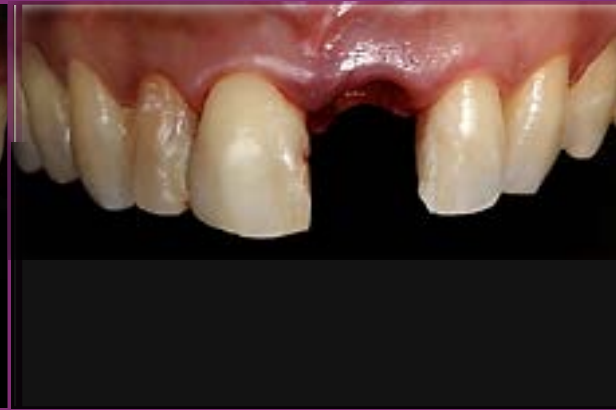Clinical Case



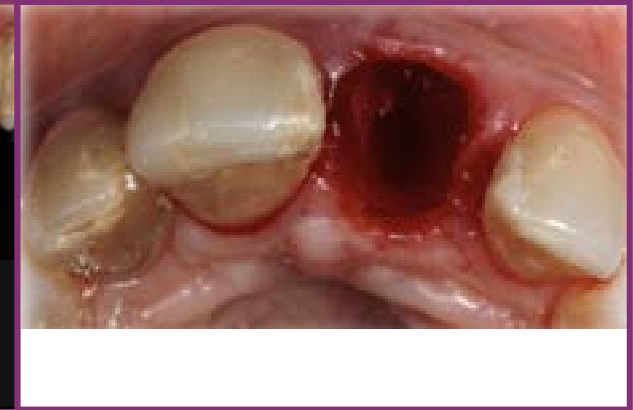Pre-operative CBCT



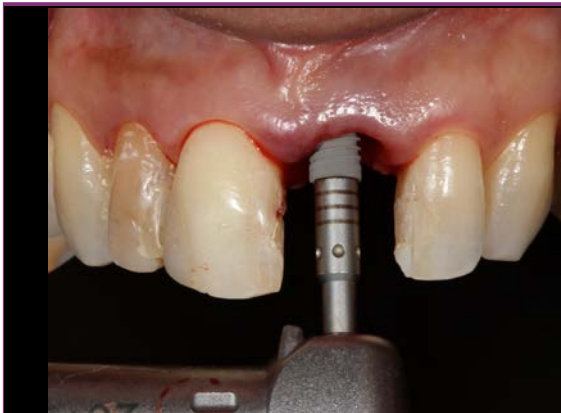
Pre-operative intraoral frontal view



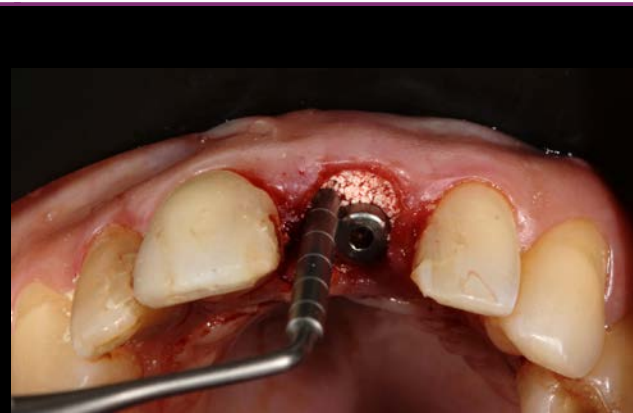Extraction site - frontal view



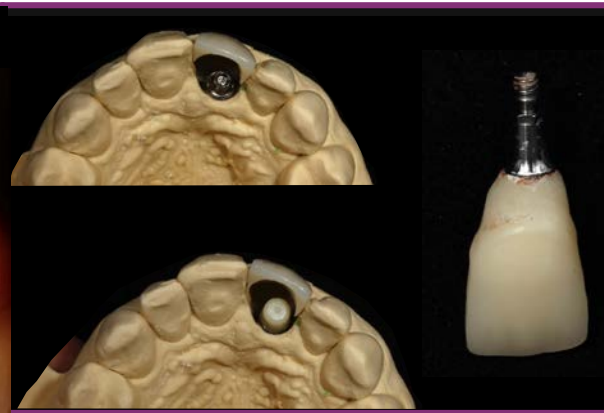Extraction site - occlusal view



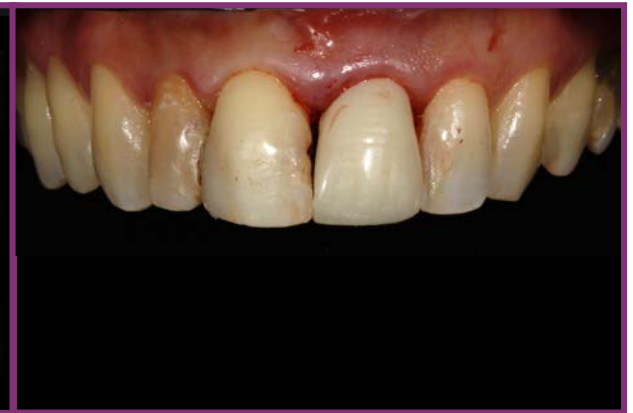Implant placement



Gap management - Xenograft

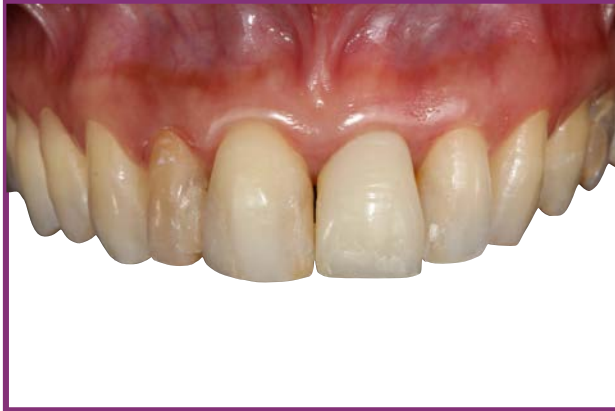

*Provisional Restoration Procedure
(Dooren et al., 2016)*

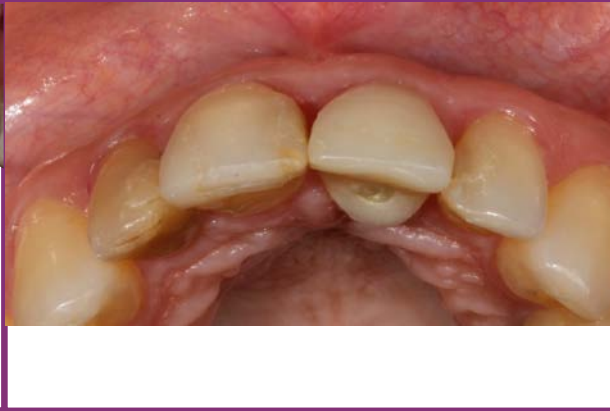

Immediate provisional restoration in place

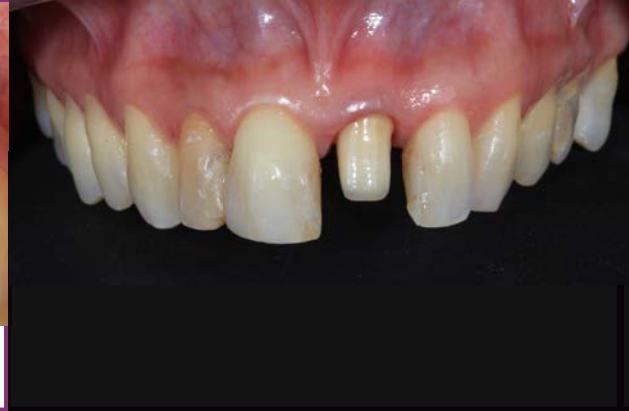Clinical Case



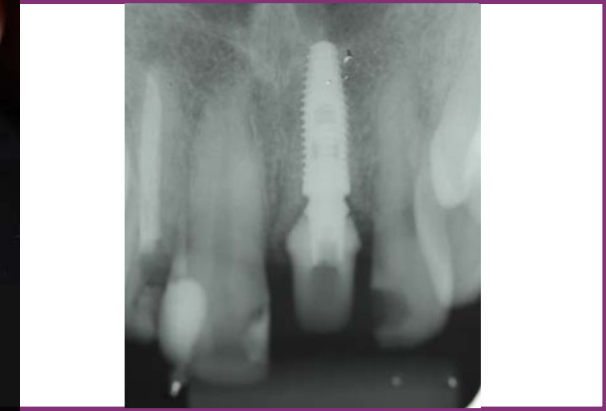
*Provisional restoration 5-month follow up -
intraoral frontal view*



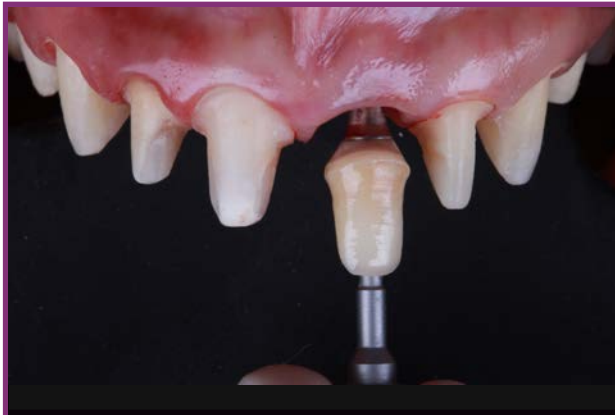*Stable soft tissue contour
5 months after surgery*



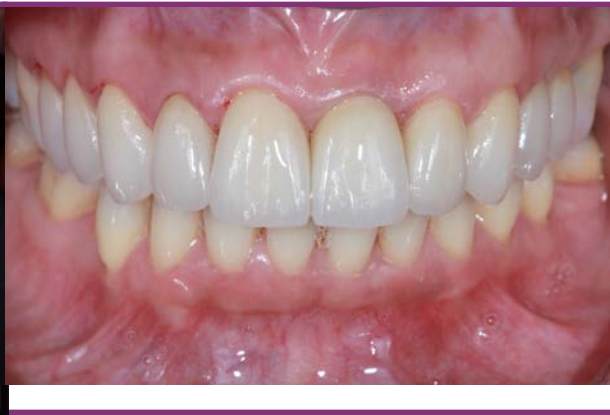Try in customized abutment intraorally



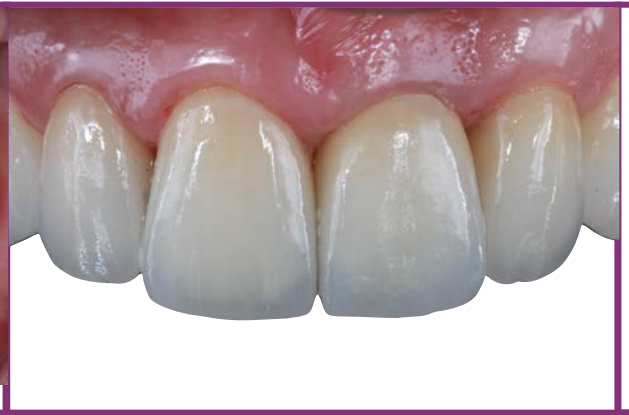Try in customized abutment X-ray



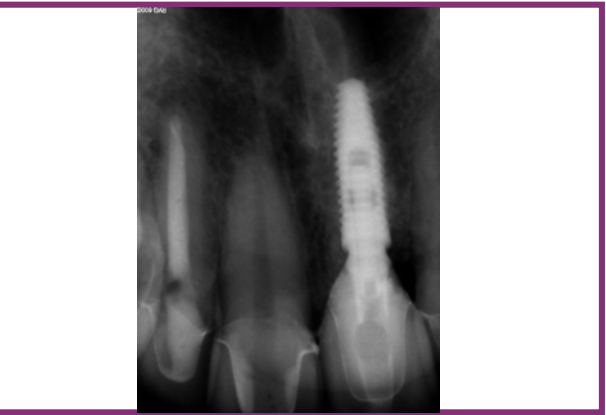
*Adjacent teeth preparation for upper-arch
cosmetic treatment (color - A3)*



*Final restorations
After cementation*



Final restoration close-up view



1-year follow-up X-ray