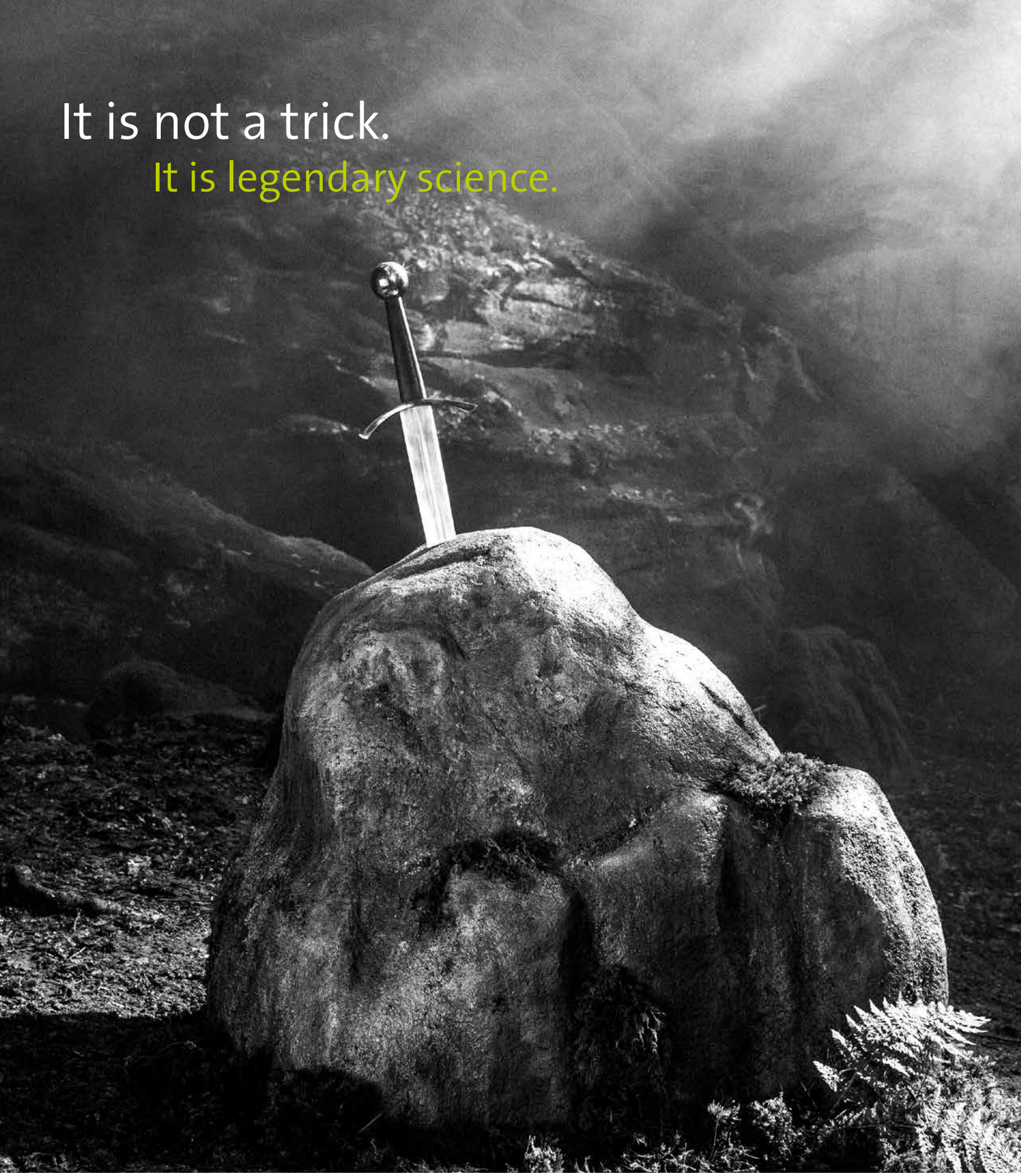

Contents

Replacement of Congenitally Missing Lateral Incisors with Straumann Bone Level Tapered Roxolid® SLActive® Implants

EDWARD GOTTESMAN, DDS

Dr. Edward Gottesman is a diplomate of the American Board of Periodontology and a fellow of the International Congress of Oral Implantologists. He is a clinical assistant professor at Stony Brook University School of Dental Medicine, State University of New York, Stony Brook, N.Y., where he received his DDS degree and completed his periodontal residency training. Dr. Gottesman maintains a private periodontal and dental implant practice in Manhattan, NY.

ROBERT W. BERG, DMD

Dr. Robert W. Berg received his DMD degree from Tufts University School of Dental Medicine and a Certificate in Prosthodontics from Albert Einstein College of Medicine/Montefiore Medical Center. He currently maintains a full-time private practice limited to prosthodontics in Manhattan, NY. He is a clinical instructor in Surgery (Dentistry, Oral & Maxillofacial Surgery) at New York Presbyterian Hospital – Weill Cornell Medical College.

DAVID H. SELIGMAN, DMD

Dr. David H. Seligman received his DMD from University of Connecticut School of Dental Medicine and a Specialty Certificate in Orthodontics and Dentofacial Orthopedics from Vanderbilt University Medical Center. Dr. Seligman is currently in full-time private practice in Manhattan, NY.

A thirty-one-year-old female in good health presented for the replacement of her congenitally missing lateral incisors. She was wearing an upper transitional removable partial denture (flipper) which was no longer satisfactory to her as it retained disproportionally small, unesthetic lateral incisors. Her initial clinical presentation (Fig. 1, Fig. 2) and radiographic exam (Fig. 3, Fig. 4) revealed that her permanent maxillary canines were tipped palatally in crossbite and mesially into the lateral incisor spaces.

Fig. 1 Pre-operative facial view of 31 year old female patient with congenitally missing lateral incisors

Fig. 2 Pre-operative occlusal view of 31 year old female patient with congenitally missing lateral incisors

Fig. 3 Pre-operative Panorex radiograph confirming congenitally missing lateral incisors

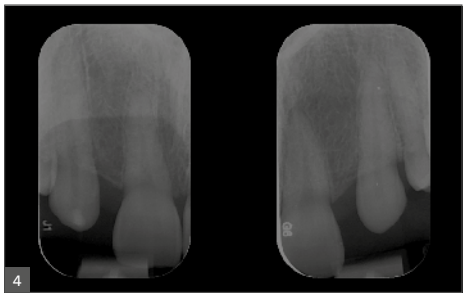

Fig. 4 Pre-operative periapical radiographs confirming congenitally missing lateral incisors with inadequate inter-radicular space to

She had inadequate restorative space to replace her absent adult lateral incisors (Fig. 5, Fig. 6). Orthodontic therapy was necessary to improve the esthetics and occlusion and to develop space between the permanent canines and central incisors (Fig. 7, Fig. 8, and Fig. 9) to accommodate two dental implants in the lateral incisor positions which would replace her adult lateral incisor teeth. During the final weeks of her orthodontic therapy, a CBCT scan (Fig. 10) was taken to ensure adequate ridge dimension and proper root alignment (Fig. 11) for two narrow diameter (3.3 mm) dental implants. To best maximize the esthetic outcome, Straumann® Bone Level Tapered (BLT) Roxolid® SLActive® implants were selected (Fig. 12 and Fig. 13). A tapered implant, specifically, was selected to avoid damaging the neighboring teeth during osteotomy preparation and placement. Its taper also facilitated initial stability due to bone compression at the apical extent of the osteotomy when the implant is fully seated. The bone level implant is designed to provide the restorative dentist with many restorative options including custom milled ceramic abutments which avert metal collar exposure or the potential for a dark hue at the gingival margin in patients with a thin tissue biotype. The hydrophilic nature of the BLT implant's SLActive surface promotes faster osseo-integration and reduces healing time* for the patient. This was a real benefit as the implant permitted the patient to achieve their desired esthetic outcome earlier.

Fig. 5 Right lateral view showing inadequate restorative space for right lateral incisor due to mesially and palatally tipped upper right canine

Fig. 6 Left lateral view showing inadequate restorative space for left lateral incisor due to mesially and palatally tipped upper left canine

Fig. 7 Orthodontics completed with ideal restorative space for lateral incisors

Fig. 8 Orthodontics completed with ideal restorative space for right lateral incisor

Fig. 9 Orthodontics completed with ideal restorative space for left lateral incisor

Fig. 10 CBCT scan volume rendering confirming appropriate root spacing and adequate bone volume in for dental implants in the edentulous sites of the permanent maxillary lateral incisors

Fig. 11 Panorex confirming appropriate root spacing and adequate bone height for dental implants in the edentulous sites of the permanent maxillary lateral incisors

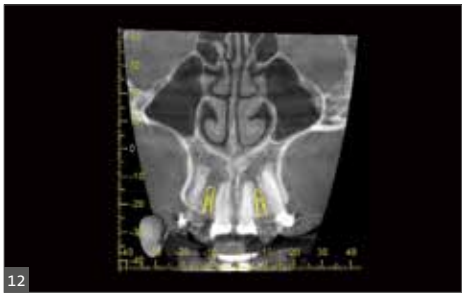

Fig. 12 CBCT reconstructed Panorex confirming appropriate root spacing and adequate bone height for dental implants in the edentulous sites of the permanent maxillary lateral incisors

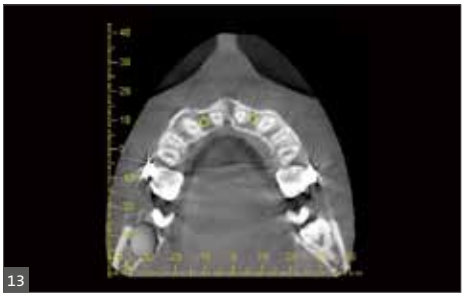

Fig. 13 CBCT axial view confirming appropriate root spacing apically for narrow diameter dental implants in the edentulous sites of the permanent maxillary lateral incisors

After crestal incisions were made in the edentulous sites corresponding to teeth #7 and #10, full thickness buccal and palatal mucoperiosteal flaps were elevated to visualize the osseous crest. Two 3.3x10 mm Straumann® BLT Roxolid® SLActive® implants were placed with an electric hand-piece and seated fully in the osteotomy with a hand ratchet at high torque (>45Ncm). Initial stability was objectively measured with an Ostell® revealing an ISQ value of 69 for implant #7, and an ISQ value of 67 for implant #10. Straumann 3.3x3 mm healing abutments were attached to the implants in a stage one fashion avoiding a second stage uncovering surgery owing to the primary stability achieved (Fig. 14-Fig. 19).

After a healing period of twelve weeks to allow for osseointegration, the orthodontic wire was removed and PVS impressions were made for provisional restorations. Screw retained provisional crowns were fabricated and inserted. A new orthodontic retainer was fabricated and inserted.

Five weeks after the implants were provisionalized, a crown lengthening procedure was performed to correct for Type 2B altered passive eruption (Fig. 20) defined as a normal amount of gingiva and normal crest-to-CEJ relationship. By repositioning the attached gingiva and more apically utilizing a full thickness apically positioned flap (Fig. 21 and Fig. 22), the complete clinical crown was exposed, reducing the pseudo pockets (Fig. 23) and displaying the appropriate crown proportions.

Fig. 14 After full thickness flap elevation, two 3.3 x10 mm Straumann® SLActive®, Bone Level Tapered implants were placed along with NC 3.6 x 2 mm healing abutments

Fig. 15 Right lateral view after full thickness flap elevation; a 3.3 x 10 mm Straumann SLActive, Bone Level Tapered implant was placed along with an NC 3.6 x 2 mm healing abutment in site #7

Fig. 16 Left lateral view after full thickness flap elevation, a 3.3 x 10 mm Straumann SLActive, Bone Level Tapered implant was placed along with an NC 3.6 x 2 mm healing abutment in site #10

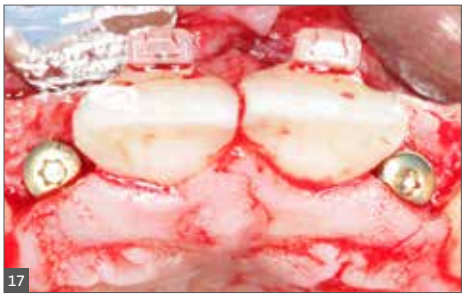

Fig. 17 Occlusal view after full thickness flap elevation; two 3.3 x 10 mm Straumann SLActive, Bone Level Tapered implants were placed along with an NC 3.6 x 2mm healing abutments in sites #7 and #10

Fig. 18 Occlusal right view after full thickness flap elevation; a 3.3 x 10 mm Straumann SLActive, Bone Level Tapered implants was placed along with an NC 3.6 x 2 mm healing abutment in site #7

Fig. 19 Occlusal left view after full thickness flap elevation; a 3.3 x 10 mm Straumann SLActive, Bone Level Tapered implants was placed along with an NC 3.6 x 2 mm healing abutment in site #10

Fig. 20 Altered Passive Eruption (normal amount of gingiva and normal crest-to-CEJ relationship)

Fig. 21 Buccal full thickness flap elevated from teeth #3-14 beyond the mucogingival junction

Fig. 22 Flap sutured apically with 5-0 Chromic gut sutures exposing complete clinical crown

After a healing period of 7 weeks to allow for the soft tissue to fully mature and remodel, new impressions were made for final restorations (Fig. 24). Two cast custom abutments were fabricated and opaqued (Fig. 25 and Fig. 26). Two e.max® crowns were fabricated with occlusal accesses (Fig. 27). The crowns were etched, silinated and luted to the custom abutments with resin cement (Panavia™ f) and torqued into place. Mild blanching of the soft tissue was evident immediately after this insertion visit (Fig. 28). PTFE tape and composite was placed in the occlusal accesses (Fig. 29).

Two weeks after final delivery, the soft tissue surrounding the final crowns in sites #7 and #10 have molded and replicate the emergence profile of a natural tooth. (Fig. 30, Fig. 31 and Fig. 32). The final smile demonstrates a natural esthetic result for the patient who was very pleased with the outcome (Fig. 33).

*Compared to Straumann SLA surface

Credits:
Prosthodontist: Dr. Robert W. Berg, D.M.D.
Orthodontist: Dr. David H Seligman, D.M.D.

Fig. 23 Clinical crowns are completely exposed, reducing pseudo pockets and displaying appropriate crown proportions

Fig. 24 Impression copings placed and verified with radiograph

Fig. 25 Shade determination for e.max® crowns

Fig. 26 Opaqued custom abutments

Fig. 27 Pressed e.max® crowns with occlusal access holes that will be cemented to custom abutments

Fig. 28 Crowns definitively torqued immediately after insertion

Fig. 29 Occlusal view of final screw retained crowns inserted in sites #7 and #10

Fig. 30 Final screw retained crowns inserted in sites #7 and #10

Fig. 31 Close up view, final screw retained crown in site #7

Fig. 32 Close up view, final screw retained crown in site #10

Fig. 33 Final smile

Straumann® Bone Level Tapered Implant (BLT)

Surgical and Prosthetic Treatment of a Failed Maxillary Central Incisor (#8)

ROBERT A. LEVINE, DDS, FCPP, FISPPS

Diplomate, American Board of Periodontology
Fellow, International Team for Implantology (Basel, Switz.

Private Practice at the Pennsylvania Center for Dental Implants & Periodontics
Philadelphia, PA

Clinical Professor in Periodontics & Implantology Kornberg School of Dentistry at Temple University
Philadelphia, PA

Rlevine@padentalimplants.com

Restorative Therapy:
Dr. George Segel, DMD
Member, International Team for Implantology (Basel, Switz)
Private Practice in Restorative & Implant Dentistry
Newtown, PA

Dental Laboratory:
NewTech Dental Laboratories, INC.
Landsdale, PA

The patient presents as a 26-year-old healthy non-smoking male (ASA 1) in November 2014 to our offices (Figs. 1-3). His chief complaint was discomfort apically in the area of #8 (ADA), which had a previous root canal treatment many years prior due to a traumatic event to the face. A full mouth periodontal exam revealed no bleeding upon probing except around #8 with no probing depths greater than 3 mm. He was aware that #8 was hopeless due to a chronic periapical lesion and was interested in permanent tooth replacement without involving his adjacent teeth. He presented with high esthetic expectations, a medium lip-line and gingival biotype and slightly triangular shaped maxillary anterior teeth. (Fig. 4)

The comprehensive team treatment plan that was discussed with the patient was based on clinical, radiographic (including maxillary CT scans) exams and included:

1. Mounted study models with final restorative consultation with Dr. Segel for a maxillary anatomically correct surgical guide and a transitional Essix appliance to replace #8.
2. Surgical Visit: surgical extraction #8 with evaluation for immediate implant placement (Type 1 Placement) with hard & soft tissue reconstruction or ridge preservation with delay of implant placement for 3-4 months (Type 3 Placement). The decision would be made after tooth extraction and 3-dimensional evaluation of the socket after full debridement of the apical lesion as well as insertion torque values. The patient was given Amoxicillin, a NSAID and chlorhexidine gluconate (CHG) rinse to start 1 hour prior to surgery and continue to completion for 1 week, 5 days and 2 weeks, respectively.

Fig. 1 Pre-treatment

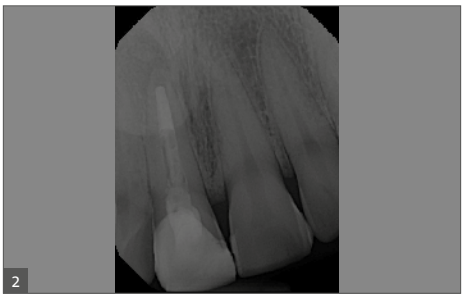

Fig. 2 Pre-treatment

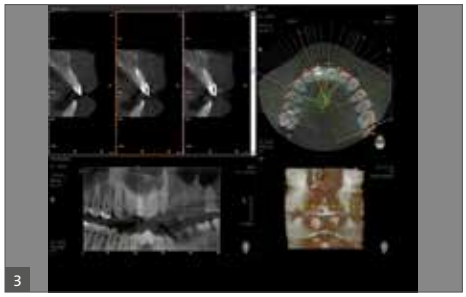

Fig. 3 Pre-treatment CBCT

Fig. 4 ERP

3. Screw-retained provisional #8 to sculpt soft tissues and to act as the "blueprint" for the final restoration. The provisional will be worn for 6-8 weeks and reevaluated by both clinicians for any modifications needed.
4. Commence completion of single crown #8 upon establishing favorable soft tissue scalloping and contours.
5. Periodontal maintenance visits every 6 months with the restorative dentist's office.

TREATMENT OF SITE #8 USING A STRAUMANN® BONE LEVEL TAPERED (BLT) ROXOLID® SLACTIVE® IMPLANT

The involved tooth #8 was extracted using a flapless approach with minimal trauma. The periapical lesion was debrided carefully and removed separately in predominately one large piece which was sent out for oral pathology evaluation (Kornberg School of Dentistry at Temple University, Philadelphia, PA; *Dx.: Periapical Granuloma and Abscess).* The socket was sterilized with the use of the Milllenium Dental Laser (ablation setting) after vigorous usage of the PIEZOSURGERY (OT4 insert). (Figs. 5,6)

The goal was to place the implant immediately, if possible. Site preparation was completed with the use of the index finger for tactile sense along the buccal plate of bone to confirm that no buccal vibration or buccal fenestration was evident during site preparation using the Straumann twist drills. All socket walls were intact except the most apical buccal where the abscess was removed resulting in a fenestration without a fistula. A BLT Roxolid SLActive 4.1 mm x 14 mm implant was installed using the rules for 3-dimensional placement **(ITI Treatment Guide # 1; 2007; Quintessence Publishing Co., Inc.)** with the aid of the anatomically correct surgical guide template of placing along the palatal wall and in an apical position of 4 mm below the mid-facial position of the surgical guide. As the coronal buccal wall was totally intact and soft tissue measured 3 mm mid-buccal, the position of the buccal implant shoulder was 1 mm deeper than the buccal height of bone (Fig. 7).

Insertion torque value of the implant was approximately 10Ncm as it was hand tightened to final seating. A buccal gap of 2 mm was measured (Fig. 8) and packed tightly with anorganic bovine bone (BioOss; Geistlich) previously soaked for 10 minutes in PDGF (Gem-21; Osteo-Health) to aid in both soft and hard tissue healing.

Fig. 5 Extracted tooth #8

Fig. 6 Debriding socket with PIEZOSURGERY

Fig. 7 Palatal placement #8 with aid of surgical guide to allow for a buccal gap of at least 2 mm and a screw-retained restoration

Fig. 8 Flapless placement with along the palatal wall with a 2 mm buccal gap recorded

Fig. 9 Minimal reflection of the buccal flap from line-angle to line-angle with a Buser membrane instrument

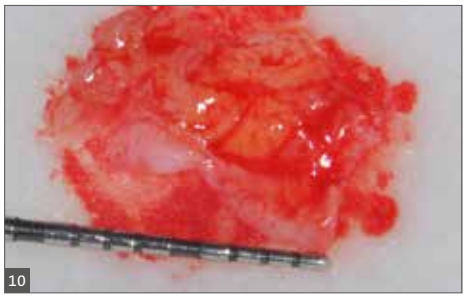

Fig. 10 Palatal connective tissue graft (10x7 mmx2 mm thick)

A palatal soft tissue connective tissue graft (CTG) was harvested from the #4-5 site. The CTG was then placed and sutured under the partially elevated buccal flap from mesiobuccal to distobuccal line angle and apically approximately 10 mm to further aid in long-term soft tissue contours. This was done to mimic the root eminence of the extracted tooth as well as to act as a membrane to aid in guided bone regeneration of the buccal gap. (Figs. 9-11) In addition, the CTG changes the periodontal biotype from a medium to a thick biotype ("biotype conversion"). A 7 mm tapered RC healing cap was placed to lightly support the soft tissue graft. Prior to placing, the healing cap was beveled to the level of the palatal tissues to prevent transmucosal loading by the tongue. (Fig. 12)

The dental laser (Millenium, Cerritos, CA) was then used on the palatal incisions (hemostasis setting) to aid in bleeding control and post-operative comfort for the patient. No periodontal dressing or sutures were necessary. The Essix appliance was relieved so as not to place any pressure on the surgical site. Post-operative plaque control was reviewed with the patient which included normal brushing and flossing in all areas except site #8 where a cotton swab would be used dipped in CHG rinse to locally clean the site along with rinsing with CHG bid till completed along with finishing his other medications as prescribed. A post-surgical CBCT was taken to confirm 3-D placement along with avoidance of the nasopalatine foramen (NPF). The benefits of the BLT implant are readily noted on the post-surgical CBCT as the apical taper avoids the NPF and a buccal perforation due to the anatomical bony buccal undercut. (Fig. 13)

Healing of the surgical site was uneventful and the patient was seen at 2 weeks, 5 weeks and at 12 weeks post-surgery. A periapical x-ray was taken at 12 weeks and a reverse torque test at 35Ncm was completed using the manufacturer's torque driver and an RC implant carrier device to confirm bone healing. (Figs. 14,15) The patient was scheduled with the restorative dentist for impressions to fabricate a lab-made screw-retained provisional restoration using the indirect method. The patient was seen in our office at 3 weeks after placement of the provisional to evaluate soft tissue healing, tissue support and a periapical x-ray. (Figs. 16-18) Based on clinical healing and gingival margin location being slightly apical for #8 implant vs. #9 natural tooth, further mid-buccal support with acrylic was recommended. The adjacent papillaes were healing as expected and the patient was very happy with the results so far. The case went to completion using the custom impression coping technique of duplication of the transitional subgingival zone for the lab. Due to the proximity of the screw-access hole in the provisional being near the palatal incisal edge, a custom abutment (1 mm subgingival margins circumferentially) was fabricated and the final crown was cemented with ZnPO4 cement using the copy abutment teflon-tape technique. This technique was employed to avoid subgingival cement remnants. Final pictures and x-rays were taken of the final case in our office a few weeks after completion. Clinical exam revealed healthy soft tissues and excellent buccal contours mimicking the adjacent natural tooth. (Figs. 19-22) He will continue periodontal maintenance visits twice yearly with his restorative dentist and yearly exams under our care for 5 years to document soft and hard tissue healing with clinical digital photos and x-ray exam of the implant site.

Fig. 11 Donor site post laser hemostasis

Fig. 12 7 mm tapered RC healing cap was placed to lightly support the soft tissue graft

Fig. 13 Post-surgical CBCT of #8; buccal gap bone grafting is noted along with a widened NPF

Fig. 14 Healing at 8 weeks; reverse torque test visit

Fig. 15 Sulcular healing at 8 weeks

Fig. 16 Screw-retained provisional at 3 weeks

CONCLUSION

The treatment of an esthetic zone case was successfully completed using the team approach for maximizing our combined knowledge for the benefit of the patient, which is an ITI doctrine. The use of the Straumann® Bone Level Tapered Roxolid® SLActive® Implant for immediate placement helped in the anatomical management of the central incisor site where the nasopalatine foramen can be an issue along with the normal anatomical buccal undercut. Comprehensive case planning, the use of an anatomically correct surgical guide, evidenced-based materials including the use of connective tissue grafting along with taking the necessary time to sculpt the soft tissues in the provisional phase, are all important factors in achieving a successful outcome. As esthetic zone implant placement, as described in this case report, is a complex SAC procedure, the surgical and literature knowledge of this technique-sensitive area is necessary for the clinician to consistently result in a happy patient as described in this report. **(ITI 5th Consensus Conference: IJOMI 2014 (Supplement); Morton D., Chen ST., Martin WC., Levine RA & Buser D. and IJOMI 2014 (Supplement); Levine RA, Huynh-Ba G, Cochran DL)**

Fig. 17 Screw-retained provisional #8

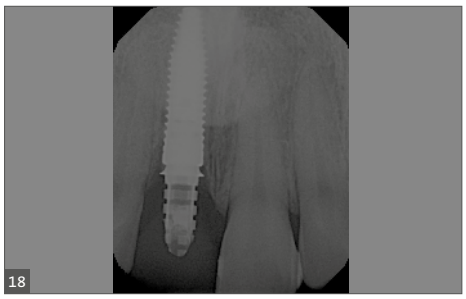

Fig. 18 Periapical x-ray of screw-retained provisional

Fig. 19 Final crown 8 (6months post-placement)

Fig. 20 Favorable buccal contours simulating the adjacent natural tooth

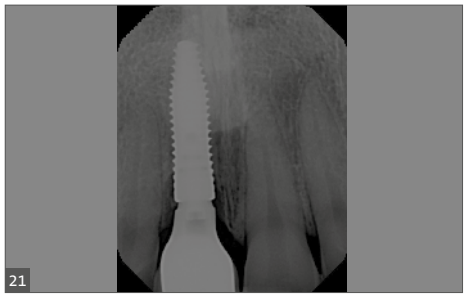

Fig. 21 Final periapical x-ray

Fig. 22 Final smile

Replacement of a failed root canal of the second molar with a Straumann® Bone Level Tapered (BLT) Implant

BRAD MCALLISTER, DDS, PHD

Diplomate, American Board of Periodontology
Diplomate, International Congress of Oral Implantologists
Fellow, International Team for Implantology

mcallister@portlandimplantdentistry.com

Periodontal Associates
18753 SW Martinazzi Ave
Tualatin, OR 97062
Phone: 503/620 2807
Fax: 503/968 5419

www.portlandimplantdentistry.com

Assistant Professor
Department of Periodontology
Oregon Health and Sciences University

A 50 year old female presented with hopeless tooth #18 (Fig. 1). Her medical and dental history was uneventful. This previously root canaled tooth was hopeless due to deep decay and extensive furcation involvement (Fig. 2 and 3). In planning a size for placing an immediate Straumann BLT Implant a cross sectional view was employed to measure the distance to the inferior alveolar nerve (Fig. 4). Approximately 3 mm of bone was observed apical to the tooth root and superior to the nerve.

The patient initiated a one week course of antibiotic therapy, which included 500mg tid Amoxicillin, the day prior to her surgery. After local anesthetic was given a localized flap was elevated, the tooth was sectioned and extracted taking care to preserve the buccal plate of bone. The socket was degranulated, curetted and rinsed with sterile saline prior to initiating any implant osteotomy preparation. The osteotomy was underprepared in diameter and the Straumann® Roxolid® SLActive® BLT implant (10 mm x 4.8 mm RC) was inserted with a torque of 35Ncm (Fig. 5). The BLT implant design easily allowed for ideal placement and excellent initial stability. A wider diameter healing abutment was placed along with a mineralized allograft (Fig. 6). The site was sutured to a tension free primary closure with Vicryl 4-0 suture (Fig. 7). A digital radiograph was taken to evaluate implant and bone graft placement (Fig. 8). Given the inferior alveolar nerve positioning was not clear a CBCT was taken to verify implant position relative to the inferior alveolar nerve (Fig. 9 and 10). It was observed that nearly 2 mm of clearance was present. Initial healing was uneventful as shown in the 1 month healed clinical presentation (Fig. 11).

Following 4 months of healing, the final restoration of a screw-retained gold abutment with a crown consisting of porcelain fused to metal was fabricated and torqued to 35Ncm (Fig. 12 and 13). The radiographic evaluation showed ideal restoration contours and excellent radiographic bone healing (Fig. 14).

Fig. 1 Female patient presented with hopeless tooth #18

Fig. 2 CBCT of #18 showing root canal, deep decay and extensive furcation

Fig. 3 CBCT of #18 showing deep decay and extensive furcation

Fig. 4 CBCT of #18 and the inferior alveolar nerve

Fig. 5 Immediate placement of 4.8 mm x 10 mm Straumann® Roxolid® SLActive® Bone Level Tapered Implant

Fig. 6 Placement of a wide diameter healing abutment along with a mineralized allograft

Fig. 7 Site sutured

Fig. 8 Digital radiograph to evaluate implant and allograft placement

Fig. 9 CBCT of #18 showing implant position relative to the inferior alveolar nerve

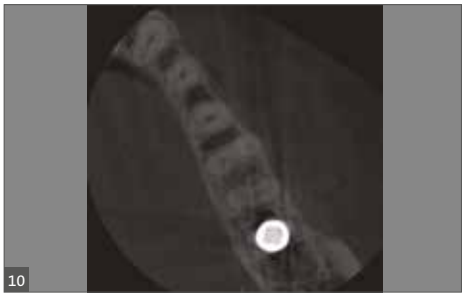

Fig. 10 CBCT of #18 showing implant position

Fig. 11 One-month post-op image shows uneventful initial healing

Fig. 12 Four-months post-op with a screw-retained crown

Fig. 13 Four-months post-op with a screw-retained crown

Fig. 14 Digital radiograph of #18 showing ideal restoration contours and excellent osseointegration

Quality of life restored using Straumann® AlloGraft, Bone Level Tapered Roxolid® SLActive® Implants and Screw-Retained Abutments

ROBERT J. MILLER, DMD

Dr. Robert J. Miller received his dental degree from Boston University Goldman School of Dentistry in 1984. He received his Certificate for Advanced Graduate Study in periodontics from Boston University in 1986 and has maintained a private periodontal practice in Plantation, Florida for over 25 years. He is an active member of the Academy of Periodontology, Academy of Osseointegration, Pierre Fauchard Academy, Academy of Dentistry International, American Dental Association, Florida Dental Association, South Palm Beach County Dental Association, Broward County Dental Association, and is a Fellow of the International Team for Implantology (ITI). He has a courtesy appointment with the Community Based division program at the University of Florida Hialeah Dental Clinic.

shmat1@aol.com

http://www.webperio.com/

BACKGROUND

The patient is an 82 year old male who is presented with his wife hoping to be able to have a fixed implant prosthesis fabricated for his maxilla (Fig 1a, b, c). His remaining four incisors (ADA #7 through 10) are hopelessly involved and require extraction (Fig 1d). He is presently suffering from dementia and his wife reports that he has misplaced his removable appliance on several occasions prompting a fixed solution. She also believes that his digestive issues may be a result of his inability to masticate food properly and is concerned about malnourishment. Due to these concerns his wife was hoping for immediate provisionalization.

Careful review of his medical history revealed that he is an ASA type III who suffers from cardiac issues, including aortic valve replacement and is currently taking Coumadin. Medical clearance was required prior to any surgical procedures. His physician would not let us stop the blood thinner, as he was a stroke risk. It was also recommended that we do not use epinephrine during our surgery.

We exposed a CT scan which revealed extensive bone loss in the anterior sextant, leaving position #7 and 10 poor candidates for implant placement. Adequate bone was noted distal to the lateral incisors. The scan disclosed what appeared to be Type III and IV bone with proximity to his Maxillary Sinus in position #4 and 13 (Fig 2a, b). After careful examination, which included collaboration with his restorative dentist and laboratory technician, we felt that immediate provisionalization could be accomplished with six fixtures, placed strategically in position #4, 5, 6, 11, 12, and 13. Successful osseointegration with immediate loading requires excellent initial stability. The thread design and apical taper of the Straumann Bone Level Tapered implant (BLT) which matches the natural tooth morphology helps meet this objective. The CrossFit® Connection lends prosthetic flexibility making the BLT an ideal choice for this case. The BLT implant paired with Straumann Screw-Retained Abutments (SRA) gives the clinician many options for complex cases.

Fig. 1a Initial patient presentation

Fig. 1b Initial patient presentation

Implant planning involved taking advantage of the available bone and strategic placement with a large enough span to ensure cross-arch stabilization (Fig 2c). Due to the sinus proximity in both the right and left second bicuspid areas, we knew that the Summers Technique was indicated. We also preferred to perform the surgery "incision-less" using a tissue punch to gain access to the osseous crest. This was indicated as a result of his complex medical history and desire to make the procedure less traumatic.

Six BLT implants were planned for the maxillary right and left cuspids, and bicuspids. This would create a large span which will improve his chewing efficiency and positively impact his quality of life. A tooth borne computer guided stent was fabricated using the remaining maxillary lateral and central incisors to stabilize the guide while the implants are being placed (Fig 3a).

Standard surgical protocol was observed. The patient was anesthetized with eight carpules of Mepivicane 3% (without epinephrine) in

Fig. 1c Initial patient presentation

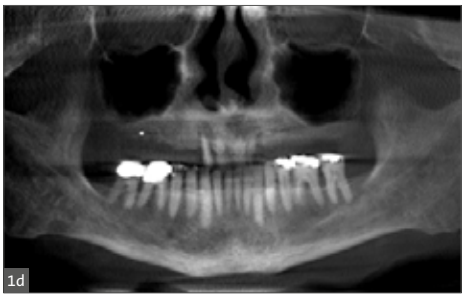

Fig. 1d Incisors 7-10 to be extracted

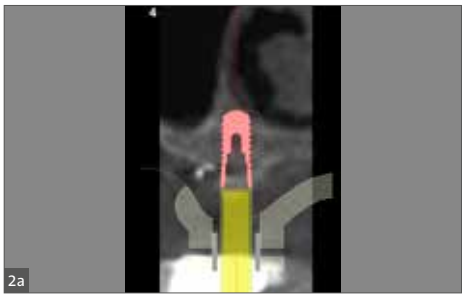

Fig. 2a Type III and IV bone with proximity to his Maxillary Sinus

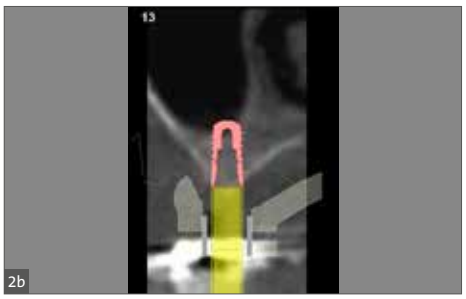

Fig. 2b Type III and IV bone with proximity to his Maxillary Sinus

Fig. 2c Planning for cross arch stabilization

Fig. 3a Tooth borne computer guided stent

Fig. 3b Tissue punch was used to create access to the osseous crest

Fig. 3c Drilling procedure using Straumann Guided Surgery kit

Fig. 3d Drilling procedure using Bone Level Tapered drill bit

accordance with the restrictions necessitated by his medical issues. A 5 mm diameter tissue punch was used to create access to the osseous crest in position #4, 5, 6, 11, 12, and 13 (Fig 3b). The Straumann® Guided Surgery Kit was used with the appropriate handles and burs to create the osteotomies. Each of the three twist drills (2.0, 2.8, and 3.5 mm) were purposely "under-drilled" by approximately 20% to enable the final 2-3 mm to be created using the Bone Level Tapered twist drills due to their tapered design (Fig. 3c and d). The second bicuspid sites were only brought to the depth of approximately 6 mm as the remaining 2-4 mm were created using Osteotomes. Please note that 2.8 mm diameter Osteotomes in each of the second bicuspid sites were used to take advantage of the aggressive apical threads and root form design which improved the initial stability (Fig 3e). Straumann® Allograft was used to help tent the Schneidarian Membrane prior to the placement of the implants as called for by the Summers Technique.

Twelve millimeter Regular Connection (4.1 mm diameter) Straumann Bone Level Tapered Roxolid SLActive implants were placed in position #6 and 11. Ten millimeter Regular Connection (4.1 mm diameter) Straumann Bone Level Tapered Roxolid SLActive Implants were placed in position #5, 12, and 13 with an eight millimeter fixture placed in position #4 (Fig. 3f). The Loxim™ Transfer piece with 1, 2, and 3 mm markings allowed for precise placement of all implants. Good initial stability was attained as evidenced by Ostell readings between 76 and 81 (ISQ) (Fig 3g and h) making it possible to immediately load the implants predictably. The remaining four teeth were extracted and thoroughly debrided with hand instruments prior to suturing with 4-0 Mild Chromic Gut. Straumann Screw-Retained Abutments (SRA) were hand tightened to each of the six implants. All 0° abutments were used except for the fixture in position #4, which required a 17° angulated abutment (Fig 3i). An open tray impression technique was employed, bite taken, midline determined and healing abutments placed prior to the patient being dismissed (Fig 4a, b, c, d, e).

A metal reinforced lab processed provisional was fabricated overnight by our laboratory technician using a "cold-welded" titanium bar to improve the cross arch stabilization (Fig 5a, b, c). The provisional was delivered the next day with very minor occlusal adjustments (Fig 6a, b, c, d). The patient was rechecked after one and three weeks, three

Fig. 3e 2.8-mm diameter Osteotomes were used in each of the second bicuspid sites

Fig. 3f Placement of Straumann Bone Level Tapered Roxolid SLActive implants

Fig. 3g Good initial stability measured with Ostell

Fig. 3h Ostell readings between 76 and 81 ISQ

Fig. 3i 5 0 degree abutments plus a 17 degree angulated abutment in position 4

Fig. 4a Open tray impression technique

Fig. 4b Bite taken

Fig. 4c Midline determined

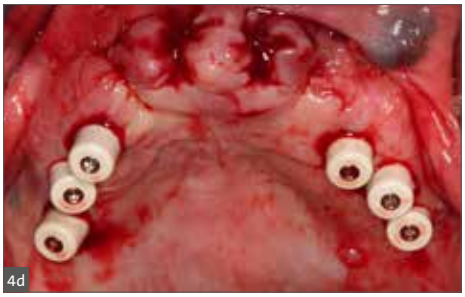

Fig. 4d Healing abutments placed

months (Fig. 6e) and 12 months (Fig. 6f, 6g) of soft tissue maturation. The patient was asymptomatic and the prosthesis was extremely stable which can be attributed to the BLT design, surface and material. The osseointegration process begins at the time of implant placement due to the hydrophilic SLActive surface, which draws the blood and blood proteins deep into the crevices of the roughened surface. This results in very little dip in the overall stability of the dental implants over the first three or four weeks. The combination of these factors gives the clinician confidence that sophisticated treatment plans such as these are predictable.

The patient's quality of life has dramatically improved as a result of this procedure. He is now able to chew more effectively and is no longer having digestive issues. Consequently his smile and demeanor has been restored which his close family and friends believe has made a significant improvement to his life (Fig 6h).

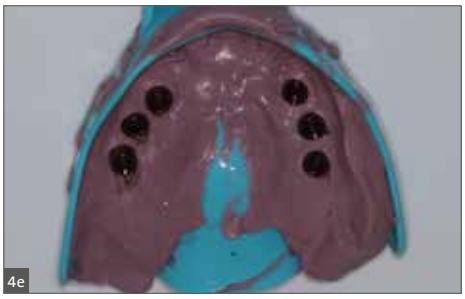

Fig. 4e Bite taken

Fig. 5a Cold-welded titanium bar to improve the cross arch stabilization

Fig. 5b Metal reinforced lab processed provisional was fabricated overnight

Fig. 5c Metal reinforced lab processed provisional was fabricated overnight

Fig. 6a Minor occlusal adjustments

Fig. 6b Minor occlusal adjustments

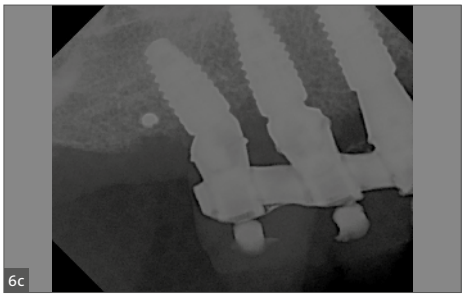

Fig. 6c Patient was rechecked after one and three weeks

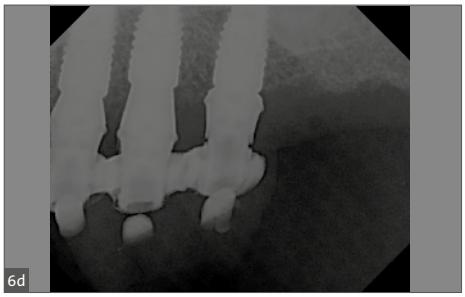

Fig. 6d Patient was rechecked after one and three weeks

Fig. 6e Three Months Post-op

Fig. 6f One year post-op

Fig. 6g One year post-op

Fig. 6h Final restoration

Straumann® Bone Level Tapered Implant (BLT)

The BLT's contribution to primary stability and osseointegration in damaged esthetic areas

SEPEHR ZARRINE, DDS

Oral surgeon. Exclusive private implantology practice (Saint Dié, France). Speaker ITI France. European Master in Dental Implantology. Surgery, prosthetics, bone grafts (Frankfurt, Germany). University diploma in surgical maxillofacial rehabilitation (Medicine, Paris VII).

Surgitechstudies.com
dr.zarrine@gmail.com

Thanks to Pierre Chapuis and his team at Laboratoire Oral Beauty (Bruyeres, France).

BACKGROUND

The patient is a 56-year-old, active and healthy man. He does not smoke, does not take any medications and has no allergies. He was referred to us, presenting a loose anterior bridge from 11 to 22. Since his profession requires speaking in the public, his clinical situation in the esthetic zone has a negative impact on his self-confidence. The clinical examination **(Figs. 1, 2)** revealed a slightly inflamed gum with no abscess. Clinical probing indicated that there was vestibular bone loss at tooth 11 and a decayed root, but no bone loss at tooth 22.

TREATMENT PLAN

Two treatment options were considered:

1. Extraction of both roots, healing, re-entry to place two non-submerged implants with simultaneous GBR, healing, gingivoplasty and placement of the final prosthesis.

2. Extraction of both roots, immediate implantation with simultaneous bone reconstruction and gingival reinforcement, dental crown placement on the same day, i.e. immediate placement and immediate provisionalization.

In order to restore the patient with a reduced overall treatment time (including the time needed for surgery), we opted for the second solution.


1


2


3


4

We have adapted an osteogingival tissue graft technique that has been employed for several years with excellent results. Pre-surgical assessment indicated potential primary stability issues at the site of tooth 11, where only a few millimeters of bone remained for implant anchorage.

Therefore, we used this novel bone level tapered implant, designed to achieve good primary stability even in clinical indications where this would be difficult to achieve. Furthermore, the Straumann® SLActive® surface is known to provide security for the critical osseointegration period. Pre-surgical impressions were taken in order to prepare a surgical guide and a perforated impression tray.

SURGERY

Once the bridge was removed, a vertical radicular fracture was confirmed in tooth 11 and an extensive decay in tooth 22. Atraumatic root extractions were performed, on tooth 22 by applying the Benex® Extraction System **(Fig. 3)** and on 11 with a very fine elevator **(Fig. 4)**. A gingival flap was elevated to access the bone defect at tooth 11 **(Fig. 5)**.

Since the buccal side at tooth 22 was still intact, the gingiva was also left attached to the bone (i.e. flapless procedure) in order not to disturb the periostium attachment to the bone. At tooth 21, a flap was rolled to thicken the buccal alveolar ridge aspect.

The two tooth sockets were meticulously scraped and cleaned with a round bur. The surgical guide helped identify the ideal axis for the implant as well as the best emergence level **(Figs. 6, 7)**. Once the landmarks were identified, the drilling was performed and then the guide was repositioned to verify the axis of the alignment pins **(Fig. 8)**. To achieve a sufficient primary stability, the BLT drill with a diameter of 2.8 mm was used as the final preparation step.

The insertion torque for both Roxolid® Bone Level Tapered Implantat, Ø 4.1 mm RC, SLActive® 14 mm was greater than 50 N/cm. The implant at site 22 was placed towards the palate to maintain a narrow buccal gap between the implant and the socket wall.

The implant at site 11 had 8 visible threads after insertion. It was also inserted towards the lingual aspect of the extraction socket such as that a gap remained between the implant and the buccal bone wall **(Fig. 9)**. The anchoring for both implants was achieved with the last apical millimeters, which is why the 14 mm length and underpreparation were necessary.


5


6

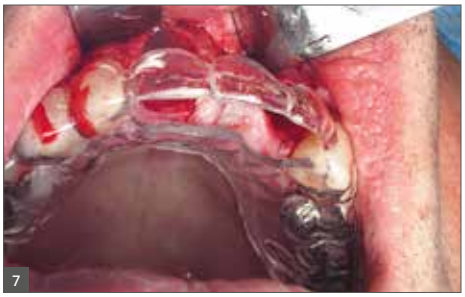
7


8


9

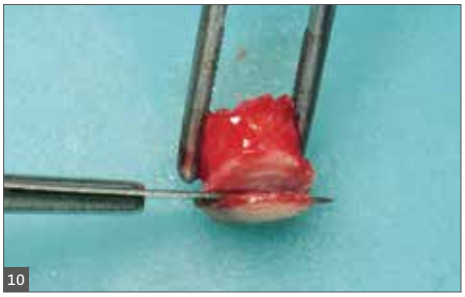
10

The majority of the drilled bone fragments were recovered thanks to the design of the BLT drills and a portion of this bone was used to fill the gap around the implant on position 22. The remaining material was used to cover the surface of the implant. To simultaneously regenerate the bone deficit and reinforce the gingiva, we used a special technique that we have been optimized during several years.

We took an osteogingival graft form the maxillary tuberosity of the wisdom tooth. A prior 3D examination had confirmed that the maxillary tuberosity presented good volume. This combined graft for osseointegration was de-epithelialized **(Fig. 10)** and then impacted into the vestibular gap of the central incisor. To prevent any mobility, an osteosynthesis screw fixed the bone core on the residual alveolar ridge by engaging the cortical bone of the palate **(Fig. 11)**.

Straight Straumann® Screw-retained Abutments (SRA) with a height of 2.5 mm were placed on the implants. Suturing was performed using resorbable 5.0 monofilament.

Then, abutment-level open tray impression posts were screwed on and a sectoral impression was taken using the perforated impression tray **(Fig. 12)**. Once the impression was taken, two protective caps were placed to prevent the gingiva from covering the SRAs during the day. The prosthetic planning process was performed with the dental laboratory, which will also perform the final work. Six hours after surgery the gingiva was stable enough **(Fig. 13)** to remove the protective caps without anesthesia and the temporary bridge was screwed onto the SRAs **(Figs. 14–17)**.

Visual and radiological examinations were performed one week post-surgery **(Figs. 18, 19)** which demonstrated that the initial healing phase was successful. The gingiva looked healthy and the patient was without clinical complications. At a re-entry after two months clinical observation determined that the implants, bone and gingiva had healed perfectly **(Fig. 20)**.


11


12


13


14


15


16

CONCLUSION

This challenging case demonstrates the possibility to compress a multi-step clinical procedure into a manageable and cost efficient time-frame. Furthermore, given this implant's location in the esthetic zone, the technique could be of particular interest to both clinicians and patients alike. The restoration was successful due to the combination of several state-of-the-art technologies and techniques:

1. The use of Straumann® Bone Level Tapered Implants, which, thanks to their design and a flexible drilling protocol, allow for good primary stability in compromised recipient bone conditions
2. The retrieval and reuse of bone fragments using the Straumann® Bone Level Tapered implant drills
3. The use of the maxillary tuberosity osteogingival tissue graft technique.

With this, we were able to provide our patient fixed teeth in a single day. The temporary bridge had no occlusal contact and only served to enable the patient to speak and smile. Once osseo-integration is completed and the graft has been consolidated, the final bridge can be planned.


17


18


19


20

Straumann North American Headquarters
Straumann USA, LLC
60 Minuteman Road
Andover, MA 01810
Phone 800/448 8168 (US) • 800/363 4024 (CA)
Fax 978/747 2490
www.straumann.us • www.straumann.ca

ifu.straumann.com

NAMLIT.1129 10/16 V1