Straumann® BLX Implant System

Predictable Immediate Loading for the Single Tooth-bound Site. Anterior and Posterior Case Review

TASSO IRINAKIS

DDS, MSC, DIP. PERIO, FRCD(C)

Associate Clinical Professor
Division of Periodontics & Implant Surgery,
Faculty of Dentistry, UBC
Board Certified Specialist in Periodontics,
Private Practice in Vancouver, Nanaimo,
Courtenay/ Canada

FARZIN GHANNAD

DDS, MSC, DIP. PERIO, FCDS(BC), FRCD(C)

Assistant Clinical Professor
Division of Periodontics & Implant Surgery,
Faculty of Dentistry, UBC
Board Certified Specialist in Periodontics,
Private Practice in Vancouver, North
Vancouver, Kamloops, Yellowknife/ Canada

Abstract

Immediate provisionalization of implants has been a valid treatment option for a considerable amount of time in modern dentistry. Yet the great majority of clinicians are hesitant to offer such treatment to their patients other than full arch cases, where cross-arch stabilization is utilized. This article describes in detail the treatment planning process, the surgical execution and the prosthetic management of an anterior case and a posterior case that were both tooth bound and immediately restored in a non-functional loading capacity. In these scenarios, we illustrate the importance of implant design in achieving consistent and predictably favorable torque at the time of implant placement, without which the concept of immediate restorations could not exist. This article will also analyze the available literature on single implants when immediately restored (in partially dentate patients), regardless of position in the dentition.

Introduction

Immediate loading was met with scepticism for many years. With time, more and more studies clearly proved the predictability and comparable success of immediate loading in fully edentulous arches. This is supported by an extensive literature review by Chiapasco in 2004[1]. Initially the mandible appeared to be more predictable but with proper treatment planning and occlusal management, maxillary full arch cases have also become consistently successful[2]. What was lacking, was literature support for single implants, more so in the posterior zone. Recent studies tend to suggest that immediately restoring single implants, whether functionally or non-functionally, can be done predictably and provide excellent survival rates. Functional immediate occlusal loading takes place when the implant is restored within 2 weeks from the time of implant insertion and it's in direct occlusal load. Non-functional immediate restorations are those placed on implants within 2 weeks of implant insertion with no direct occlusal load[3]. Raes et al[4], provided 4y survival rates on single implants with immediate functional loading of 98.1% in a multicenter prospective clinical study. All implants were placed in tooth-bound sites and were at least 10mm in length. In another prospective study[5], the authors followed patients for 9 years in a split-mouth randomized controlled trial and found that short 6.5mm single implants (placed with flapless approach) immediately or early loaded, exhibited a long term survival of over 96%. Nearly all implants were placed in single edentulous premolar or molar locations and were inserted with a minimum torque of 40 Ncm. In a recent systematic review[6] on implant placement and loading with various protocols, Gallucci et al found that regardless of the combinations between delayed or immediate implant placement and delayed or immediate implant loading in partially edentulous patients, the weighted cumulative survival rate was

within 96-98.4%. Huynh-Ba et al in 2018 reviewed the literature to evaluate patient reported satisfaction when receiving an immediate implant which was either immediately or in a conventional time frame. Although patient satisfaction was high in both scenarios, studies agreed on the positive impact immediate implant placement and loading has on patients' quality of life and thus consideration should be given to this option[7].

A protocol of non-functional immediate provisionalization in the esthetic zone has been favoured for the last several years from clinicians around the world. Degidi et al in 2005[8] was one of the first researchers to show excellent results on single tooth bound implants immediately restored with non-functionally loaded restorations with a 2-year success rate of 95.4%. In a 5-year study[9] of immediately restored single implants in the aesthetic zone, similar successful results were shown with no implants failing within the study time frame. 10-year results from Raes S et al[10] confirm such favorable outcomes in a study of single maxillary implants, which were immediately loaded in the anterior or premolar region. These implants were placed in fresh extraction sockets (flapless technique) and then immediately restored. After the first year of loading, the bone levels remained stable and favorable for the duration of the study.

In the posterior region and more specifically in the single molar sites in the maxilla, Zarrabi MJ et al[11] performed a randomized clinical trial and showed statistically near-identical crestal bone levels up to 1 year when comparing single posterior maxillary implants with non-functional immediate loading and conventional delayed loading. The initial torque of implant placement in this study was averaging around 50 Ncm and was achieved by under-prepping the osteotomy sites. In a similar randomised controlled trial[12] of single first molars in the mandible but with a 5-year follow-up, out of the 40 implants that were investigated in this split-mouth study, none failed. Bone levels remained similar in both groups as did complication rates. The torque of implant placement was within 35-45 Ncm. The overall clinical outcome was comparable, suggesting that non-functional immediate loading of single mandibular molars is a predictable and valid treatment option for our patients.

The key factor in all these studies tends to be the initial implant stability and the clinicians' ability to predictably achieve a high enough torque to allow for an immediate restoration, regardless if the occlusal loading is functional or non-functional[13]. However, overzealous application of torque on implants, especially in the mandible can lead to crestal bone necrosis and unfavorable results as shown in Aldahlawi et al when a torque in excess of 55 Ncm was applied in the mandible[14].


1

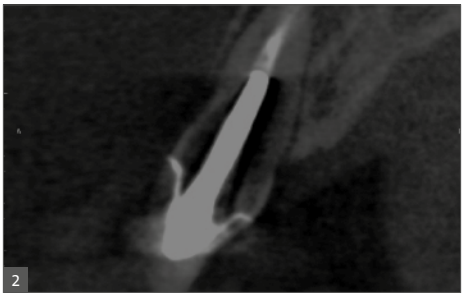
2


3


4

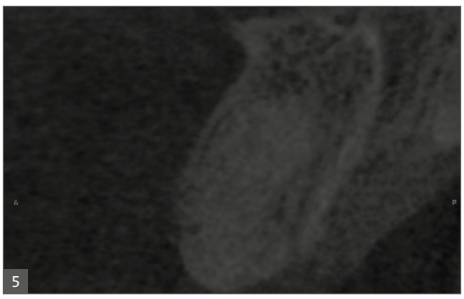
5

Straumann® BLX Implant System

Predictable Immediate Loading for the Single Tooth-bound Site. Anterior and Posterior Case Review

The authors have formulated a list of guidelines that influence their decision making when treatment planning the immediate loading of single site implants (Table 1)

Table 1

Guidelines recommended by the Authors when Immediate Loading is considered in Single Implant Sites:

1. Use of cone beam computed tomography in every case
2. Use of a surgical guide; The use of computer generated guides is preferable
3. Strictly restoratively driven implant placement with aim for a screw retained crown
4. Avoid moderate-severe periodontal disease, poorly controlled diabetes, heavy smoking and parafunctional habits (and other potentially detrimental systemic conditions).
5. Favorable keratinized gingiva present
6. Favorable amount of buccal bone still present after implant placement
7. Favorable primary stability of at least 35Ncm; the use of an implant system conducive to high initial torque should be considered.
8. Non-functional loading is preferable
9. In immediate extraction sockets: no residual infection and atraumatic extraction
10. Good oral hygiene habits are favoured
11. Patient willing to adhere to soft diet for recommended period of time
12. Implant maintenance protocol should be established

6


7


8


9


10

Anterior Single Implant Case (Dr. T.I.)

A 41 year old male with no medical concerns experienced an abscess on the upper left central incisor. He had an endodontic and periodontal consultation and he decided to proceed with an implant rehabilitation option. He also presented with a very deep overbite and occlusal interferences so an orthodontic consultation was recommended. A 2-year orthodontic treatment plan was formulated to begin after the extraction and bone graft of the central incisor (Fig.1).

The tooth was associated with a large periapical cyst (Fig.2). The buccal bone was largely missing and given the forecasted 2-year orthodontic treatment, we decided to consider utilizing xenograft particles. The choice for xenograft bone material was made as we felt it would have a favorable chance of resisting resorption over the 2-year orthodontic period prior to implant placement. At the extraction appointment, a provisional acrylic removable

partial dental prosthesis was delivered. We allowed 6 weeks of healing and soft tissue coverage over the extraction socket and re-entered the site to proceed with lateral ridge bone grafting. The xenograft particles were placed at the site (Straumann Xenograft) and secured with a resorbable collagen membrane (Straumann FLEX). The patient then started his orthodontic treatment, which lasted 2.5 years. The improvement in the overbite was quite noticeable (Fig. 3,4) and we were able to consider the option of immediately restoring our implant.

The updated CBCT Scan showed favorable long term bone grafting results and we agreed to pursue an immediate provisionalization protocol with non-functional loading (Fig.5). The periodontist would be placing his implant and on the same day the patient would have his restoring clinician take implant level impressions. His restoring dentist would deliver a lab processed screw retained provisional acrylic crown within 48h.

Surgery Day (Immediate loading on a healed site)

The patient was given pre-operatively 2 gr of amoxicillin and 8 mg of Dexamethasone orally. A papilla preservation technique was utilized for the flap elevation, thus sparing any compromise to the adjacent papillae. A small full thickness flap was raised accordingly.

The most important aspect of our treatment plan was our ability to achieve high primary implant stability with a reliable torque. This was accomplished by utilization of a Straumann SLActive Roxolid BLX implant. The BLX implant has a unique thread design, which allows placing an implant with a high insertion torque of no less than 35 Ncm without instilling overwhelming crestal bone pressure. A BLX RB 3.75 x 12 mm implant was placed (Fig.6,7) at 50 Ncm under copious irrigation of Saline cooled at 5 degrees Celsius as per the implant manufacturer's surgical protocol. The implant was placed in a prosthetically driven fashion that would allow a screw retained final prosthesis at the end of the restorative phase of treatment (Fig 8,9).

An advantage of the healing abutments on the BLX system is that they allow the surgeon to choose the height of the transgingival component (Gingival height, GH) and the supra-gingival part (Abutment height, AH). In our case, a 5mm, GH 1.5mm, AH 2mm RB/WB healing abutment was placed with chlorhexidine gel 0.2% and then hand tightened (Fig 10,11).

The vertical incisions of the papilla preservation flap were closed with 5-0 chromic gut sutures in a continuous interlocking manner (Fig 12). A final placement periapical radiograph was taken (Fig 13) for patient records. No other prescription medications were provided.


11


12

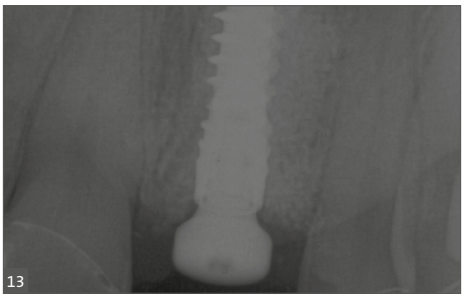
13


14a


14b

Predictable Immediate Loading for the Single Tooth-bound Site. Anterior and Posterior Case Review

The patient then went immediately to his restoring dentist who took implant level impressions with PVS impression material, in order to have the laboratory fabricate a highly polished and lab-designed screw retained acrylic provisional crown. The crown was delivered within 48h ensuring there were no contact in centric or excursions (Fig 14).

Posterior Single Implant Case (Dr. F.G.)

A 45 year old female with clear medical history was referred for Implant treatment replacing a non salvageable mandibular left first molar due to sub-gingival caries and furcation involvement (Fig.15). The patient has had her first premolars removed for the left side at a very young age for orthodontic reasons.

After clinical and radiographic (CBCT) examination (Fig 16), it was felt that the osseous structure would allow for extraction and immediate implant placement. We discussed with the patient the option of immediate temporization, should the insertion torque be favorable and allow it.

Surgery Day (Immediate placement in fresh extraction socket with immediate loading in 7 days)

The patient was given 2gr Amoxicillin and 400mg Ibuprofen pre-operatively. The tooth was removed atraumatically by sectioning the roots without raising a flap (Fig 17). Preparation of the osteotomy site was initiated using the Straumann Needle Drill engaging the inter-radicular bone. Once the position and angulation of the osteotomy site was confirmed clinically and with a periapical radiograph, the site was further prepared for placement of a Straumann SLActive Roxolid BLX WB 5.5x10mm (Fig 18). Based on the unique thread design of the BLX Implant, the insertion torque of 50Ncm was predictably achieved. Allograft bone particles were used to graft the jumping gap circumferentially. The achieved primary stability allowed for immediate temporization. Therefore, an Implant level Impression was taken –chairside- using Open Tray Impression Copings with heavy and light body PVS Impression material (Fig 19). Limited buccal soft tissue recession was noted at the time of the impressions and therefore we decided to delay the insertion of the temporary crown beyong our usual 48h time line to allow for more soft tissue growth facially. To further enhance the growth, a small diameter healing abutment with short gingival height (RB/WB 5mm x GH 2.5mm x AH 2mm) was placed with chlorhexidine gel 0.2% and hand tightened (FIG 20). We approximated the facial tissue to the healing abutment with a horizontal mattress suture around the Implant as well as two interrupted sutures using 5-0 Ethilon Sutures (Fig 21, 22).

The screw retained temporary crown was fabricated at the laboratory using CAD/CAM technology by Zirkonzahn (Fig 23, 24, 25, 26, 27). The lab was advised to under contour the facial aspect of the crown to minimize the pressure to the facial soft tissue. The screw retained crown was inserted 7 days after implant insertion and torqued to 25Ncm. A significant improvement in the facial recession was noted (Fig 28) as well. Sterile Teflon tape


15

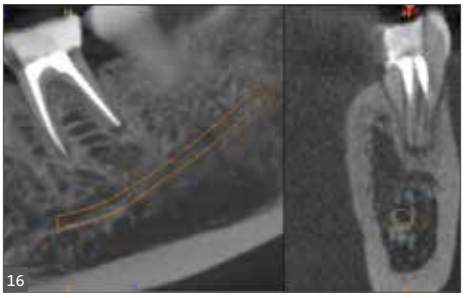
16


17


18


19

was placed in the access hole and sealed with flowable composite resin (Fig 29, 30, 31). The occlusion was checked to ensure no contact in centric or excursions.

Conclusion

Contemporary implant practices call for an enhanced patient experience with an increasing expectation for shortened treatment times and more predictable aesthetics. Implant fixture design can have a significant impact in addressing those concerns and improving surgery and prosthetic results.

The authors here utilized the advanced features of the Straumann SLActive Roxolid BLX implant to predictably achieve a favorable initial torque of 50Ncm. The thread design of this implant allows it to "cut" through bone with minimal friction and yet achieve –predictably and consistently- high primary stability. The surgeon is able to under-prep the osteotomy site and yet avoid increased heat with the inspired body vs. thread shape. Achieving a minimum torque of 35Ncm in soft maxillary bone is an outcome the surgeon can rely on. This allows the implant placer to choose an implant for immediate loading in any type of single site, be it molar or non-molar. This ability is enhanced by the fact that the BLX implant offers the same prosthetic platform across all implant diameters. For example, in scenarios where accidental over-drilling takes place and the clinician would have to abandon the implant installation or place a wider implant with a wider prosthetic platform, BLX offers an additional option. The surgeon can easily switch to a wider diameter implant (which will allow enhanced primary stability) and yet still maintain an aesthetically favorable narrow prosthetic platform, thus supporting the potential for superior cosmetic outcomes. This prosthetic flexibility (with a consistent narrow platform) of the BLX implants is made possible by their Roxolid nature (Ti-Zr implants), which exhibit superior structural integrity and mechanical resistance when compared to commercially pure titanium implants (15).

Surgeons can also utilize the BLX implant's narrow neck design to their advantage. The decrease in implant diameter at the implant head allows for minimal crestal bone pressure and for increased bone availability between adjacent structures for papilla support and maintenance. This is only one of the many distinctive features of the BLX self-condensing implant but it's worth highlighting as it has a powerful long term impact on soft tissue thickness and gingival stability around implant supported crowns and thus directly affect our final crown aesthetics and patient satisfaction.

Last but not least is the fact that the BLX implant exhibits the SLActive surface configuration which accelerates osseointegration and supports its suitability for immediate placement and immediate loading. The combination of the SLActive surface with the Roxolid structure has been shown to achieve osseointegration strength at 4 weeks, equal to the strength achieved by commercially pure Grad IV titanium implants at 12 weeks (16). The sum of the above properties for the BLX implant allows for much faster integration, flexible prosthetics and improved loading times and conseuqently patient satisfaction.

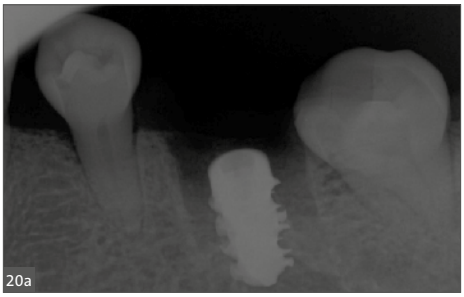
20a

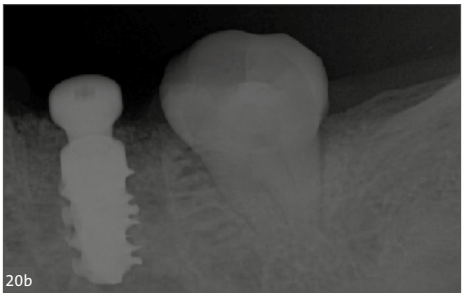
20b


21

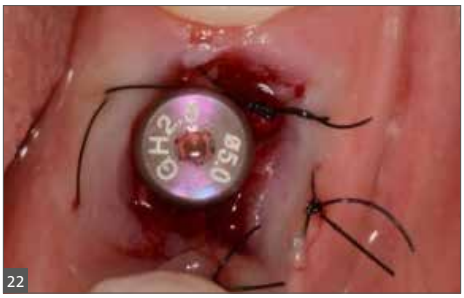
22


23

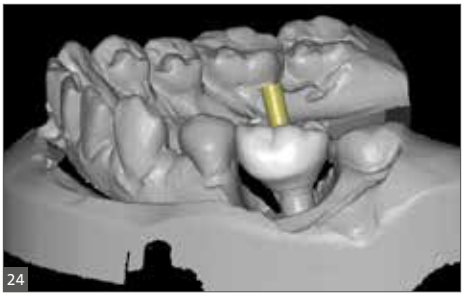
24

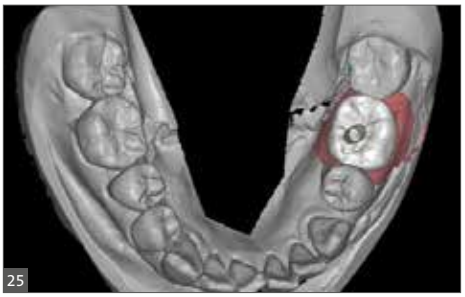
25


26

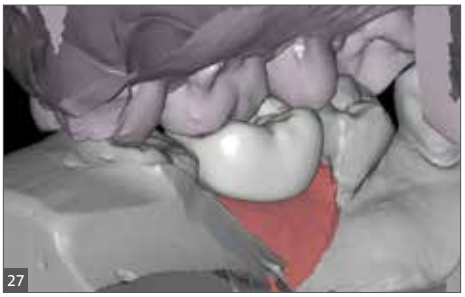
27


28


29

References

1. Chiapasco M.
Early and Immediate Restoration and Loading of Implants in Completely Edentulous Patients. Int J Oral Maxillofac Implants 2004;19(Suppl):76-91
2. Chung S, McCullagh A, Irinakis T.
Immediate Loading in the Maxillary Arch: Evidence-Based Guidelines to Improve Success Rates: A Review. J Oral Implantol. 2011 Oct;37(5)610-21
3. Avila G, Galindo P, Rios H, Wang H-L.
Immediate Implant Loadi ng: Current Status from Available Literature. Implant Dent 2007;16:235-245.
4. Raes F, Eccellente T, Lenzi C, Ortolani M, Luongo G, Mangano C, Mangano F.
Immediate Functional Loading of single implants: A multicenter study with 4 years of follow-up. J Dent Res Dent Clin Dent Prospects. 2018 Winter;12(1):26-37.
5. Cannizzaro G, Felice P, Trullenque-Eriksson A, Lazzarini M, Velasco-Ortega E, Esposito M.
Immediate vs. early loading of 6.6mm flapless-placed single implants: 9 years after-loading report of a split-mouth randomized controlled trial. Eur J Oral Implantol. 2018;11(2):163-173
6. Gallucci GO, Hamilton A, Zhou W, Buser D, Chen S.
Implant placement and loading protocols in partially edentulous patients: A systematic review. Clin Oral Implants Res. 2018 Oct;29 Suppl 16:106-134
7. Huynh-Ba G, Oates TW, Williams MAH.
Immediate loading vs. early/conventional loading of immediately placed implants in partially edentulous patients from the patients' perspective. A systematic review. Clin Oral Implants Res. 2018 Oct;29 Suppl 16:255-269.
8. Degidi M, Piattelli A.
Comparative Analysis Study of 702 Dental Implants Subjected to Immediate Functional Loading and Immediate Nonfunctional Loading to Traditional Healing Periods with a Follow-up of up to 24 Months. Int J Oral Maxillofac Implants 2005;20-99-107.
9. Ma S, Tawse-Smith A, Brown SDK, Duncan W.
Immediately restored single implants in the aesthetiz zone of the maxillar using a novel design: 5-year results from a prospective single-arm clinical trial. Clin Implant Dent Relat Res. 2019;21(2):344-351.
10. Raes S, Cosyn J, Noyelle A, Raes F, De BRuyn H.
Clinical outcome after 8 to 10 years of immediately restored single implants placed in extraction sockets and healed ridges. Int J Periodontics Restorative Dent. 2018 May/Jun;38(3):337-345.
11. Zarrabi MJ, Radvar M, Shiezadeh F, Mokhtari MR, Nejat A.
Immediate nonfunctional loading of a single implant in the posterior maxillary area: A randomized clinical trial. J Long Term Eff Med Implants. 2018;28(2):145-153.
12. Meloni SM, Baldoni E, Duvina M, Pisano M, De Riu G, Tallarico M.
Immediate non-occlusal versus delayed loading of mandibular fist molars. Five-year results from a randomized controlled tiral. Eur J Oral Implantol. 2018;11(4):409-418.
13. Irinakis T, Wiebe C.
Initial Torque Stability of a New Bone Condensing Dental Implant. A Cohort Study of 140 Consecutively Placed Implants. J Oral Implantol 2009;35(6):277-82.
14. Aldahlawi S, Demeter A, Irinakis T.
The Effect of Implant Placement Torque on Crestal Bone Remodeling After 1 year of Loading. Clinical, Cosmetic and Investigational Dentistry 2018:10-203-209.
15. Badran Z, Struillou X, Strube N, Bourdin D, Dard M, Soueidan A, Hoomaert A.
Clinical Performance of Narrow-Diameter Titanium-Zicronium Implants: A Systematic Review. Implant Dent 2017 Apr;26(2):316-323.
16. Galli S, Jimbo R, Naito Y, Berner S, Dard M, Wennerberg A.
Chemically modified titanium-zirconium implants in comparison with commercially pure titanium controls stimulate the early molecular pathways of bone healing. Clin Oral Implants Res. 2017 Oct;28(10):1234-1240.


30


31

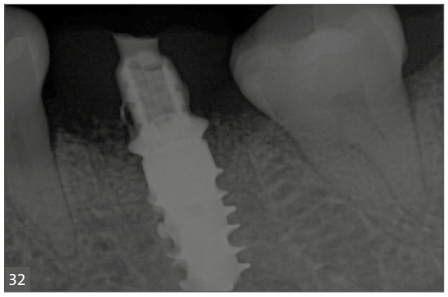
32

Straumann North American Headquarters
Straumann USA, LLC
60 Minuteman Road
Andover, MA 01810
Phone 800/448 8168 (US) • 800/363 4024 (CA)
Fax 978/747 2490
www.straumann.us • www.straumann.ca

ifu.straumann.com

6/19 V1 D1