Mandibular Pro Arch hybrid reconstruction with immediately loaded fixed provisionalization

MARIANO A. POLACK, DDS, MS

Private Practice in Prosthodontics, Gainesville, VA

JOSEPH M. ARZADON, DDS, MD

Fellow, American Association of Oral and Maxillofacial Surgeons

Board certified, American Board of Oral and Maxillofacial Surgery

Private practice, Gainesville, VA

INTRODUCTION

A 76 year-old woman presented to the prosthodontist's office with the chief concern of painful, broken and discolored teeth (Figs 1 to 4). The patient also desired an improved smile with a cost-effective solution that would allow her to function comfortably. A complete clinical, radiographic examination and study models were obtained. The medical history was significant for high blood pressure, diabetes mellitus type 2, and depression. Her medications included Losartan, Glimepiride, and Prozac. The patient presented with generalized advanced periodontal disease with gingival inflammation, recession, heavy calculus and advanced bone loss on the lower anterior teeth. The posterior mandible also showed severe bone loss. In addition, both arches had several tooth remnants, and the anterior teeth presented significant buccal flaring. The panoramic radiograph showed multiple radiolucent periapical lesions on several teeth (Fig 5). The patient's dentition was deemed unrestorable, and a Straumann Pro Arch solution was proposed to restore the mandibular arch. Due to the lack of available bone in the posterior mandible, four implants would be placed, with the two distal implants tilted at 30 degrees. A complete maxillary denture would be fabricated to restore the maxillary arch. As a result of the severe gingival inflammation and presence of multiple periapical infections the patient was not considered a good candidate for immediate implant placement. It was decided to delay implant placement for 4-6 weeks to allow for improvement of the soft tissue health and to increase the amount of attached gingiva, especially in areas of recession. This would facilitate the handling of the flaps, as well as the resolution of pathology. It was therefore proposed to extract all remaining teeth and deliver immediate complete maxillary and mandibular dentures. Approximately 6 weeks after extractions, the mandibular implants would be placed and immediately loaded with an interim hybrid prosthesis. The definitive restorative procedures for a complete maxillary denture and mandibular hybrid prosthesis reinforced with a Straumann CARES milled bar would begin eight weeks after implant placement.

TREATMENT

The study models were used to fabricate custom trays and final impressions were made to fabricate the immediate maxillary and mandibular complete dentures. Teeth #21-30 were extracted without difficulty and with minimal to no flap elevation. The apical granulomas were removed with currettes and socket granulation tissues and diseased bone were removed. Minor alveoloplasty was completed to allow the insertion of the immediate dentures. Weekly follow up appointments were made for one month, to monitor healing and adjust the prostheses, as needed. In addition, two weeks after the extractions, the patient was seen for implant preoperative evaluation using a CBCT (Fig 6 –8).

The extraction sites healed well with healthy gingiva over the sockets and resolution of the active periodontal and periapical infections. The patient's personal affairs prevented her from scheduling surgery until two months after the extractions, at which point implant placement was completed. After successful induction of IV sedation, Lidocaine 2% with 1:100,000 epinephrine x 7.2 cc was injected as block and infiltration to the surgical sites. Crestal and distobuccal releasing incisions were made to elevate buccal and lingual flaps. The crestal bone reduction was measured according to the prosthodontist's instructions and marked with a #701 bur. The ostectomy was completed with the #701 bur to remove 6mm of crestal bone and tapered posteriorly to the molar crest. A midline osteotomy was made to stabilize the Straumann Pro Arch Guide to help make the posterior angled osteotomies. The mental foramina were identified and the distal angled osteotomies were just anterior to each mental foramen. Starting with the #20,29 sites, Straumann Bone Level Implant system was used starting with the 2.2 mm drill, followed by standard drilling sequence using copious amounts of normal saline irrigation in type 3 bone. Guide pins were used to confirm position, orientation, and depth. The #23, 26 osteotomies were made without the guide. The osteotomies were lightly profiled, then Straumann RC SLActive ROXOLID implants 4.1 x 14 mm were placed with primary stability using a torque setting of 35 Ncm. A hand torque was used to seat the implants to the proper depths with torque above 35 Ncm and the height markings oriented buccally for the posterior implants and facially for the anterior implants (Fig 9 -12). Angled 30 degree, D4.6mm, GH 4mm, Type A screw-retained abutments (SRA) were connected to the posterior implants. Straight 0 degree, D4.6mm, GH 4mm screw retained abutments (SRA) were connected to the anterior implants. The abutments were torqued to 35 Ncm and the flaps were approximated with 4-0 chromic sutures making sure that the abutment margins were visible (Fig 13). The patient was dismissed to the prosthodontist's office, located at a short distance from the surgeon's office, to convert the immediate provisional denture into an interim provisional hybrid restoration.

At the prosthodontist's office, occlusal registration material was injected on the intaglio surface of the mandibular denture and the prosthesis was seated over the SRA abutments (Fig 14). In this manner, the position of the abutments relative to the denture was registered, and perforations were made in those areas to facilitate the conversion process. Non-engaging titanium NC/RC copings were connected to the SRA abutments (Fig 15). After confirmation of clearance of at least 1 mm between the copings and the perforations on the denture, a rubber dam was placed over the cylinders, to protect the surgical wound (Fig 16 – 17).

Access holes were covered with teflon tape, and autopolymerizing acrylic resin was mixed and injected with a Monoject syringe to connect the copings to the immediate denture. Profuse irrigation was used to prevent the heat of polymerization from affecting the surgical site. The interim hybrid prosthesis was removed, and SRA analogs were connected to the NC/RC copings. Additional acrylic was mixed and added over the intaglio surface of the prosthesis, to eliminate concavities and porosities (Fig 18). Flanges were removed, and the tissue side was finished with a slightly convex contour to facilitate hygiene procedures (Fig 19). An impression of the implants was made to fabricate a verification jig to be used at the beginning of the definitive restorative phase (Fig 20). Screws were torqued to 15 Ncm, occlusal access holes were sealed with teflon tape and a semi-rigid composite, and the occlusion was adjusted (Fig 21). A panoramic radiograph was taken for post treatment evaluation. After care instructions included a soft food diet, a 0.12% clorhexidine rinse and follow up appointments at 1, 2 and 6 weeks. Approximately 2 months after the implant surgery, the provisional was removed and torque tests were completed.

Fig. 1 Initial extraoral presentation.

Fig. 2 Initial intraoral presentation. Notice the flared teeth, heavy calculus and obvious esthetic compromise.

Fig. 3 Pretreatment, occlusal view, maxillary arch

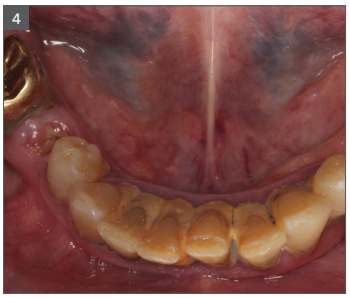

Fig. 4 Pretreatment, occlusal view, mandibular arch.

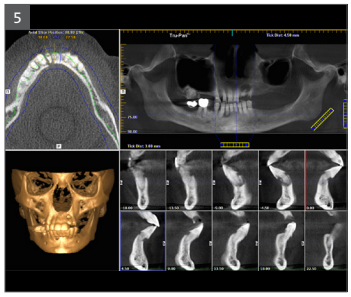

Fig. 5 Pretreatment CBCT.

Fig. 6 Two months after extraction of all teeth, soft tissues show improved quality and health.

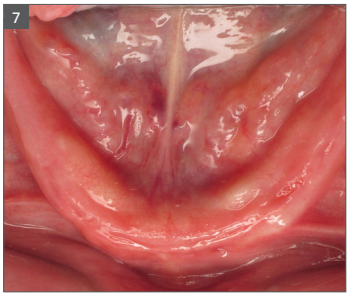

Fig. 7 Occlusal view of mandibular arch with healed ridge and presence of keratinized gingiva.

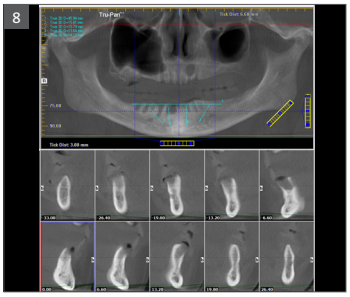

Fig. 8 Implant preoperative CBCT.

Tissues looked healthy with no evidence of mucositis or infection. There was moderate calculus on the bottom of the prosthesis and some food debris around the abutments. After cleaning and irrigating with Peridex, the abutments were torqued to 35 Ncm without pain and mobility of the implants. The provisional was placed back and the occlusal screws tightened with finger pressure. The access openings were covered with cotton, then a semi-rigid composite resin. The patient was referred back to the prosthodontist's office for fabrication of the final restoration.

The interim mandibular hybrid prosthesis was removed, and final impressions for the definitive maxillary complete denture and mandibular hybrid denture were made with custom trays and vinyl polisiloxane. At the next appointment, the accuracy of the implant master cast was confirmed with a verification jig. Occlusal and vertical dimension records were obtained and a final shade selected. A trial tooth setup was tried in and approved by the patient and prosthodontist at the following appointment. The models and tooth setup were sent to Straumann CARES to be scanned for the fabrication of the CAD/CAM titanium bar. Seamless communication between the Scan & Shape team, the prosthodontist and the dental laboratory facilitated minor modifications to the bar design which was then milled and shipped back for try in (Fig 22 – 24). At the next appointment, the passive seating of the Straumann CARES CAD/CAM bar was confirmed visually and radiographically (Fig 25). An additional try in appointment was scheduled to assess the tooth setup on the bar, and the upper and lower prostheses were processed and finished (Fig 26).

At the insertion appointment, the maxillary denture was evaluated with pressure indicating paste and adjusted. The esthetics, phonetics and cleansability of the prostheses were evaluated, and minor occlusal adjustments were made. Screws were torqued to 15 Ncm and the occlusal access holes were sealed with Teflon tape and composite resin. Hygiene instructions were reviewed with the patient, and she was placed on a 3-month implant maintenance program in order to promote healthy oral tissues and assess her biologic and mechanical needs on a regular basis (Fig 26 – 29).

CONCLUSION

The patient's needs and desires required a cost effective, flexible solution that would maximize clinical and esthetic results, while minimizing cost and the number of appointments. Straumann Pro Arch provided an excellent outcome that surpassed her expectations. The angled posterior implants made optimal use of the available bone anterior to the inferior alveolar nerve, eliminating the need for additional procedures, like nerve lateralization. The SLActive Roxolid Bone Level implants permitted the team to immediately load the fixtures with confidence. The angled SRA abutments compensated for the distal tilting of the posterior implants, allowing for a prosthesis supported with fewer fixtures, and a smaller cantilever. The expertise of the Scan & Shape team, and their fluent communication with the dental laboratory and restorative doctor facilitated the fabrication of an accurate, properly designed CAD/CAM milled bar to support the definitive prosthesis. Since the treatment was completed, the patient has returned for a consultation to receive a Straumann Pro Arch fixed solution on her maxillary arch.

The authors want to thank Dennis Purinton for the fabrication of the final restorations.

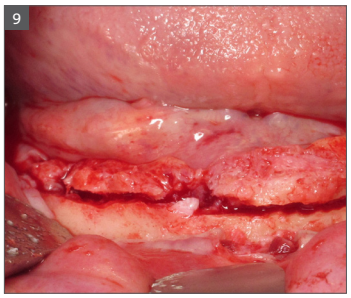

Fig. 9 Ostectomy of the crestal bone with reduction according to prosthetic requirements and leveling of the ridge.

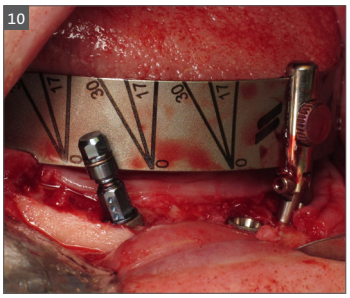

Fig. 10 Placement of implant #29 angled at 30 degrees using the Pro Arch Angulation Guide.

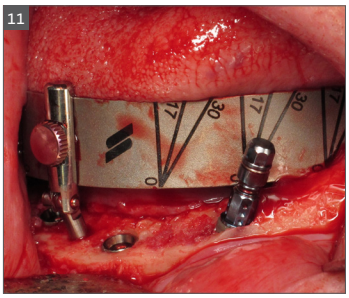

Fig. 11 Placement of implant #20 at 30 degrees using the Pro Arch Angulation Guide.

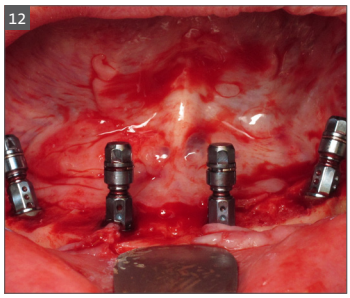

Fig. 12 Implants fully seated with height markings oriented on the buccal for the posterior implants and labial for the anterior implants.

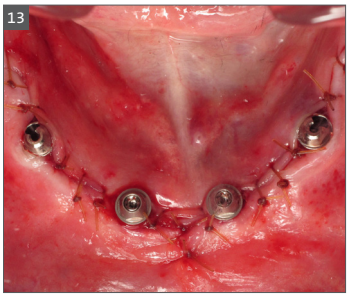

Fig. 13 SRA abutments torqued to 35 NCm and the flaps sutured around the SRA abutments.

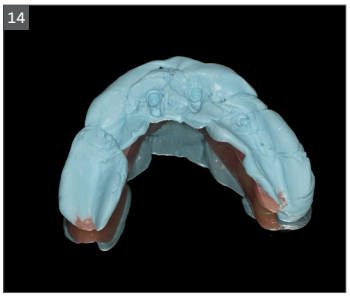

Fig. 14 Bite registration material injected on the intaglio of immediate mandibular denture to locate the position of SRA abutments. Perforations to accommodate the NC/RC copings were done through those indentations.

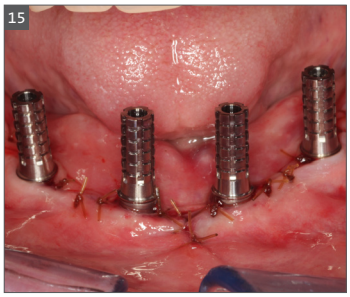

Fig. 15 NC/RC copings connected to the SRA abutments.

Fig. 16 Perforations done on mandibular denture to accommodate the NC/RC copings.

Fig. 17 Immediate mandibular denture seated over NC/RC copings. At least 1 mm clearance between the perforations and copings is desirable to allow for enough acrylic to pick up the copings. Notice the rubber dam protecting the surgical wound, and the teflon tape covering the access holes on the copings

Fig. 18 Intagliio surface of the prostheses with SRA abutment analogs connected to the NC/RC copings. Additional acrylic was added to eliminate concavities and porosities.

Fig. 19 Tissue side of interim hybrid prosthesis. Notice the slightly convex profile to allow ease of cleansabiity.

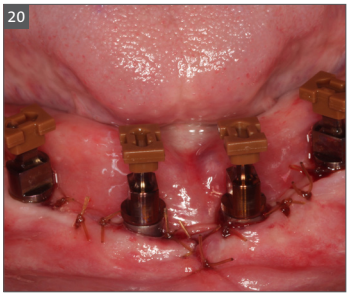

Fig. 20 Impression posts connected to SRAabutments. An impression was made to fabricate a verification jig that would be used at the start of the definitive restorative process.

Fig. 21 Immediate postoperative view of the interim hybrid prosthesis and immediate maxillary complete denture.

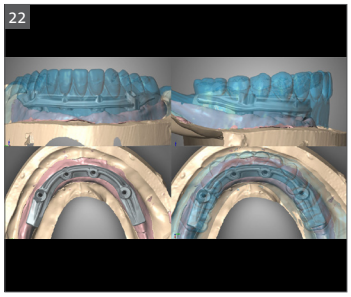

Fig. 22 Initial proposed design by the Scan & Shape Team for the CAD/CAM Strauman Cares bar. Fluent communication between the restorative team and Strauman Cares and allowed for quick design modifications specific to the case.

Fig. 23 Finished CAD/CAM Straumann Cares bar.

Fig. 24 Strauman Cares bar, intraoral view. Passive fit was confirmed at this appointment

Fig. 25 Finished complete maxillary denture and mandibular hybrid prosthesis.

Fig. 26 Intraoral postoperative view.

Fig. 27 Close-up, mandibular hybrid prosthesis. The design allowed for adequate room for oral hygiene.

Fig. 28 Extraoral postoperative view. An excellent esthetic and functional result was obtained. Detailed hygiene and maintenance instructions were given, and the patient placed on a 3-month recare program.

Fig. 29 Final radiographic presentation confirming the accuracy of fit of the Straumann Cares bar.