

## Early osseointegration to hydrophilic and hydrophobic implant surfaces in humans

### Scientific source

Lang NP, Salvi GE, Huynh-Ba G, Ivanovski S, Donos N, Bosshardt DD.  
*Clin. Oral Implants Res.* 2011;22:349–356.

### Introduction

The surface characteristics of titanium implants influence the rate and degree of osseointegration. Moderately rough surfaces such as SLA® have demonstrated superior bone-to-implant contact (BIC) than surfaces such as titanium plasma-sprayed (TPS), Al<sub>2</sub>O<sub>3</sub>-blasted or machined surfaces. Chemical modification, such as with the hydrophilic SLActive® surface, can further enhance the osseointegration process.

Investigations comparing osseointegration with various implant surfaces have been performed, but tend to be in vivo animal studies. No data are available from human studies, and the healing sequence of the early osseointegration process in man and how it compares to the process – seen in other in vivo investigations – is relatively unknown.

The aim of this investigation, therefore, was to evaluate the rate and degree of osseointegration at two different implant surfaces (SLA® and SLActive®) during the early phases of healing in a human model.

### Materials and methods

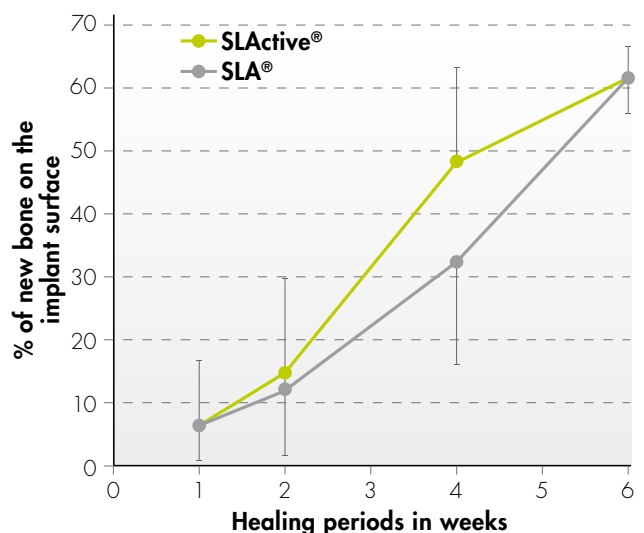
A total of 49 specially designed titanium implants (length 4 mm, outer diameter 2.8 mm) with either a SLA® or SLActive® surface were placed in the retromolar region of 28 healthy volunteers. A healing cap with an internal screw assembly was attached to the coronal part of the implant. After submerged healing periods of 7, 14, 28 and 42 days, the implants were removed using a specially designed trephine, which removed the implant and circumferential tissue of 1 mm thickness.

Histological sections were prepared and histometric analyses performed for amounts of new bone, old bone, bone debris, soft tissue and BIC.

### Results

Healing was uneventful at all sites. Of the 49 implants placed, 30 were available for histological/histometric analysis; difficulty in harvesting the biopsies resulted in the loss of some specimens.

Artifacts were present on a number of specimens – these areas were excluded from analysis so that only artifact-free regions were evaluated. The percentages of new bone-to-implant contact after 7, 14, 28 and 42 days are shown in table 1.



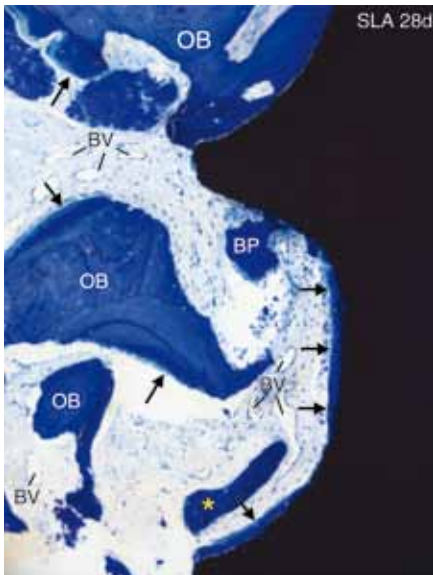
% mean value (SD)	7 days	14 days	28 days	42 days
SLActive®	6.14 (10.63)	14.80 (15.37)	48.34 (14.91)	61.62 (4.98)
SLA®	6.47 (6.02)	12.19 (10.62)	32.38 (16.21)	61.53 (5.79)

**Table 1:** Percentage of BIC after 7, 14, 28 and 42 days

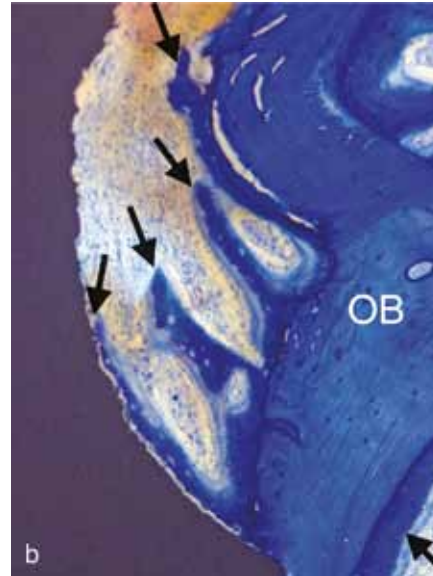
After 7 days, no differences were observed between the SLA® and SLActive® specimens. BIC was approximately 6%, and some early bone apposition was noted in places where existing bone was in close contact with the implant surface; bone therefore bridged a gap between old bone and implant in these situations. The majority of the space between bone and implant was filled with soft tissue comprising primitive matrix with various bone debris particles.

BIC increased to 12.2% and 14.8% for SLA® and SLActive®, respectively, after 14 days. Bone formation was noted on the existing bone, extending partly onto the implant surface. The beginning of new bone apposition was evident over large areas of the surface of the SLActive® implants. Larger bone particles were seen to be surrounded by osteoid, which helped trabecula formation.

BIC increased in both sample types by day 28, but was significantly higher with SLActive® (48.3%) than with SLA® (32.4%). A bony coating was observed with both specimen types (Figure 1 and Figure 2), but almost complete BIC was observed within some threads of the SLActive® implants (Figure 2), and new mineralized bone trabeculae were observed extending into the provisional matrix.



**Figure 1:** Light micrograph of the implant-tissue interface at a SLA® surface after 28 days (arrows indicate new bone)



**Figure 2:** Light micrograph of the implant-tissue interface at a SLActive® surface after 28 days (arrows indicate struts of woven bone trabeculae extending from old bone (OB) towards implant surface)

After 42 days, BIC increased further to 62% for both SLA® and SLActive®. An advanced stage of bone maturation was observed with both surfaces, and the formation of osteons was observed away from the implant surface. The osteocoating was noted to be thick and extensive, and was frequently connected via trabeculae, extending onto new bone.

### Conclusions

- Similar healing patterns were observed for both SLA® and SLActive® implants
- Osseointegration (BIC) was greater after 14 days and significantly greater after 28 days for SLActive®
- The rate of osseointegration was substantially slower (approximately double the healing time) in humans than that observed in animal studies
- This is the first study to demonstrate histologically the osseointegration process with SLActive® in humans

[www.straumann.com](http://www.straumann.com)

#### International Headquarters

Institut Straumann AG  
 Peter Merian-Weg 12  
 CH-4002 Basel, Switzerland  
 Phone +41 (0)61 965 11 11  
 Fax +41 (0)61 965 11 01