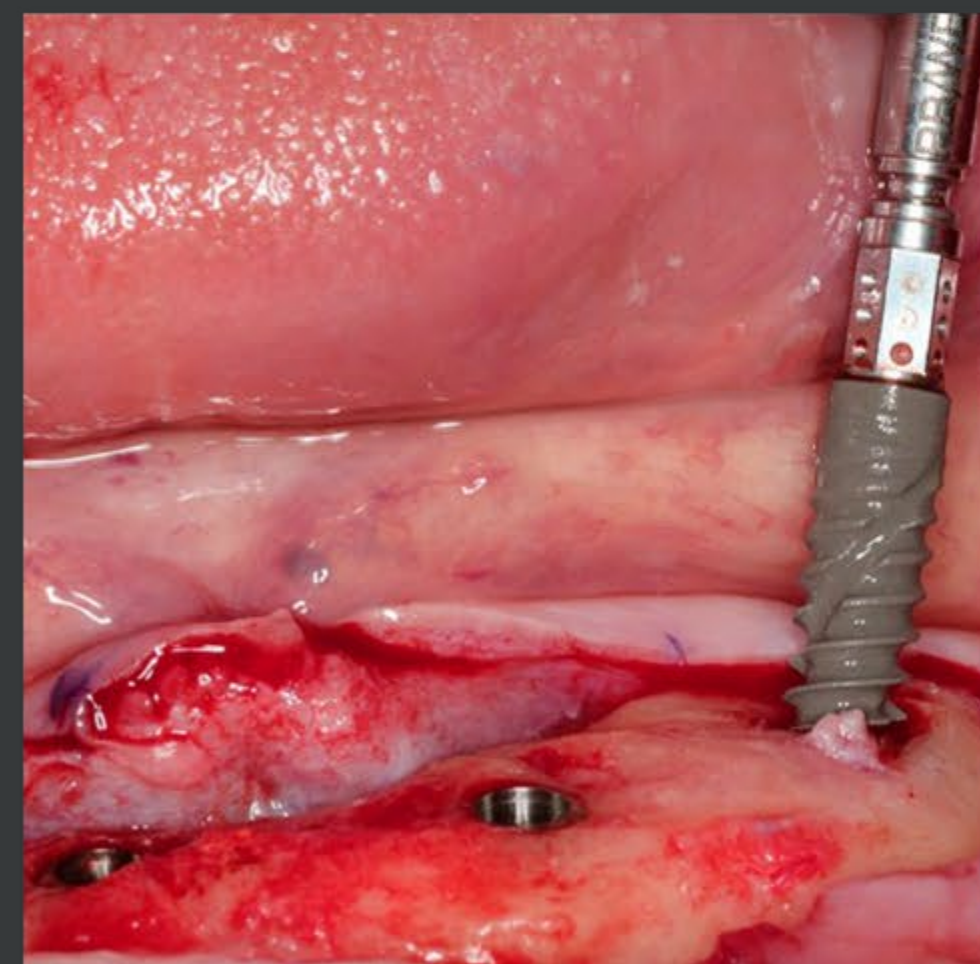
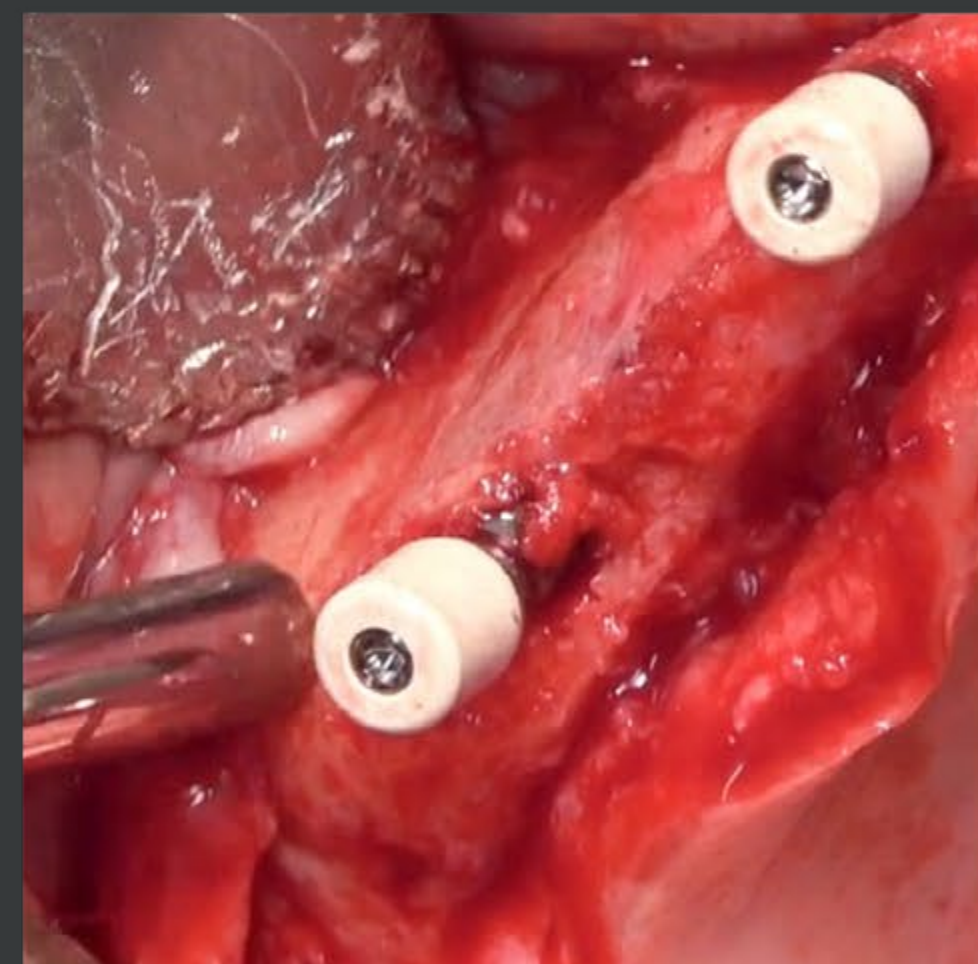
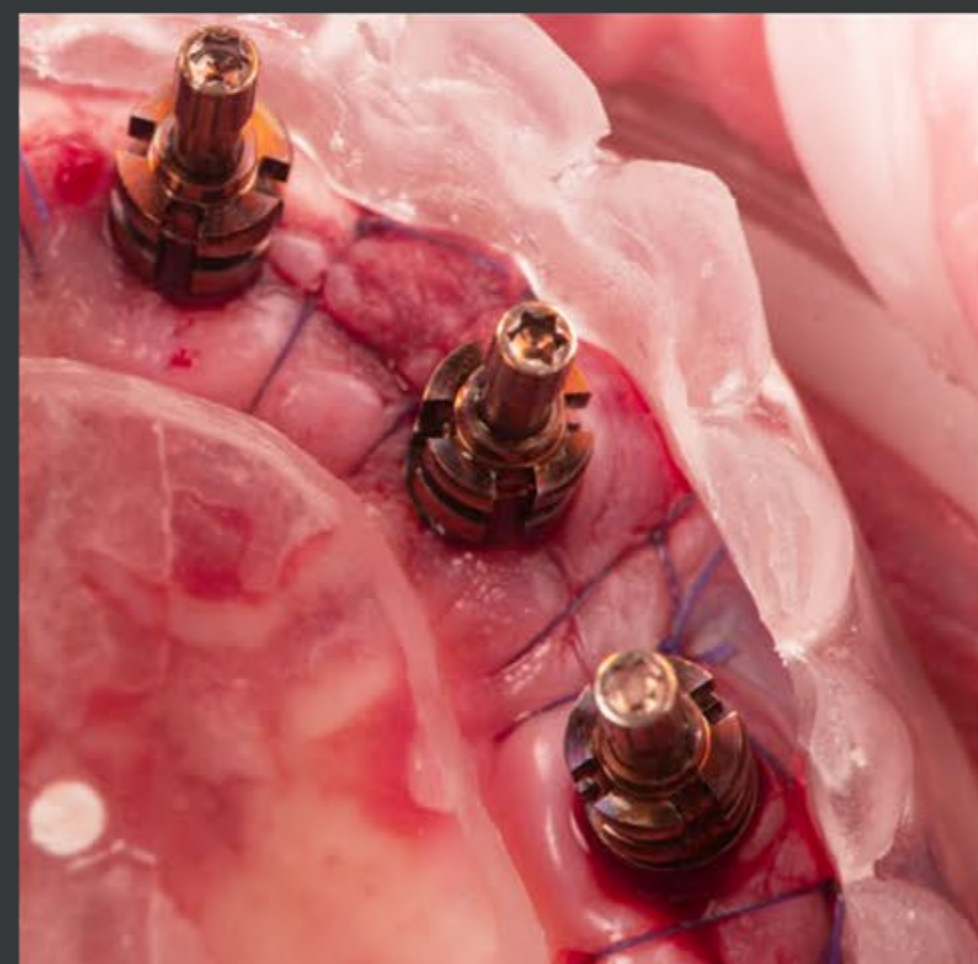
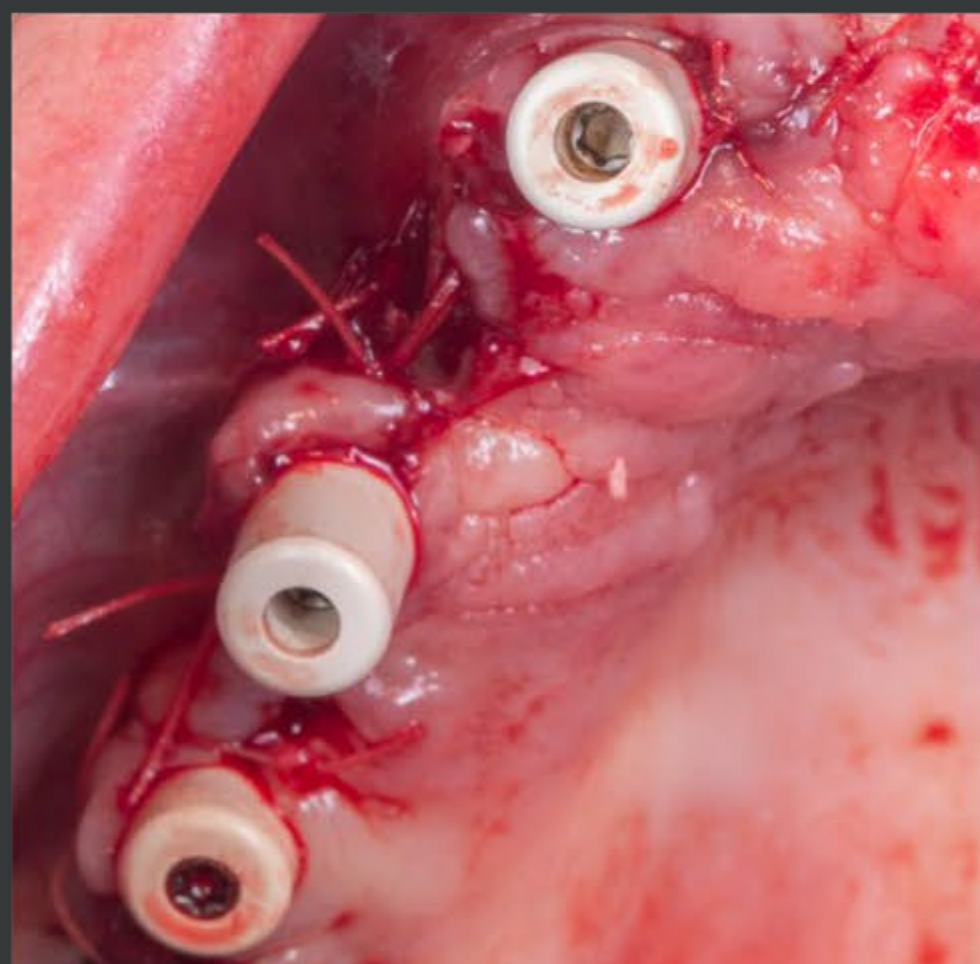
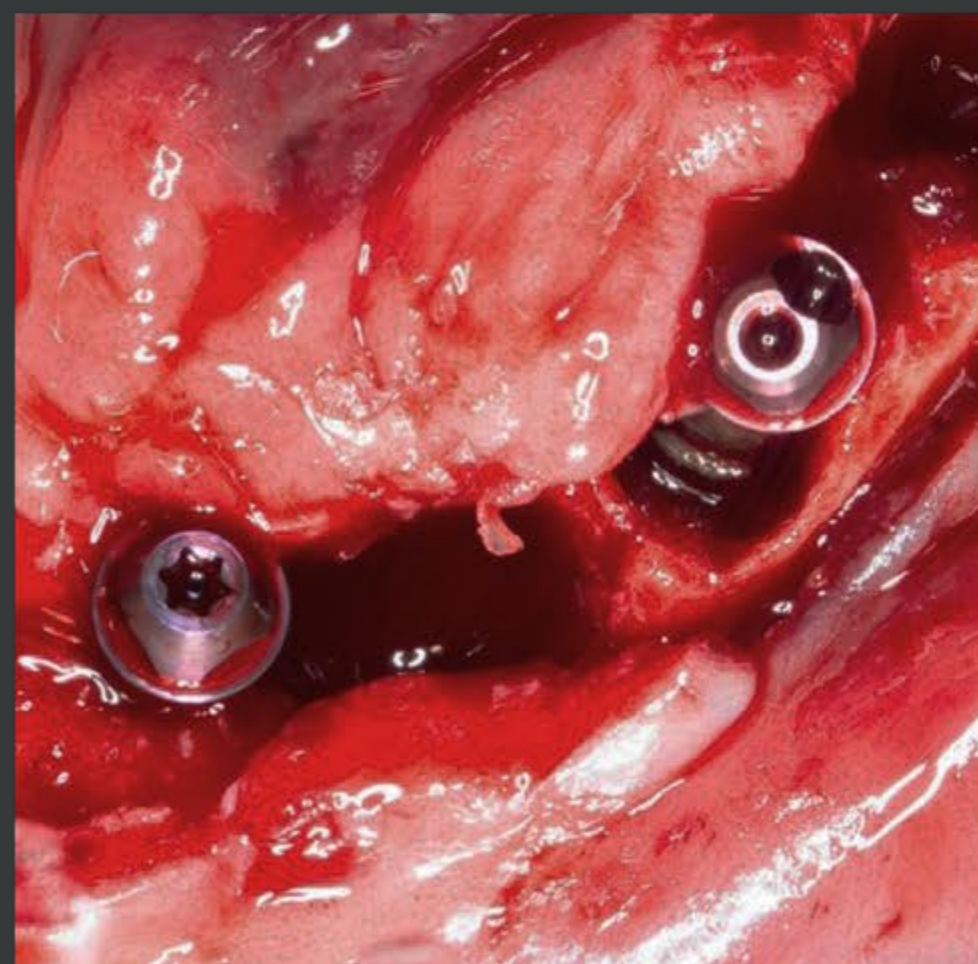
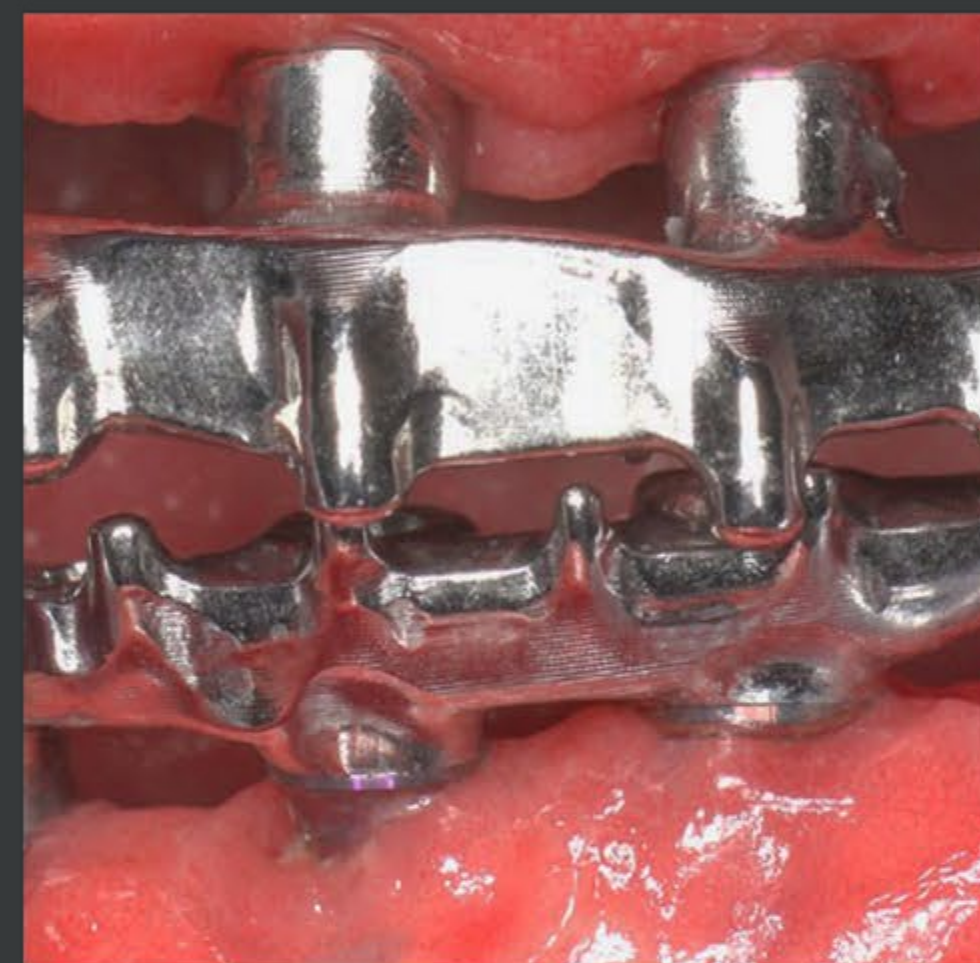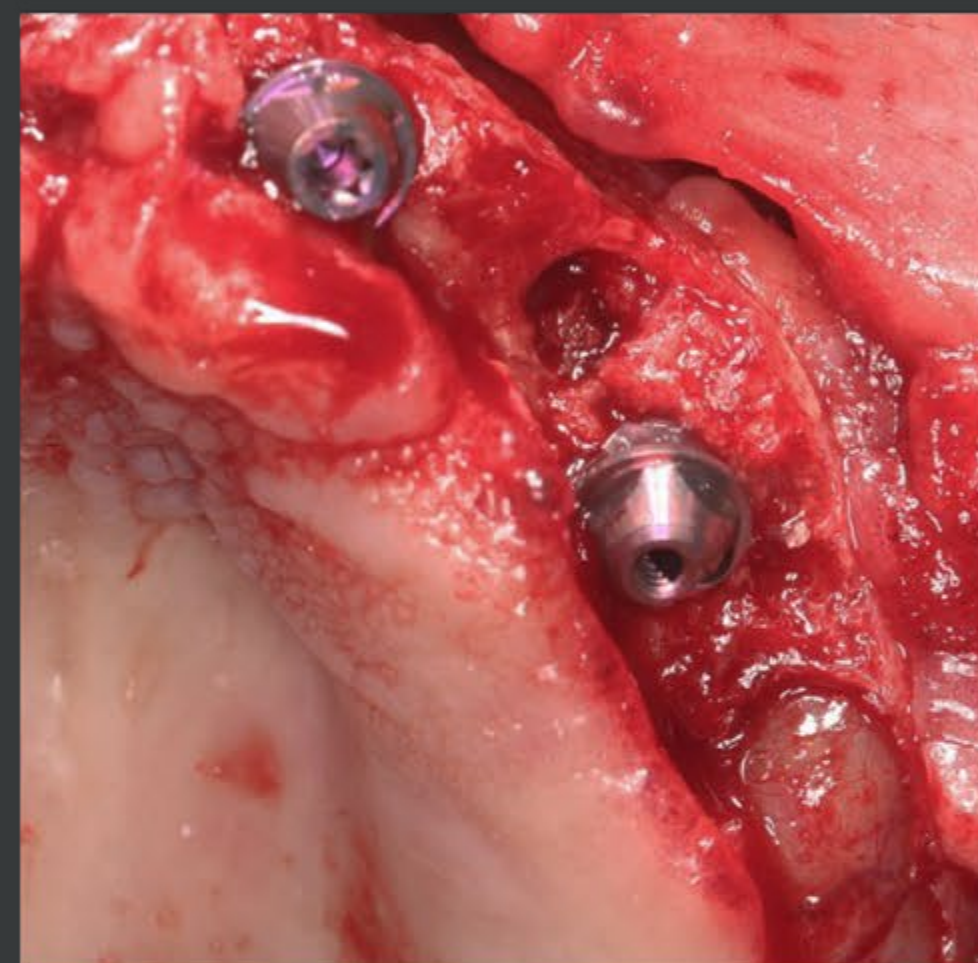
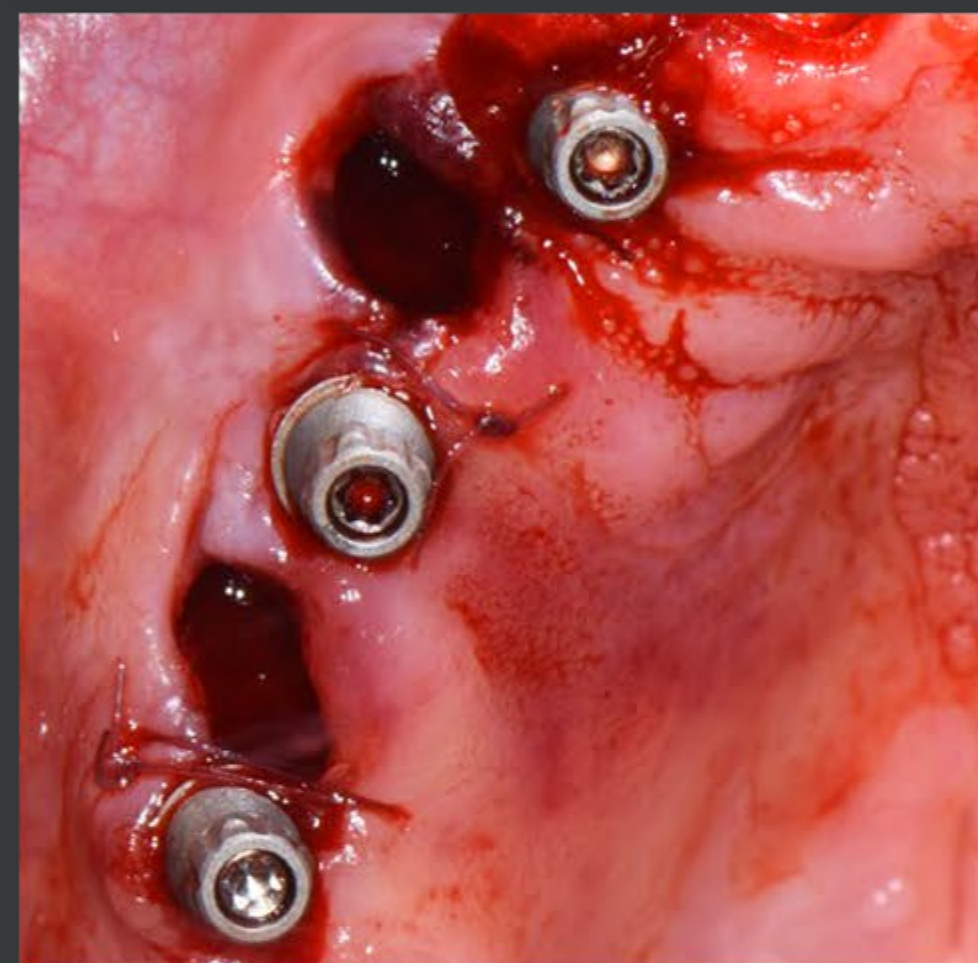

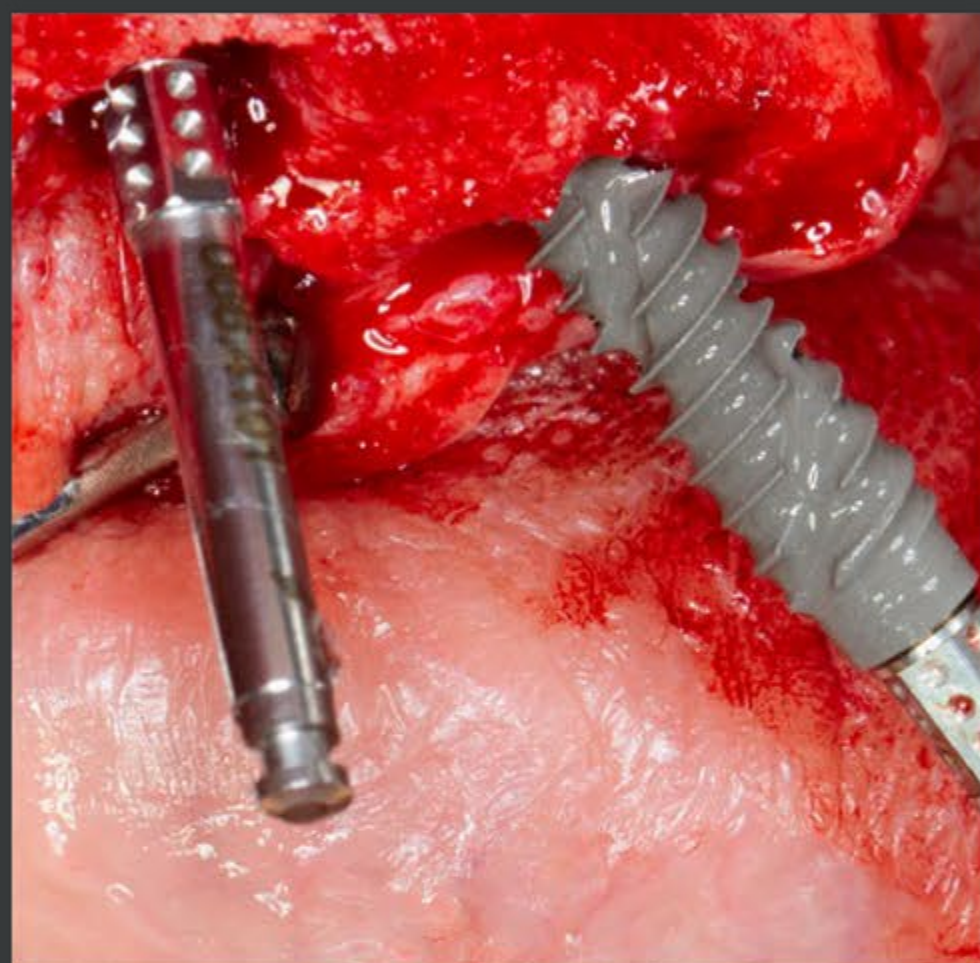
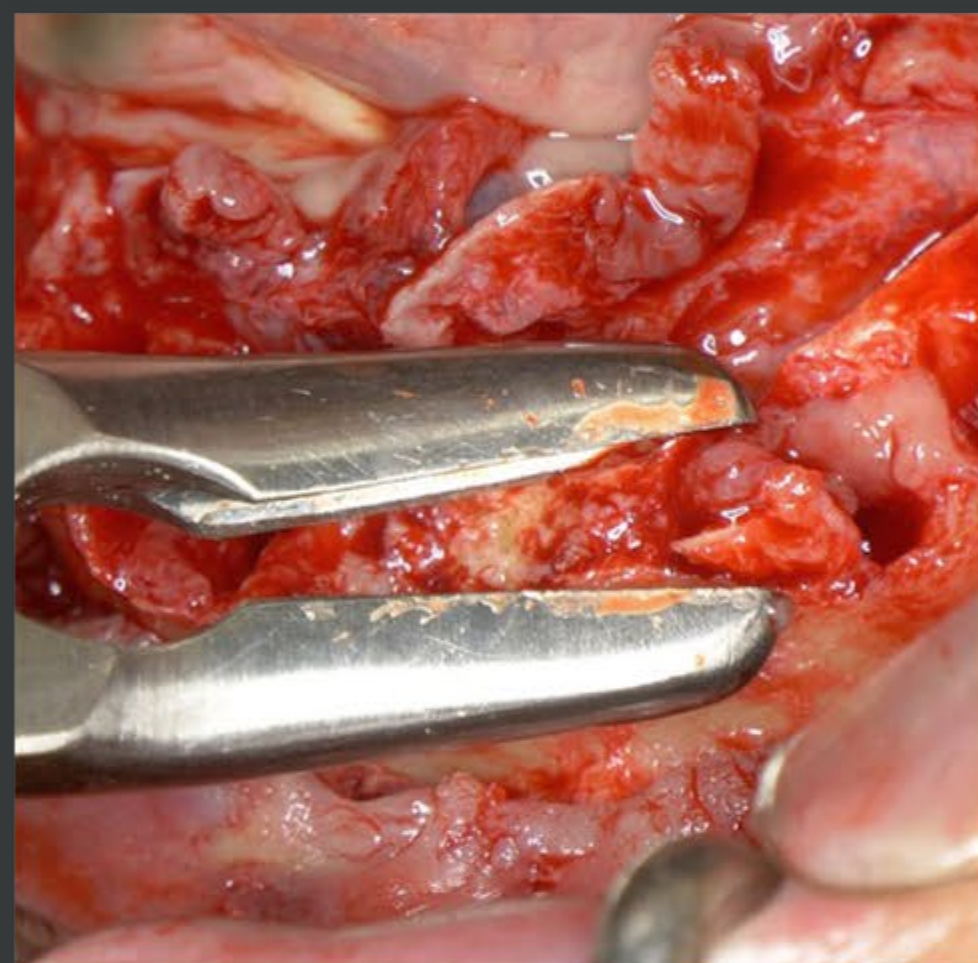# 10 full-arch challenges and solutions

with expert recommendations and clinical cases

Pro Arch BLX







**Louwrens Swart**

BChD, MChD (MFOS),  
Private practice, Cape Town,  
South Africa

## Dear reader

An aging population is leading to the need for major reform in social and health services in most of the developed world. Recently edentulism was acknowledged as one of the leading ten causes of “Years Lived with Disability” (YLD) in the developed world.<sup>1</sup> Edentulism is now the variable most often used, to gauge oral health in elderly populations.

Immediate fixed full-arch rehabilitation could be one of the cost-efficient solu-

tions for edentulous patients, and an increasing number of patients are willing to undergo this treatment.<sup>2</sup> Today the key drivers for restoration are functionality, enhanced esthetics, easy maintenance and restoring facial features for fully edentulous patients.

Each patient is unique and should be treated as such. Many treatment protocols exist, and a one-size-fits-all strategy is not always the best for the patient. The characteristics of the upper



and lower jaw can differ so much that each arch, or each quadrant could require a completely different approach, presenting a wide range of challenges to overcome.

Low bone availability is one of the most common challenges, this can often be addressed by using fewer implants (less than five, as per the 6th ITI Consensus), shorter implants or tilting of the posterior implants. At the same time, it is common for patients with abundant bone availability to present with a skeletal discrepancy that influences implant placement for an ideal post operative class 1 occlusion and

a severe cross-bite occlusion. In addition, different systemic conditions and healing patterns present an additional set of challenges that require clinicians to carefully select implant material, surface and biomaterials, to enhance the soft and hard tissue healing process to deliver long-term success.

Fortunately implant dentistry is going through a very exciting period where new and stronger materials are available allowing the use of narrow implants and less invasive procedures, “state-of-the-art” surface treatment can significantly shorten healing time





as well as overall treatment time. New implant designs such as Straumann® BLX system provide clinicians with a tool to pursue Immediacy with confidence, supported by further development in digital workflows and innovations in 3D treatment planning and guided surgery for higher efficiency, accuracy and predictability.

This e-book details 10 clinical cases exploring challenges in immediate full-arch rehabilitation and the general recommendations from experienced clinicians.

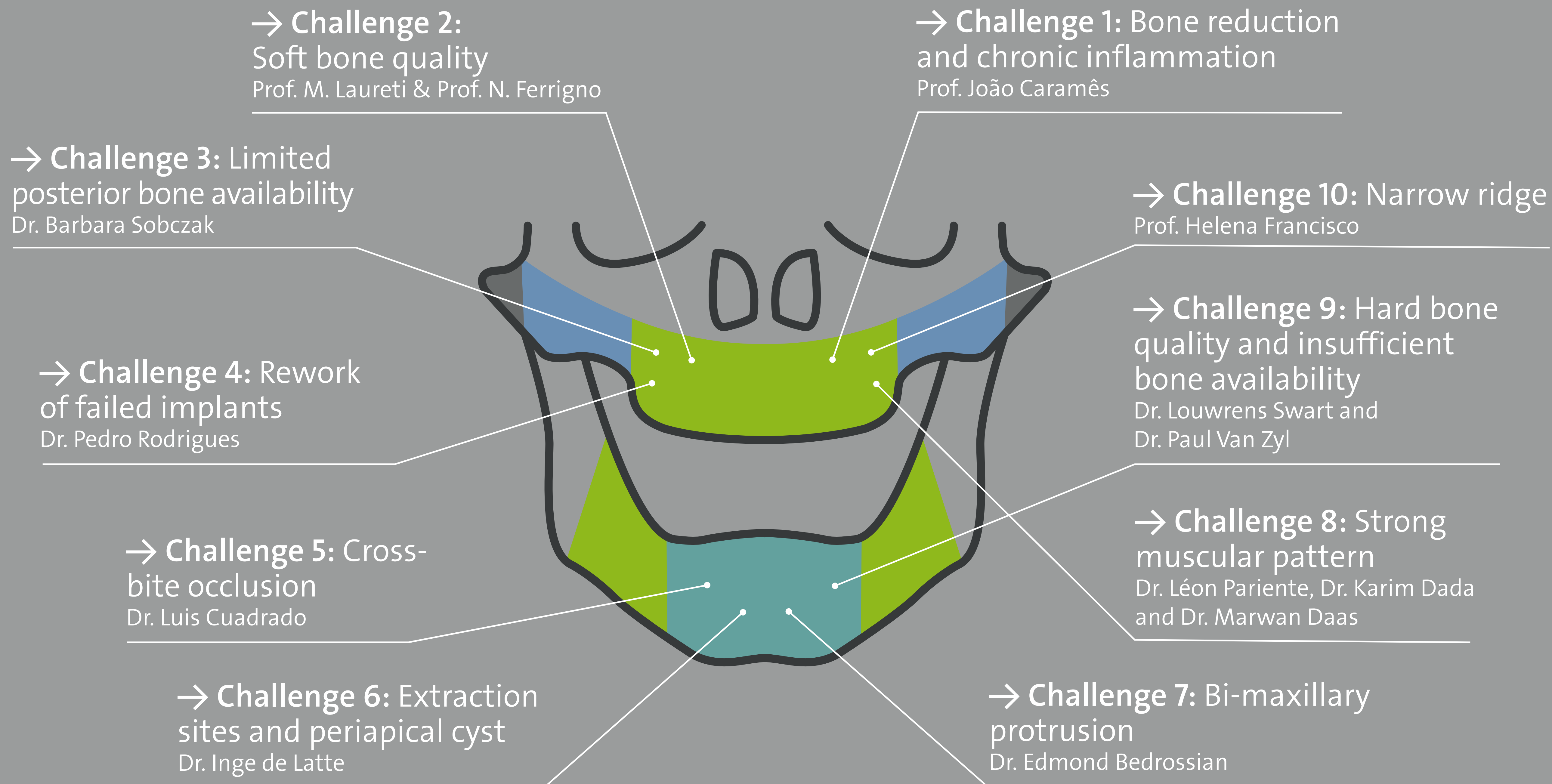
Enjoy the reading!

1 GBD 2016 Disease and Injury Incidence and Prevalence Collaborators. Global, regional, and national incidence, prevalence, and years lived with disability for 328 diseases and injuries for 195 countries, 1990-2016: a systematic analysis for the Global Burden of Disease Study 2016. Lancet. 2017;390(10100):1211-1259.

2 Millenium reports implants & Final abutments APAC 2016- add countries, EU 2015, LA 2014-add countries, NAM 2015.



# CONTENT

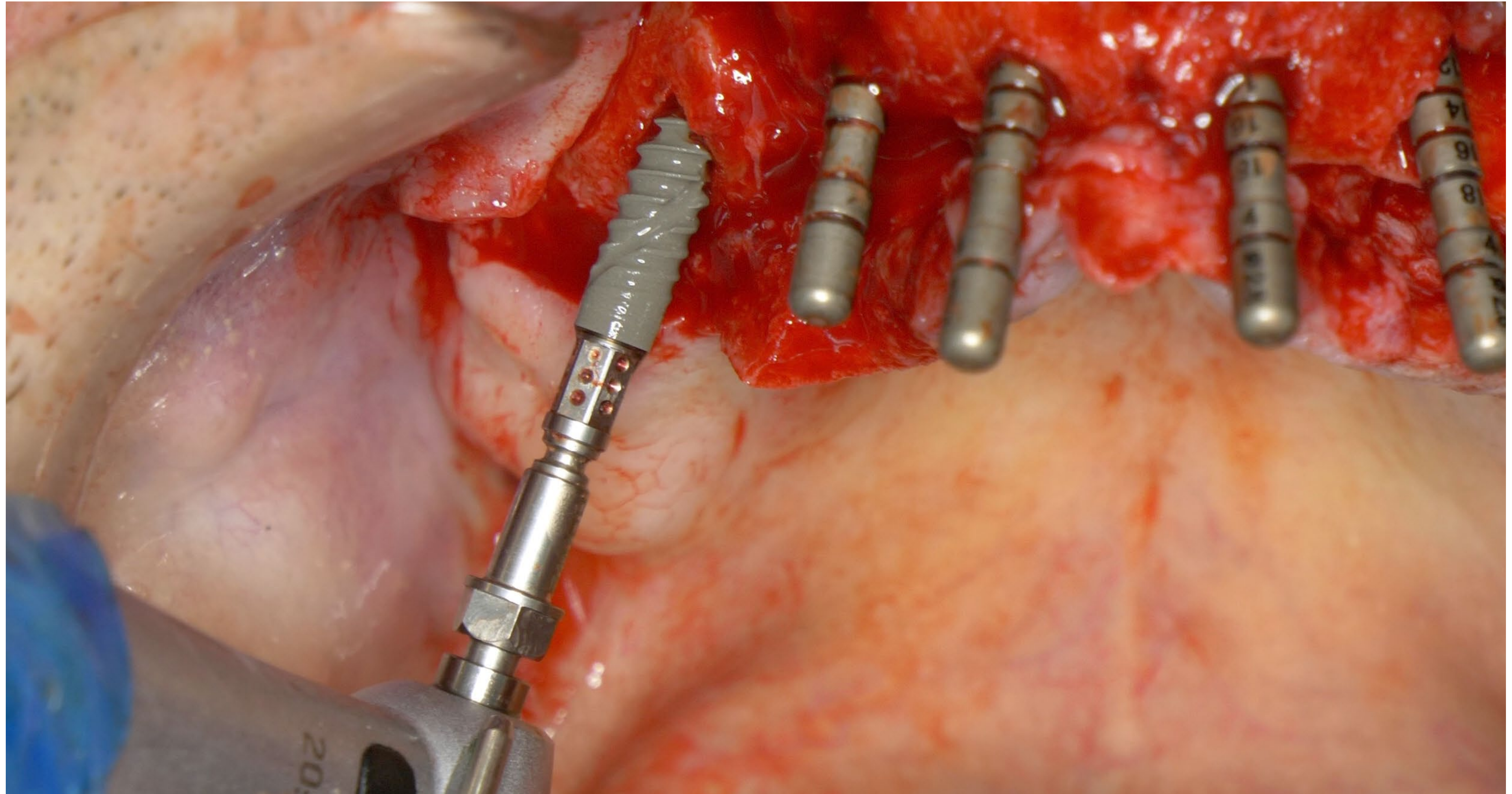


→ **Pro Arch BLX**  
Overview



# Challenge 1: Bone reduction and chronic inflammation

General recommendations and clinical case from Prof. João Caramês





# Challenge 1: Bone reduction and chronic inflammation

## General recommendations



### General recommendations from Prof. João Caramês

#### Bone reduction:

- Ensure that the bone plane is parallel to the occlusal plane and transition line won't be visible in forced smile
- Make the edges of the bone smooth and rounded to avoid soft tissue fenestration
- Retain the bone chips for bone grafting, especially for the lip support and to fill and repair bone defects

#### Chronic inflammation:

- Perform curettage and irrigation of the extraction socket to remove any remnant tooth fragments and diseased tissue
- Remove the inflamed soft tissue from the bone after raising a flap

Professor João Caramês is a Full Professor and Chairman of the Oral Surgery and Implant Department and President of the Scientific Committee at Lisbon University Faculty of Dental Medicine (FMDUL). He is Director and Founder of the Implantology Institute in Lisbon and currently a President state elect of the General Assembly of the Portuguese Dental Association (OMD).

Professor Caramês is Principal Investigator on Implantology research group at the Oral and Biomedical Research Unit of the Lisbon University Faculty of Dental Medicine (UICOB/FMDUL).

He has published and lectured extensively on a national and international level. Today his private practice is focused on Oral Surgery and Implant Dentistry.



**Prof. João Caramês**  
DMD, PhD  
Lisbon, Portugal

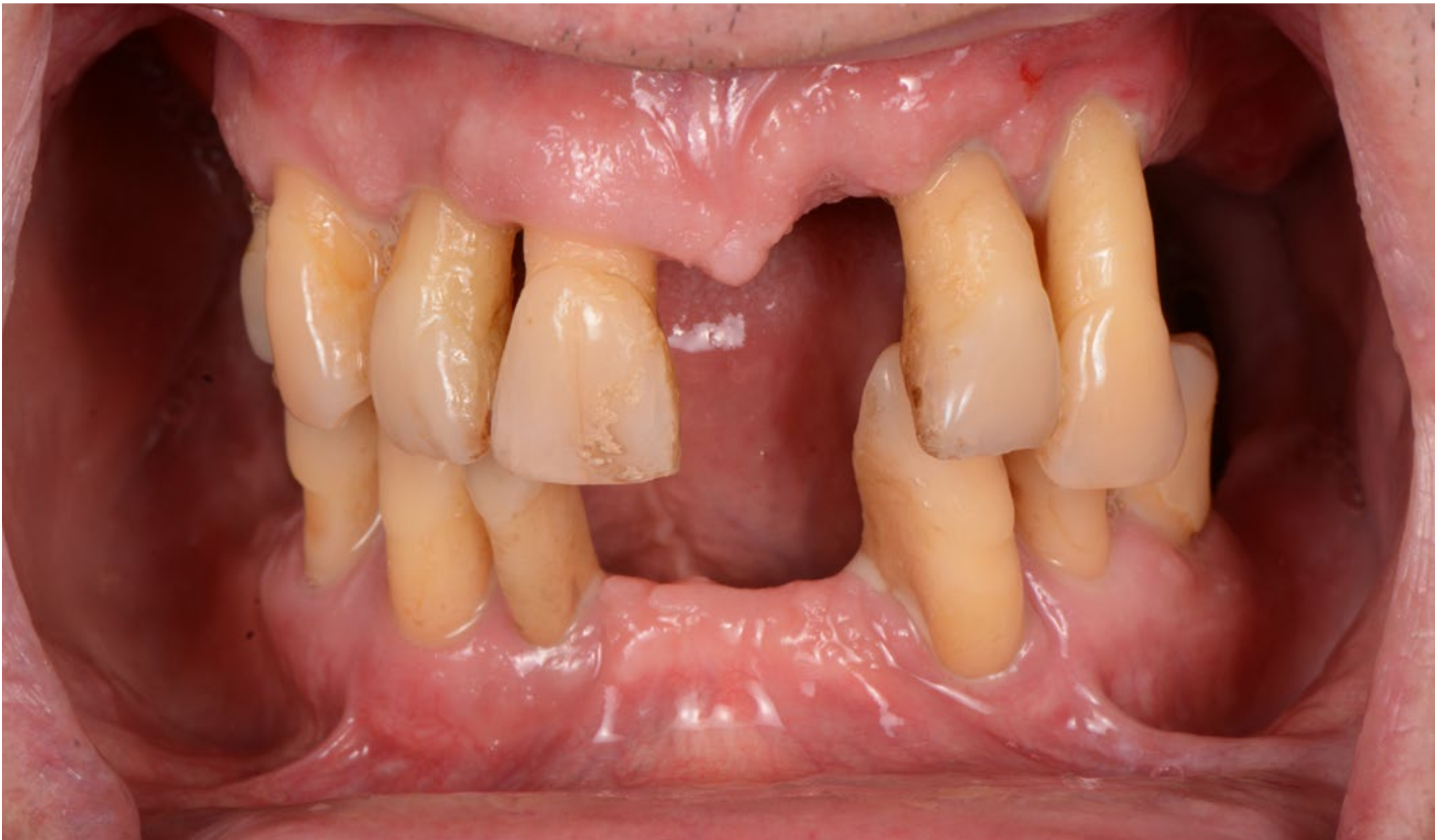

# Challenge 1: Bone reduction and chronic inflammation

Clinical case



## Initial situation



## Patient information

Age	60
Jaw	Mandible maxilla
Health status	Good
Height of smile line	Low
Bone type	Soft
Infections at implantation site	Yes
Bone anatomy defects	Yes
Risks	Yes

## Additional difficulties

Moderate resorption in the mandible and maxilla
Generalized severe chronic periodontitis

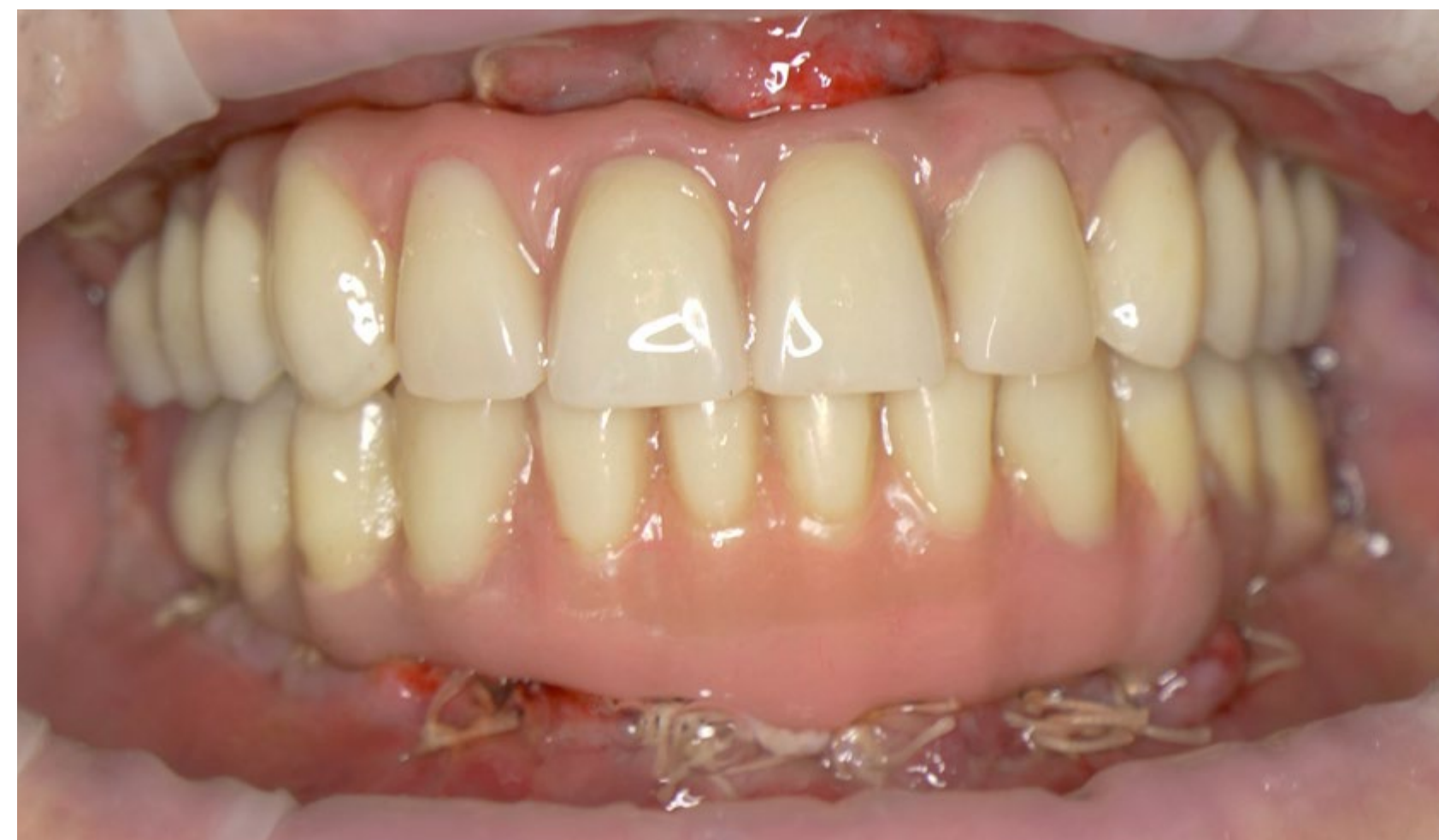

# Challenge 1: Bone reduction and chronic inflammation

Clinical case



## Provisional prosthesis



## Treatment

- Fixed immediate rehabilitation on four implants in the mandible and six implants in the maxilla
- Tilting of the posterior implants due to limited bone availability in the maxilla

**Temporary restoration:** acrylic metal reinforced provisional prosthesis

**Planned final restoration:** zirconia ceramic bridge

## Materials used



Straumann® BLX Ø 3.75 mm  
RB SLActive® 12 mm Roxolid®  
(maxilla)  
Straumann® BLX Ø 4.5 mm  
RB SLActive® 14 mm Roxolid®  
(mandible)



Straumann® XenoGraft  
0.5 mm



RB/WB Screw-retained abut-  
ments, straight, angle 0°,  
Ø 4.6 mm, GH 3.5 mm  
RB/WB Screw-retained abut-  
ments, straight, angle 17°,  
Ø 4.6 mm, GH 3.5 mm



Straumann® Membrane Flex



---

# Challenge 1: Bone reduction and chronic inflammation

Clinical case

---



## My experience



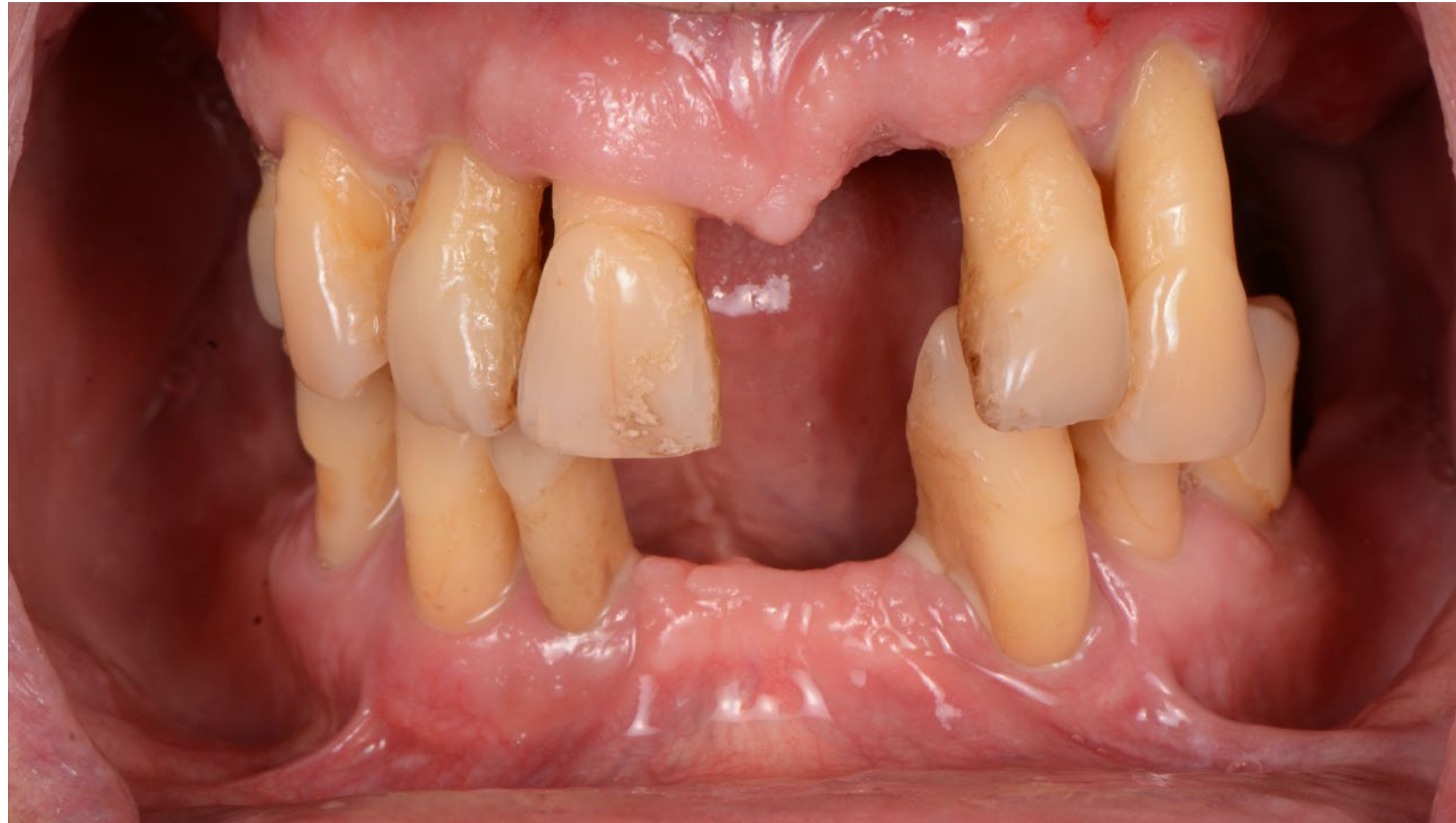**Prof. João Caramês**  
DMD, PhD  
Lisbon, Portugal

*“Straumann® BLX is a good additional tool for the full-arch rehabilitation, especially in the soft bone and extraction sockets, it delivers high primary stability.”*

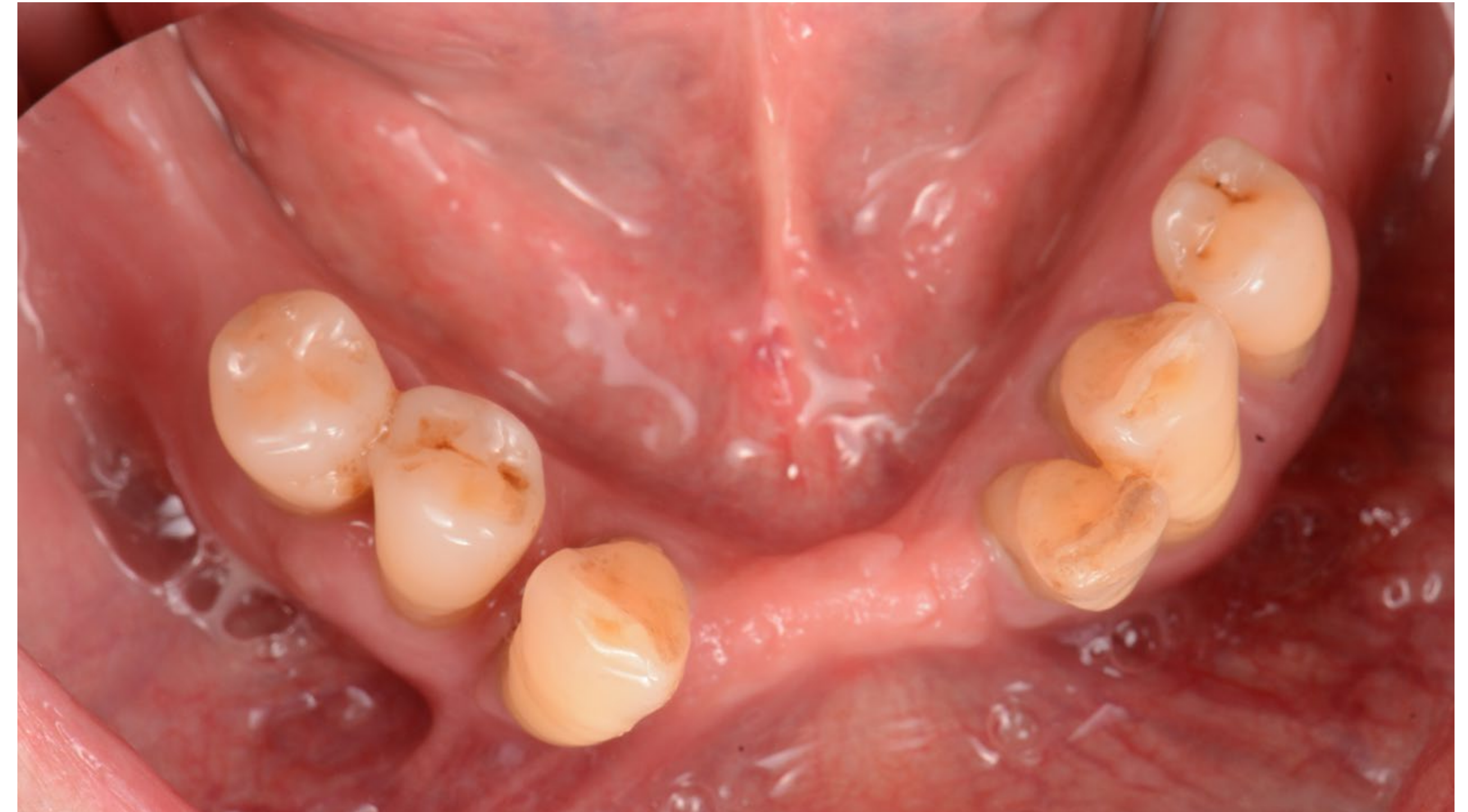

# Challenge 1: Bone reduction and chronic inflammation

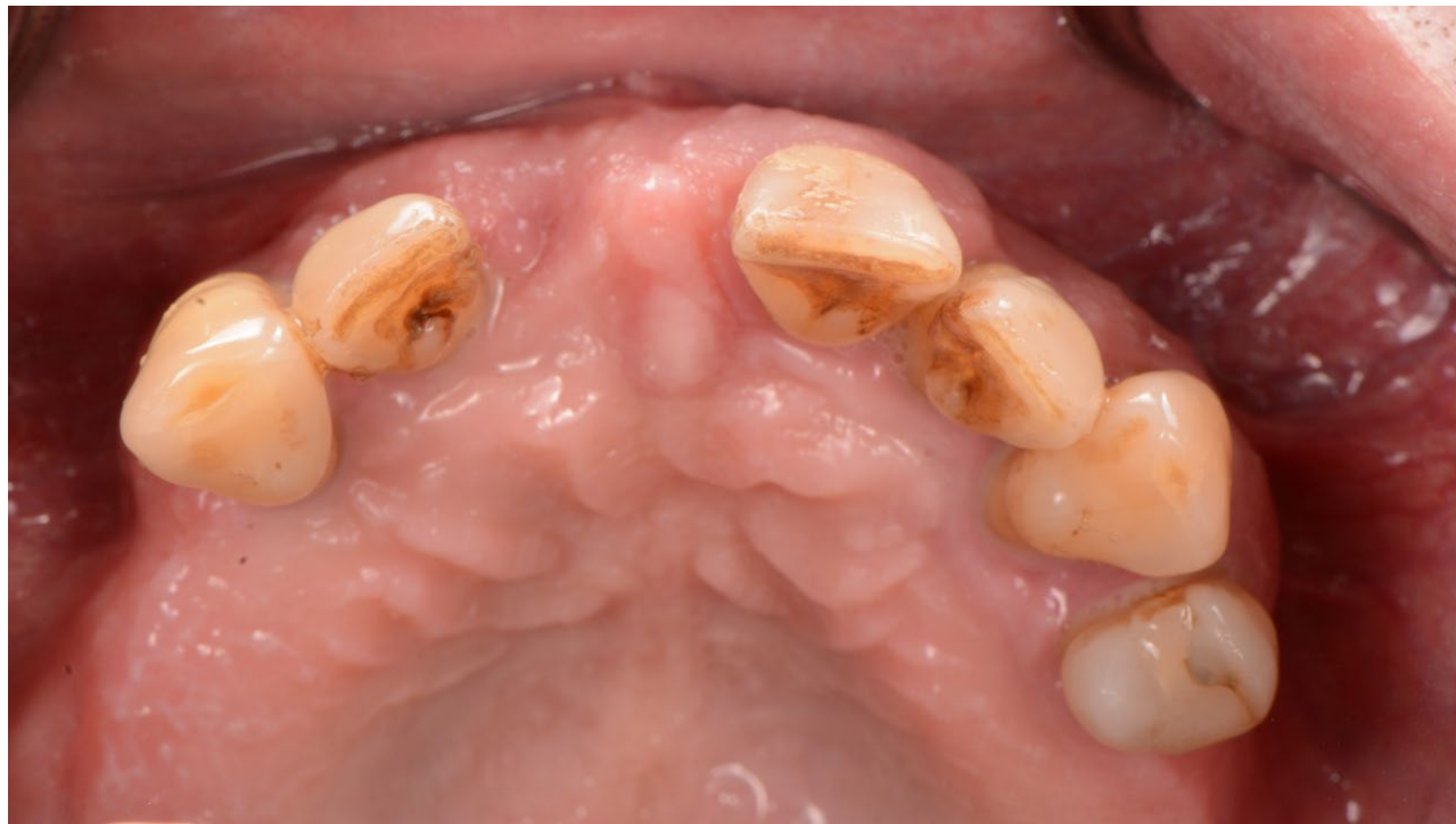Clinical case



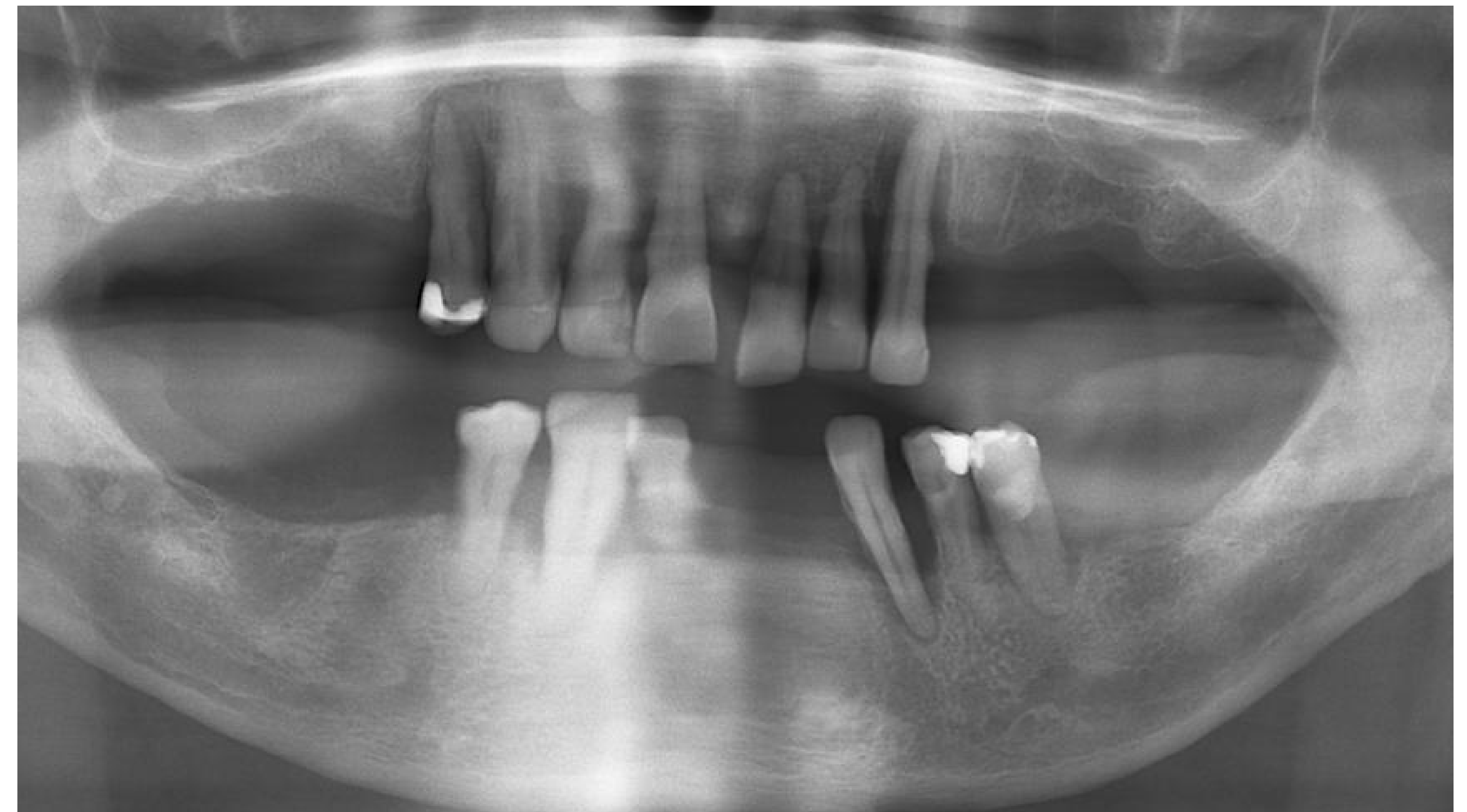
Initial clinical situation



Occlusal view of the mandible



Occlusal view of the maxilla

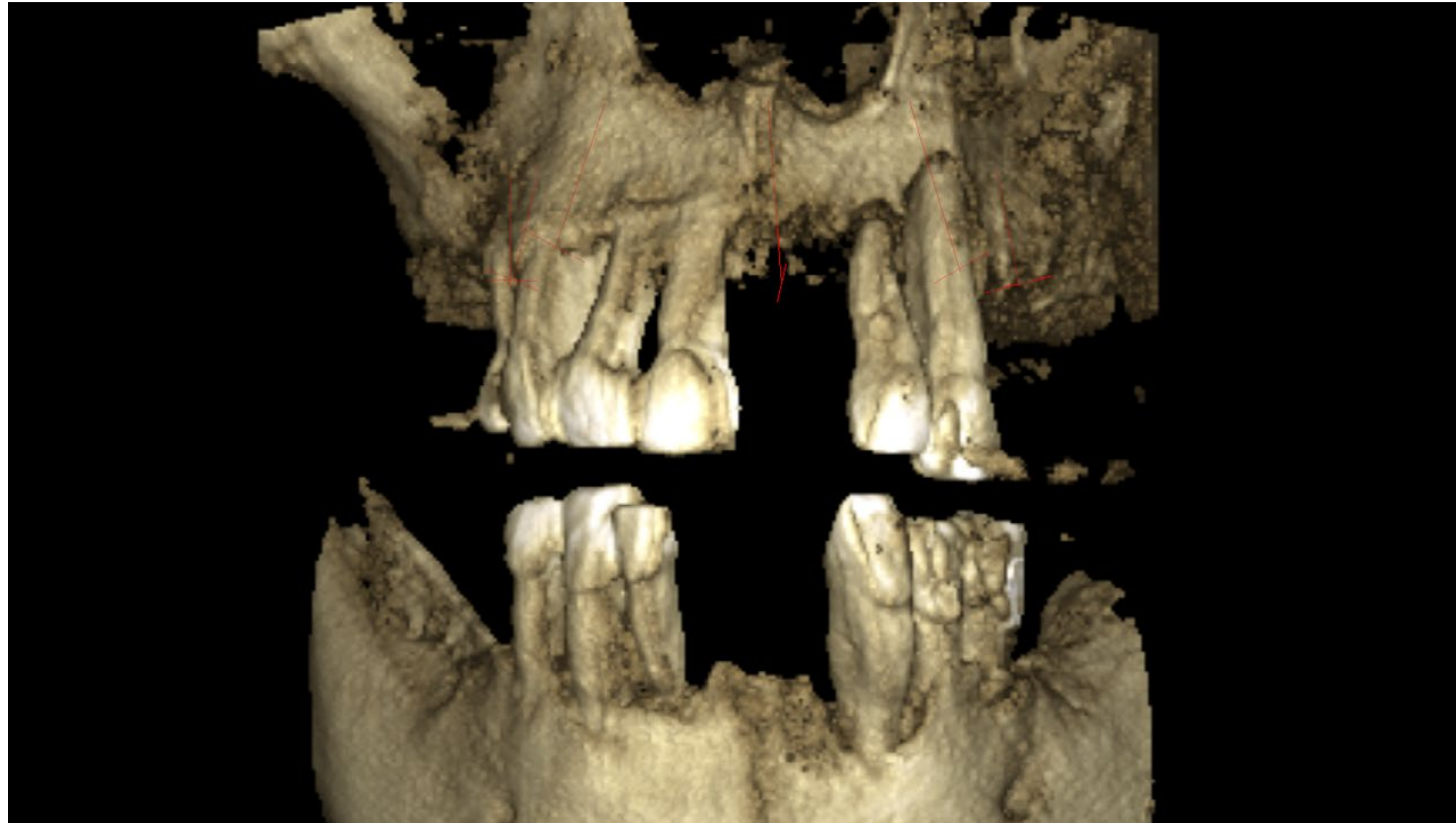


Preoperative panoramic radiograph

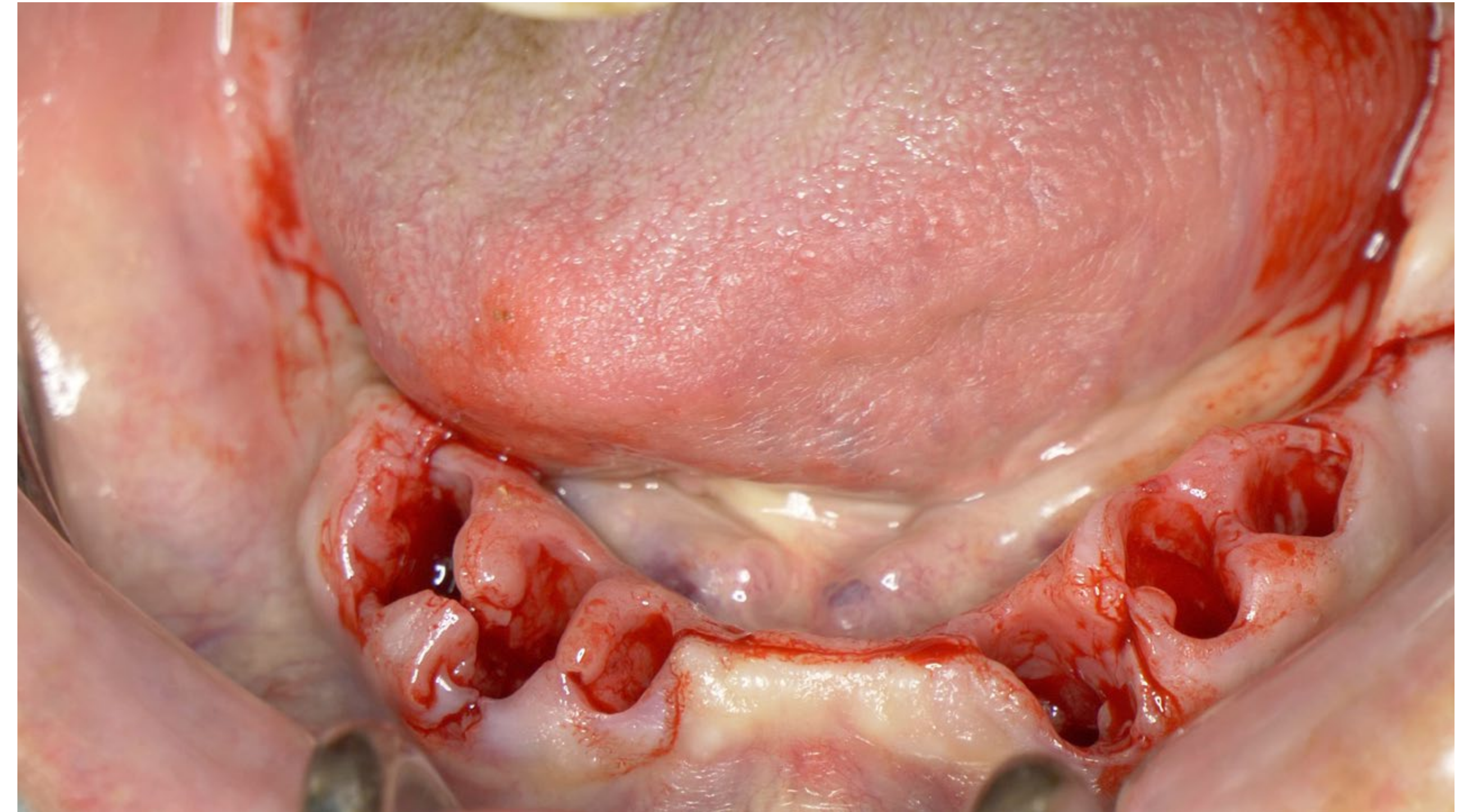

# Challenge 1: Bone reduction and chronic inflammation

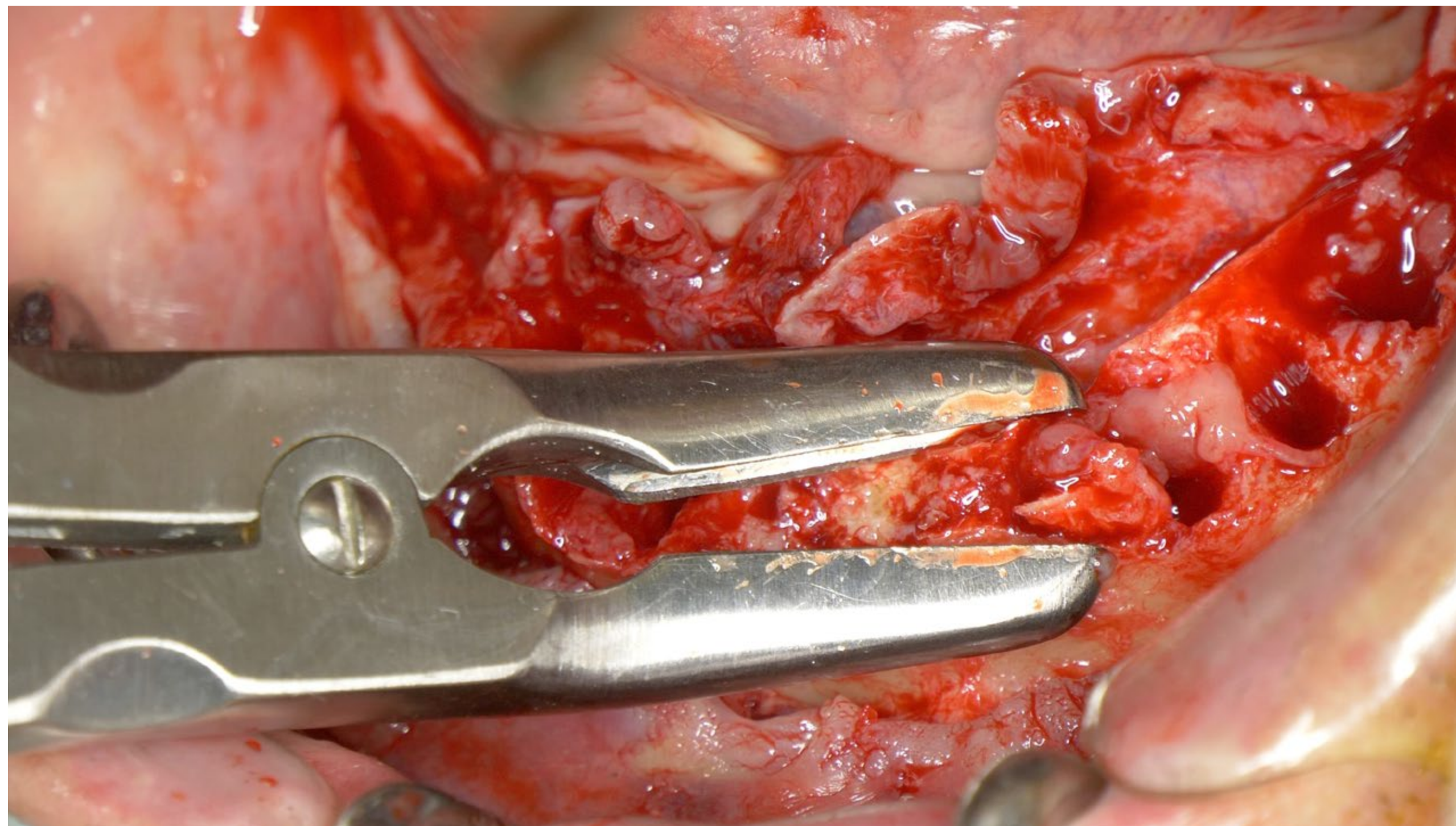
Clinical case



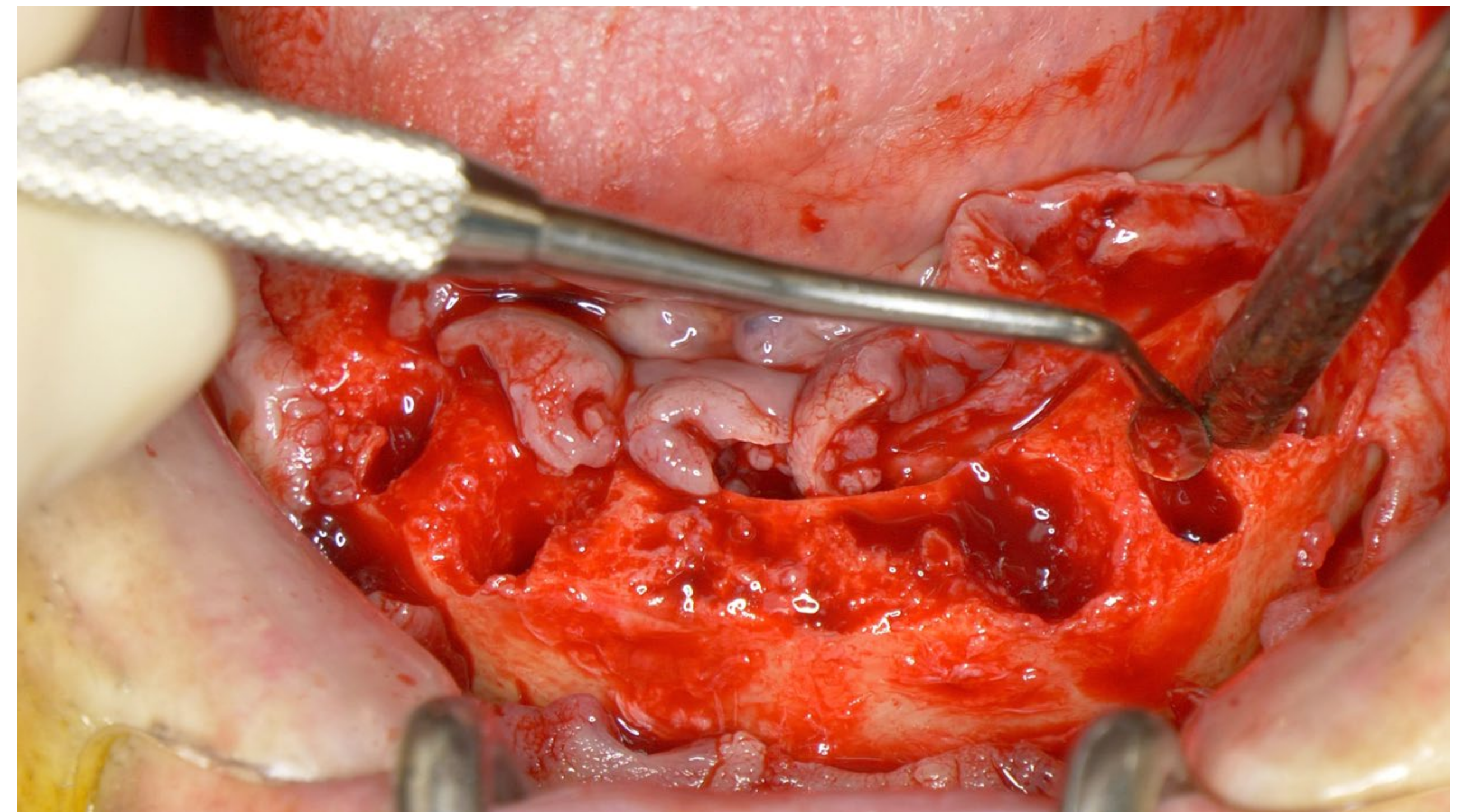
CB CT scan



Occlusal view after the extraction of hopeless teeth



Bone reduction

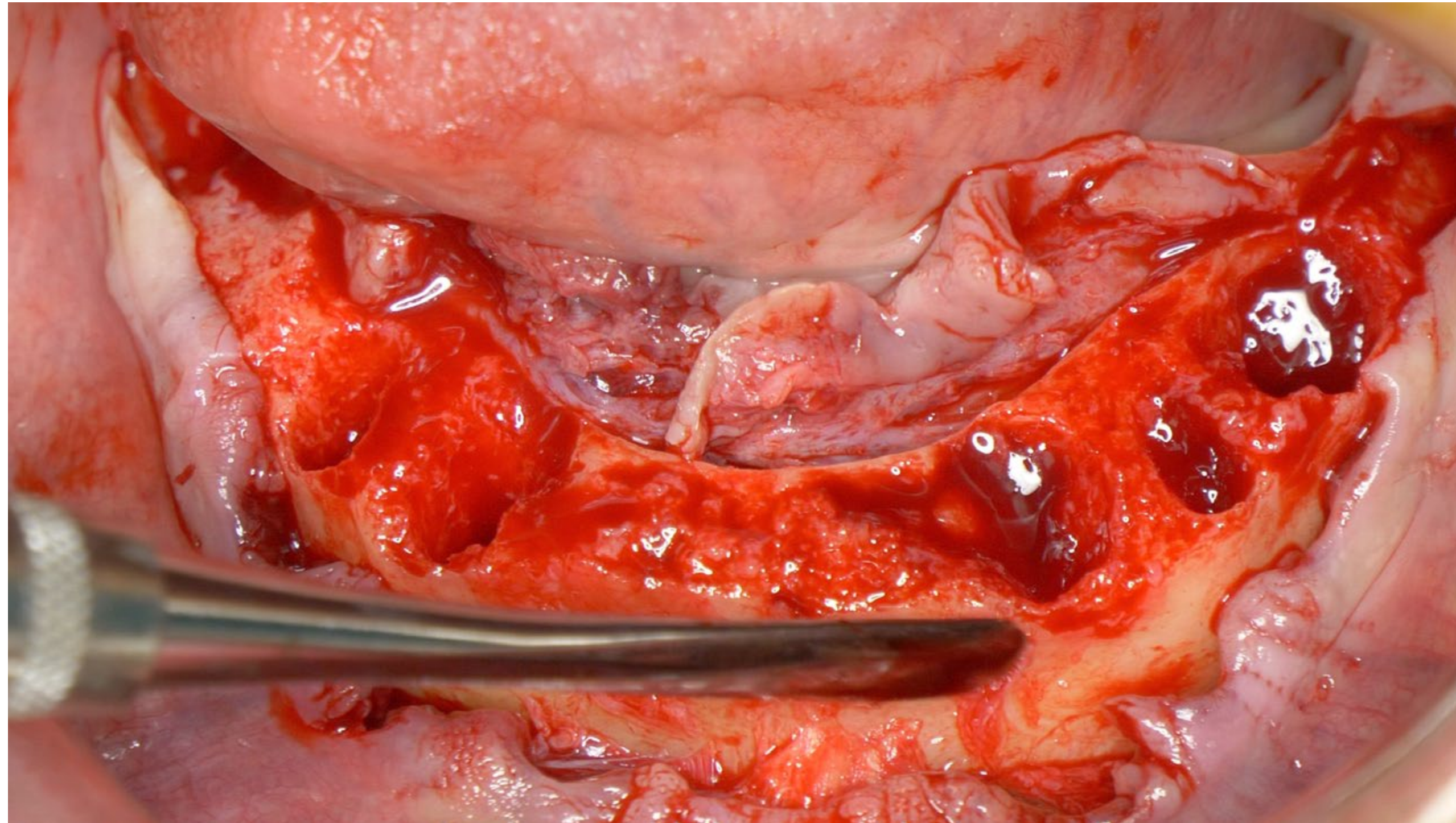


Curettage and irrigation of extraction sockets to remove any remnant tooth fragments and diseased tissue

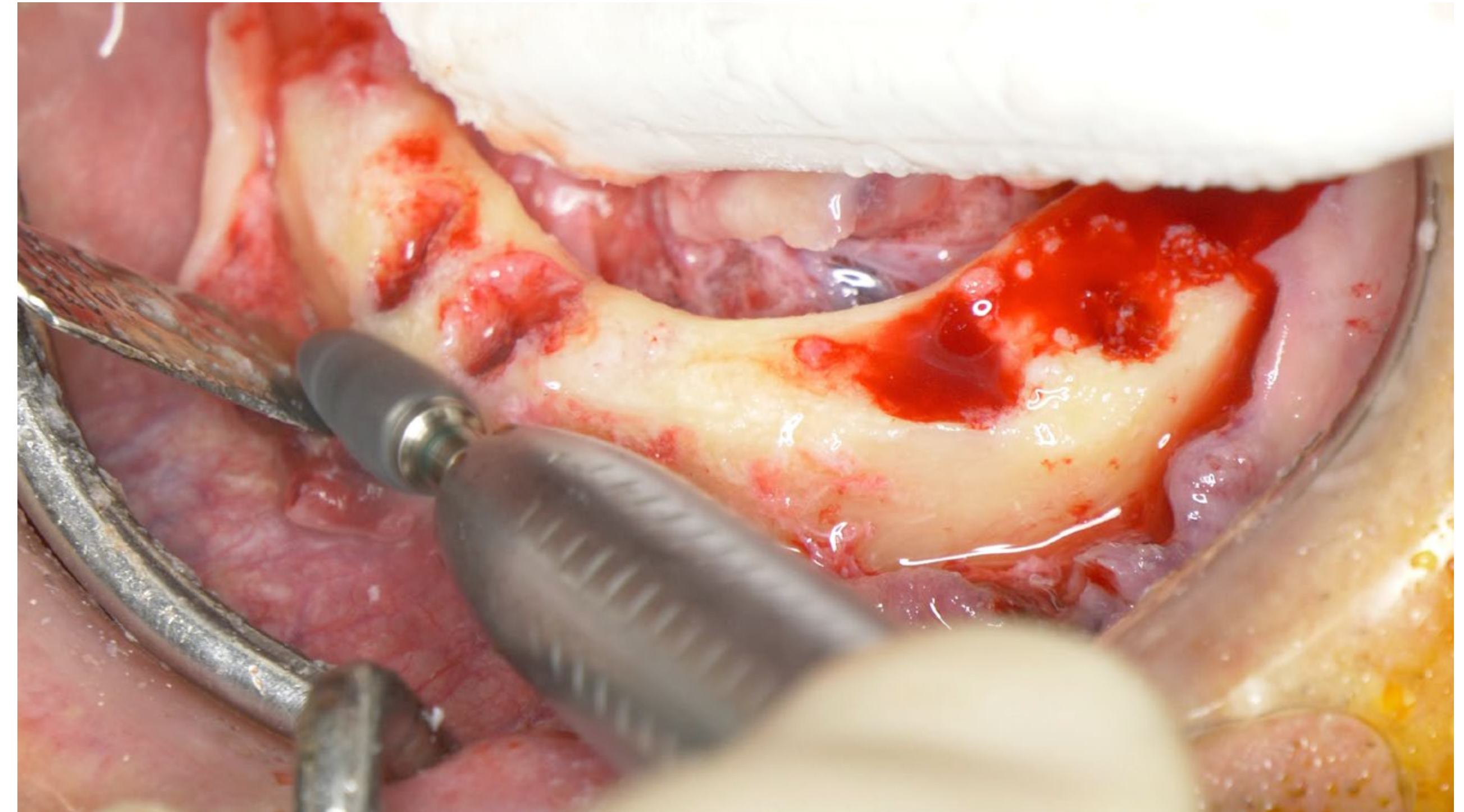


# Challenge 1: Bone reduction and chronic inflammation

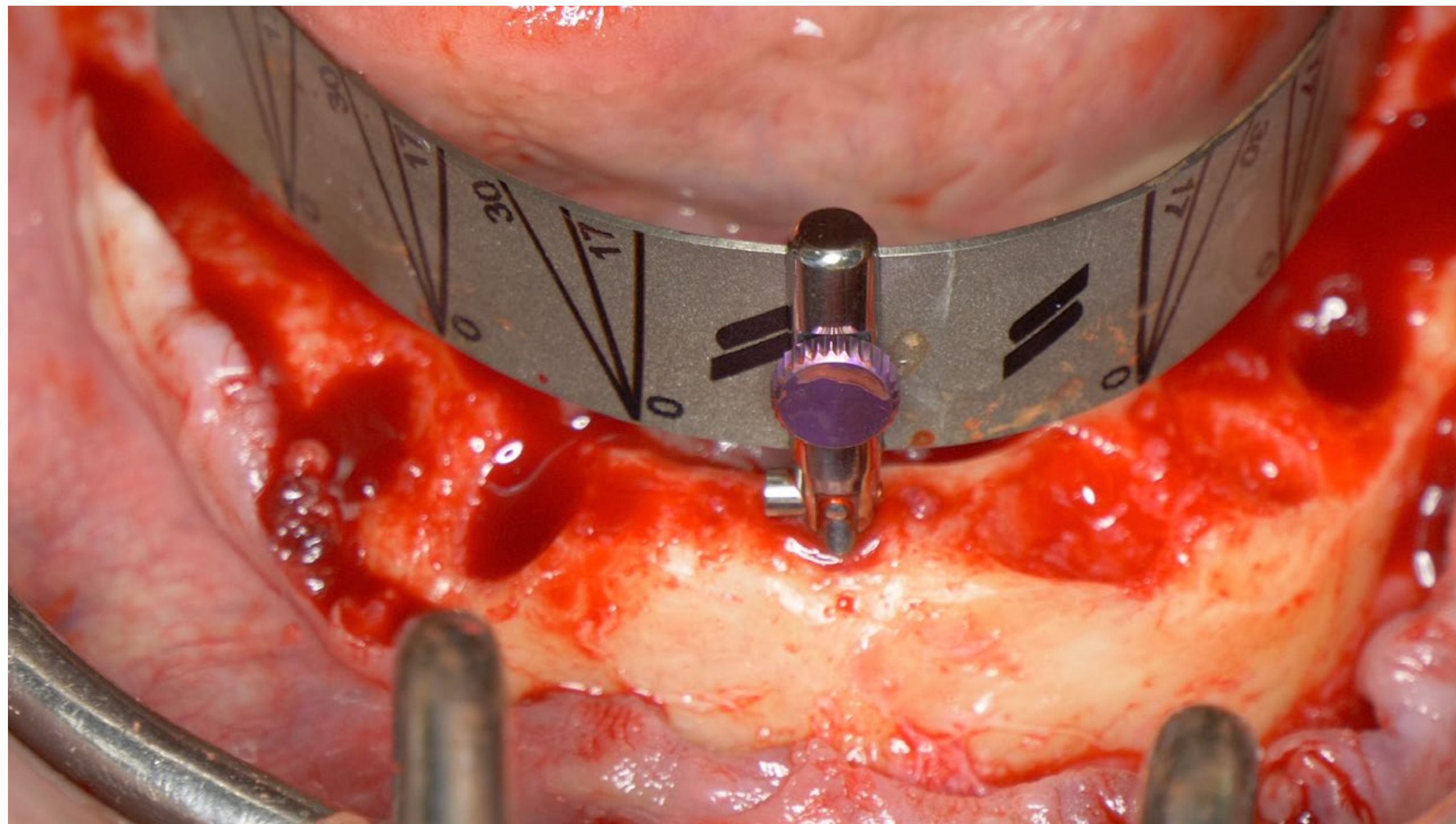
Clinical case



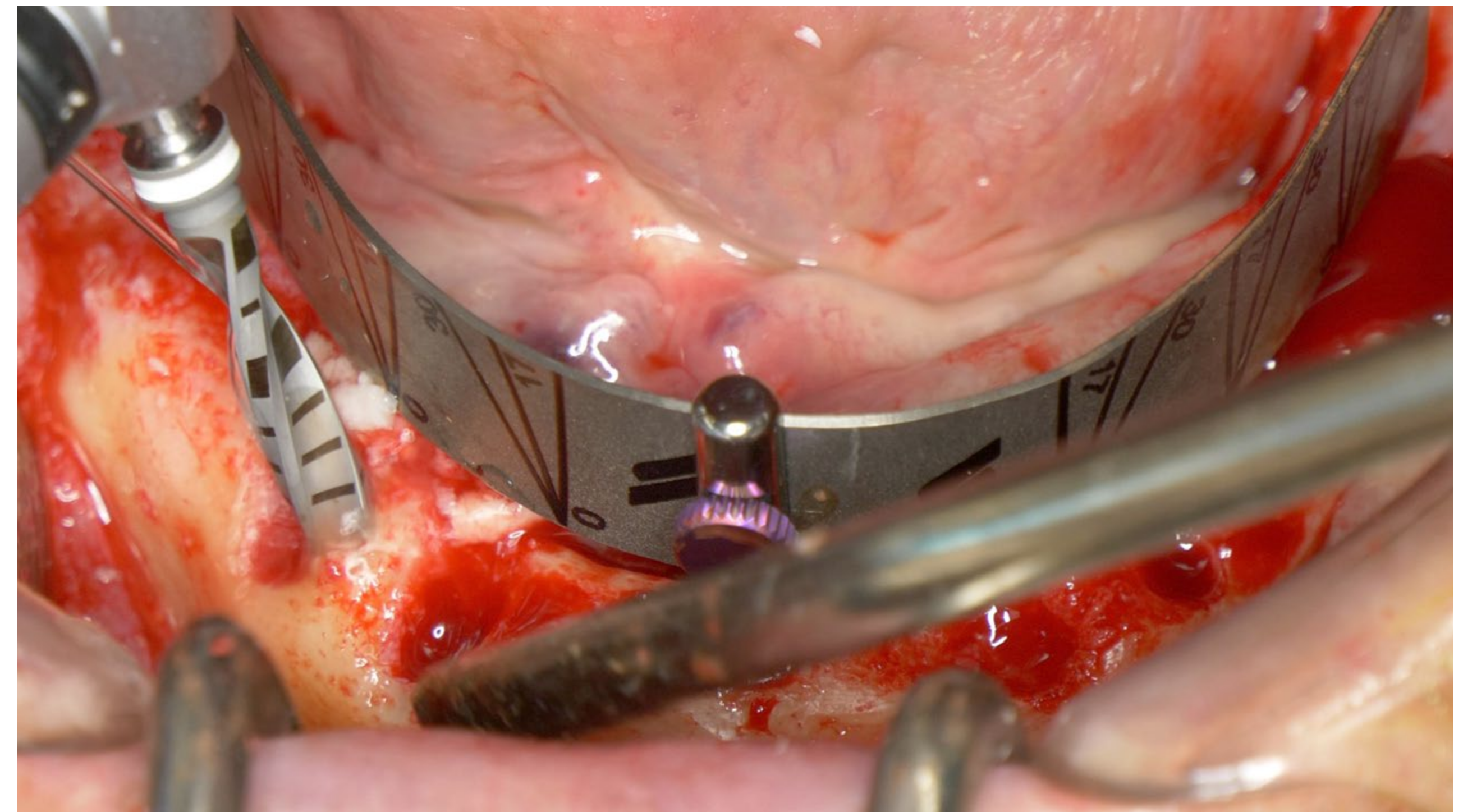
Removal of inflamed soft tissue from the bone



Bone reduction to make the edges of the bone smooth and rounded



Straumann® Pro Arch Guide in place

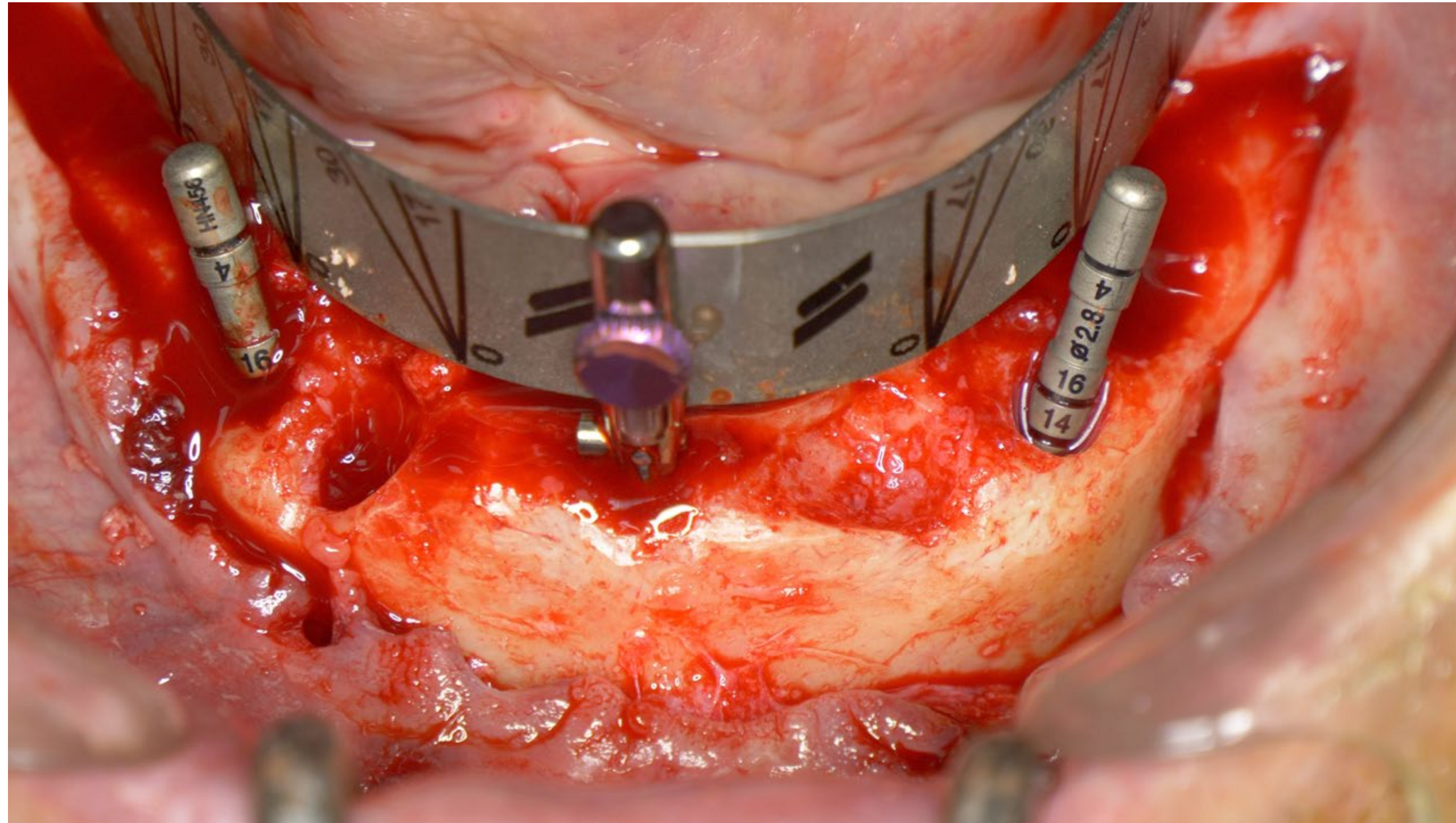


Posterior implants site preparation  
Angulation of the posterior implant to increase the A-P spread

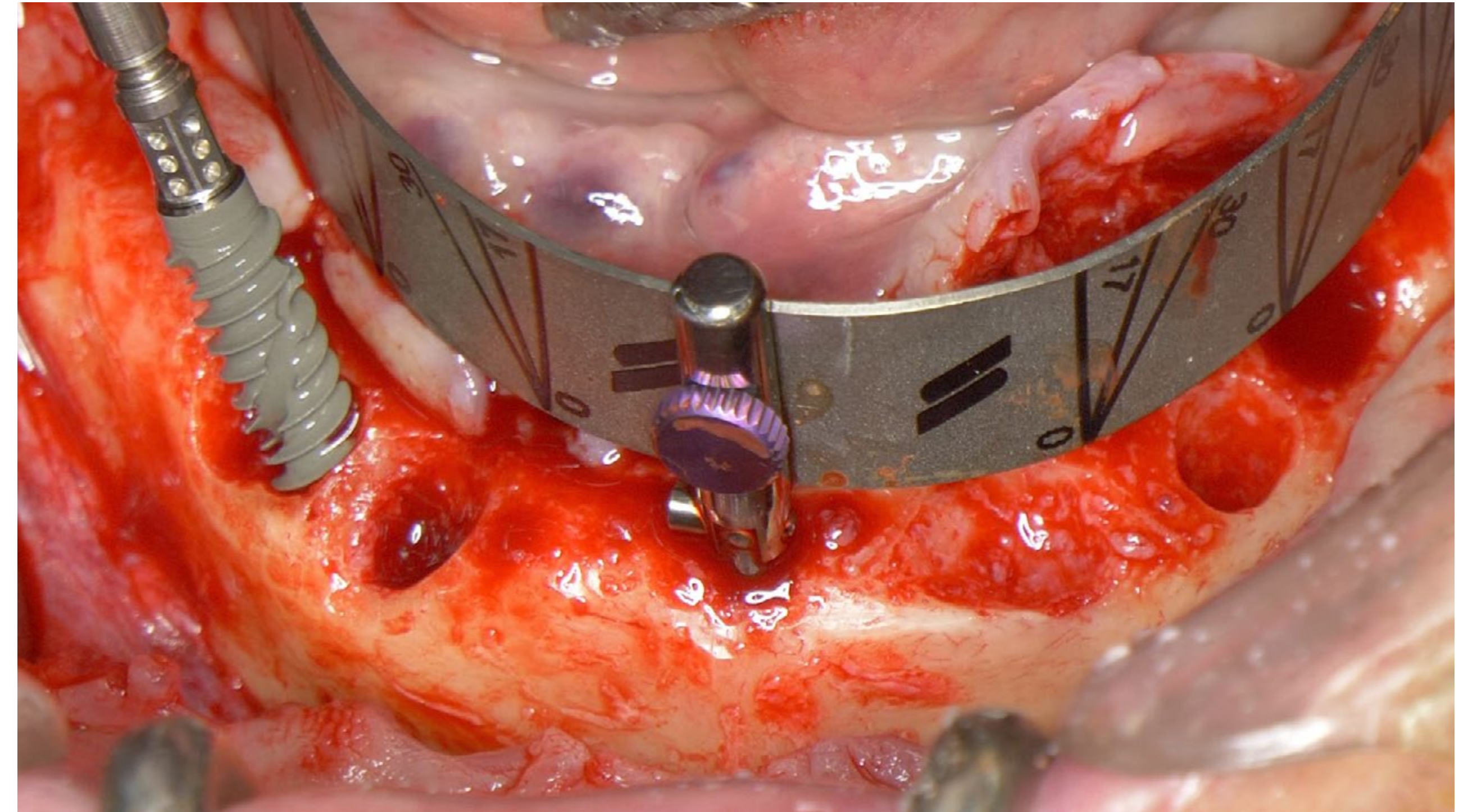


# Challenge 1: Bone reduction and chronic inflammation

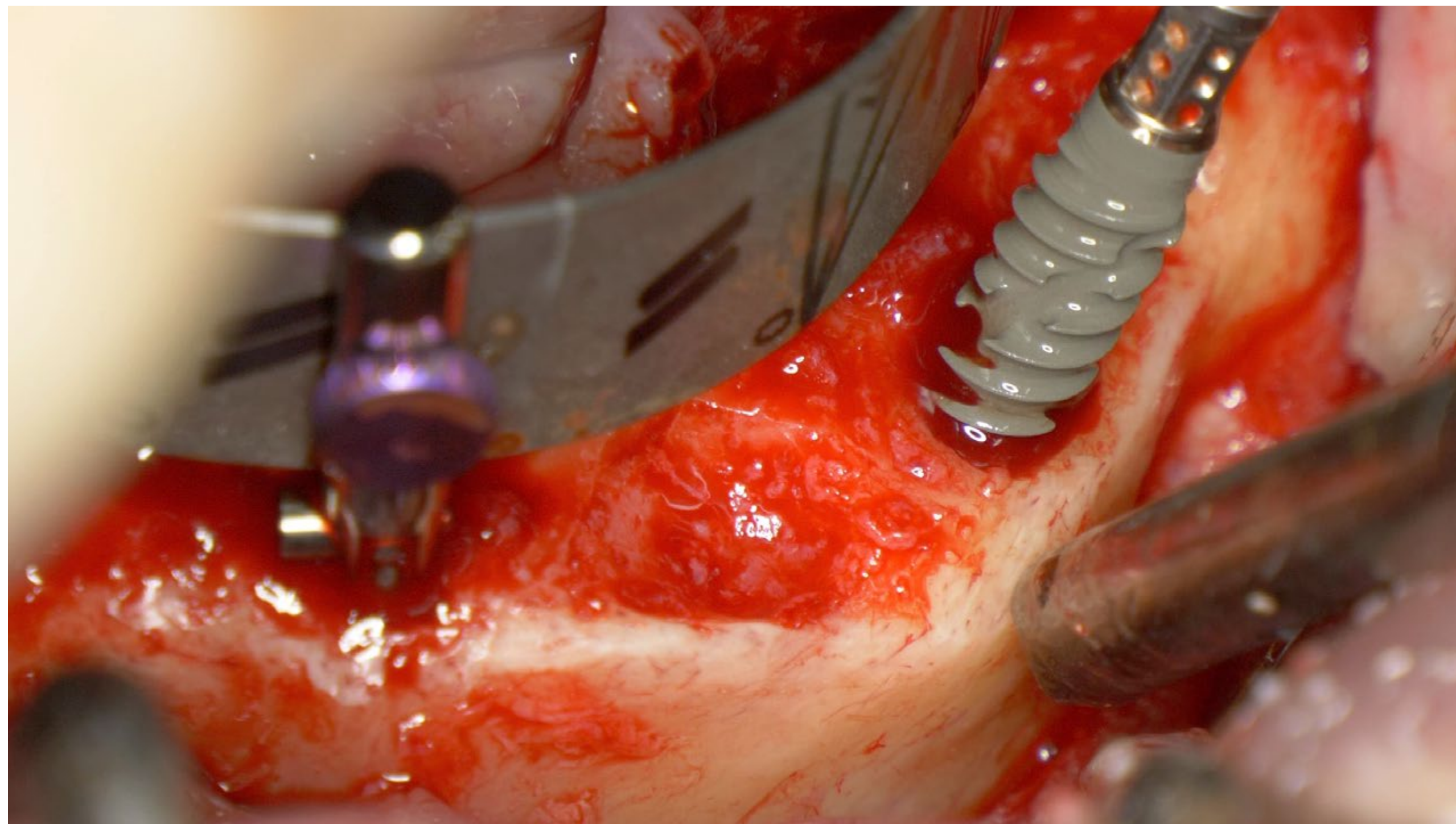
Clinical case



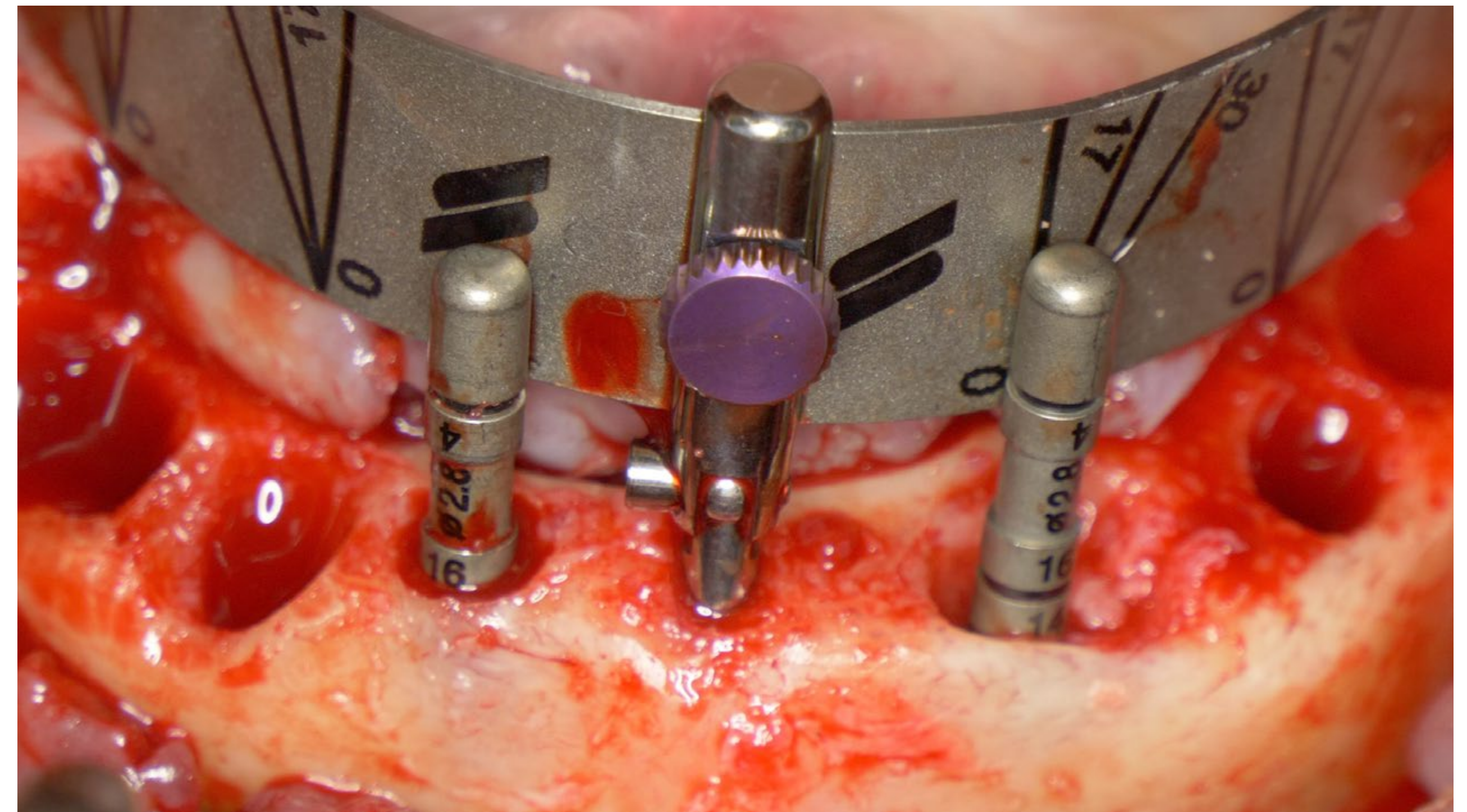
Alignment of the implant sites



Placement of the Straumann® BLX Ø 4.5 mm RB SLActive® 14 mm Roxolid® implant with the torque of 35 Ncm



Placement of the Straumann® BLX Ø 4.5 mm RB SLActive® 14 mm Roxolid® implant with the torque of 35 Ncm

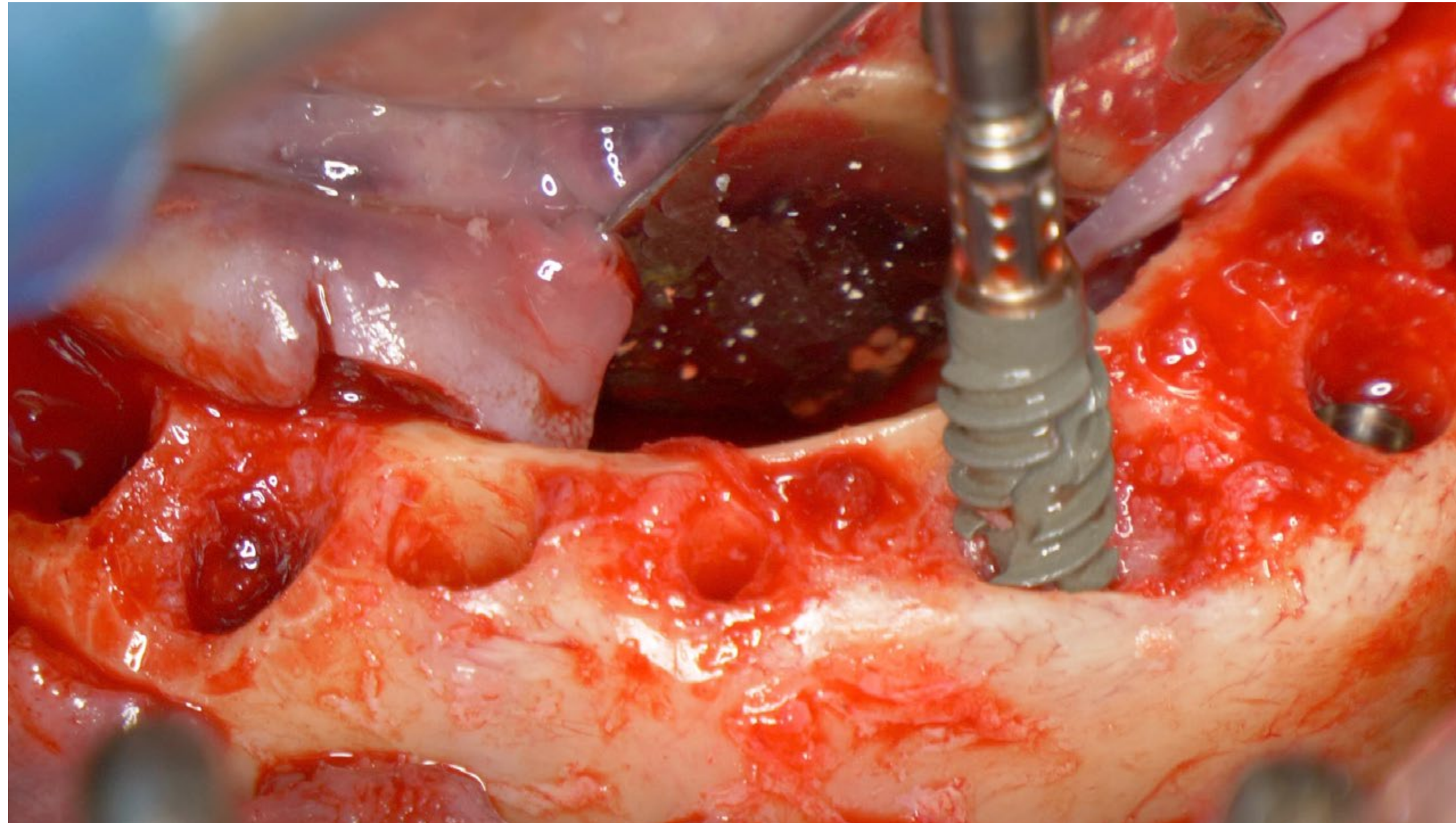


Alignment of the implant sites

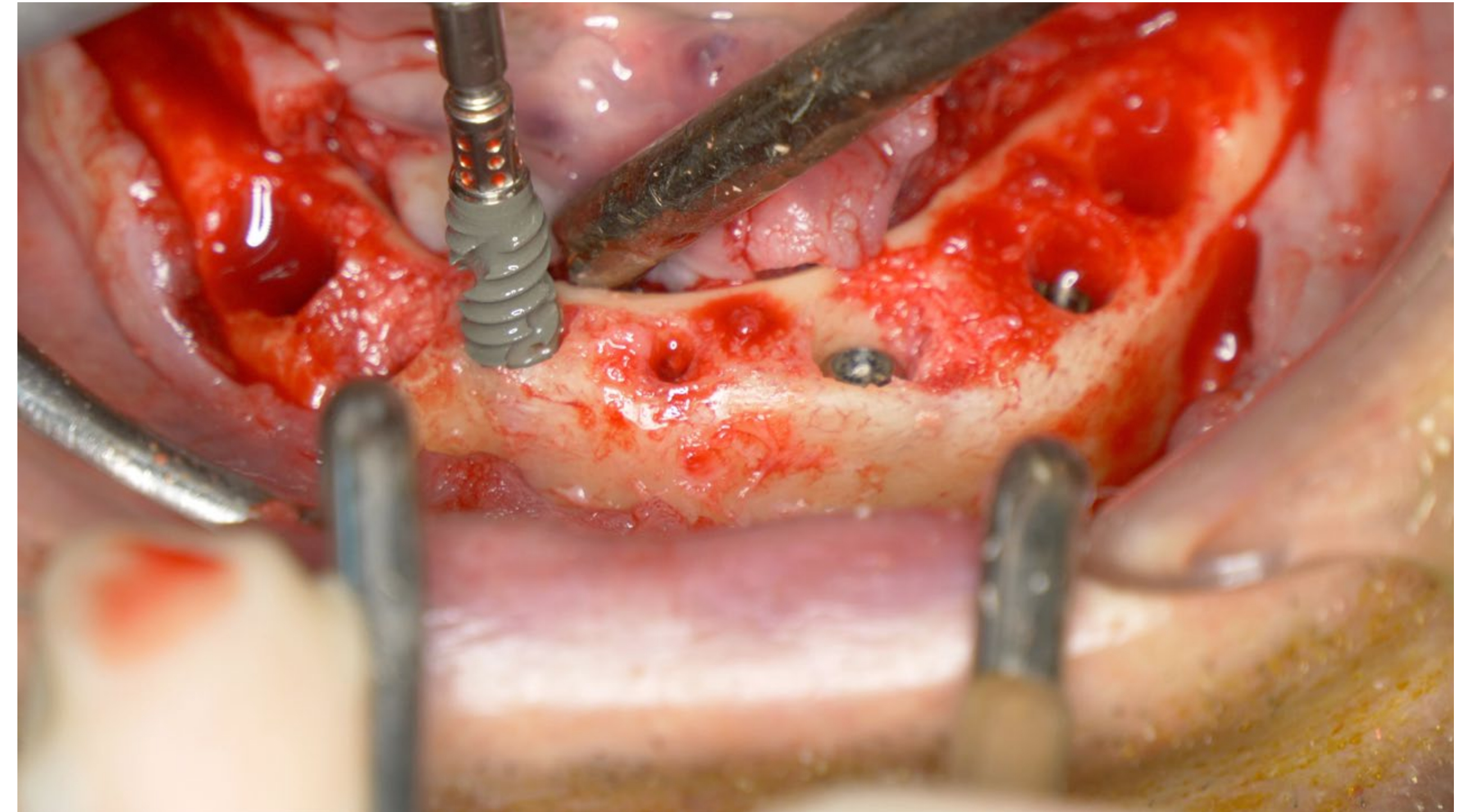


# Challenge 1: Bone reduction and chronic inflammation

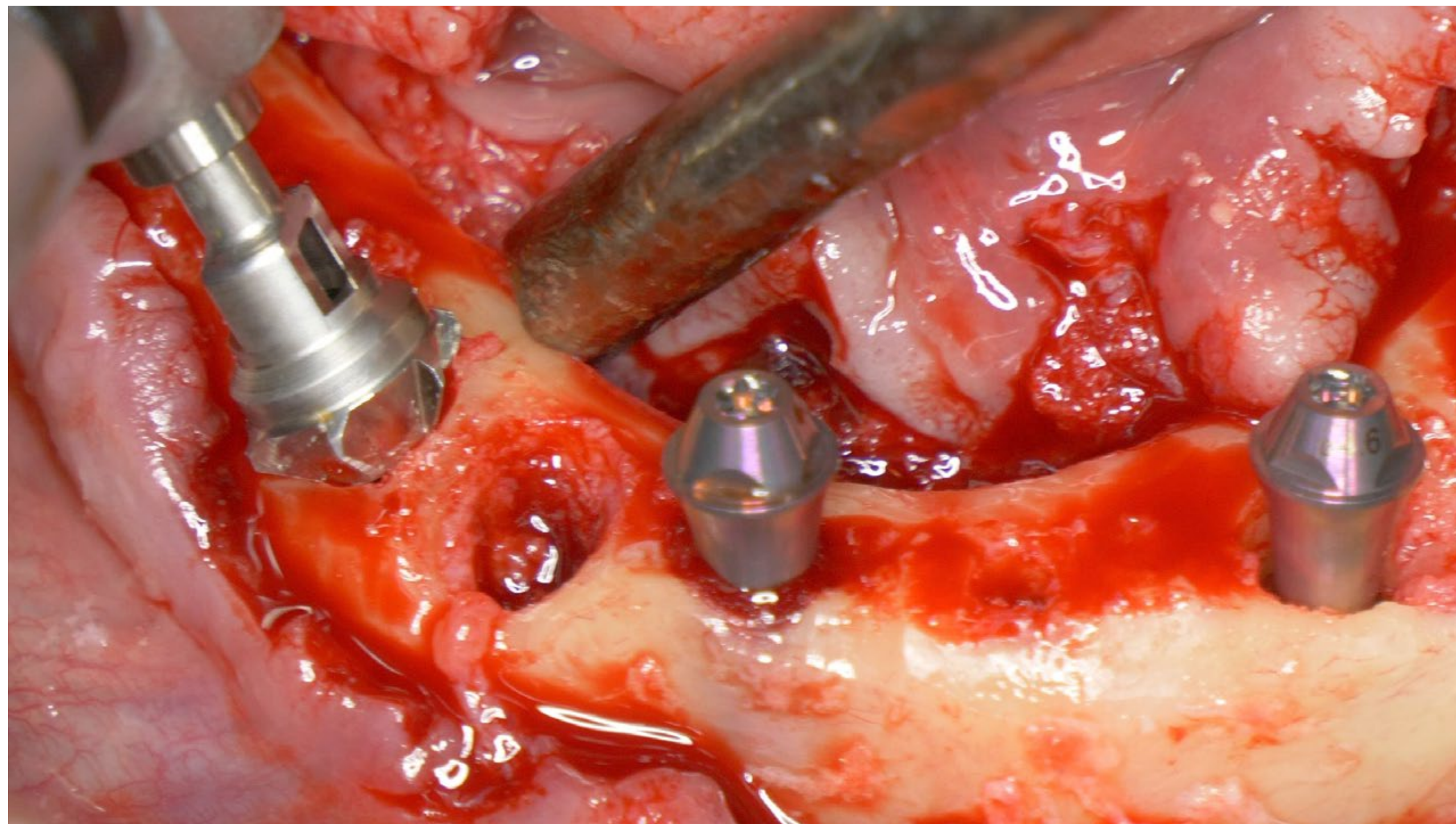
Clinical case



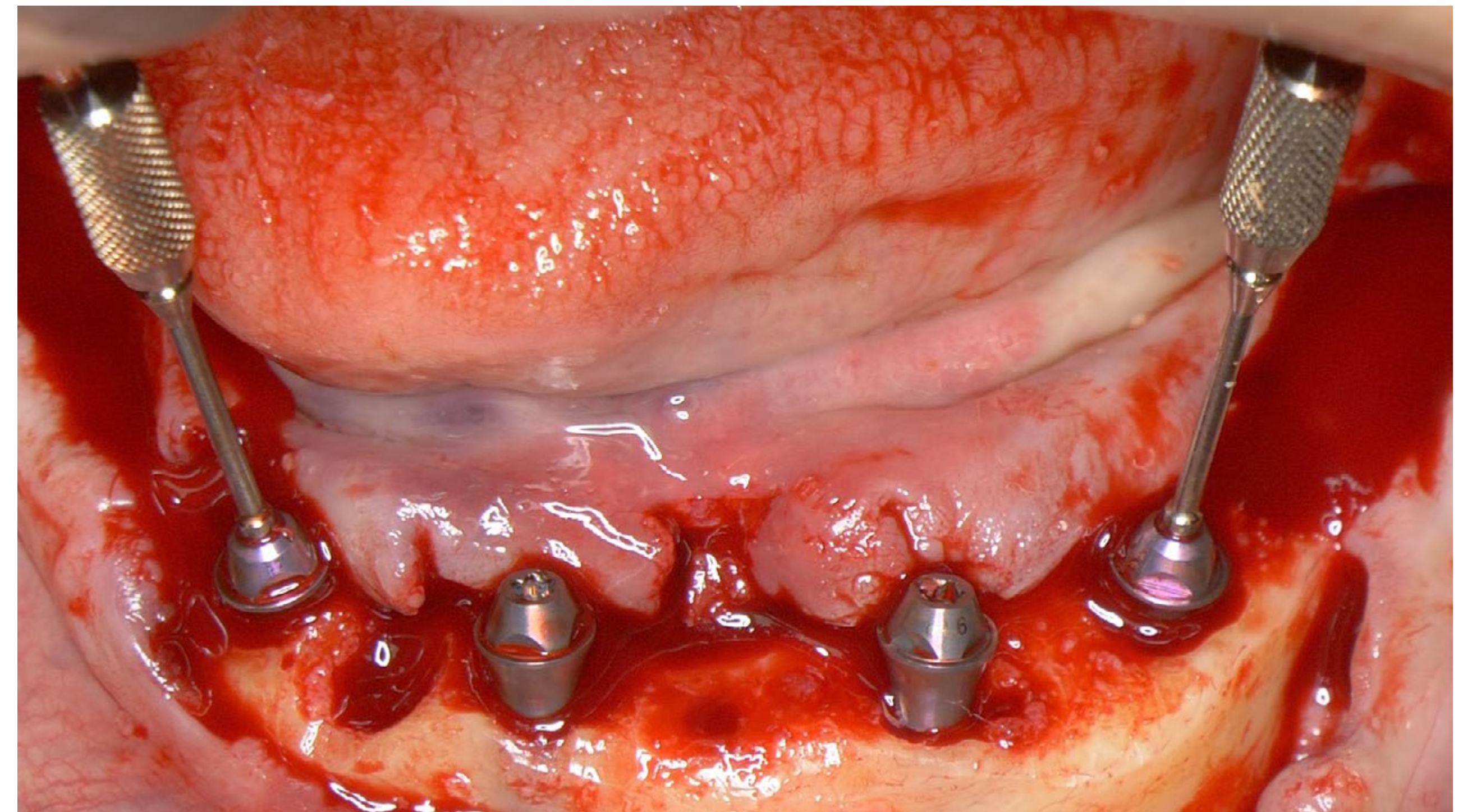
Placement of the Straumann® BLX Ø 4.5 mm RB SLActive® 14 mm Roxolid® implant with the torque of 35 Ncm



Placement of the Straumann® BLX Ø 4.5 mm RB SLActive® 14 mm Roxolid® implant with the torque of 35 Ncm



Preparation of the bone coronally with Straumann® Bone Level Bone Profiler

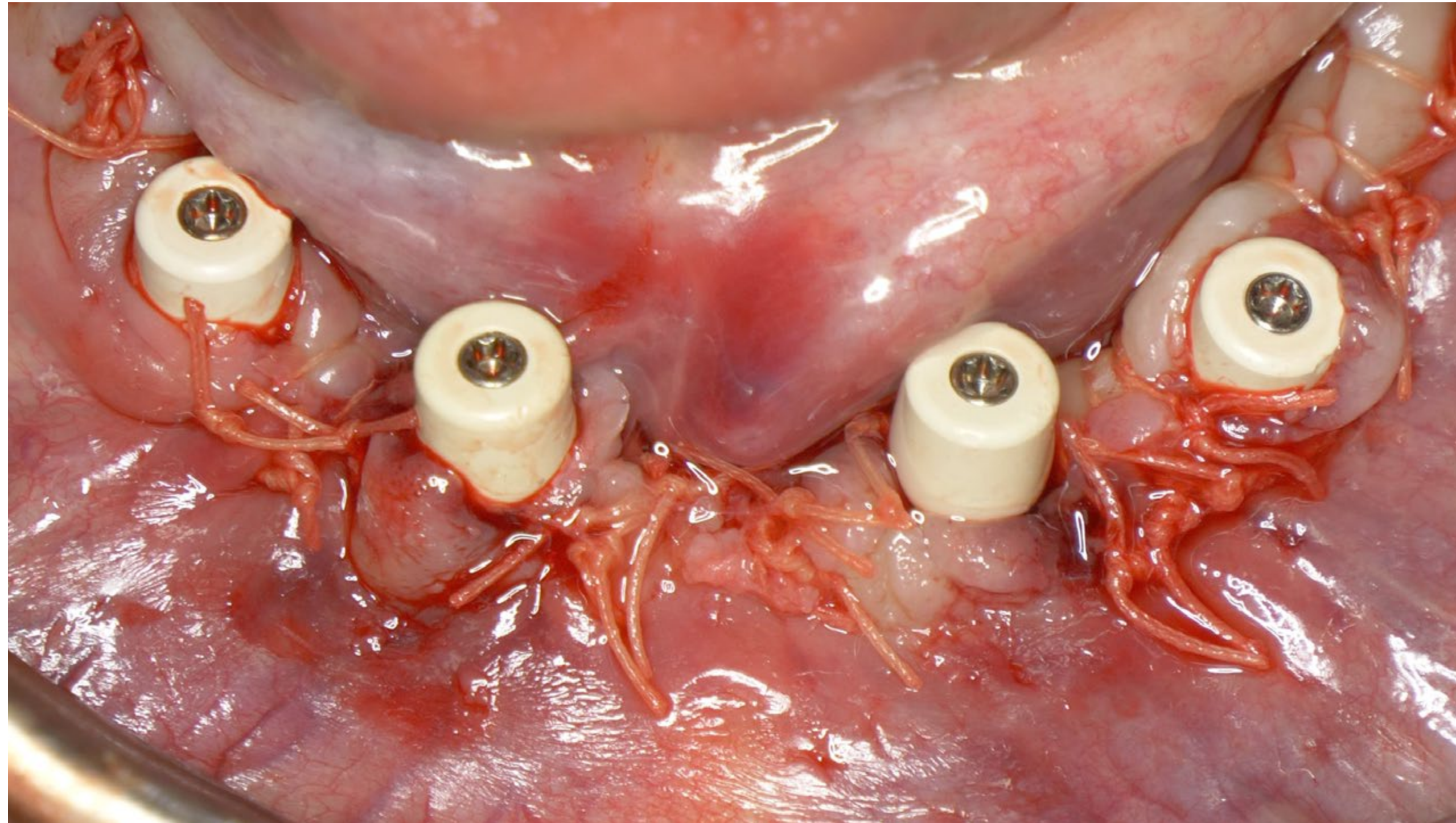


Screw-retained Abutments in place

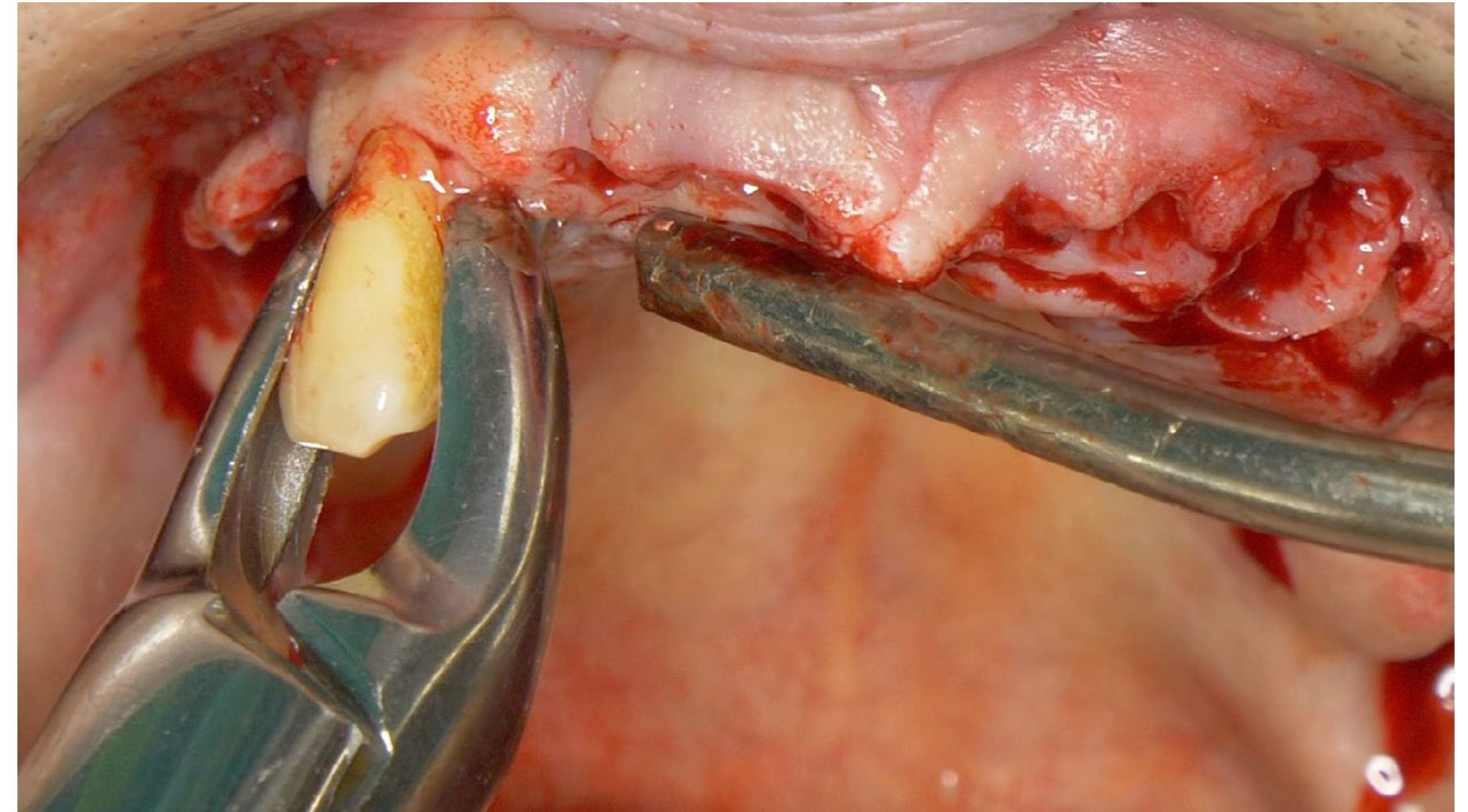


# Challenge 1: Bone reduction and chronic inflammation

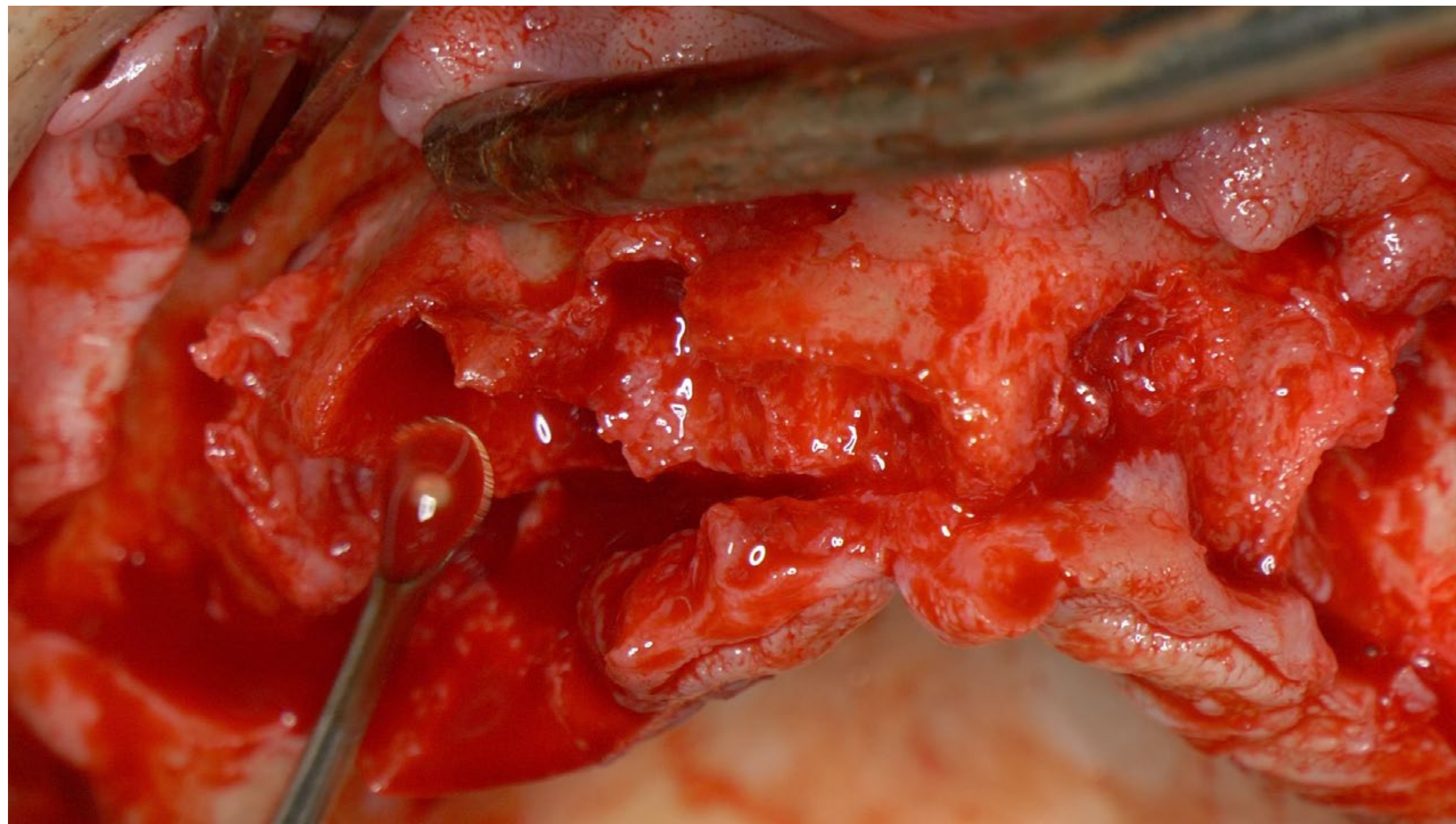
Clinical case



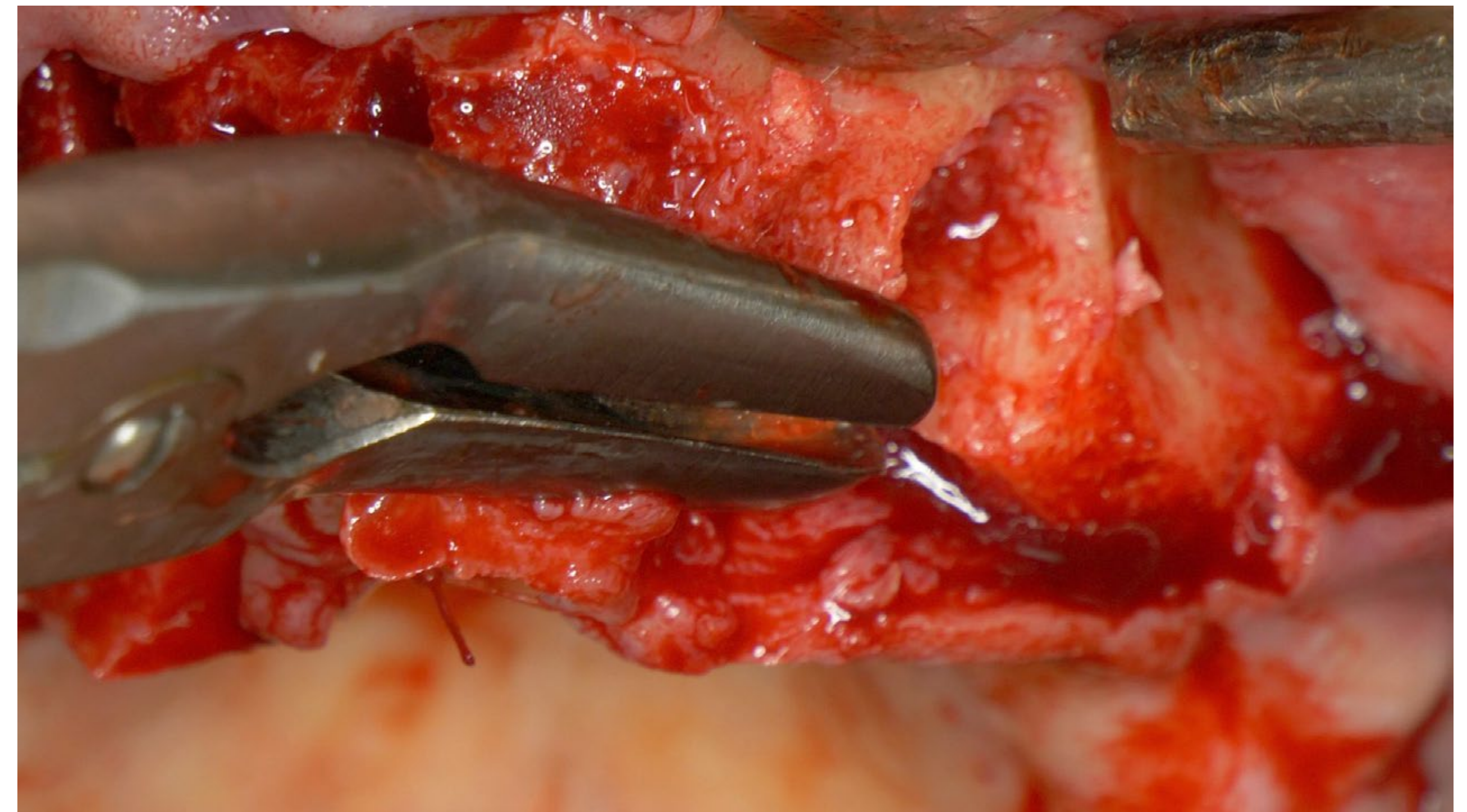
Protective caps Ø 4.6 mm in place



Extraction of hopeless teeth in the maxilla



Curettage and irrigation of extraction sockets

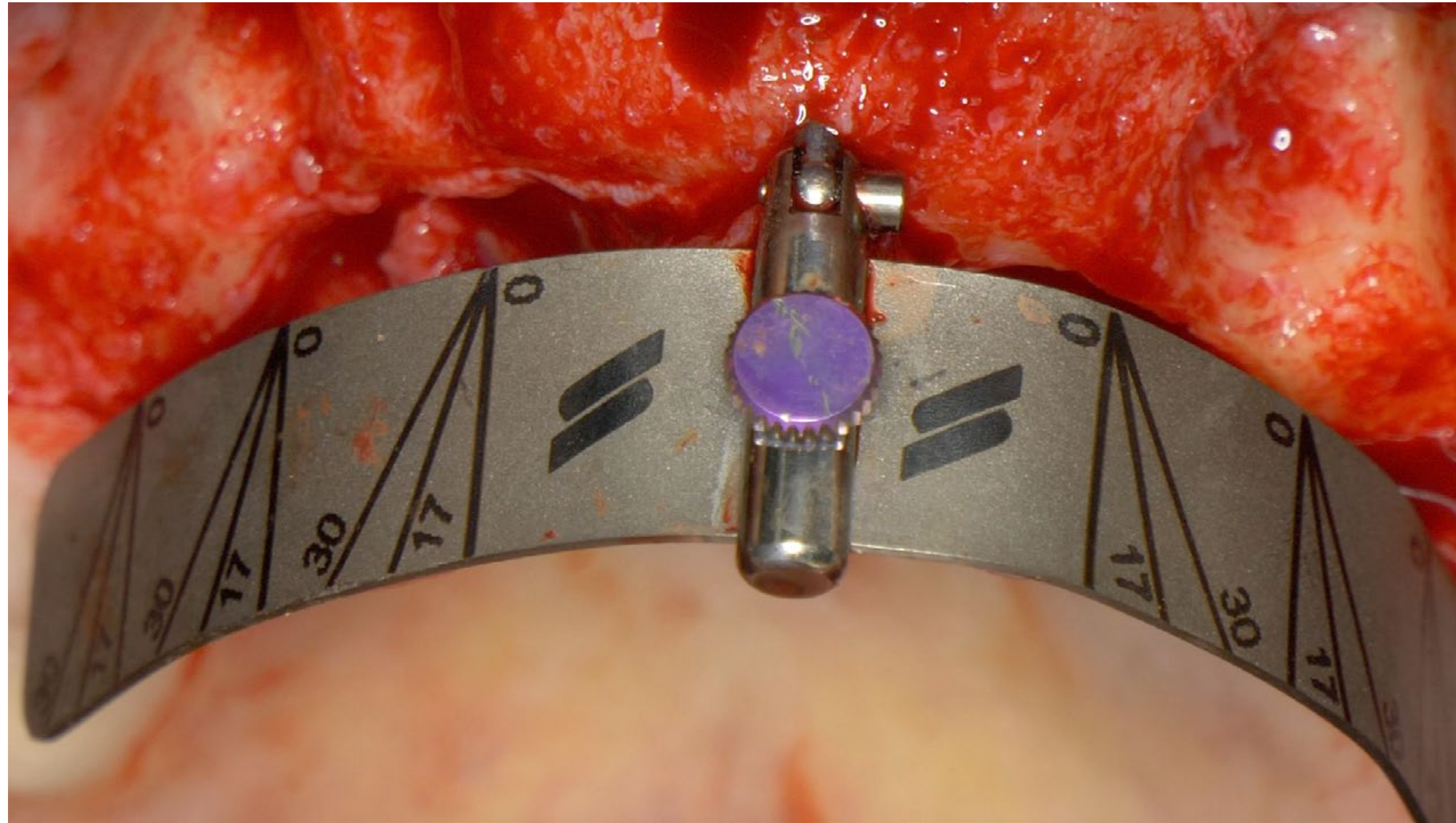


Bone reduction and levelling of the bone plane

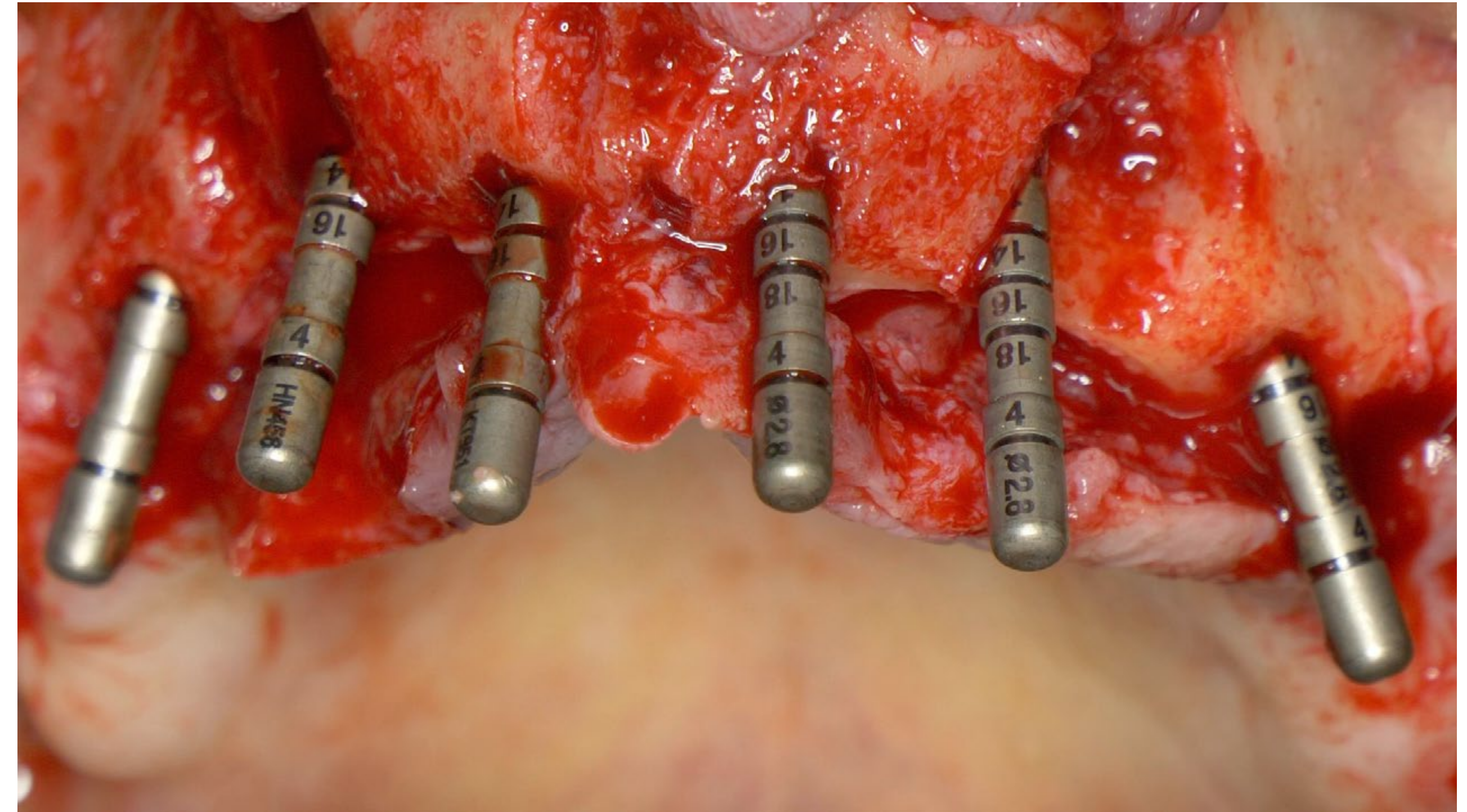


# Challenge 1: Bone reduction and chronic inflammation

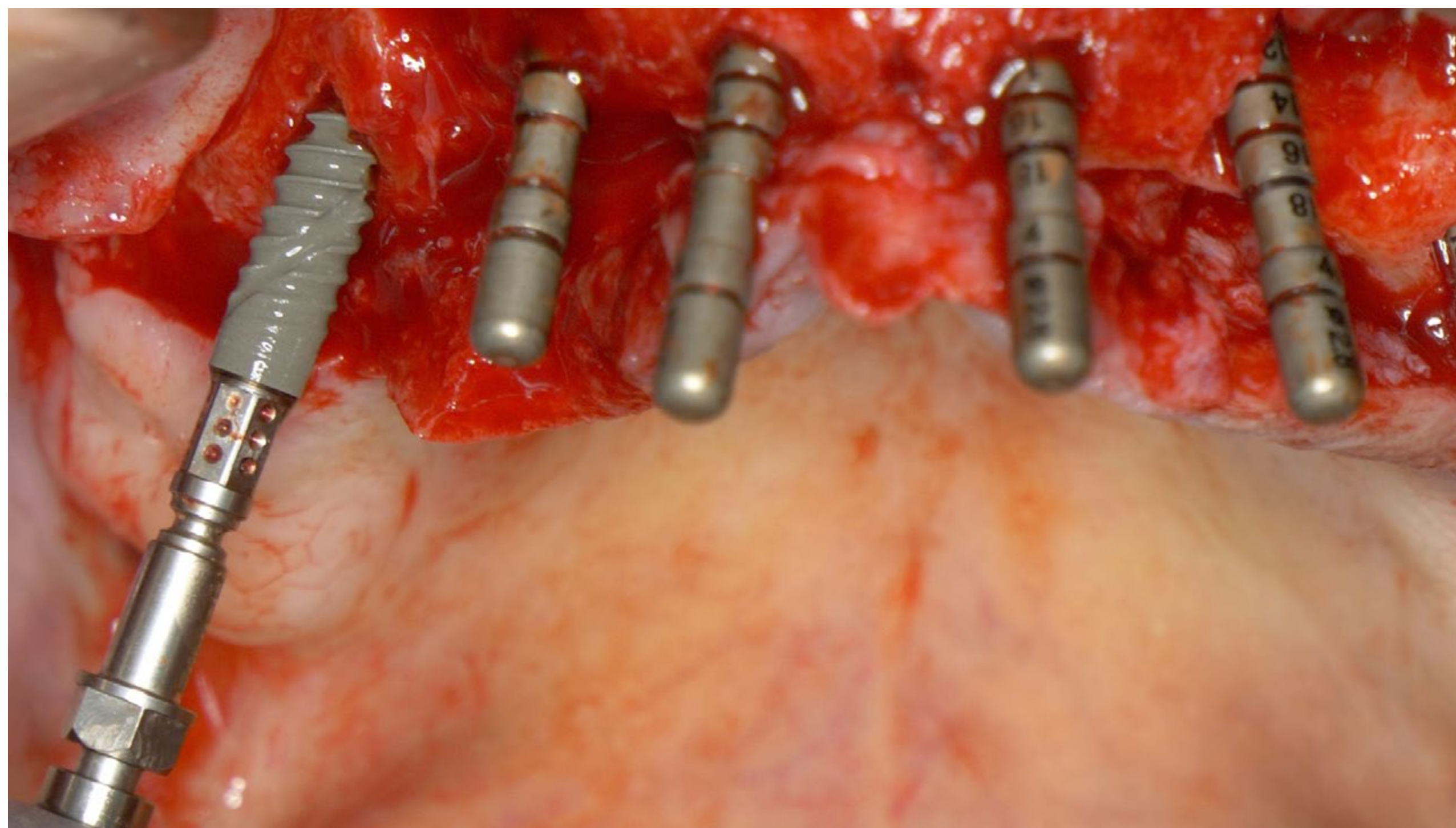
Clinical case



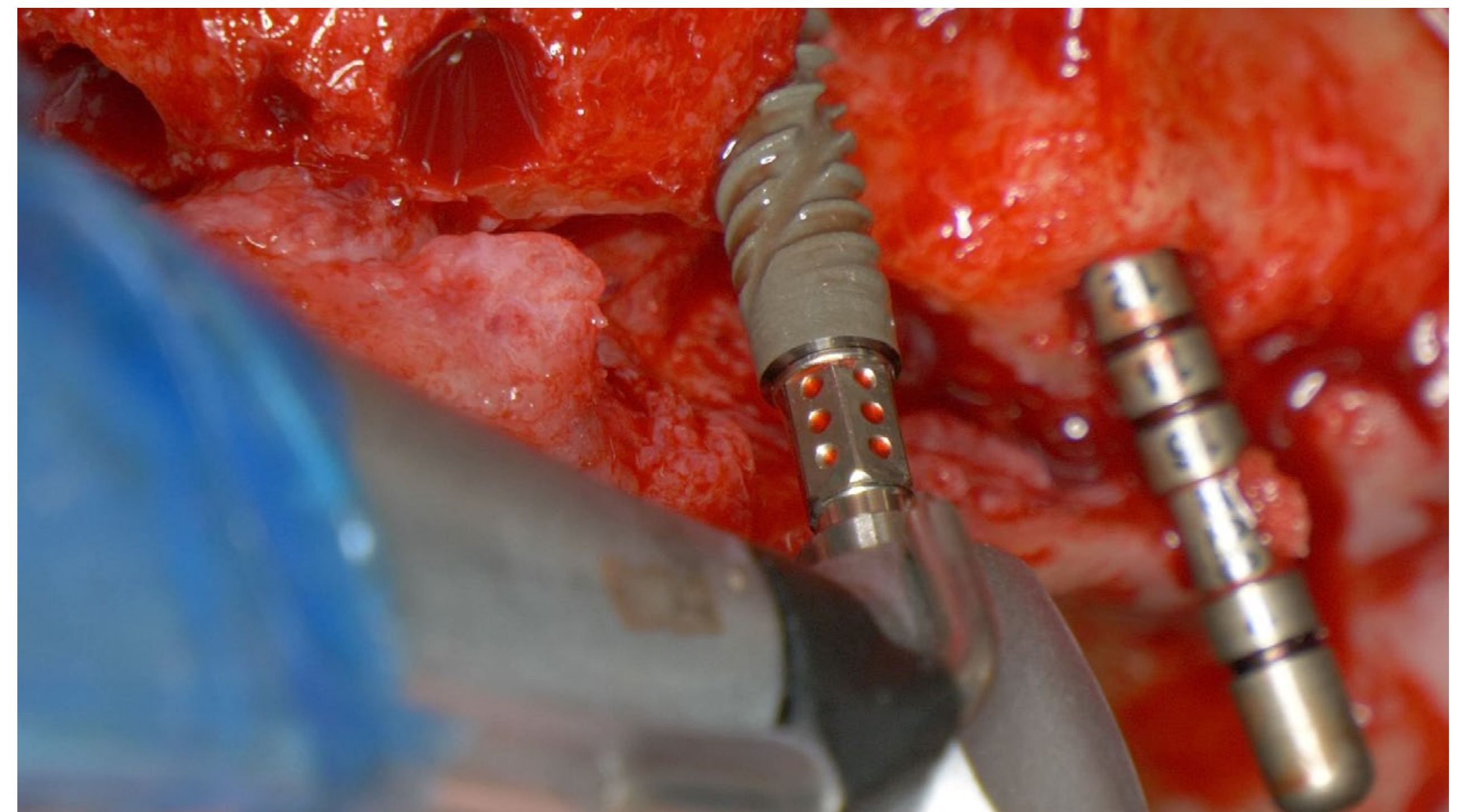
Straumann® Pro Arch Guide in place



Alignment of the implant sites



Placement of the Straumann® BLX Ø 3.75 mm RB SLActive® 12 mm Roxolid® implant with the torque of 35 Ncm

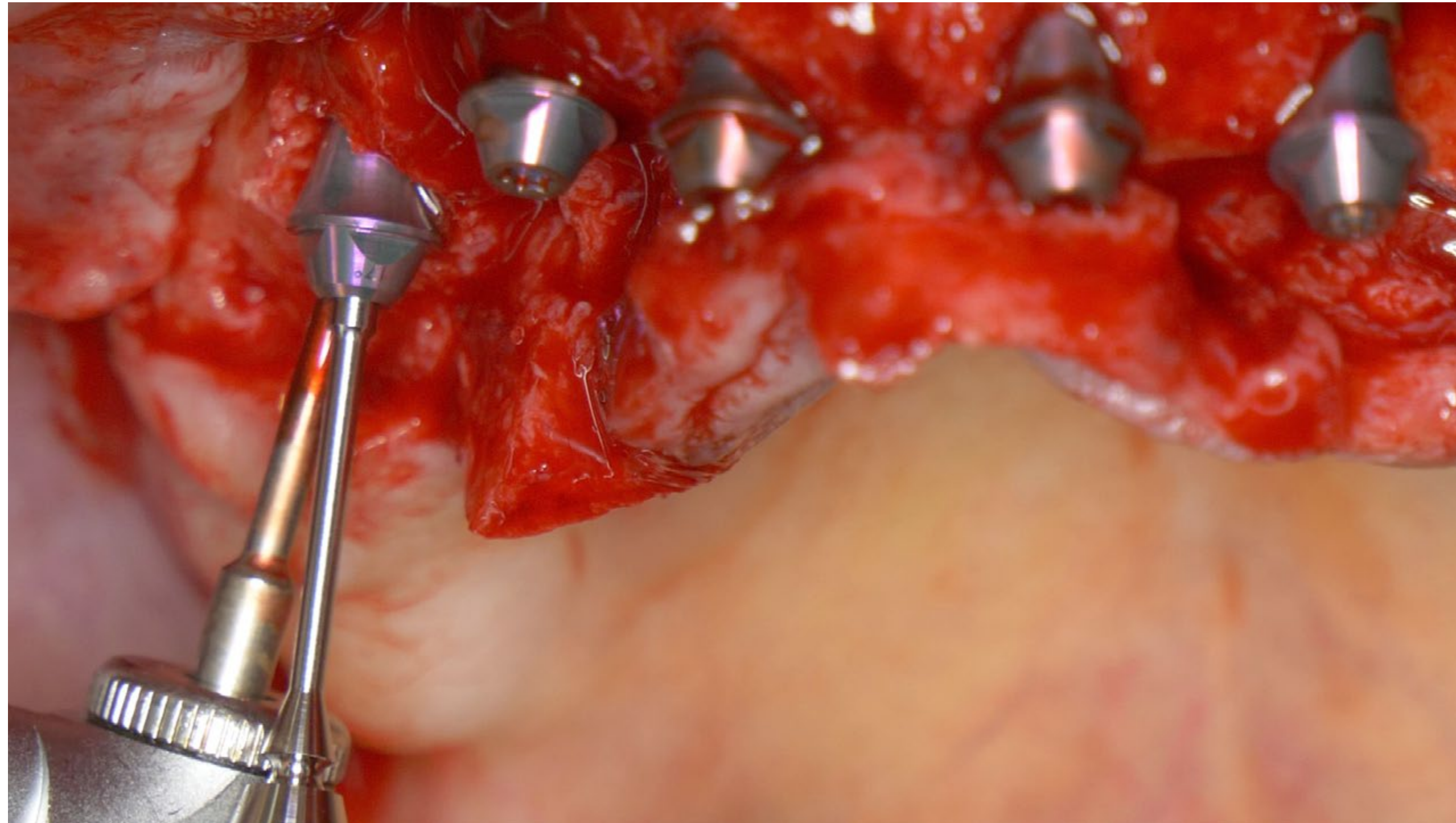


Placement of the Straumann® BLX Ø 3.75 mm RB SLActive® 12 mm Roxolid® implant with the torque of 35 Ncm

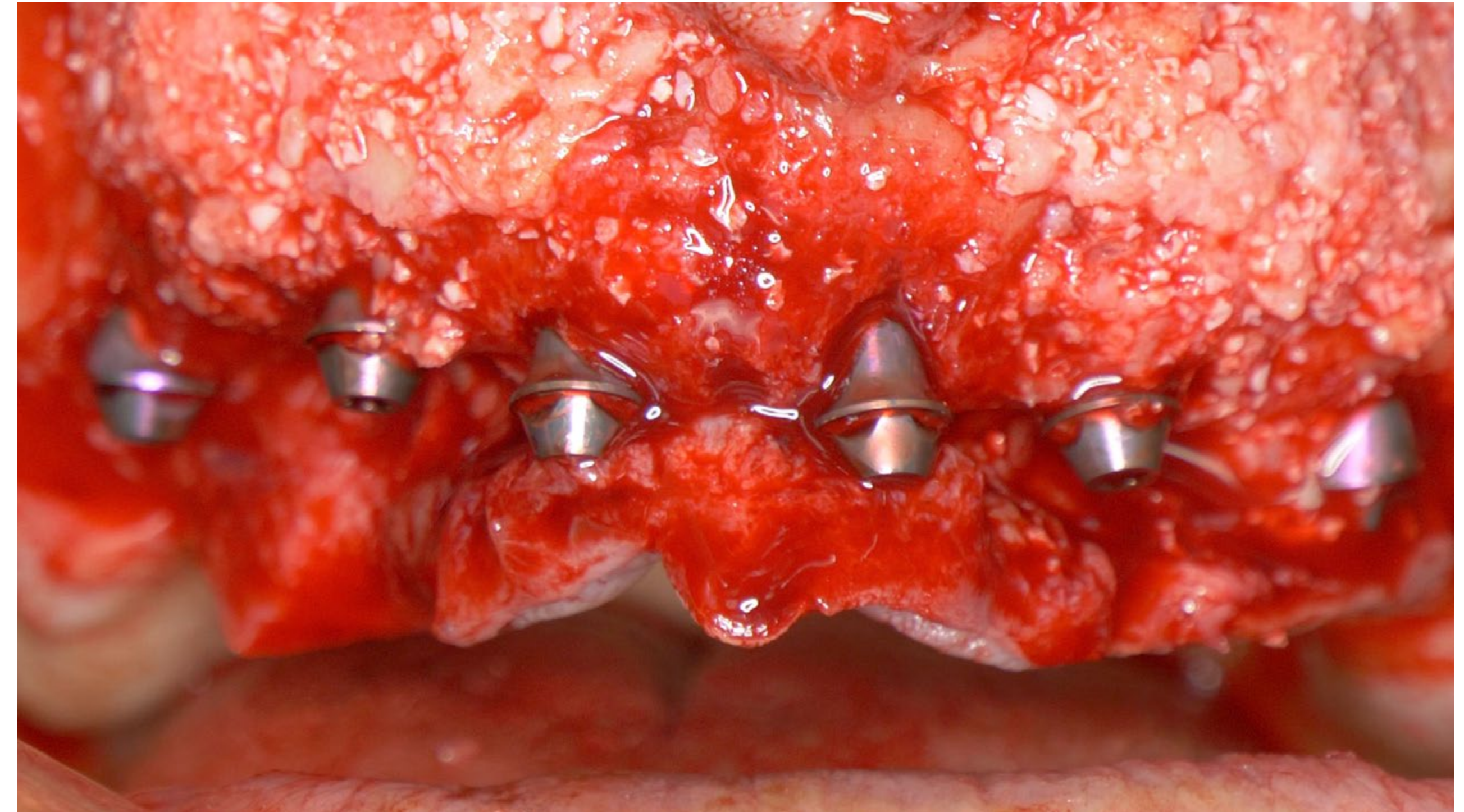


# Challenge 1: Bone reduction and chronic inflammation

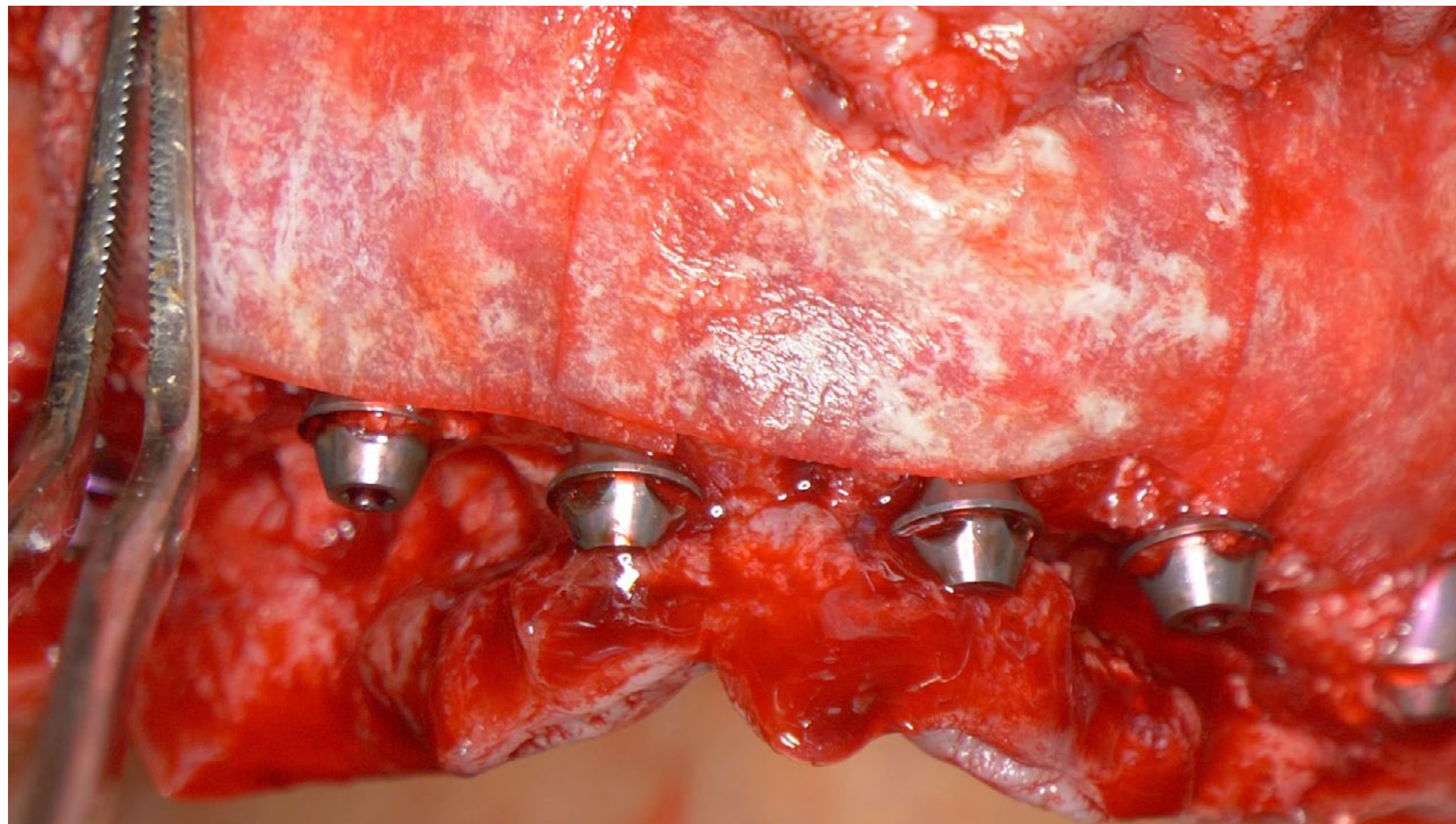
Clinical case



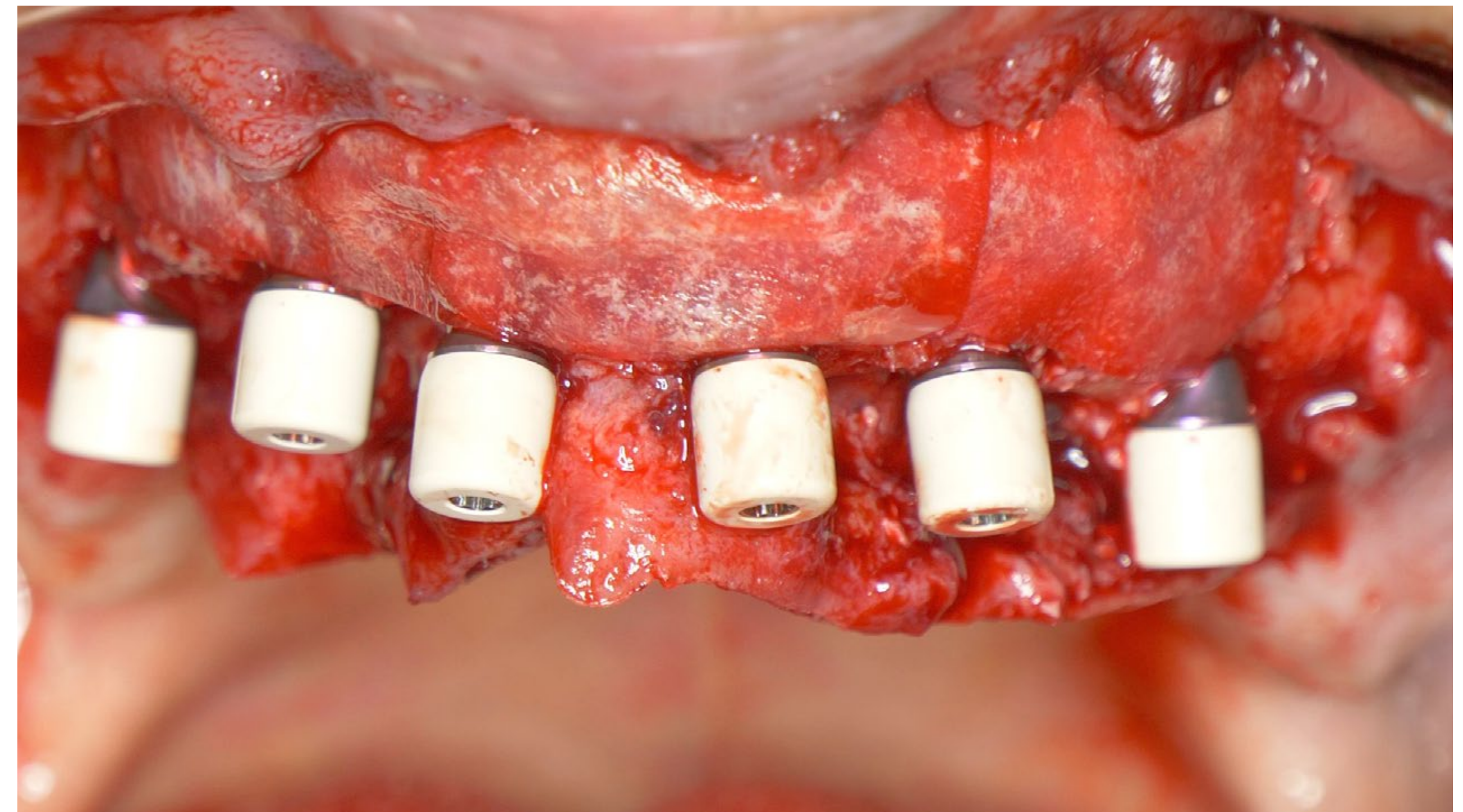
Placement of the Screw-retained Abutments



Placement of the XenoGraft® 0.5 mm to improve bone dimensions and lip support



Placement of the Straumann® Membrane Flex

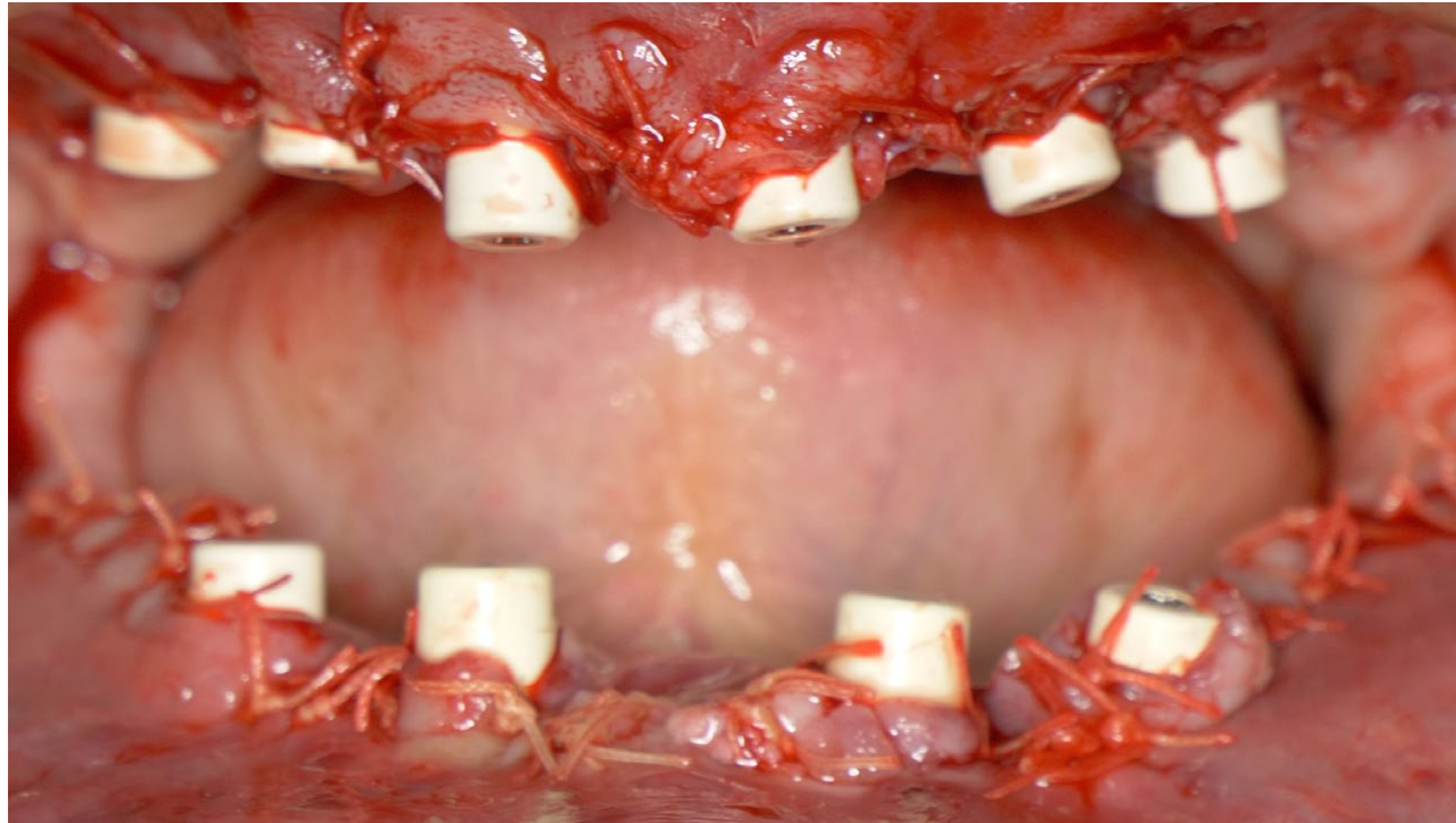


Protective caps Ø 4.6 mm in place

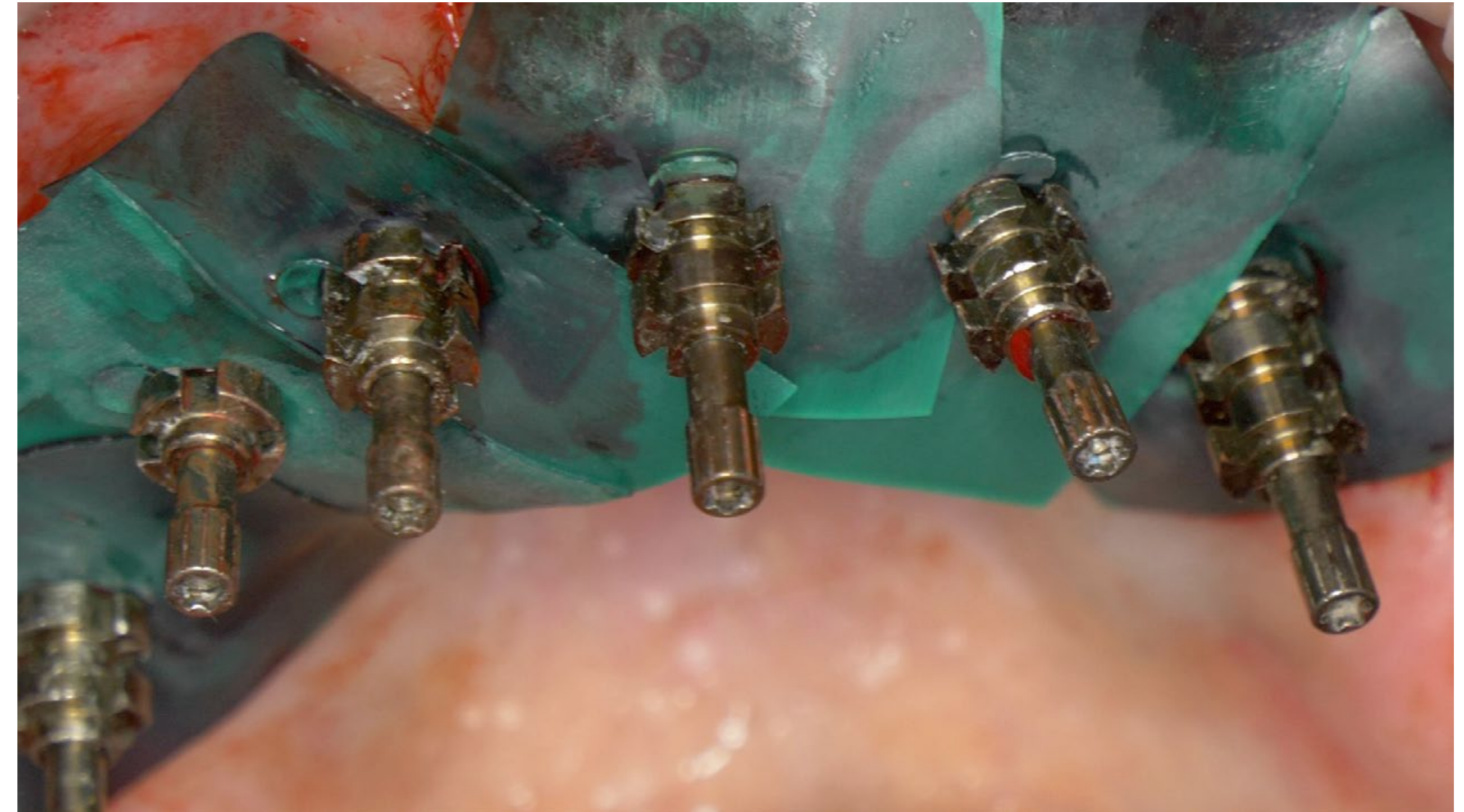


# Challenge 1: Bone reduction and chronic inflammation

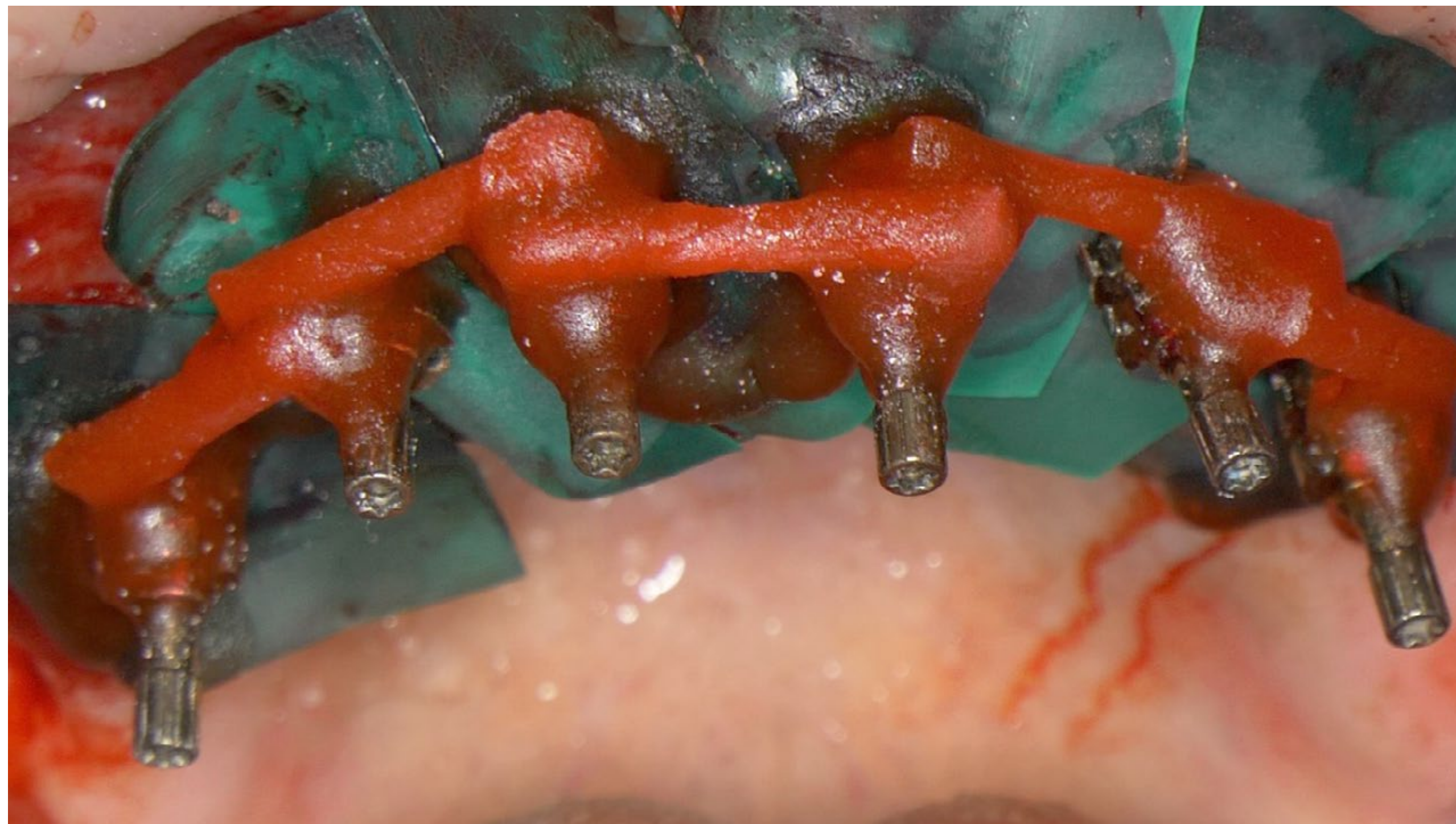Clinical case



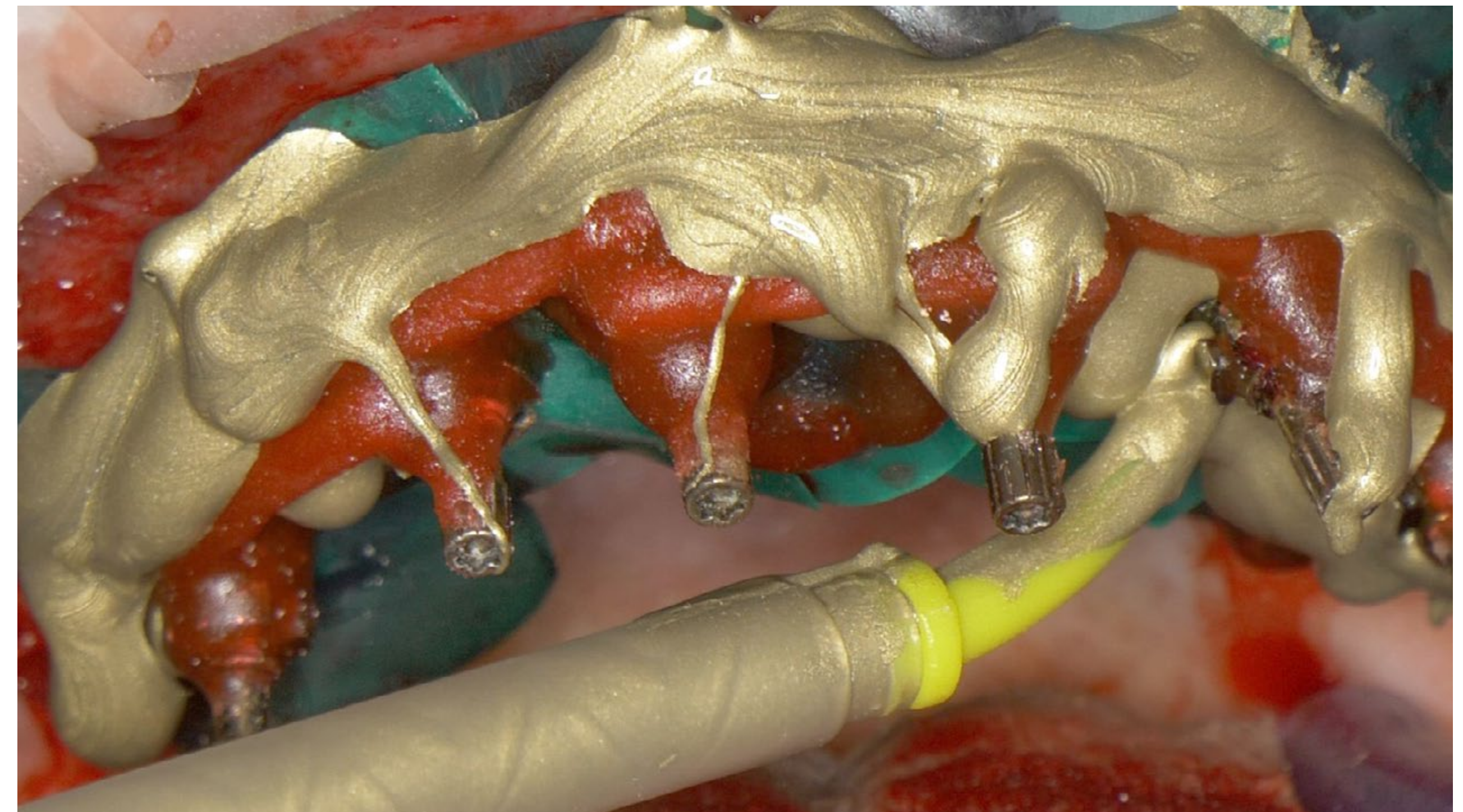Sutured site



Impression taking with open-tray technique  
Impression posts in place



Impression taking with open-tray technique  
Splint the impression posts using a resin material

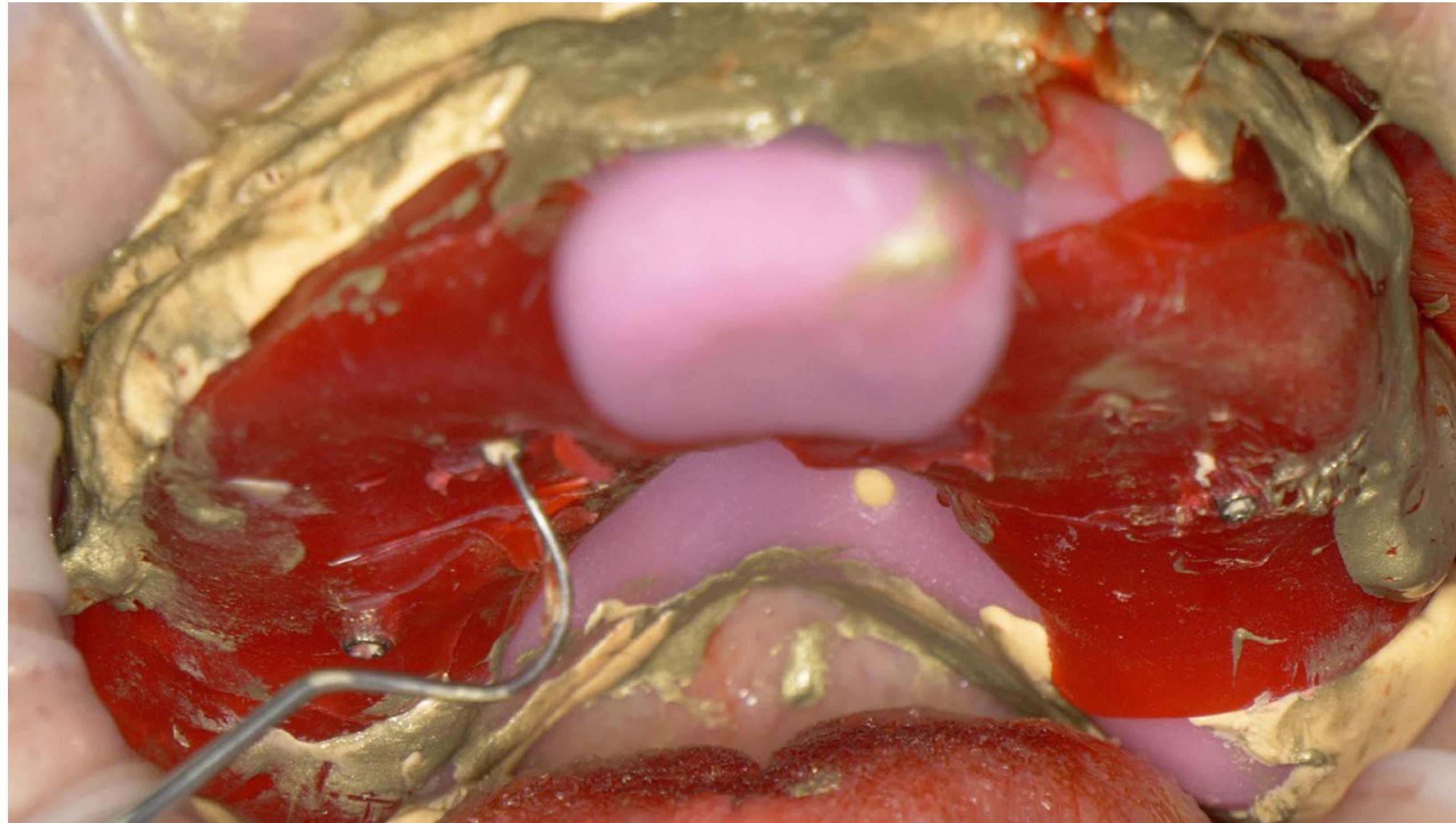


Impression taking using elastomeric impression material

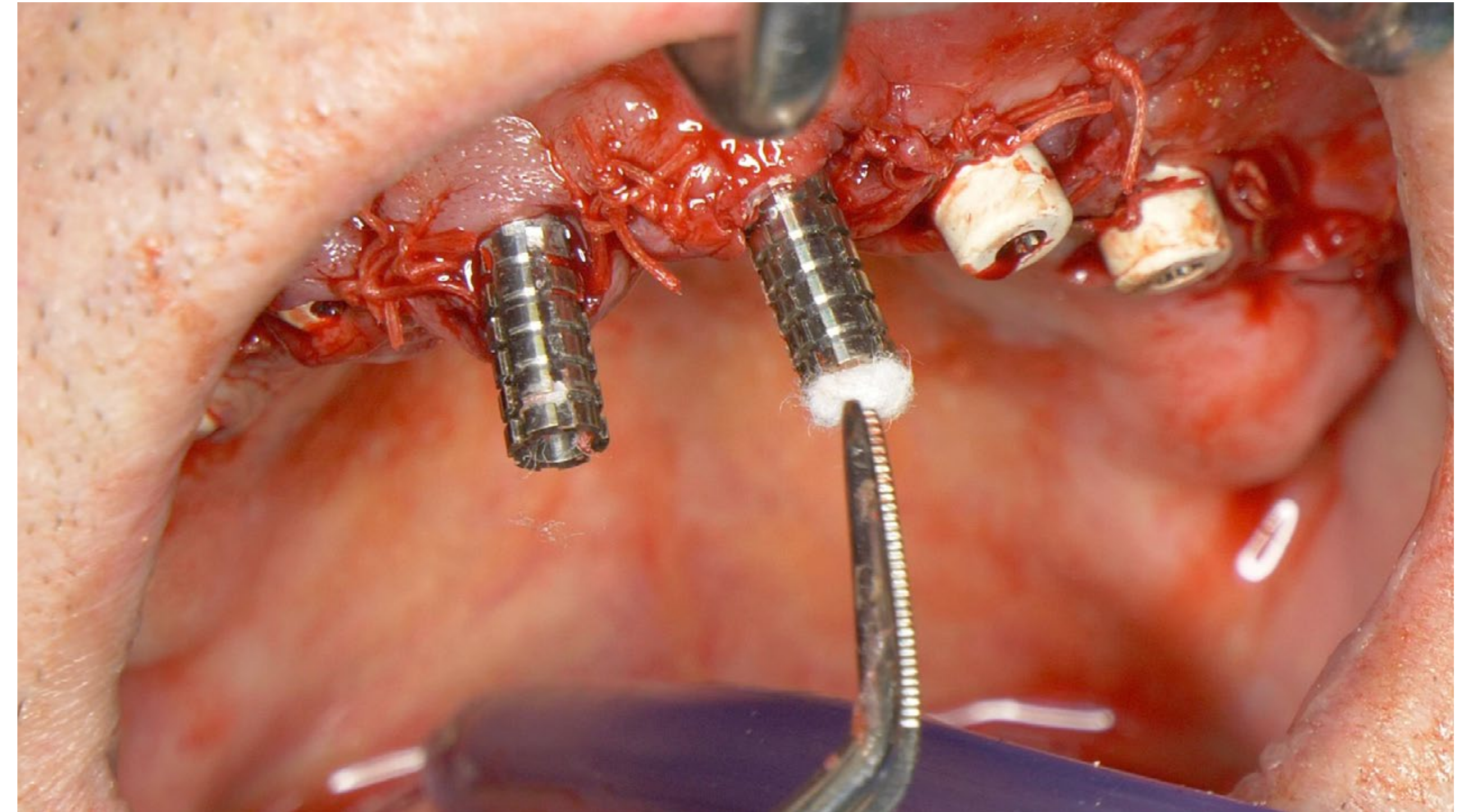


# Challenge 1: Bone reduction and chronic inflammation

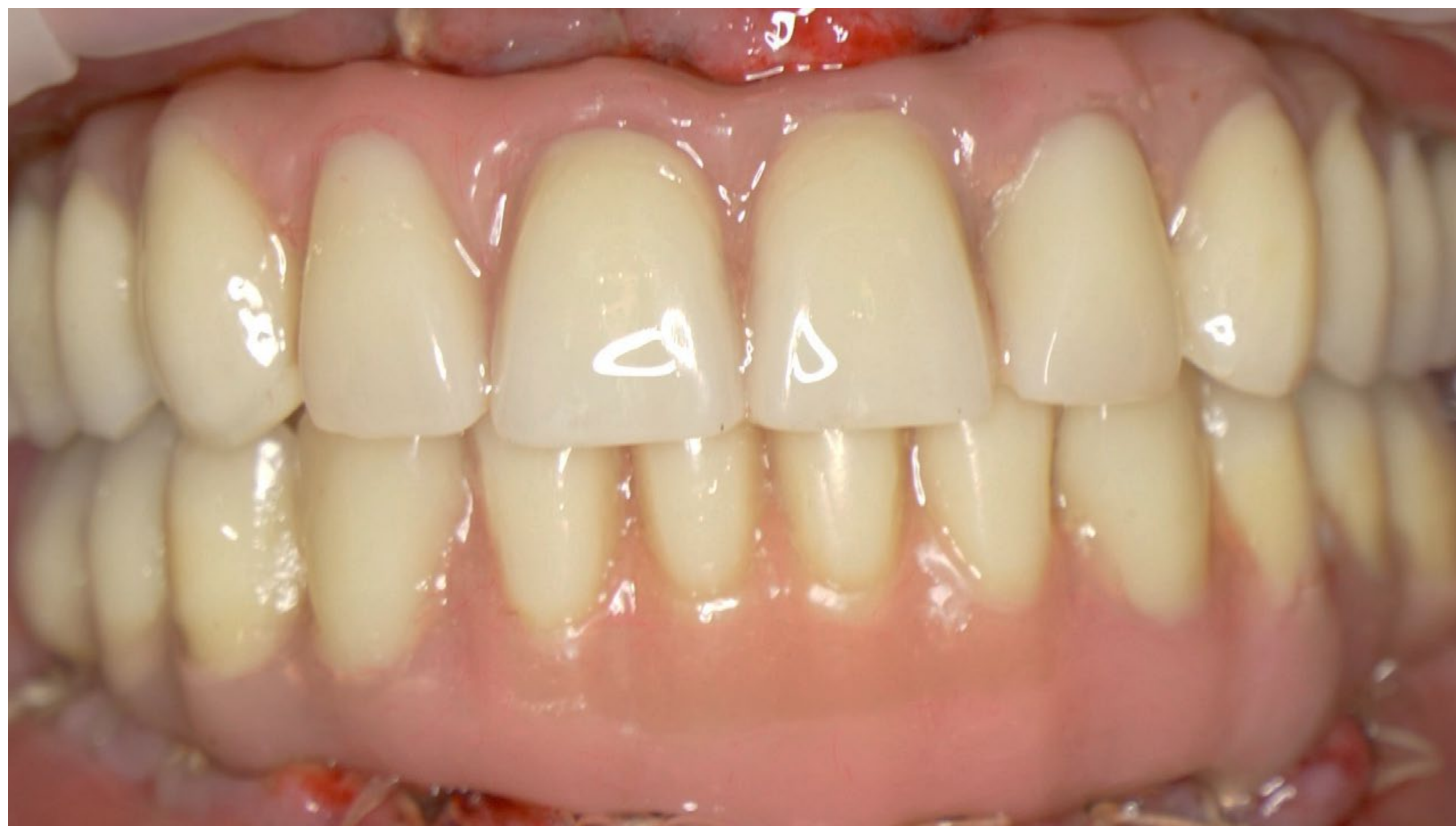Clinical case



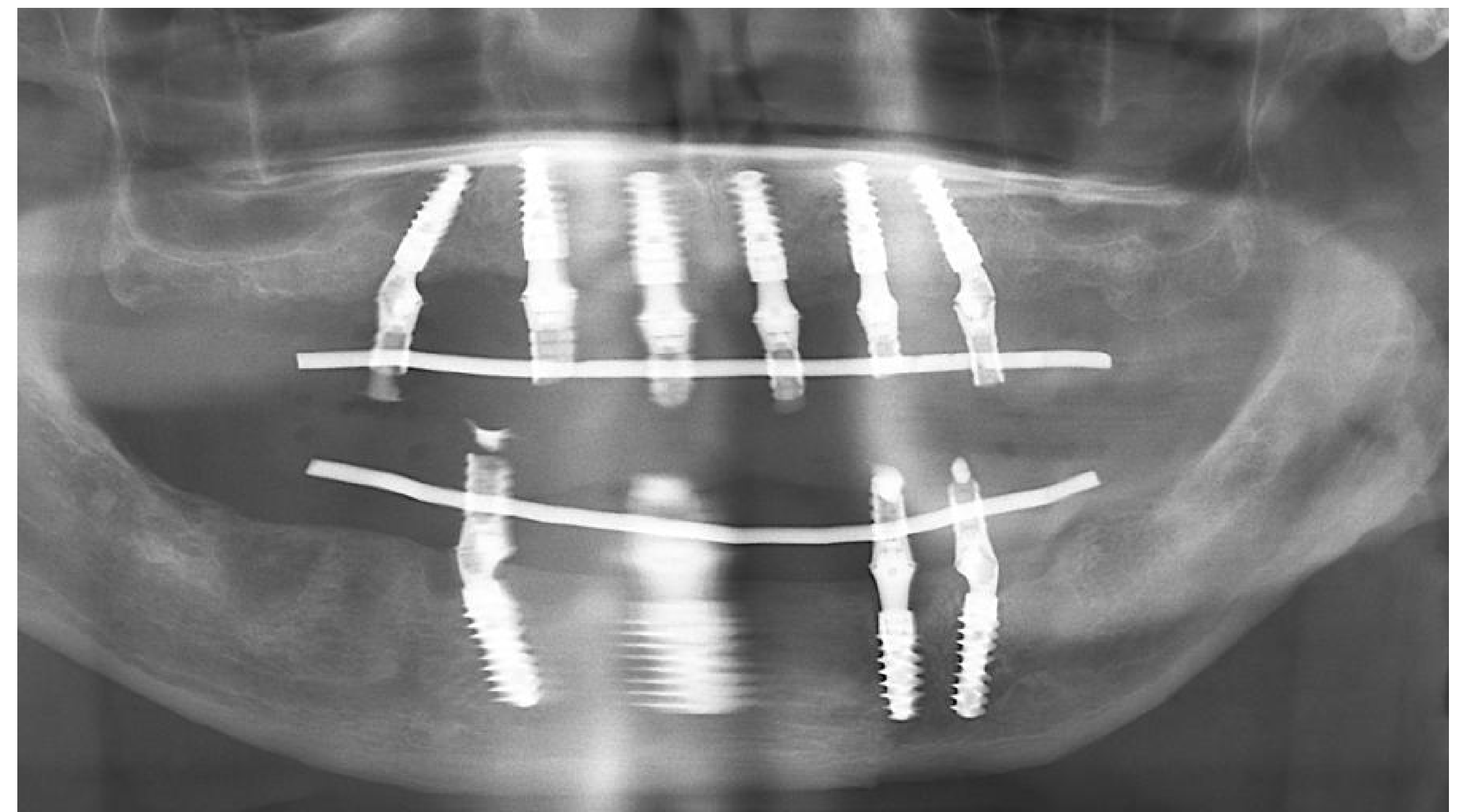
Uncovering of the screws



Titanium copings in place for pick-up procedure



Provisional prosthesis in place, the final prosthesis will be placed within six months




Panoramic radiograph after the implant placement and placement of the provisional prosthesis



# Challenge 2: Soft bone quality

General recommendations and clinical case from Prof. M. Laurenti and Prof. M. Ferrigno





# Challenge 2: Soft bone quality

## General recommendations




### General recommendations from Prof. M. Laurenti and Prof. M. Ferrigno

- Use the of implant with wide threads
- Use of long implants if possible, as the primary goal of the rehabilitation is to enable immediate loading
- Underpreparation of the bone site. In the present case the implant site preparation stopped at the Ø 2.8 mm drill for the 4.5 mm implant

Degree in Medicine and Surgery “cum laude” from the University of Rome “La Sapienza”, Italy. Has served as professor on postgraduate courses at multiple dental schools and universities in Italy and Austria.

ITI Fellow and Director of the ITI Study Group in Rome. Author of several scientific publications in the field of implantology. Speaker and instructor on national and international courses and conferences.

Private practice in Rome and Latina specialized in implantology and oral surgery, focusing on severe bone atrophy and related disorders



**Prof. Mauro Laurenti**  
MD, DDS, Private Practitioner  
Rome, Italy

Medical degree as dentist from the University of Rome “La Sapienza” with “cum laude” distinction.

Has served as professor on postgraduate courses at multiple dental schools and universities in Italy and Austria. A recognized and awarded international speaker, as well as ITI Fellow.

Author of several scientific publications in the field of implantology.

Private practice in Rome for implantology and oral surgery, focusing especially on regenerative treatment and implant therapy in the esthetic zone.



**Prof. Nicola Ferrigno**  
DDS, Private Practitioner  
Rome, Italy

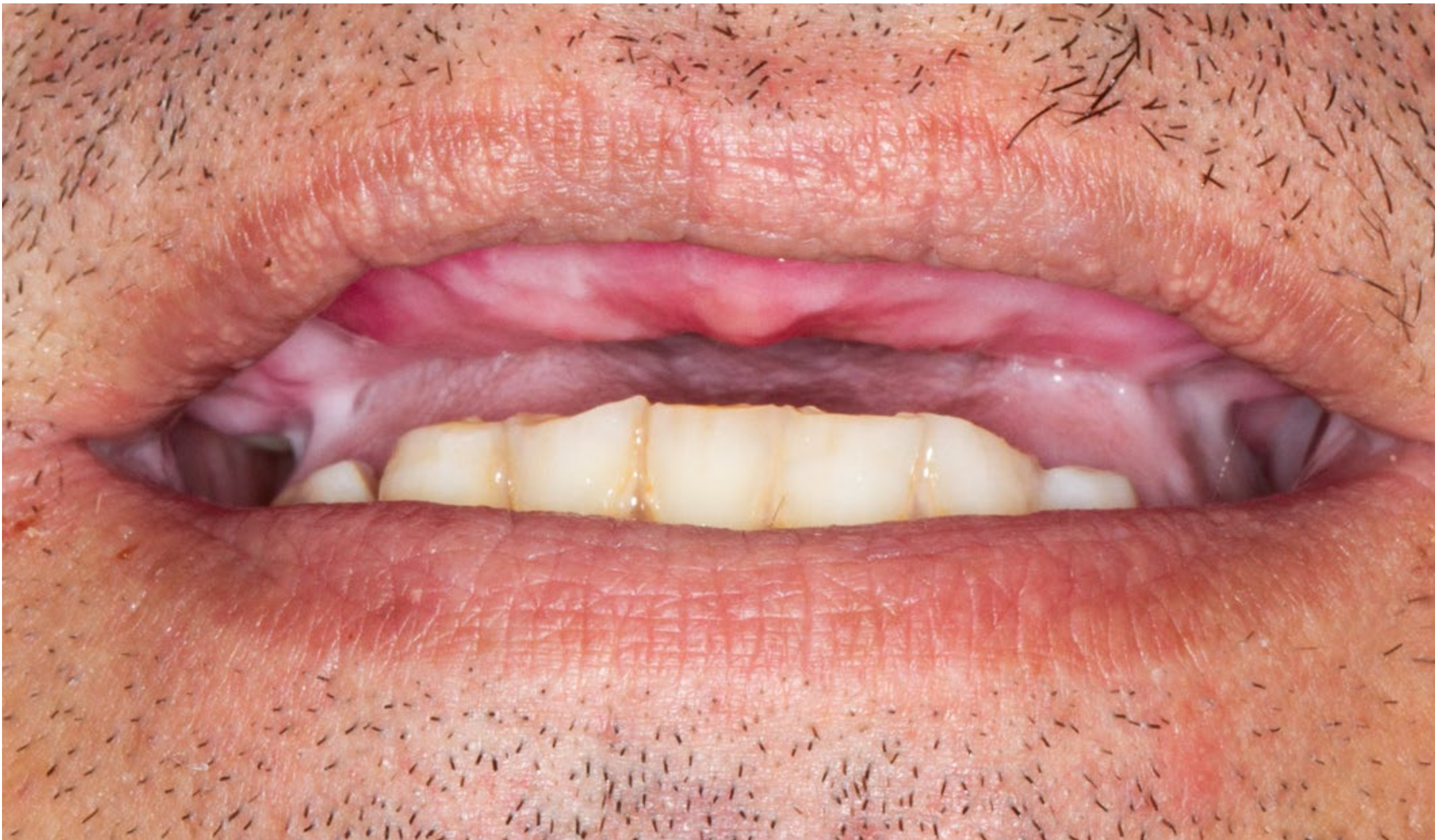

# Challenge 2: Soft bone quality

Clinical case



## Initial situation



## Patient information

Age	44
Jaw	Maxilla
Health status	Good
Height of smile line	Low
Bone type	Soft
Infections at implantation site	No
Bone anatomy defects	No
Risks	Smoker

## Additional difficulties

Soft bone quality D3/D4
Bruxism
Moderate resorption in the maxilla

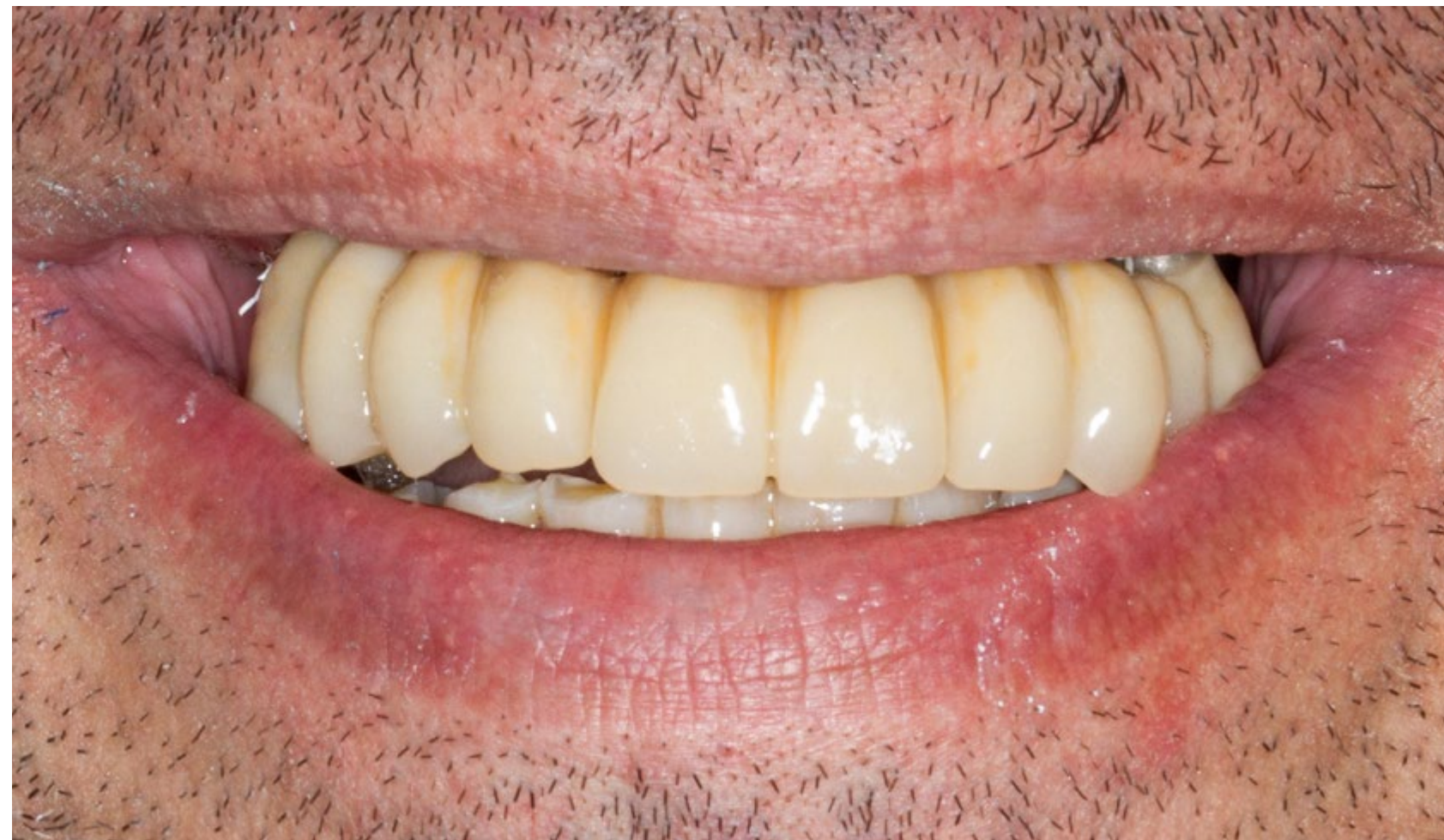

# Challenge 2: Soft bone quality

Clinical case



## Provisional prosthesis



## Treatment

- Moderate bone reduction
- Fixed immediate rehabilitation with Straumann® Pro Arch on four implants
- Tilting of the posterior implants because of low bone availability in the posterior region and to avoid bone augmentation

**Temporary restoration:** acrylic provisional prosthesis

**Planned final prosthesis:** metal-acrylic one piece fixed prostheses

## Materials used



Straumann® BLX Ø 4.5 mm  
RB SLActive® 14 mm Roxolid®



cerabone® granules  
0.5–1.0 mm



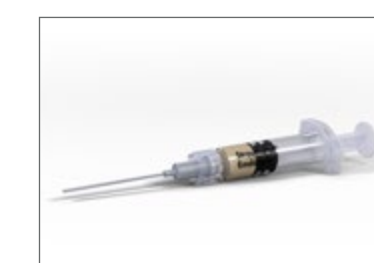Screw-retained abutments,  
straight, GH 2.5 mm  
Screw-retained abutments,  
30° angled, GH 4.5 mm



Jason® membrane



Straumann® BLX Ø 4.5 mm  
RB SLActive® 14 mm Roxolid®



Straumann® Emdogain®




# Challenge 2: Soft bone quality

Clinical case



## Our experience



Prof. Mauro Laureti  
MD, DDS, Private Practitioner

*“We are impressed by the possibility to obtain high primary stability with Straumann® BLX even in soft bone types (D3, D4). This is a fundamental requirement for immediate loading and delivery of the immediate prosthesis.”*



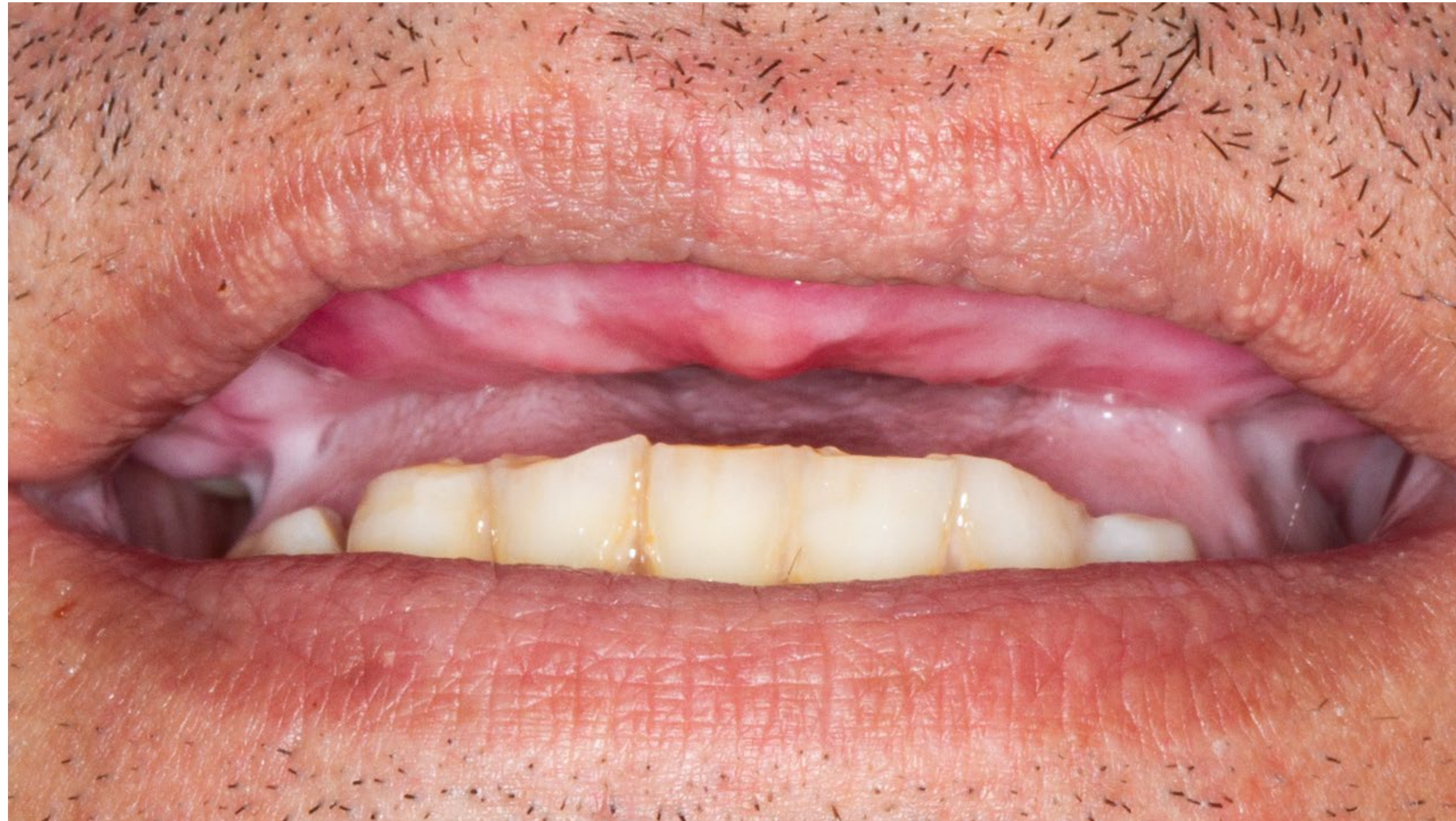Prof. Nicola Ferrigno  
DDS, Private Practitioner

*“We appreciate the prosthetic protocol. The simplification of the portfolio facilitates treatment procedure and considerably reduces chair time. Patients increasingly request immediate restorations with temporary prostheses. The Straumann® BLX Implant System allows clinicians to perform these restorations in a simple and predictable way and offers the possibility to expand the number of patients.”*

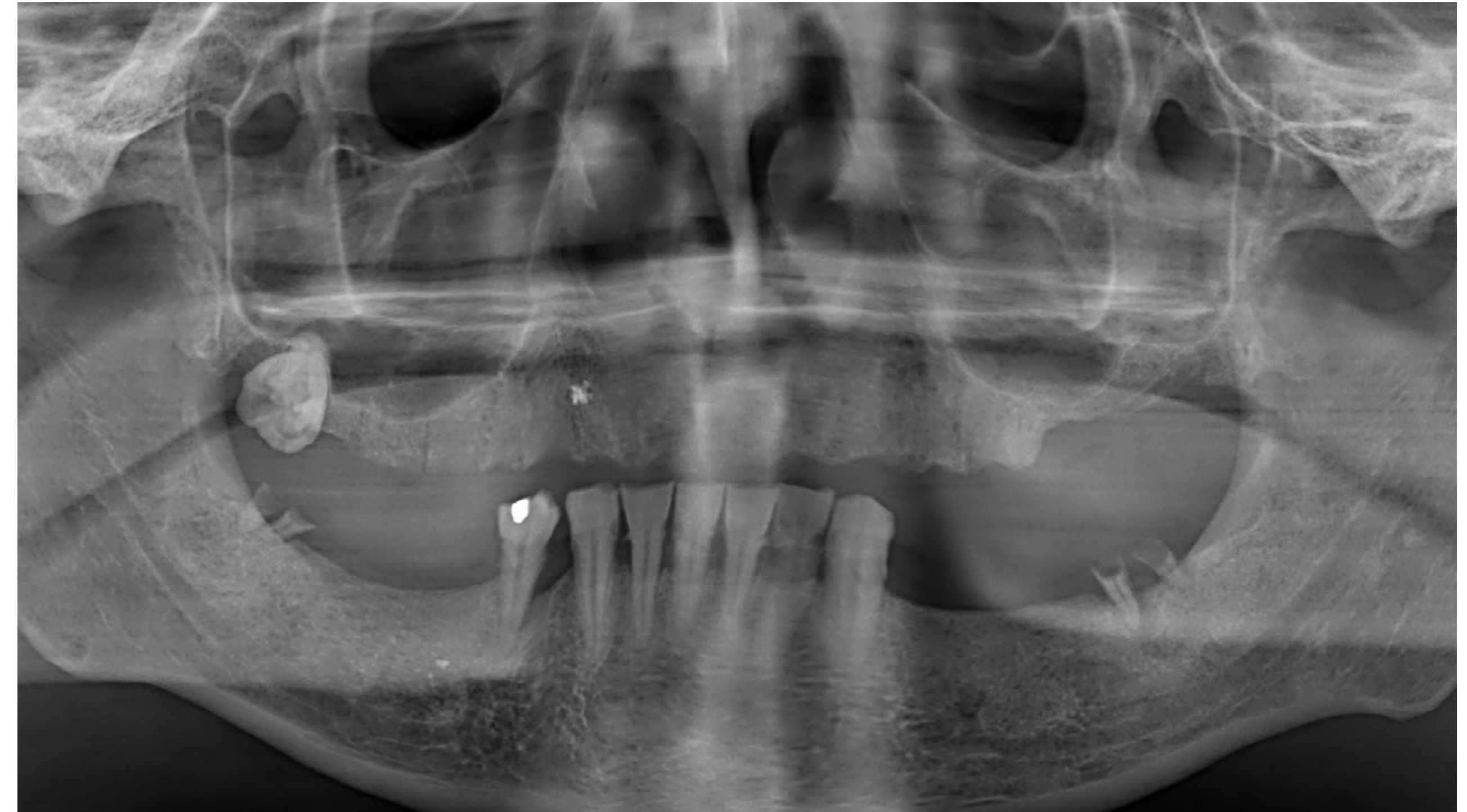

# Challenge 2: Soft bone quality

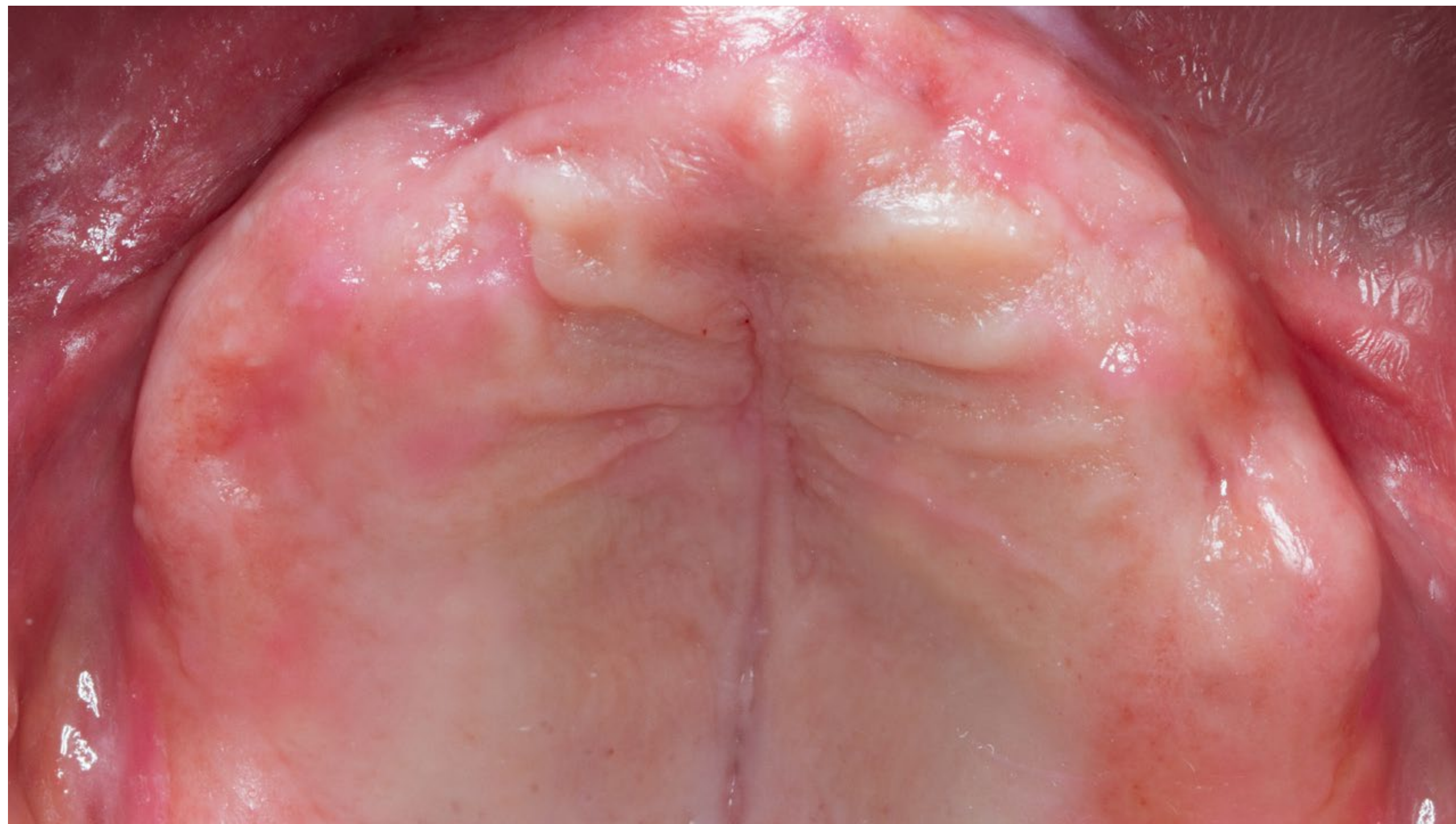Clinical case



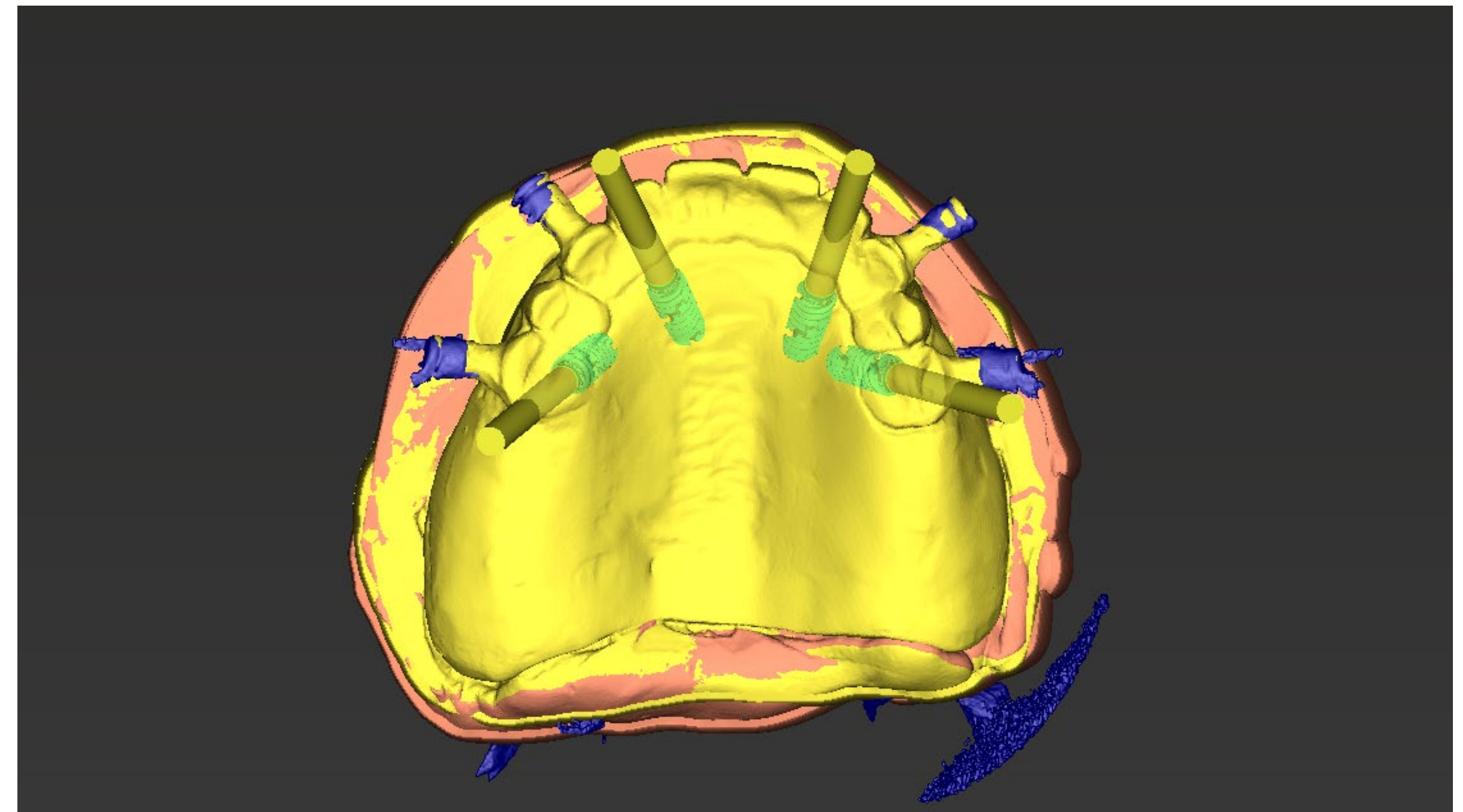
Initial clinical situation



Panoramic preoperative radiograph



Occlusal view

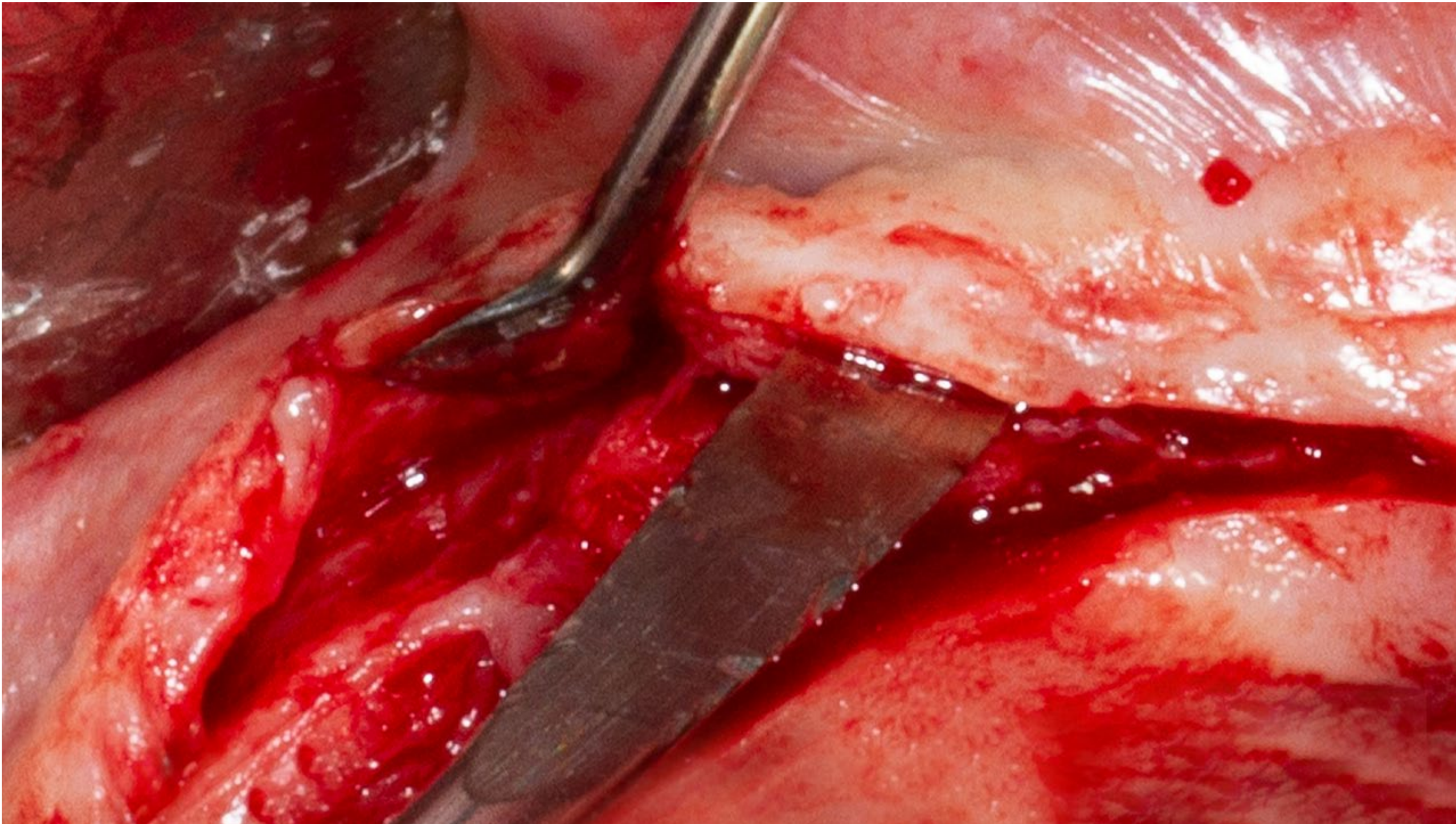


Treatment planning with CoDiagnostiX®

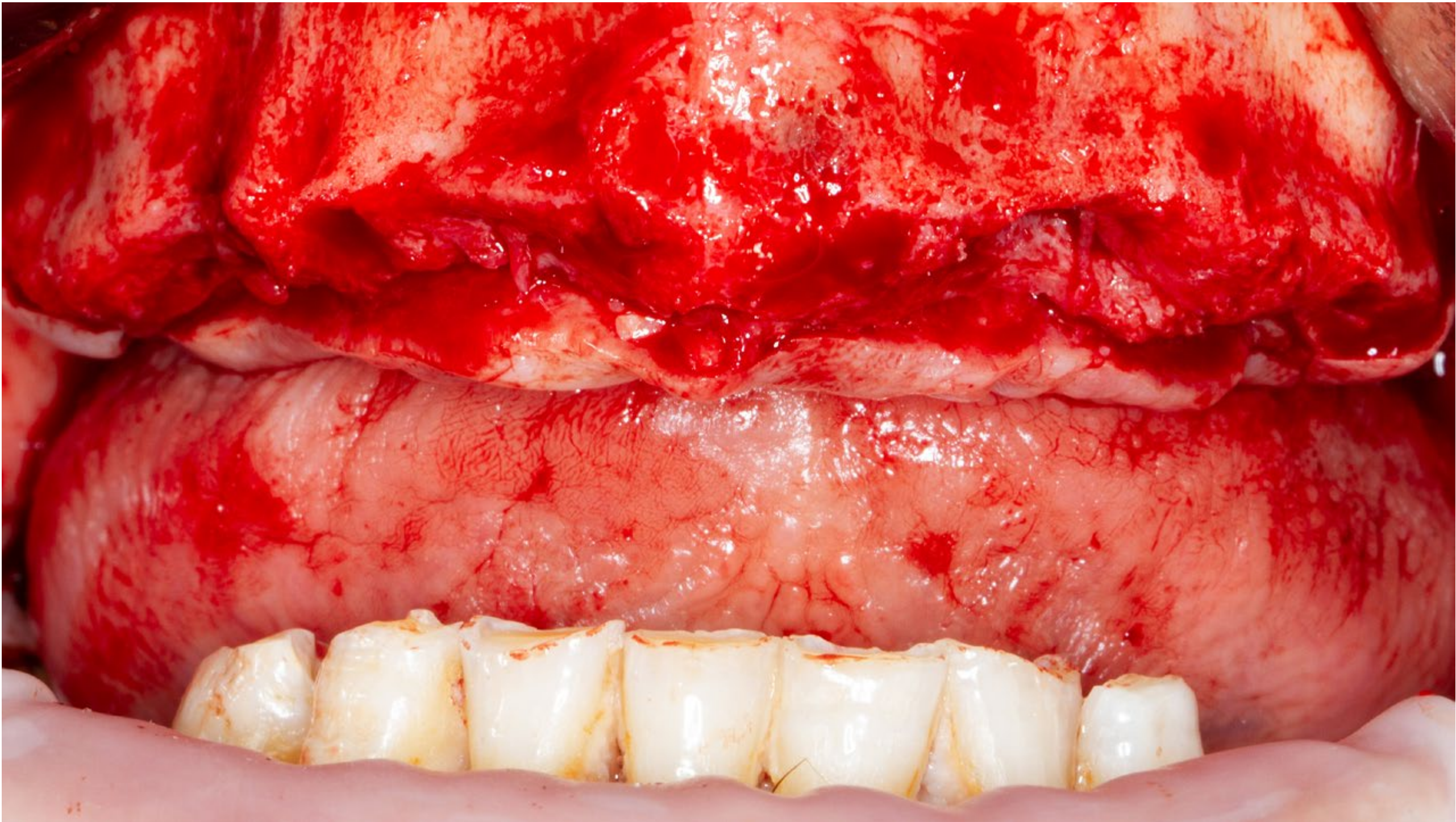


# Challenge 2: Soft bone quality

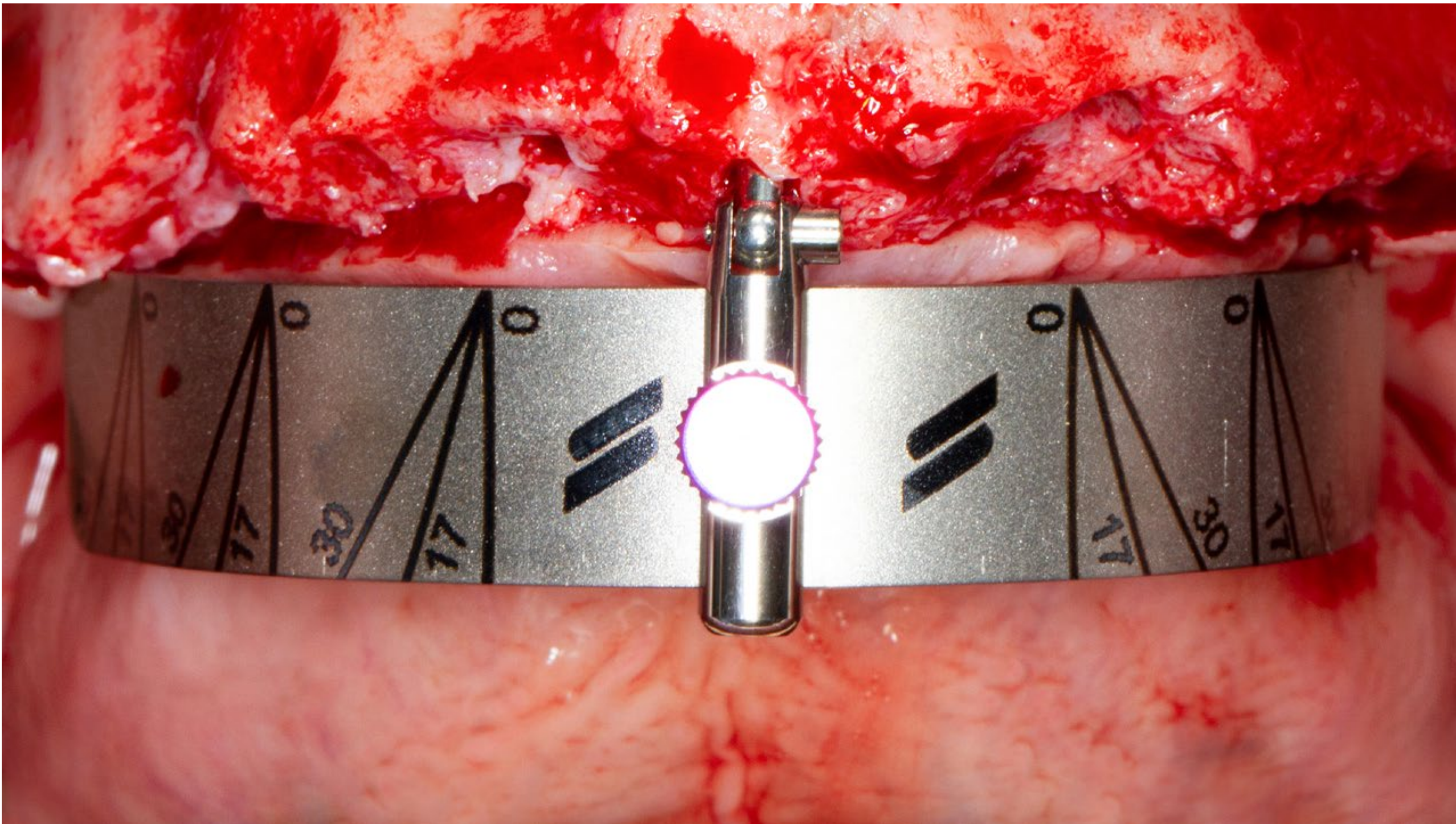
Clinical case



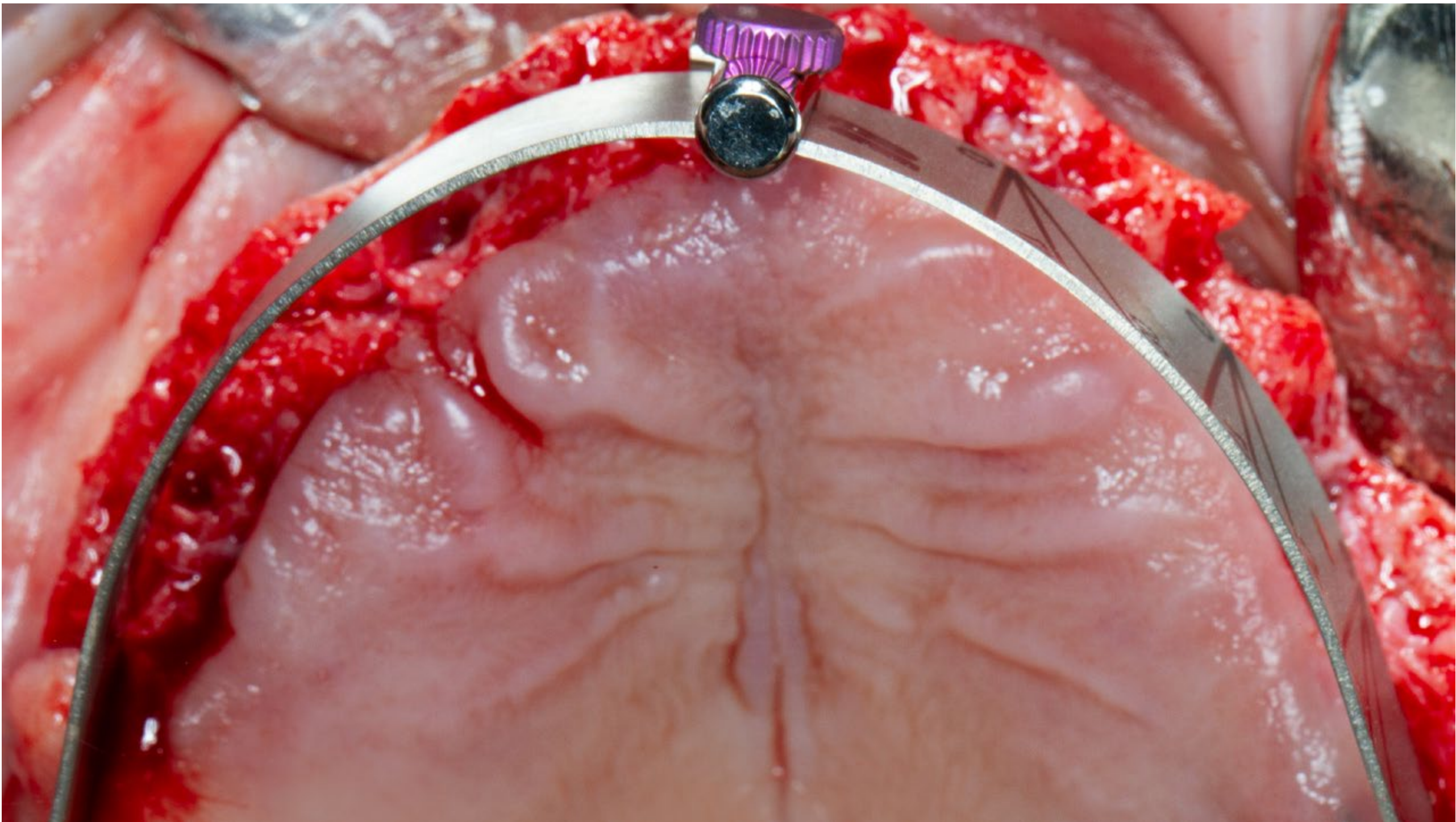
Flap elevation



Frontal view after flap elevation and bone reduction



Straumann® Pro Arch Guide in place  
Frontal view

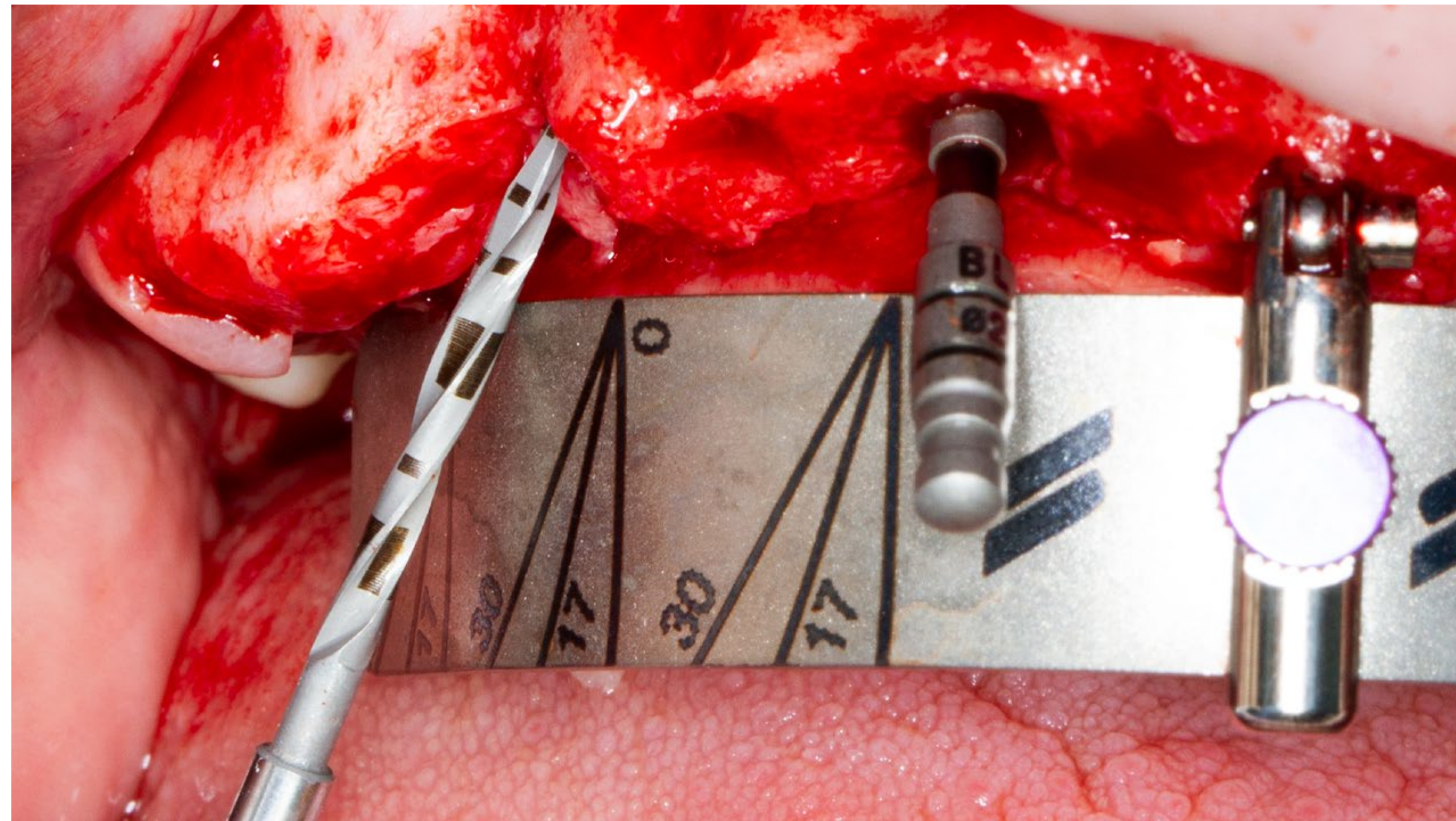


Straumann® Pro Arch Guide in place  
Occlusal view

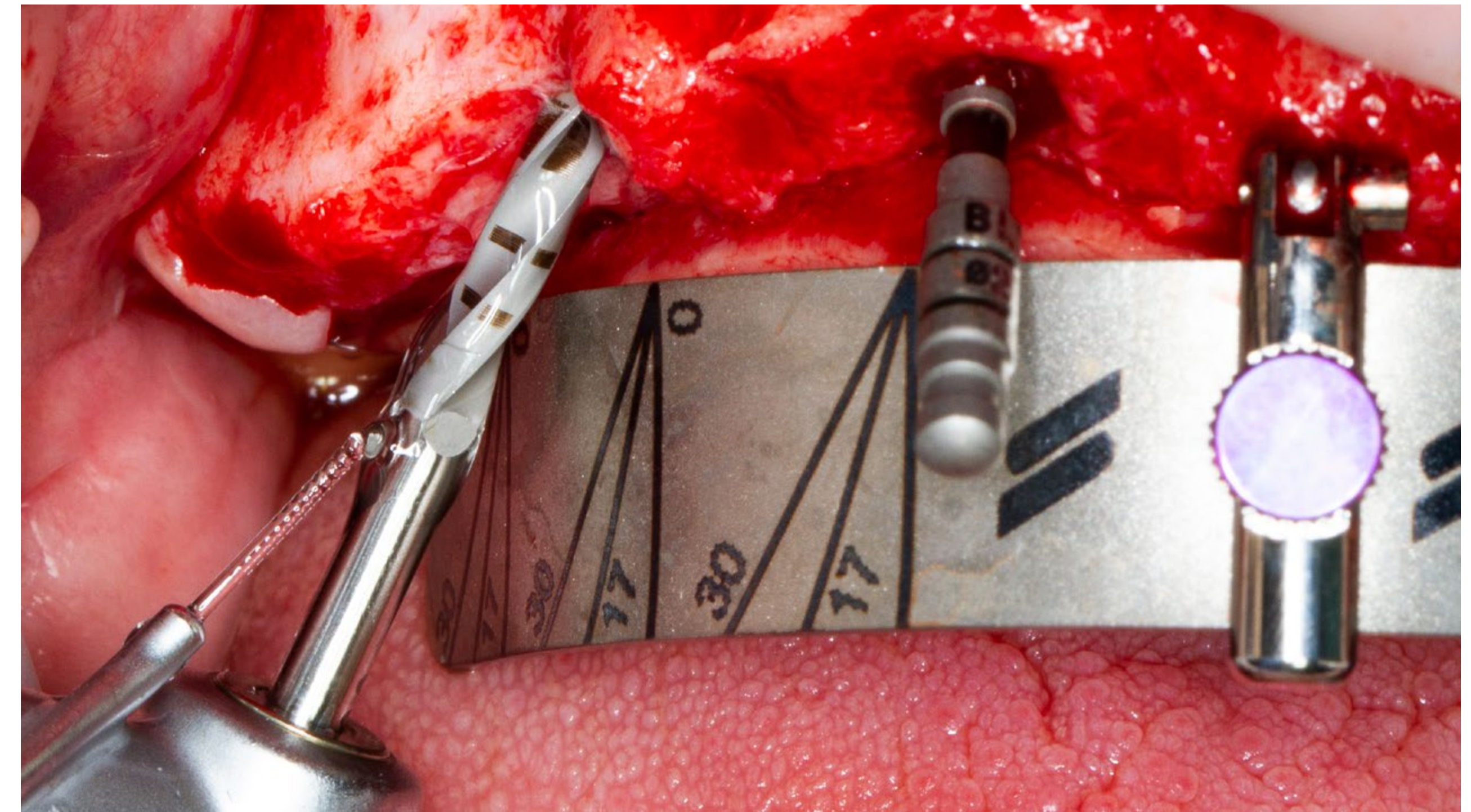


# Challenge 2: Soft bone quality

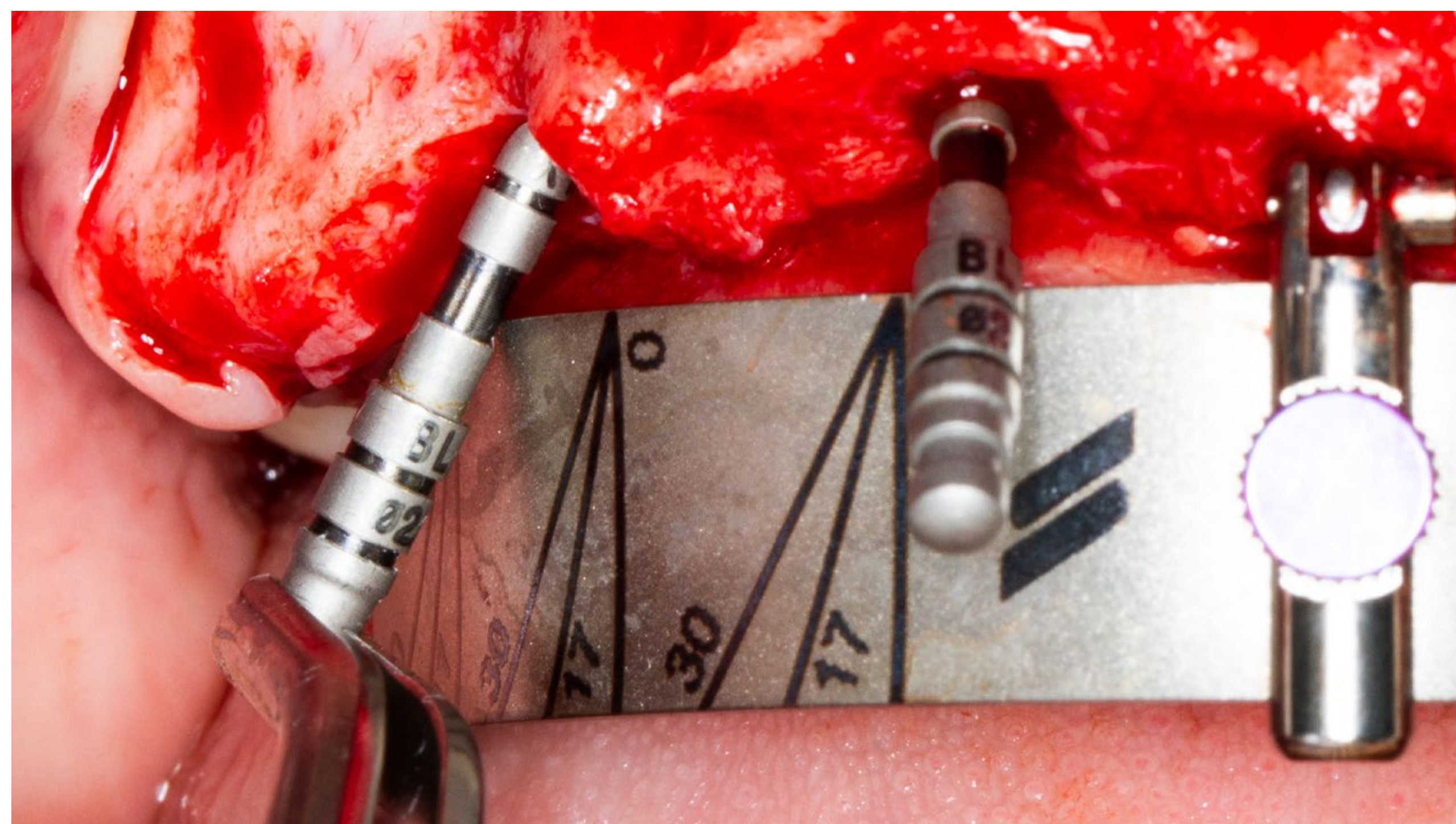
Clinical case



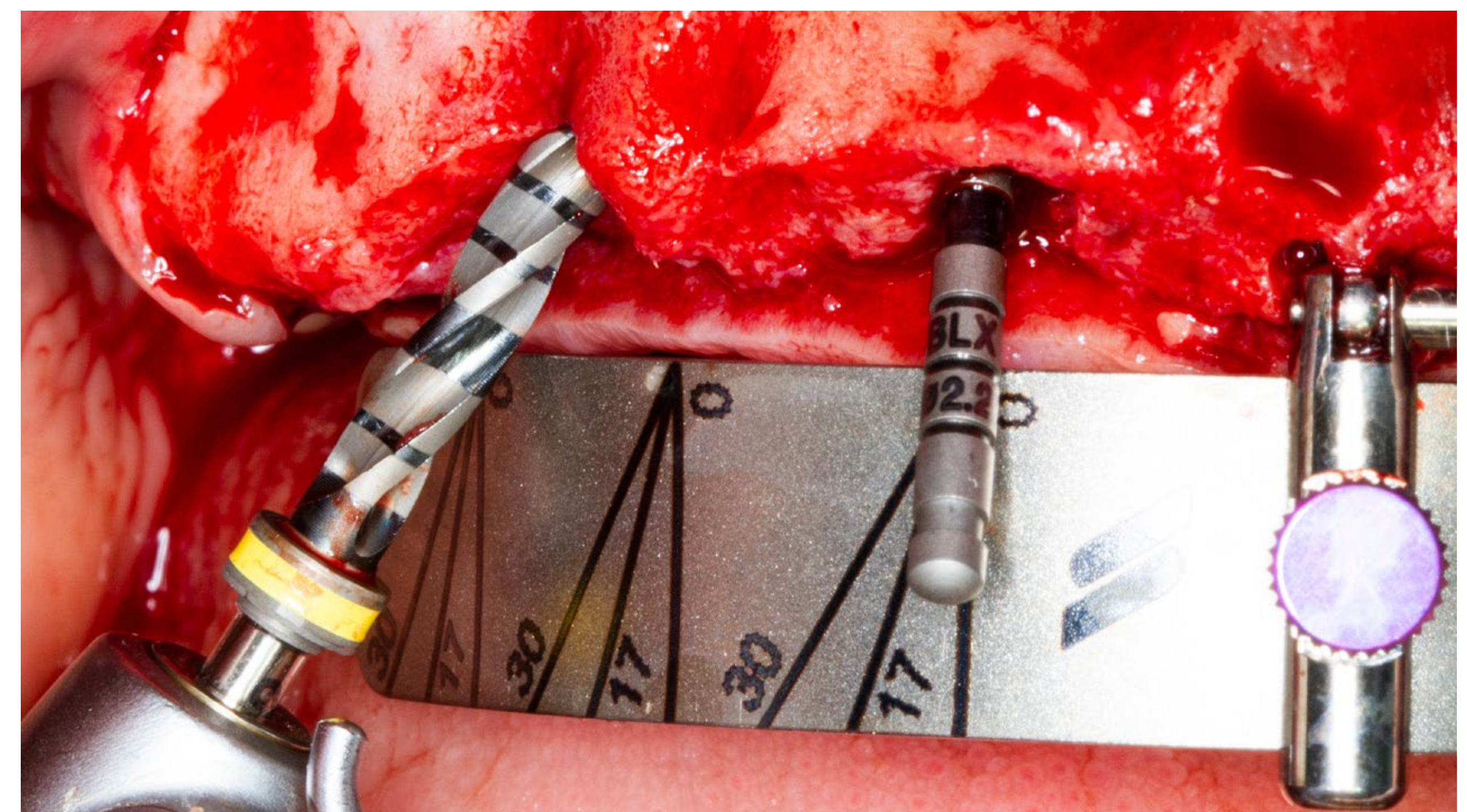
Preparation of angulated implant sites for posterior osteotomy to increase the A-P spread  
Needle Drill  $\varnothing$  1.6 mm



Preparation of posterior implant sites  
Pilot Drill  $\varnothing$  2.2 mm



Preparation of posterior implant sites  
Alignment Pin  $\varnothing$  2.2 mm

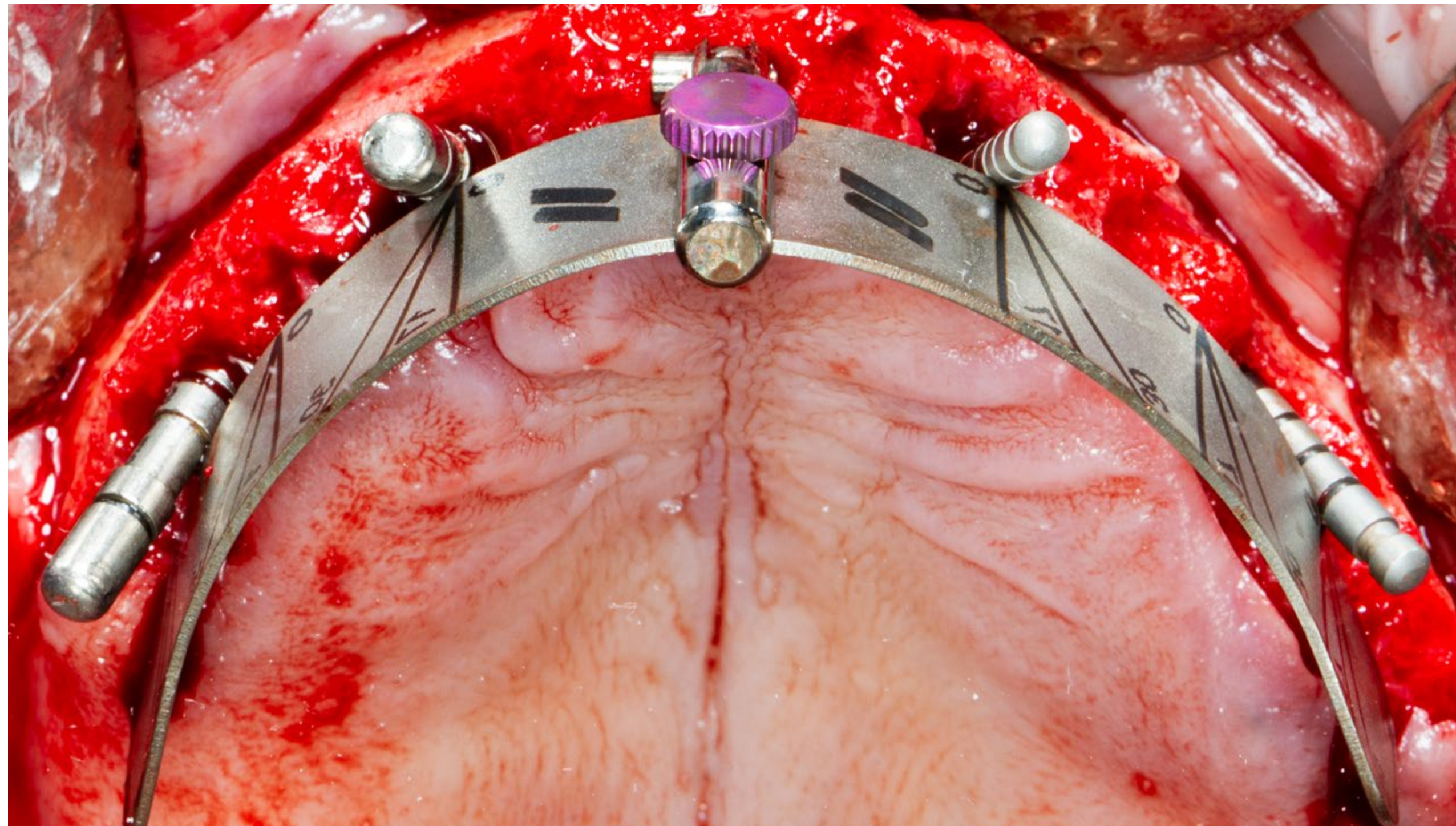


Preparation of posterior implant sites  
Drill  $\varnothing$  2.8 mm

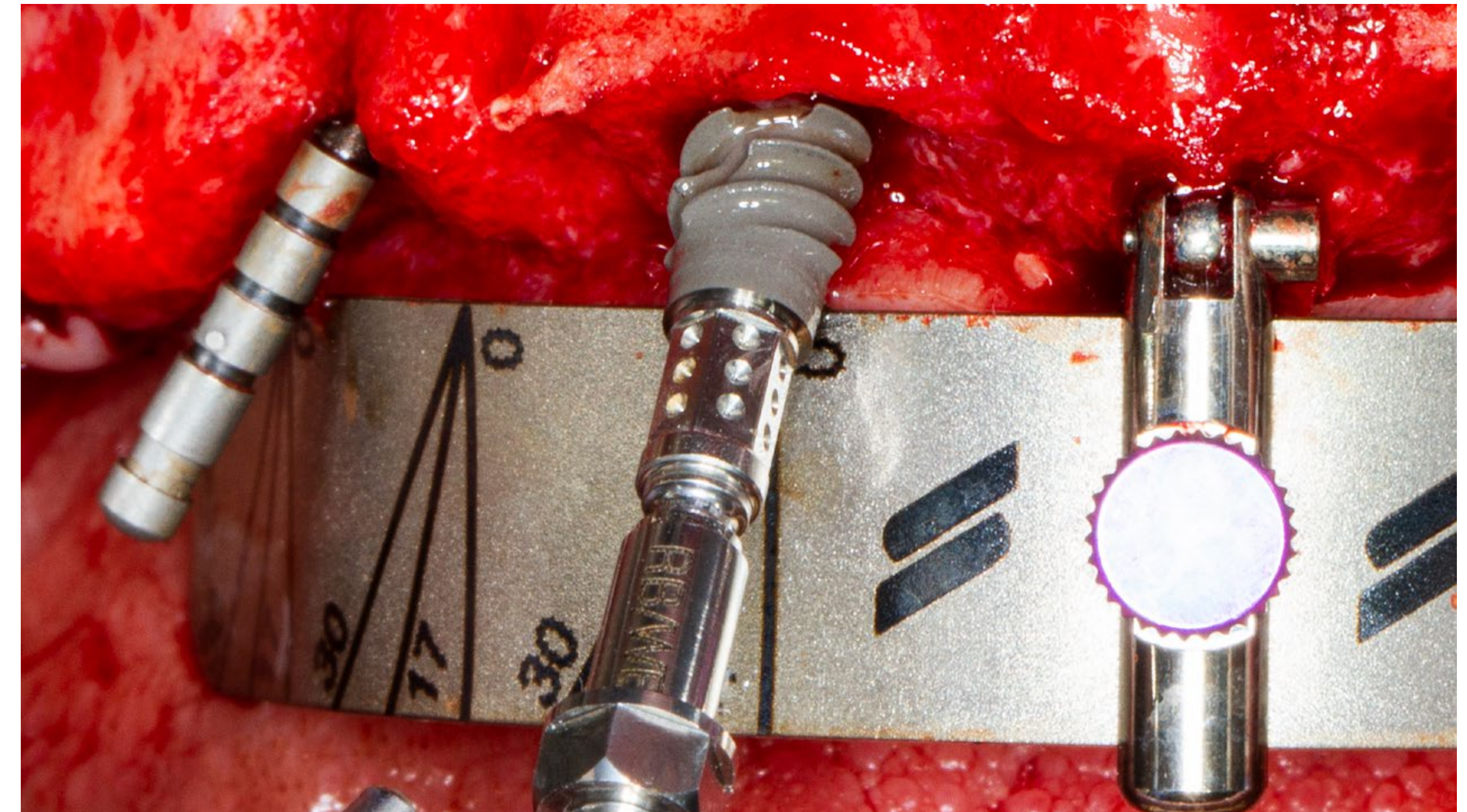


# Challenge 2: Soft bone quality

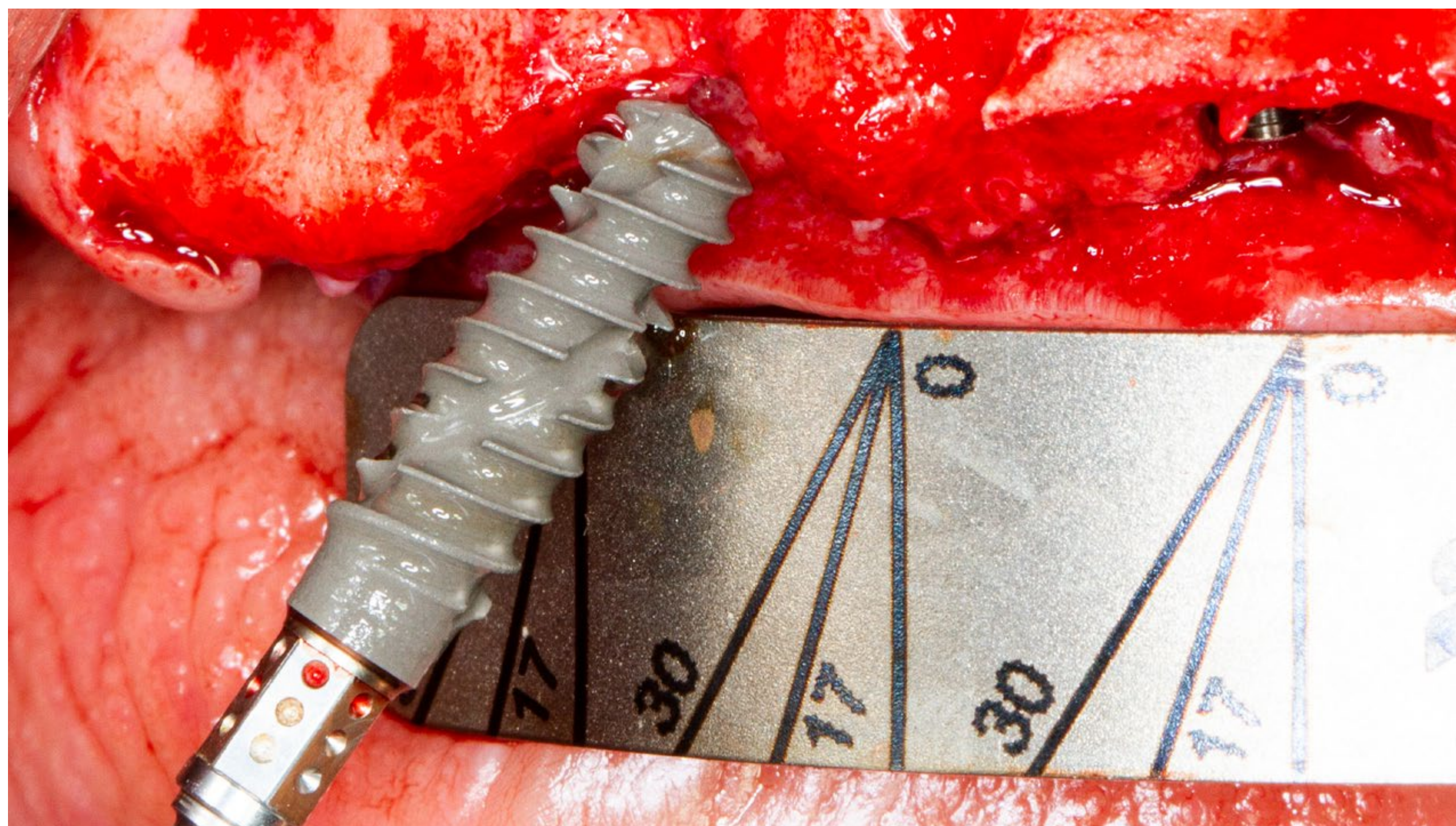
Clinical case



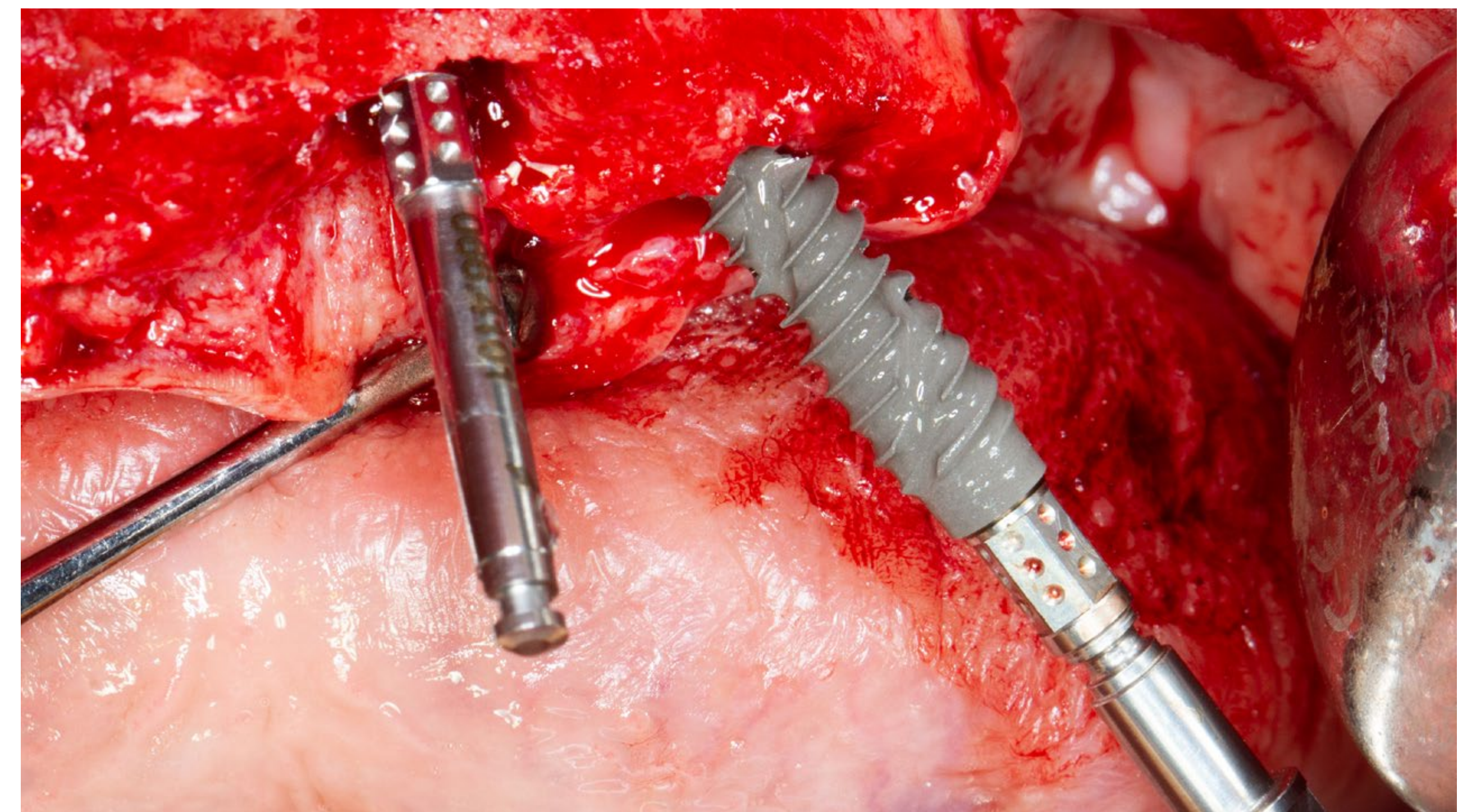
Alignment of the implant sites



Placement of the Straumann® BLX Ø 4.5 mm RB SLActive® 14 mm Roxolid® implant with a torque of 35 Ncm



Placement of the Straumann® BLX Ø 4.5 mm RB SLActive® 14 mm Roxolid® implant with a torque of 35 Ncm

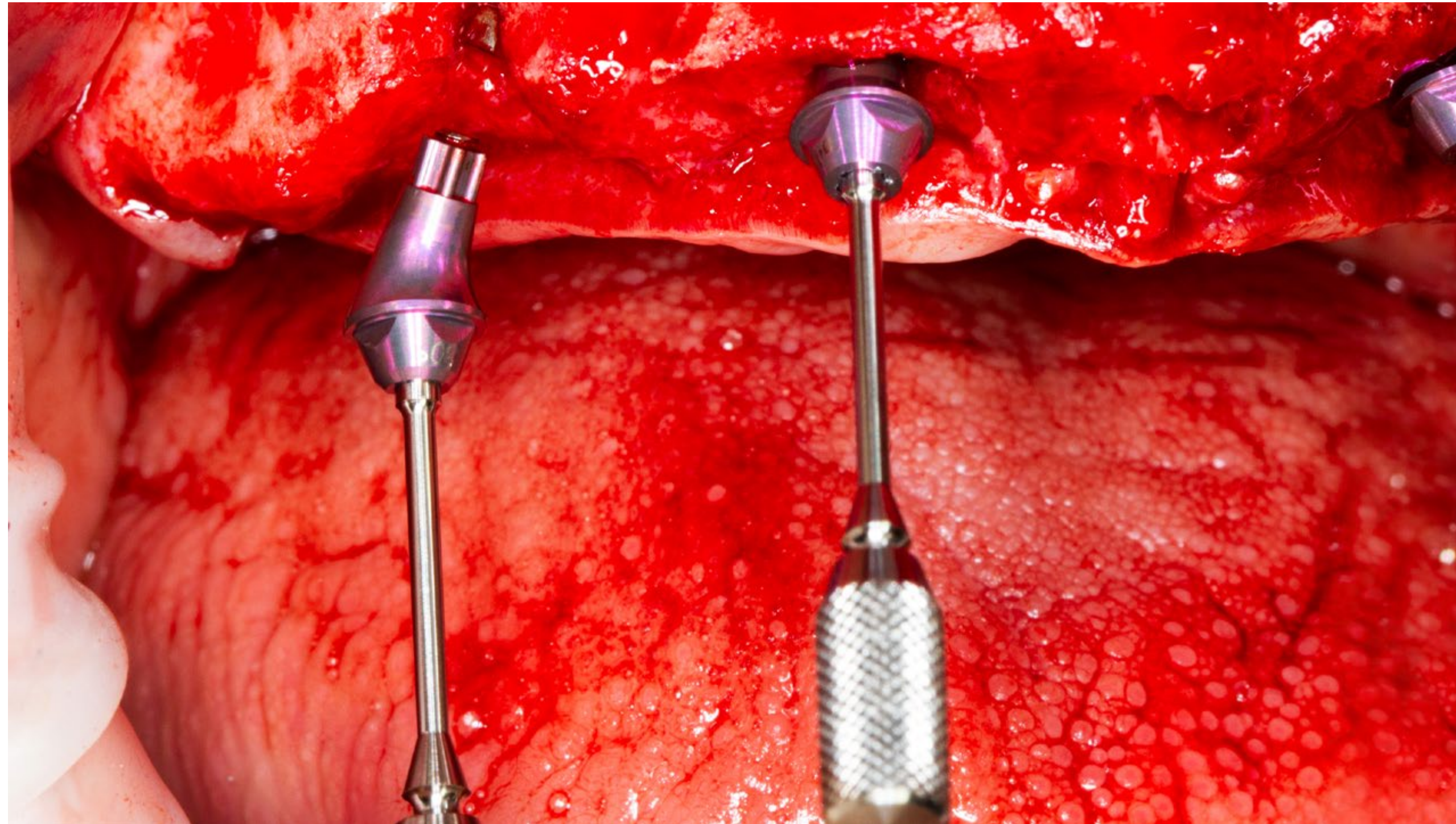


Placement of the Straumann® BLX Ø 4.5 mm RB SLActive® 14 mm Roxolid® implant with a torque of 35 Ncm

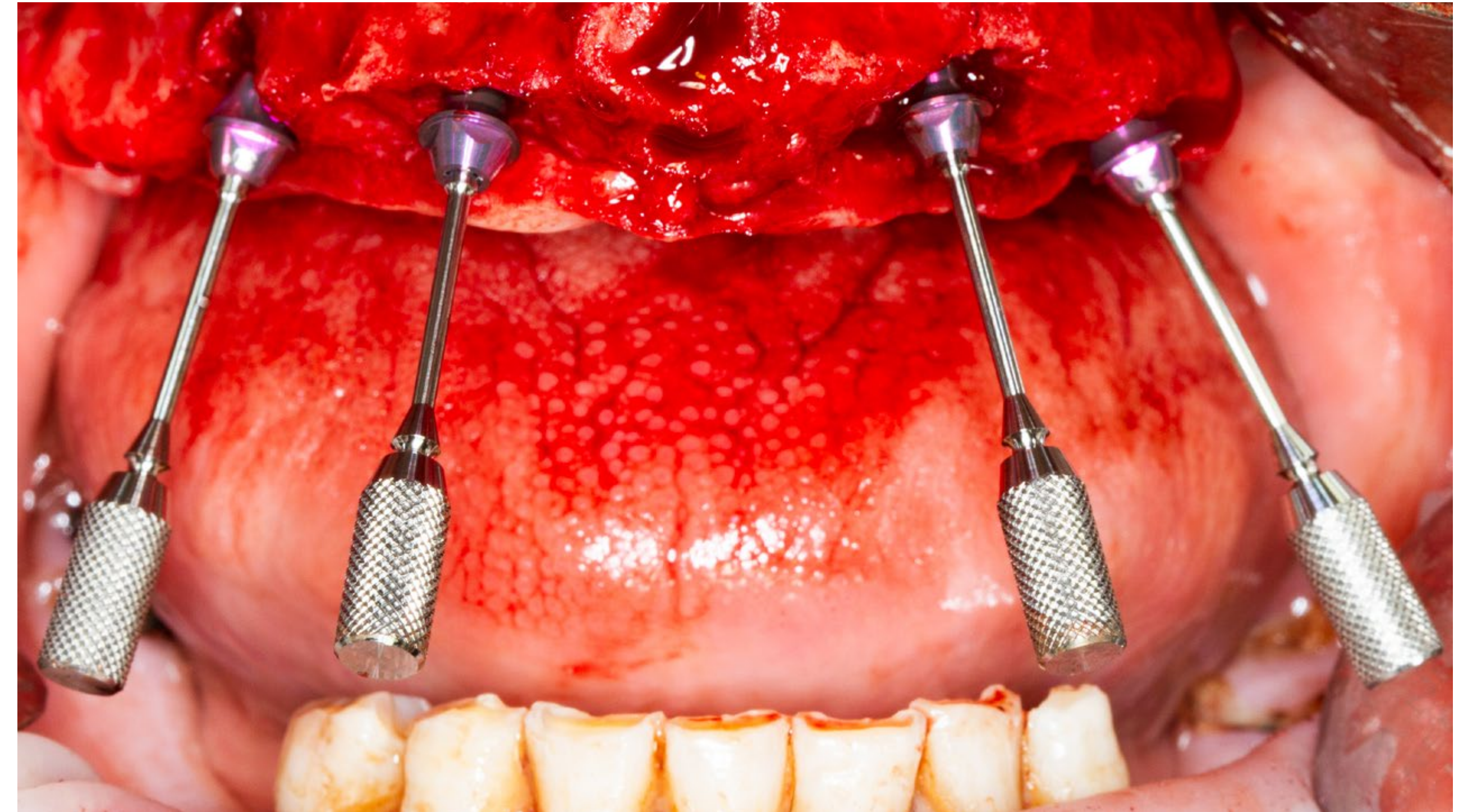


# Challenge 2: Soft bone quality

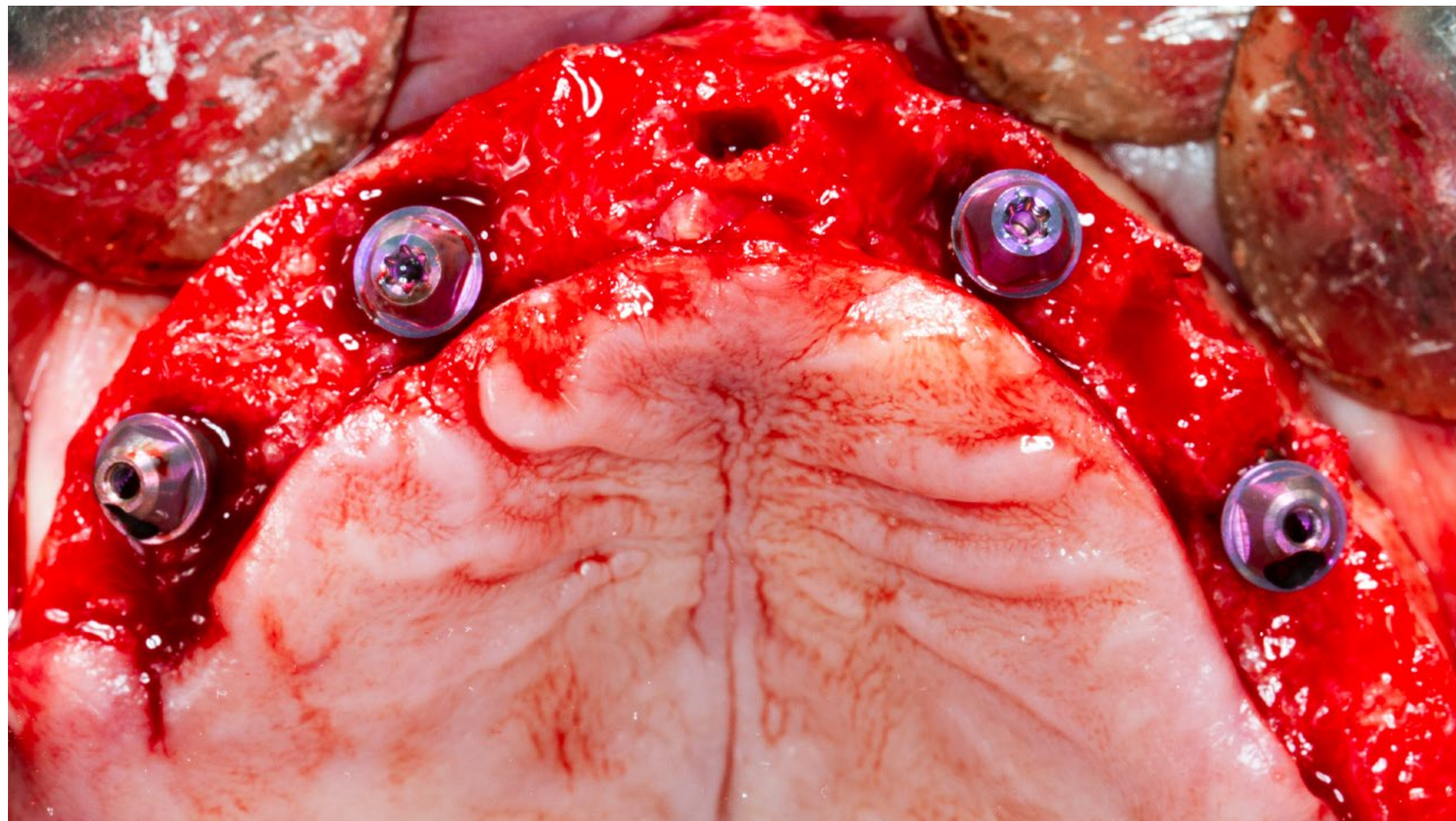
Clinical case



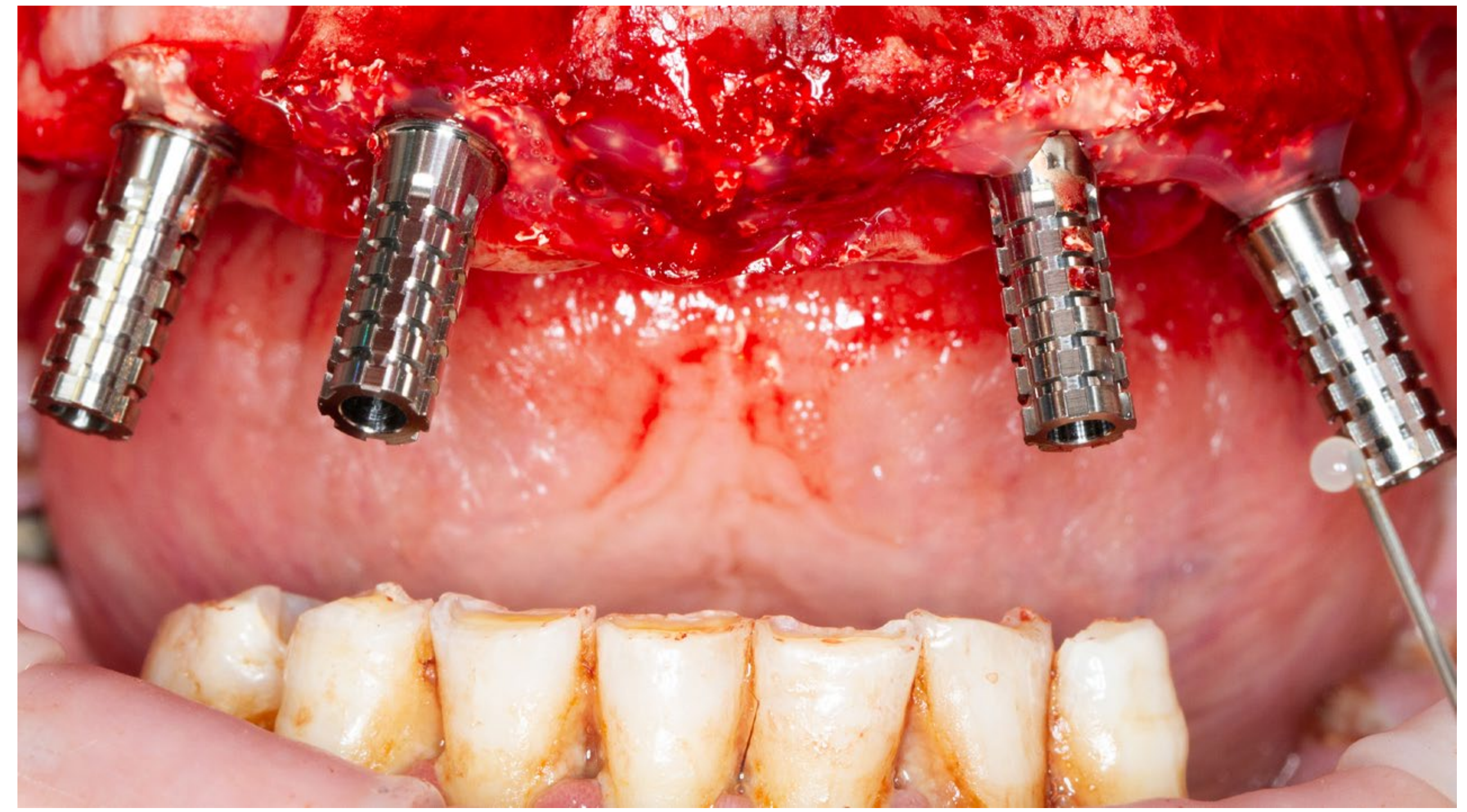Placement of the Screw-retained Abutments



Screw-retained Abutments in place



Screw-retained Abutments in place  
Occlusal view

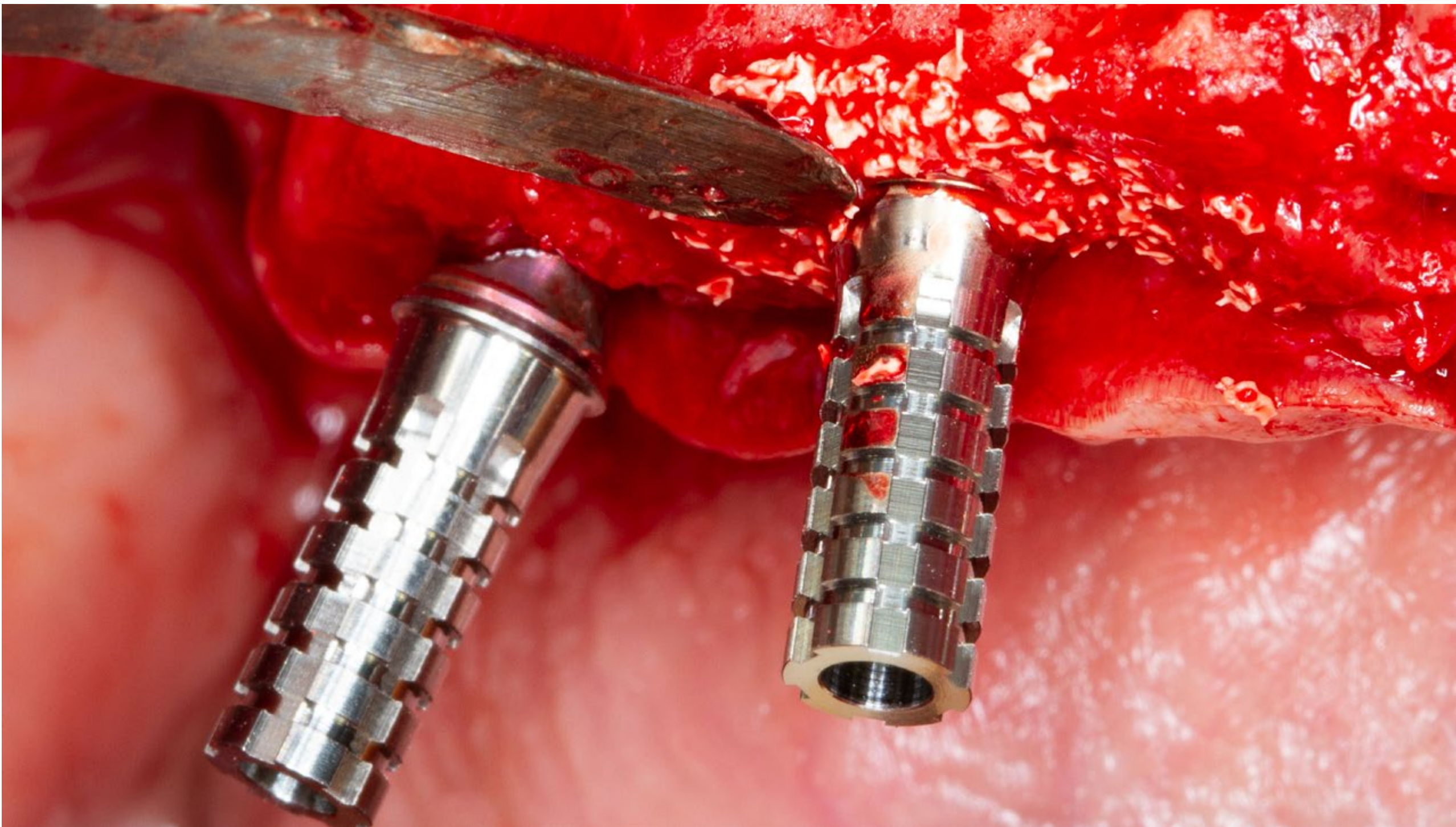

Placement of non-engaging Titanium Copings on the anterior and posterior abutments

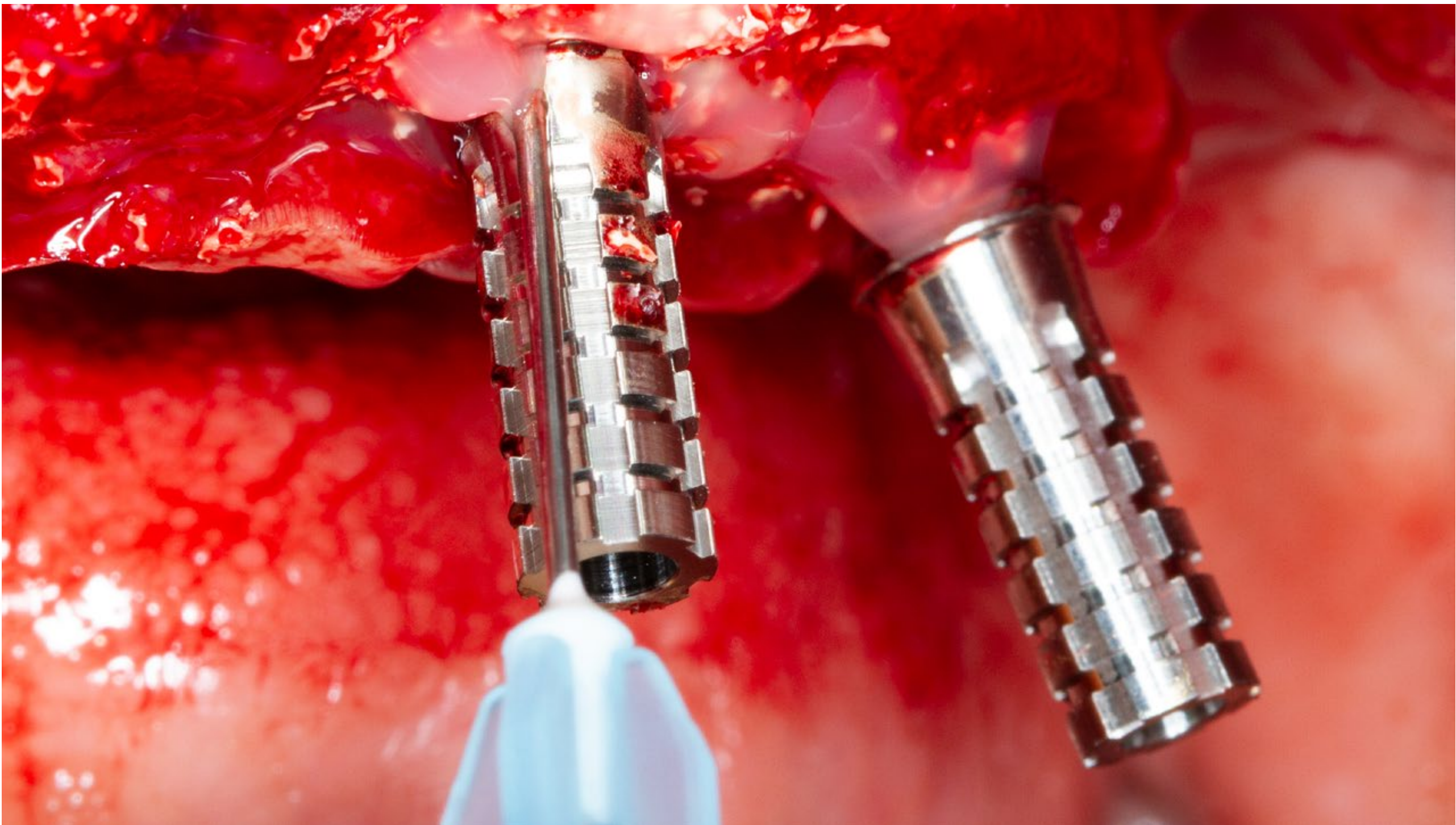


# Challenge 2: Soft bone quality

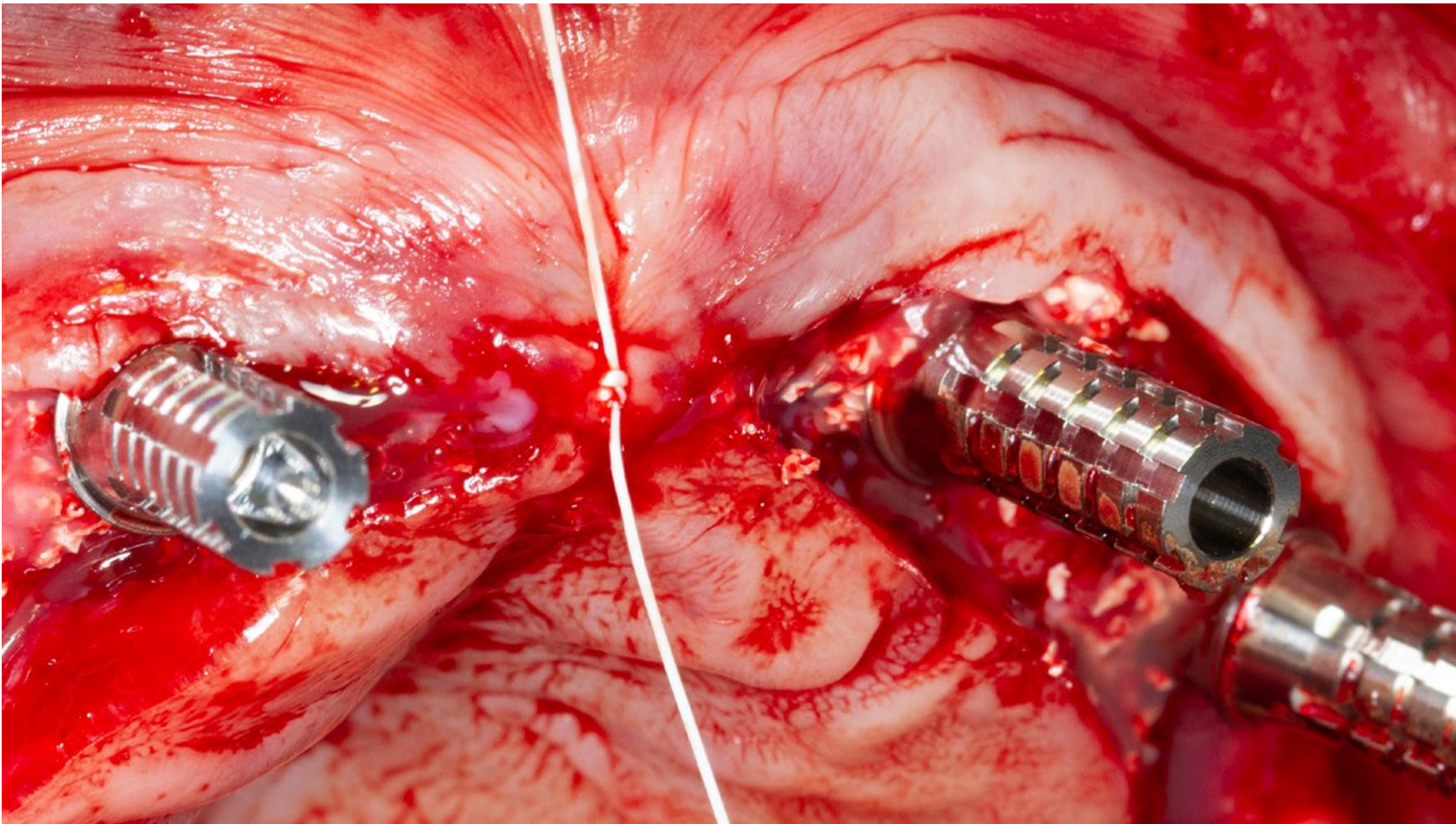
Clinical case



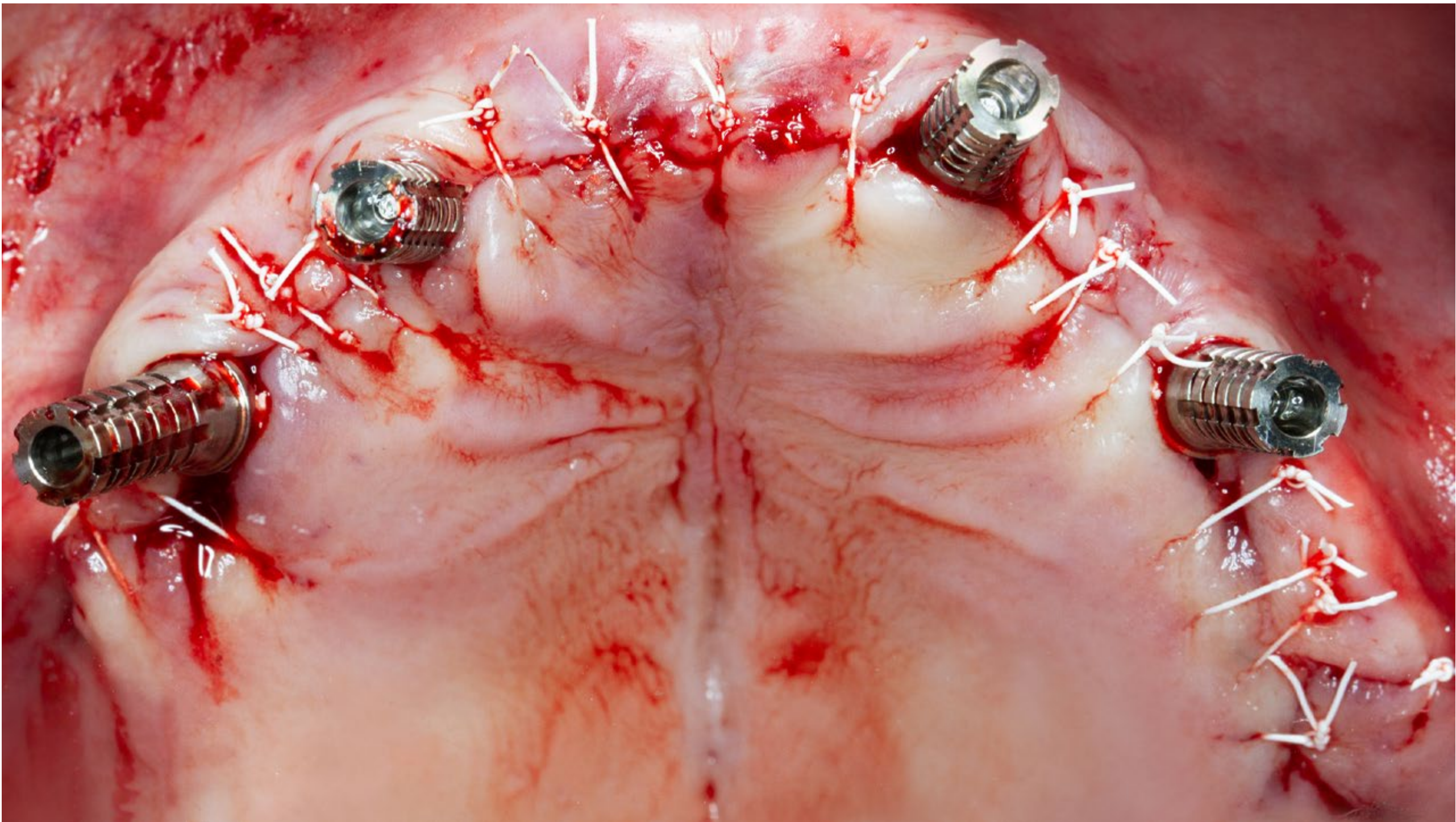
Placement of the cerabone® granules and Jason® membrane



Placement of Straumann® Emdogain® around implants



Suture

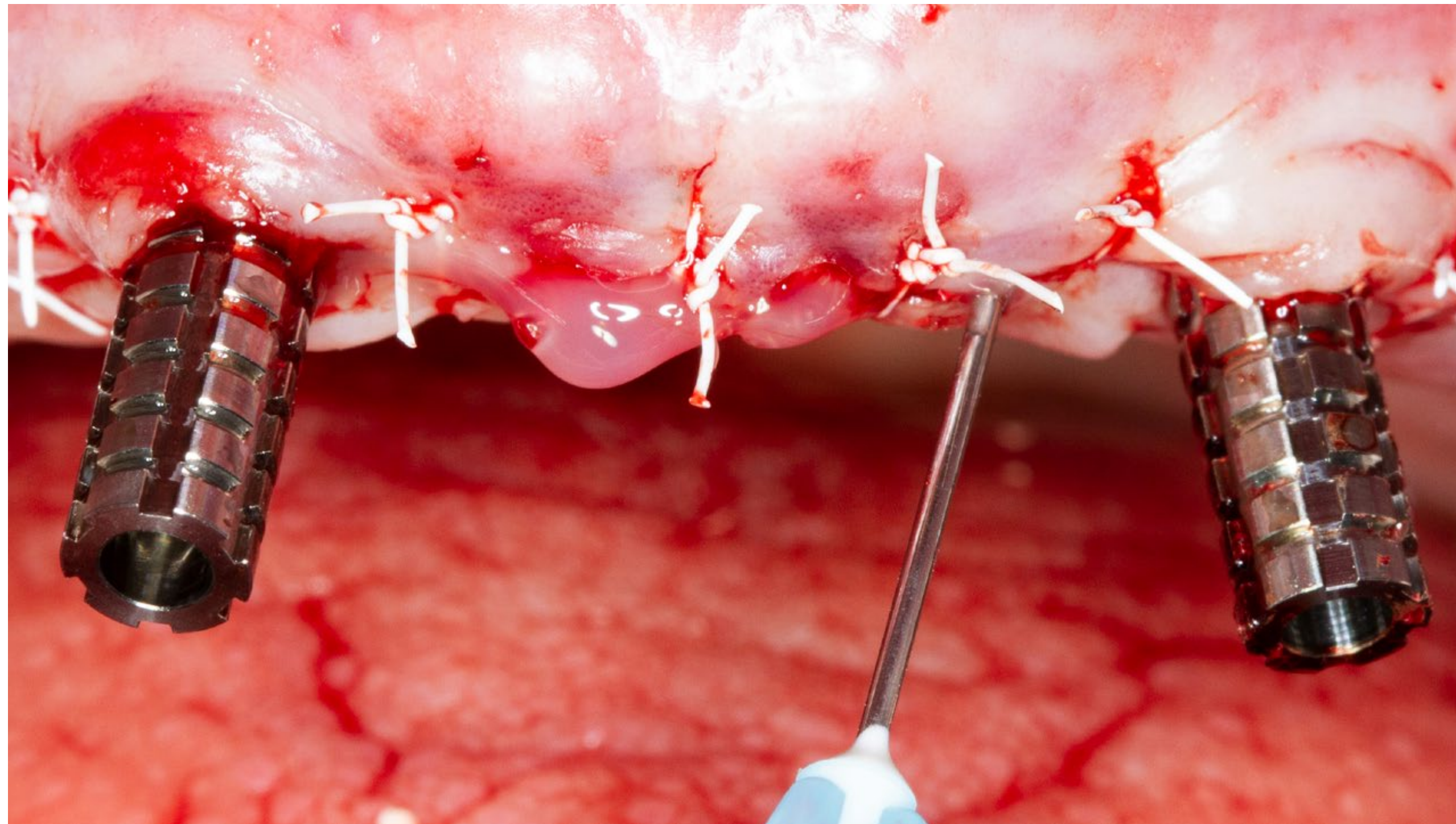


Sutured site

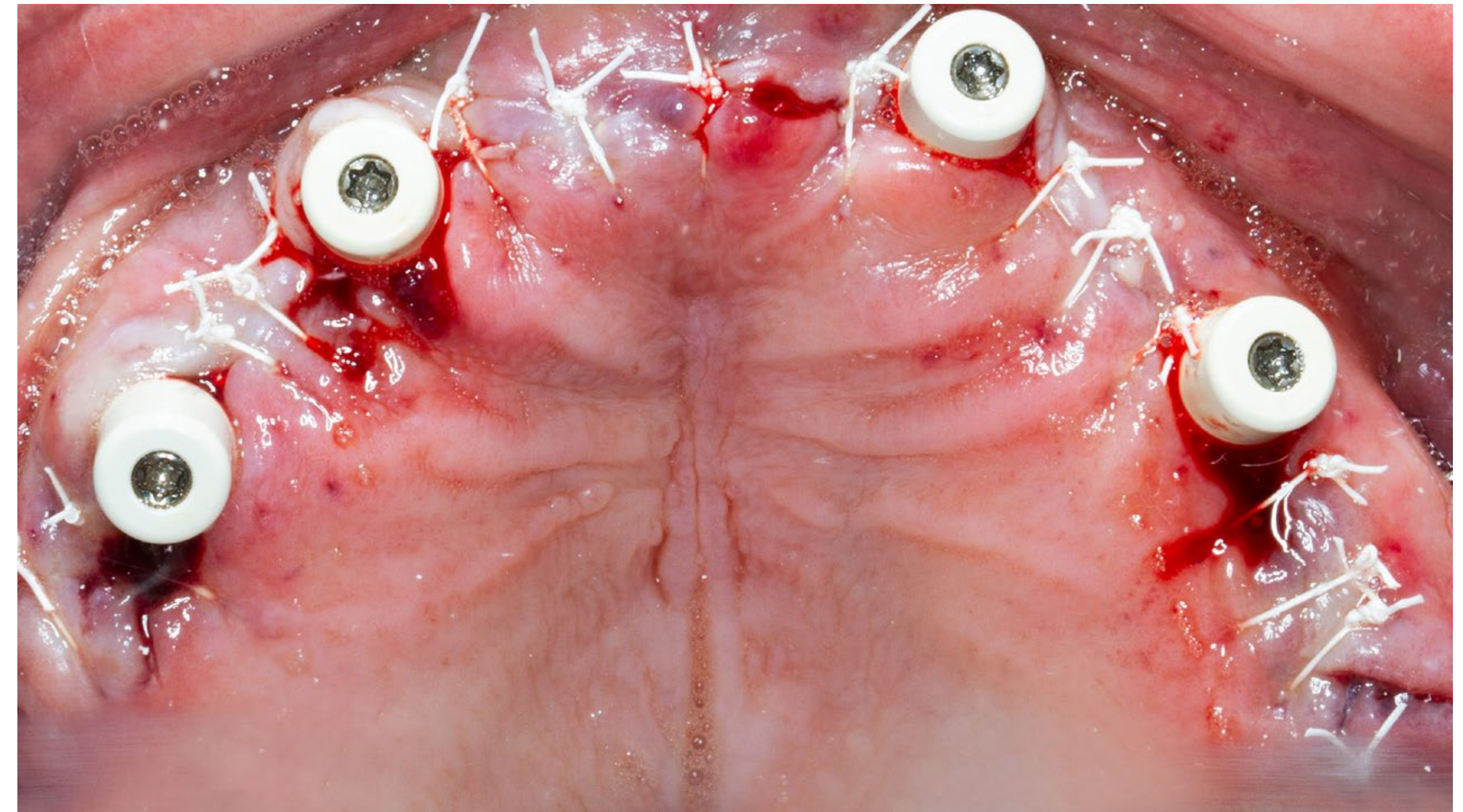


# Challenge 2: Soft bone quality

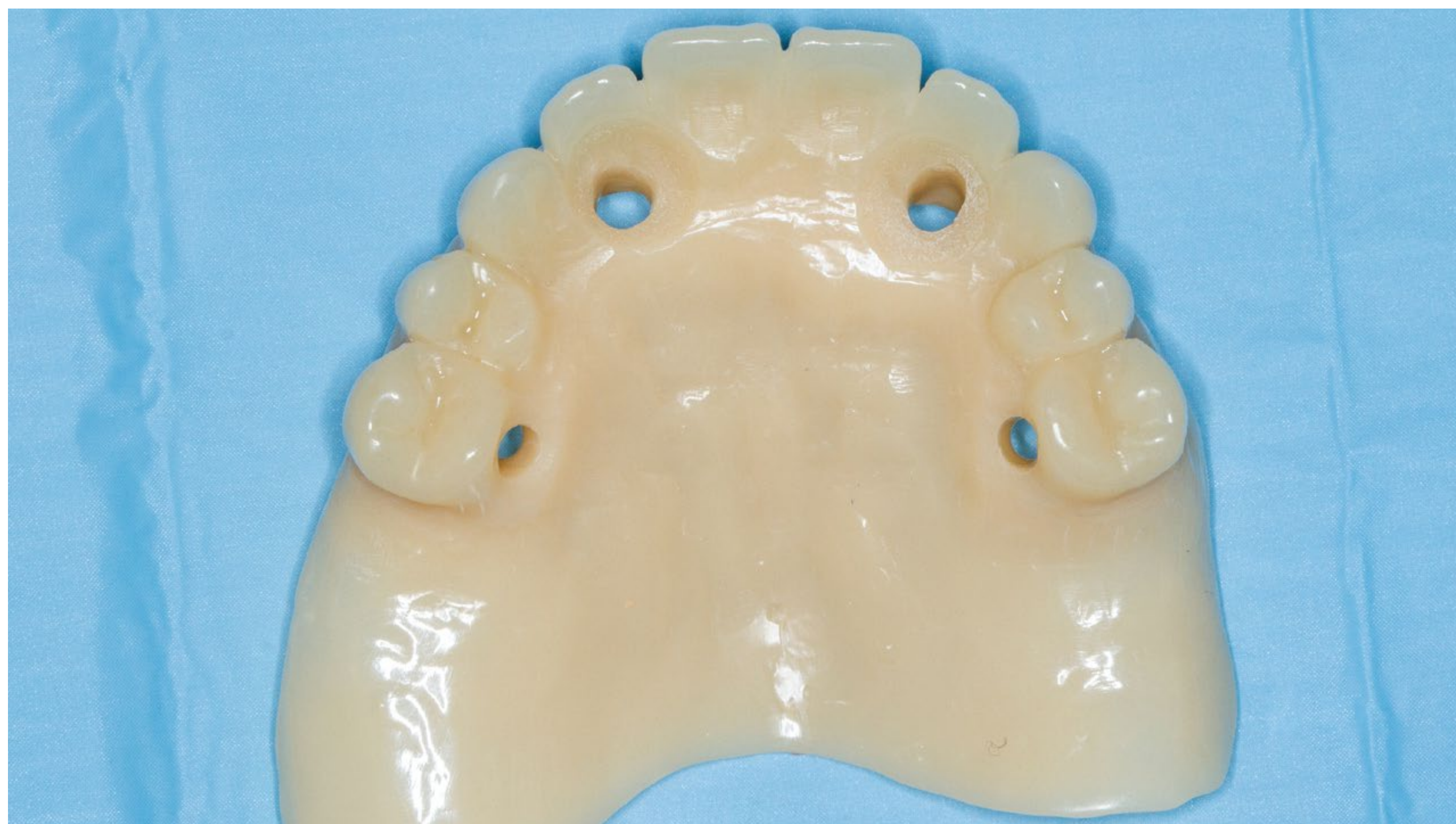Clinical case



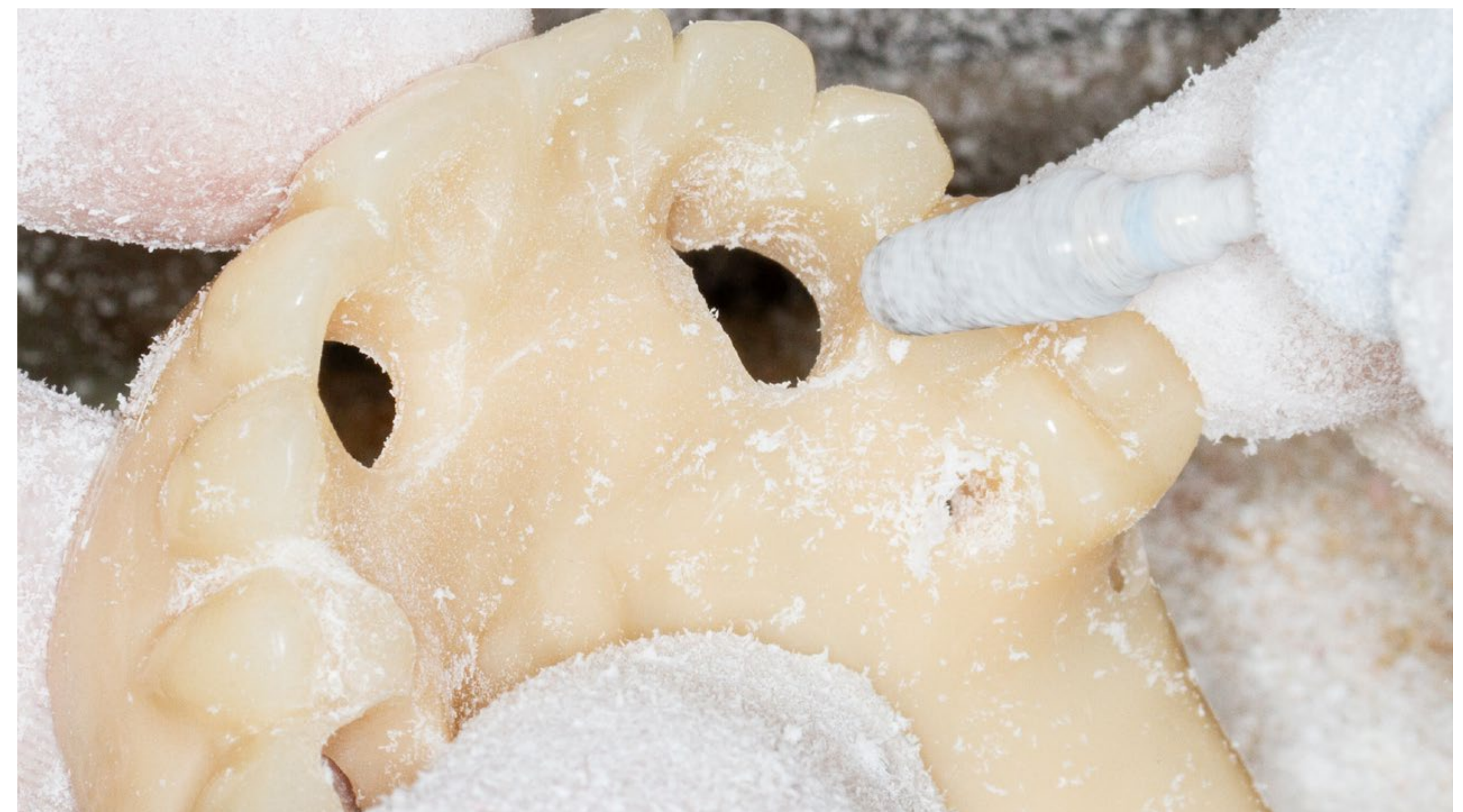Placement of Straumann® Emdogain® after flap closure



Protective Caps Ø 4.6 mm in place



Duplication of the old prosthesis for pick-up

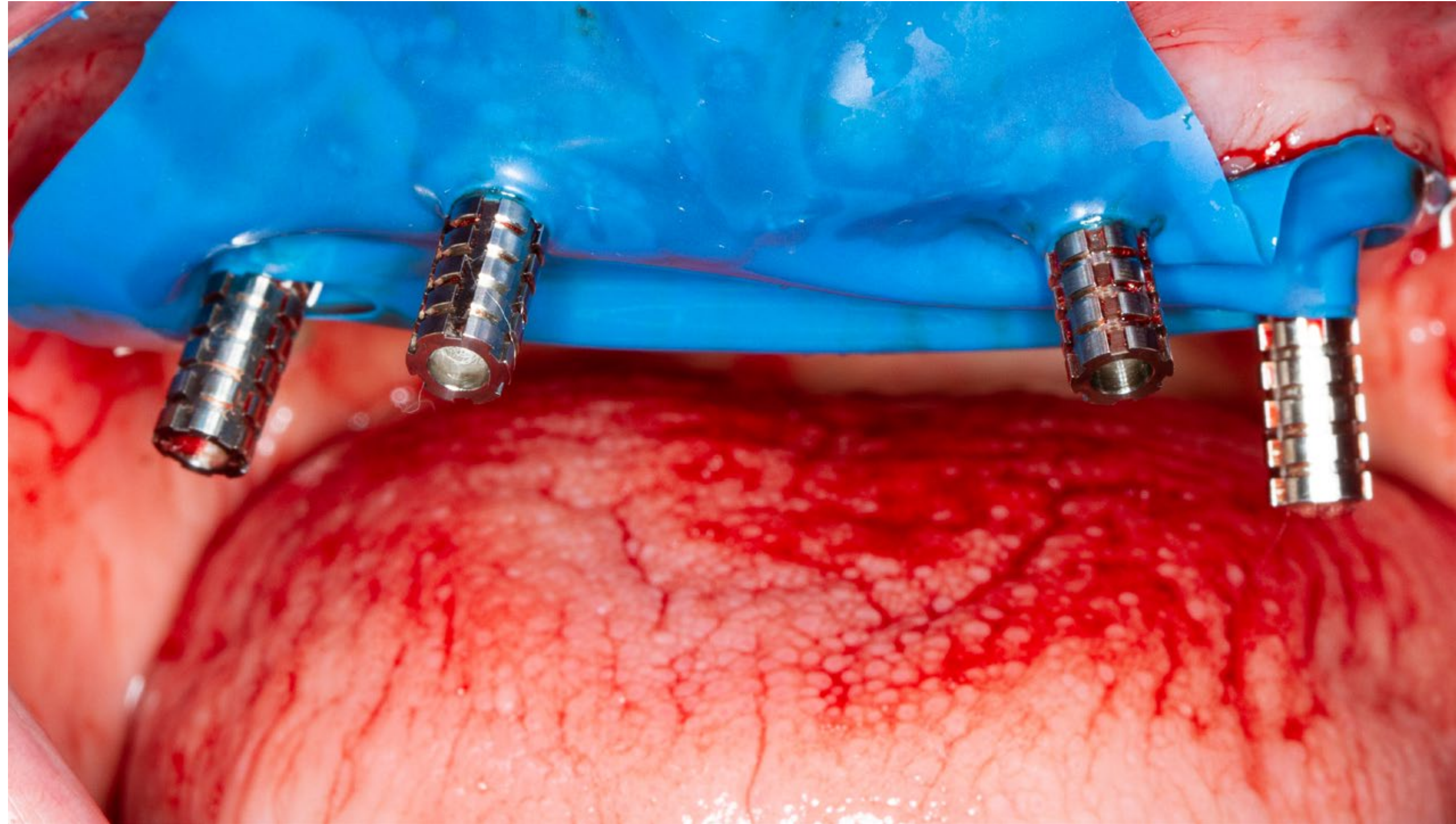


Adjustments of the duplication of the prosthesis to allow passive fit on titanium copings

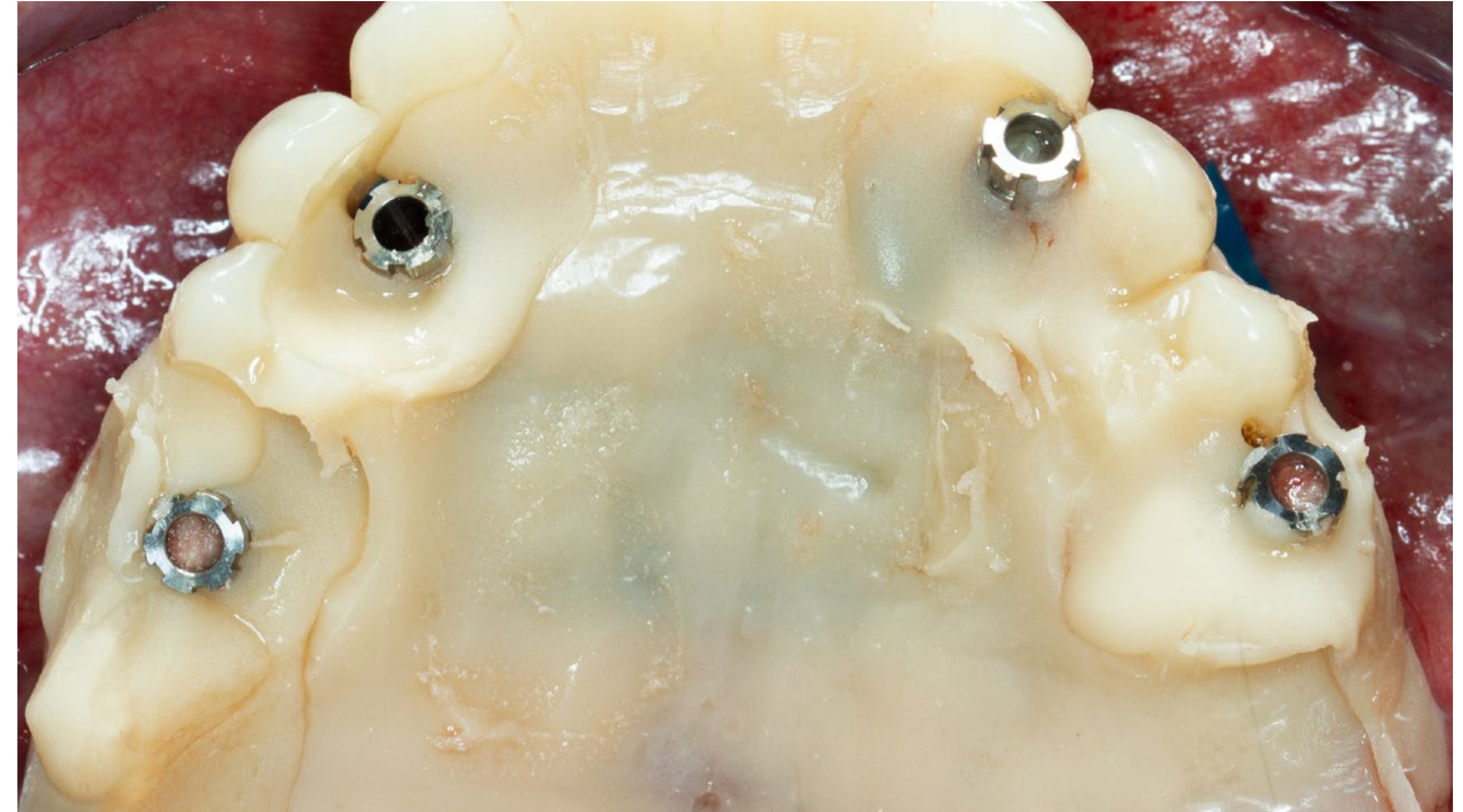


# Challenge 2: Soft bone quality

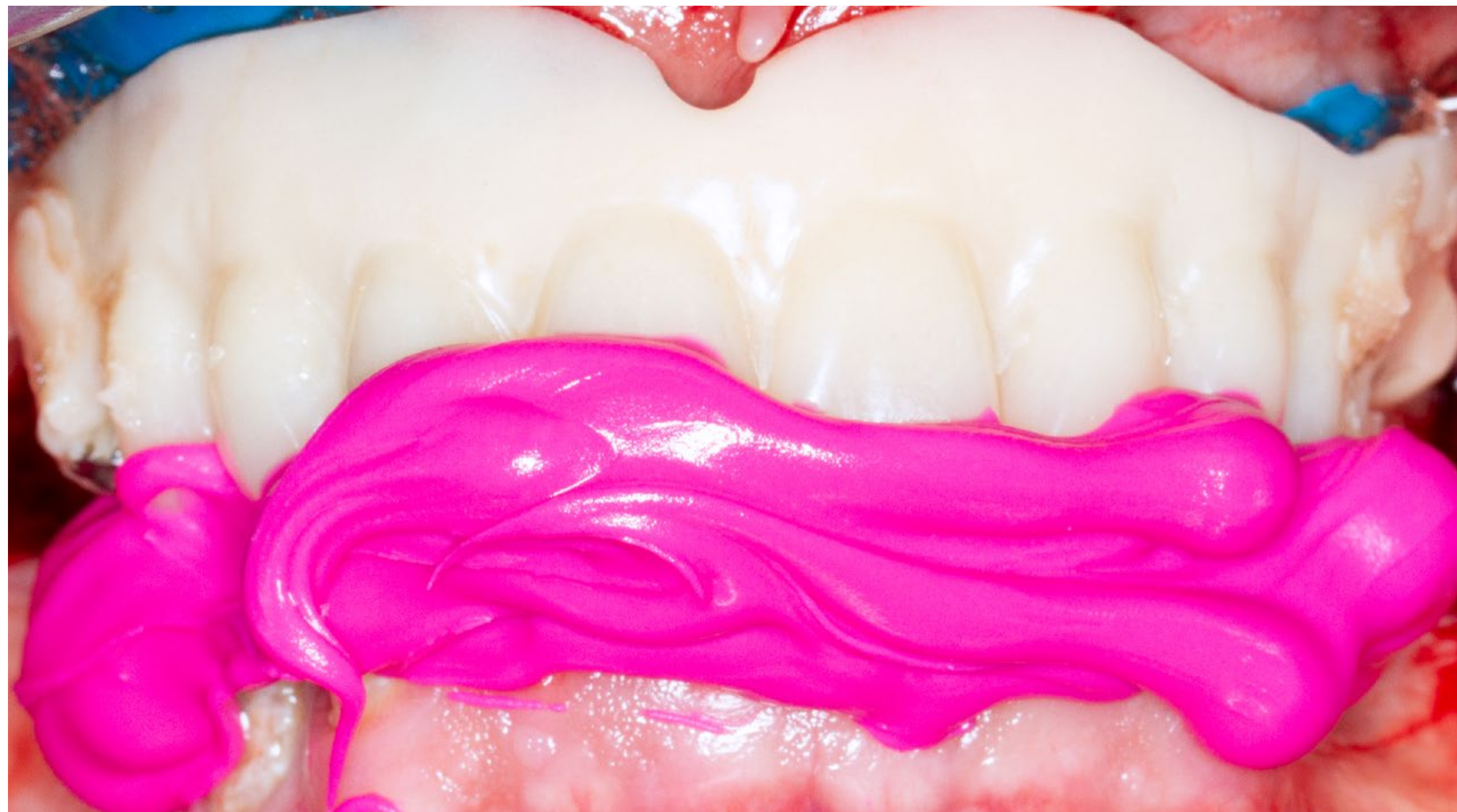Clinical case



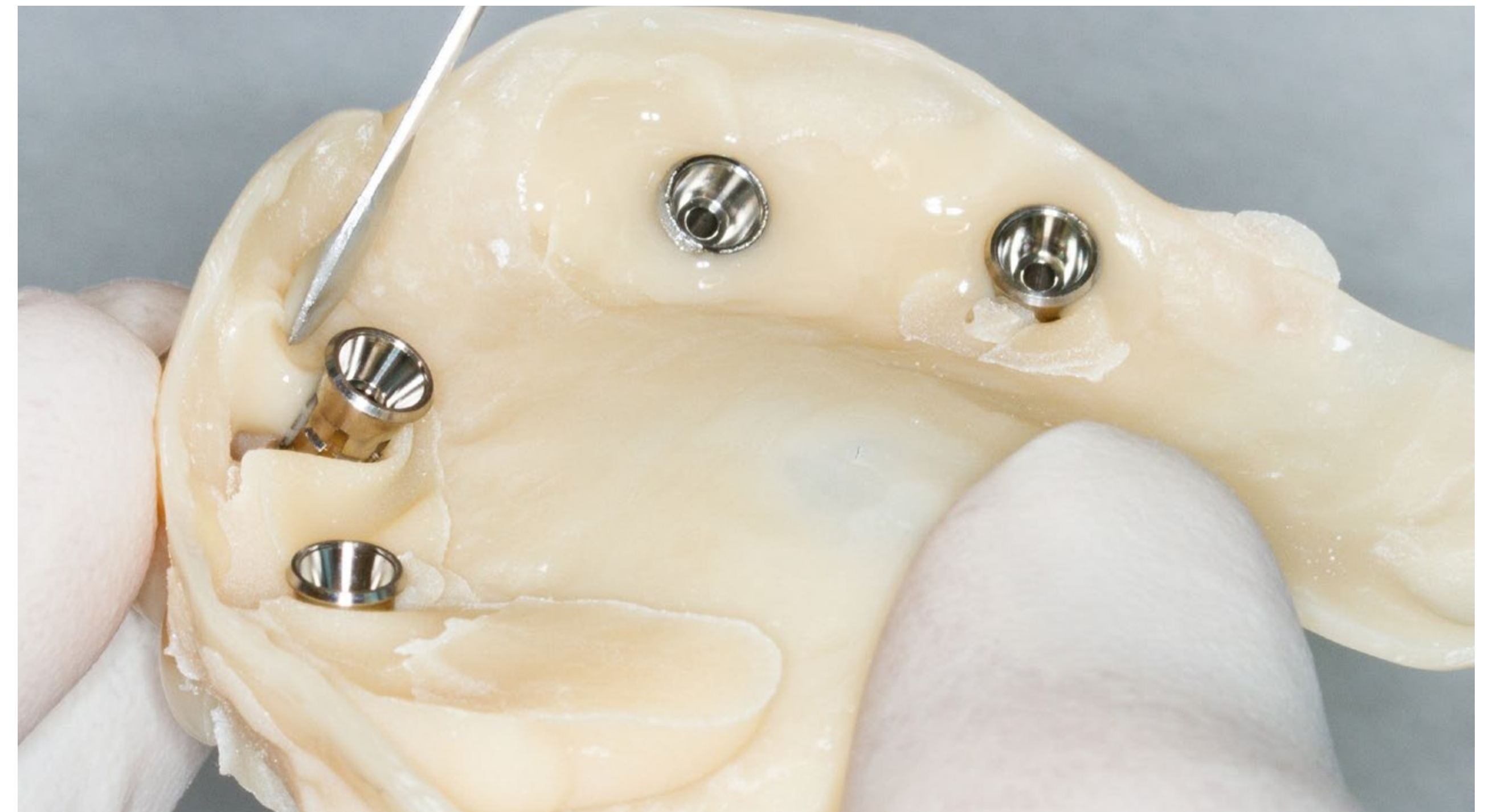Titanium copings in place for pick-up procedure



The provisional prosthesis was attached to the titanium copings



Bite registration

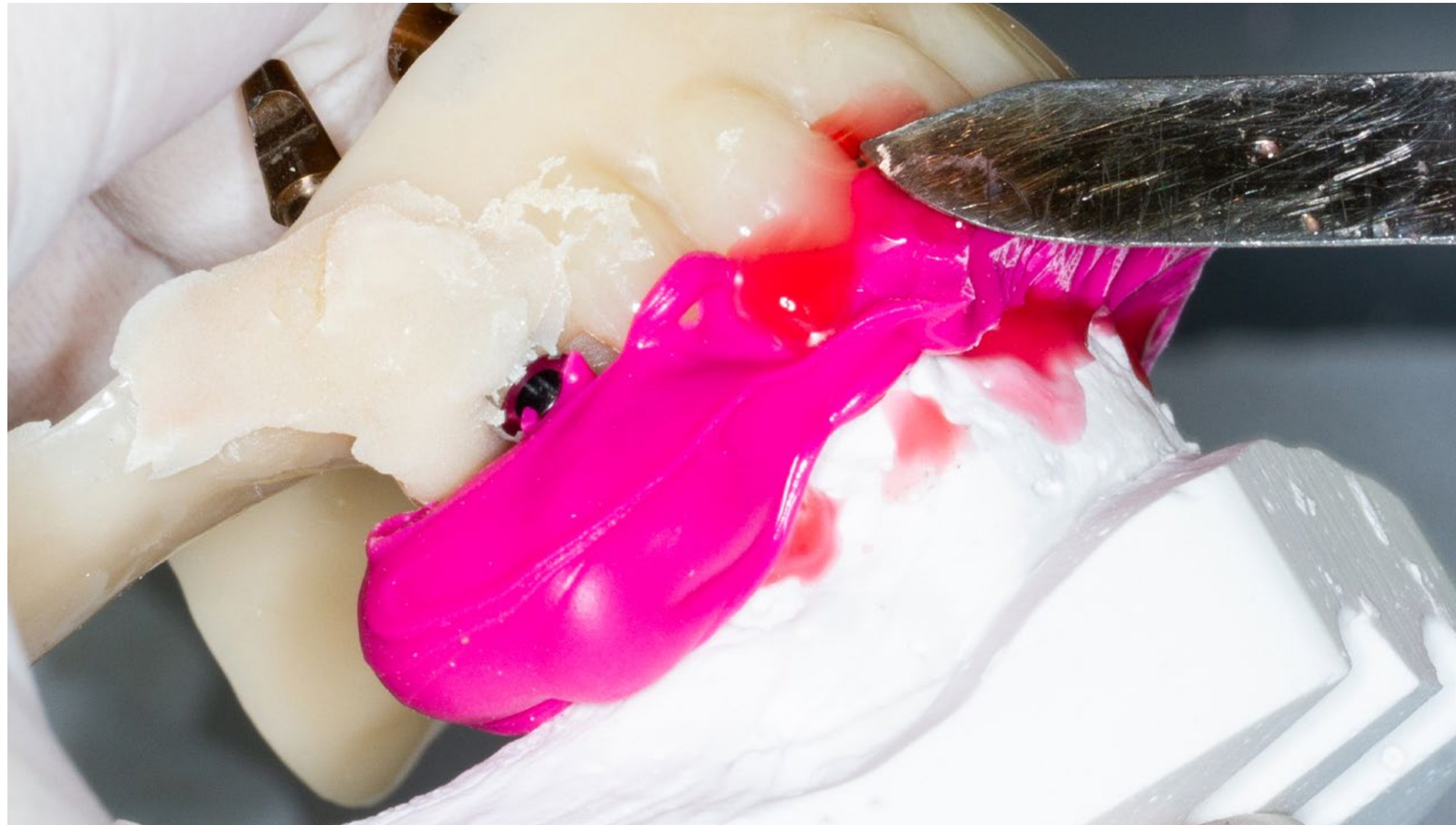

Preparation of the provisional prosthesis  
Filling gaps with acrylic

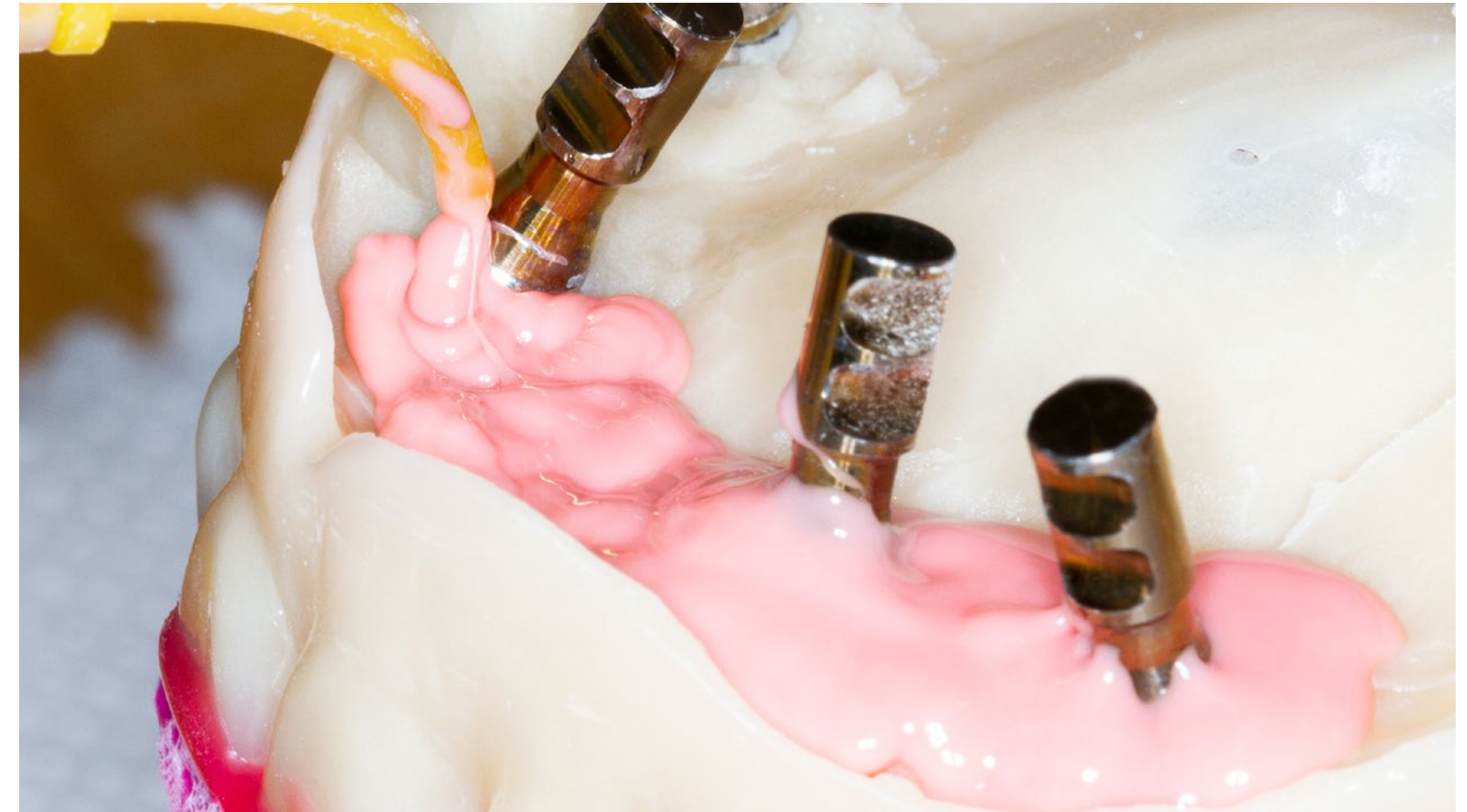

# Challenge 2: Soft bone quality

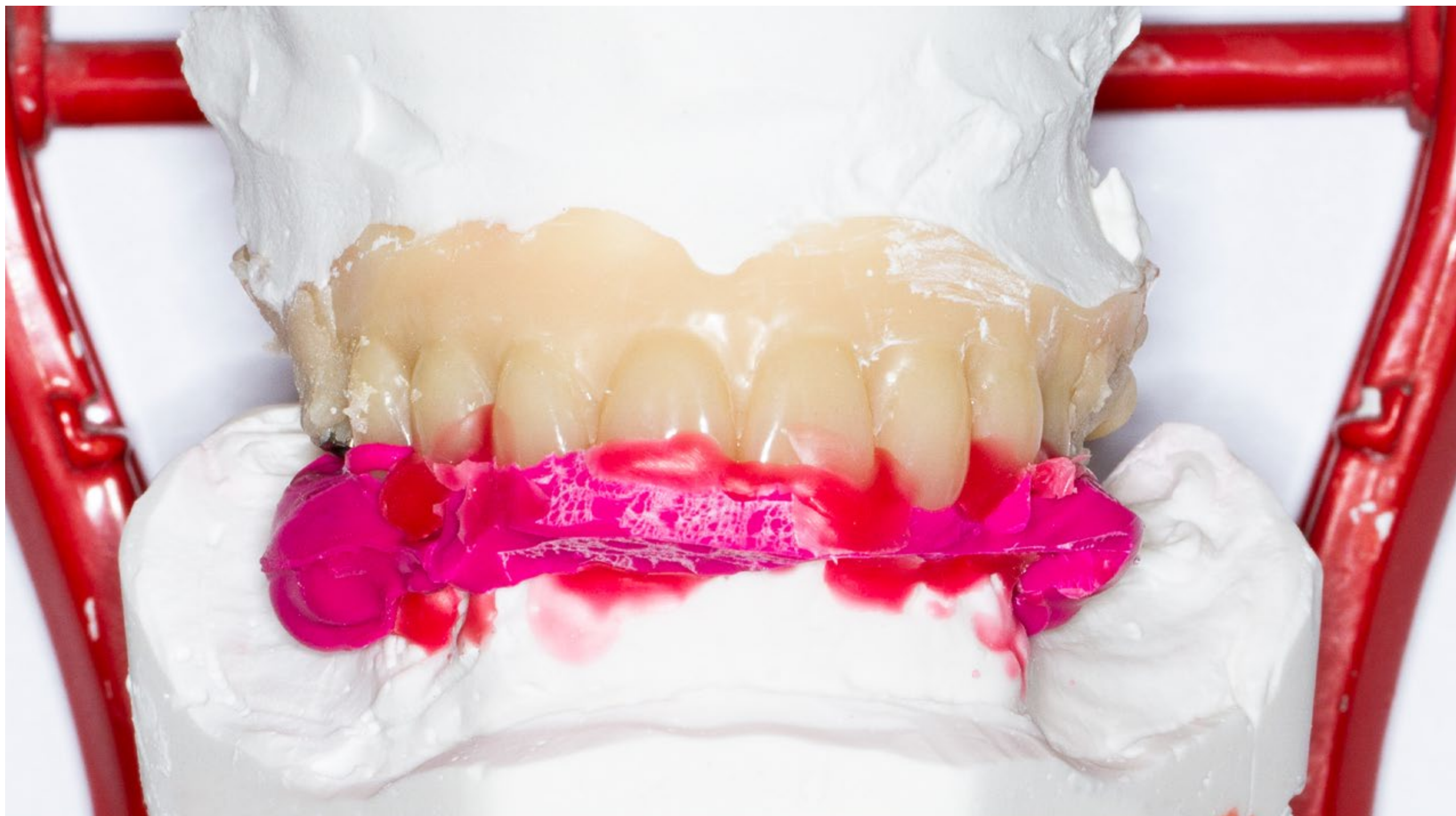Clinical case



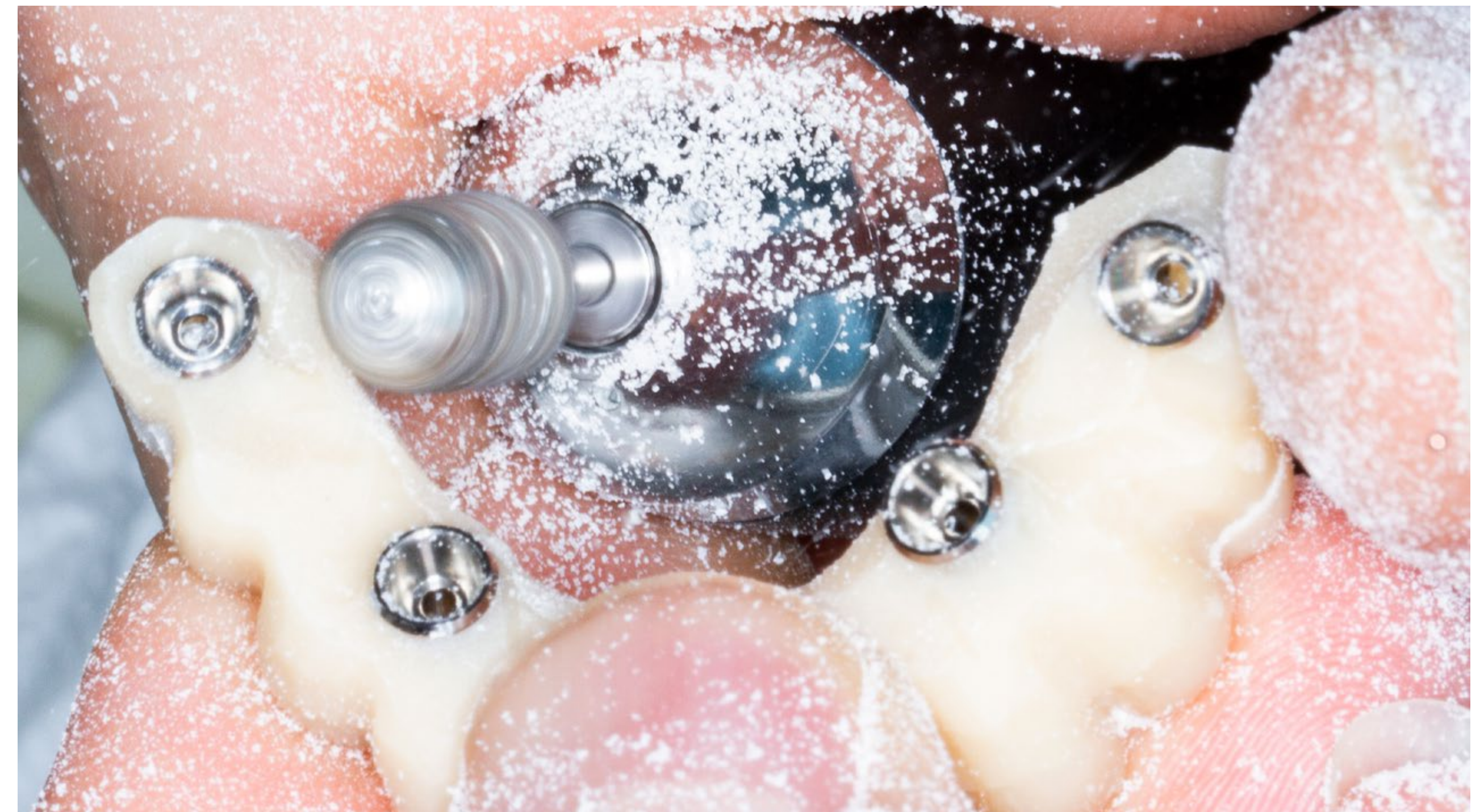Bite registration adapted



Placement of the gingival mask around implant analogs



Placement of the casts on the articulator

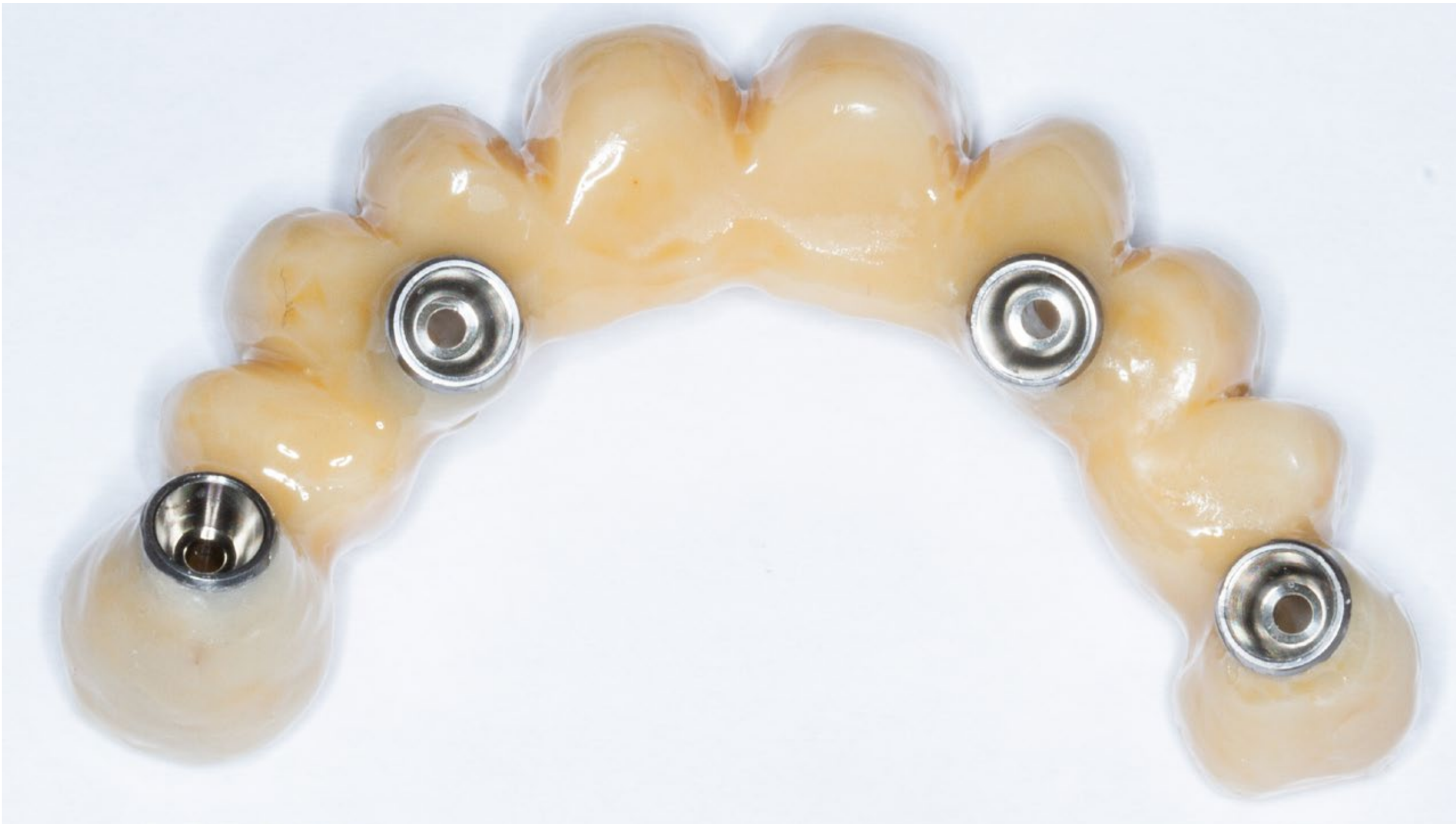

Preparation of the provisional prosthesis

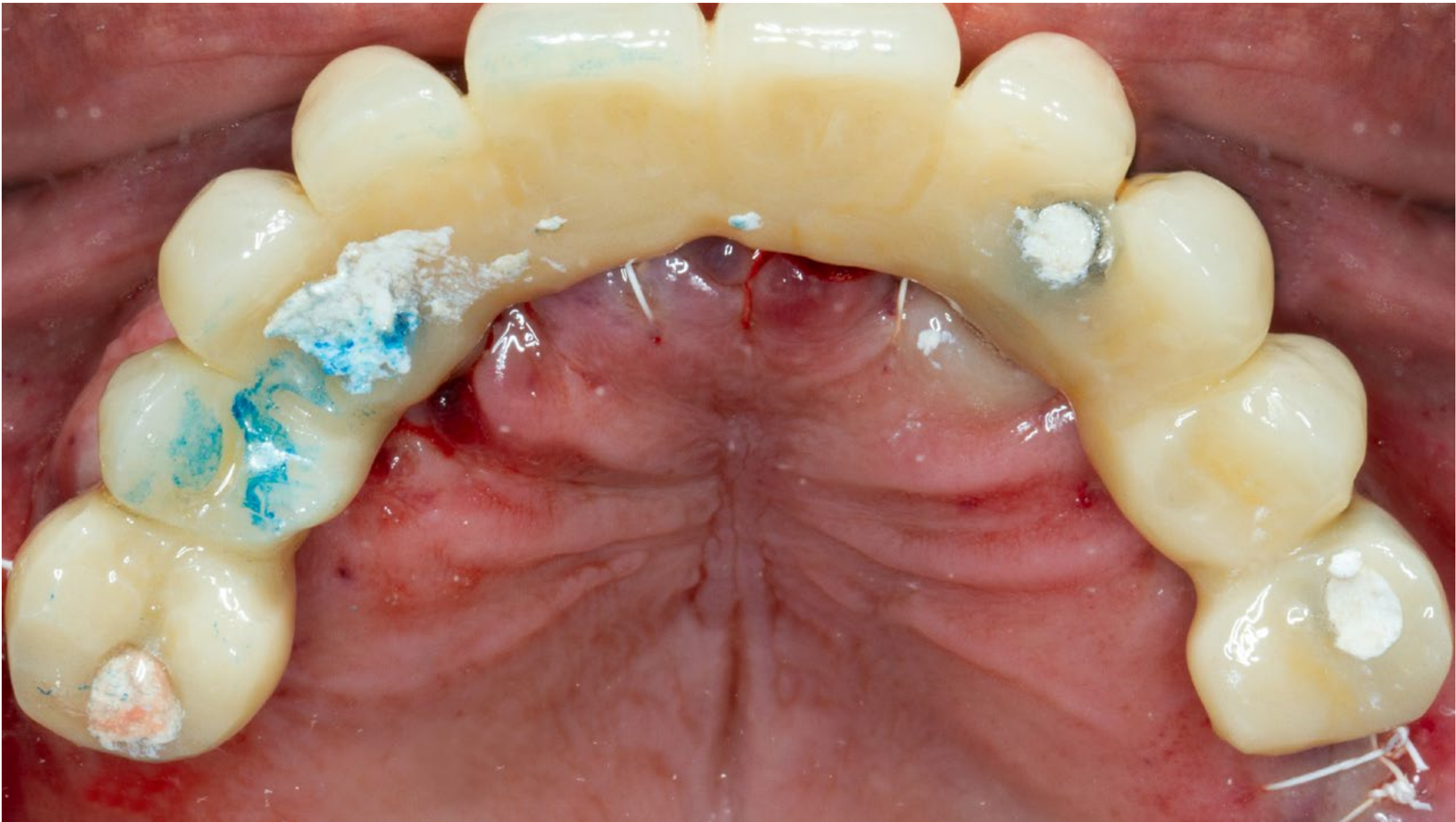

# Challenge 2: Soft bone quality

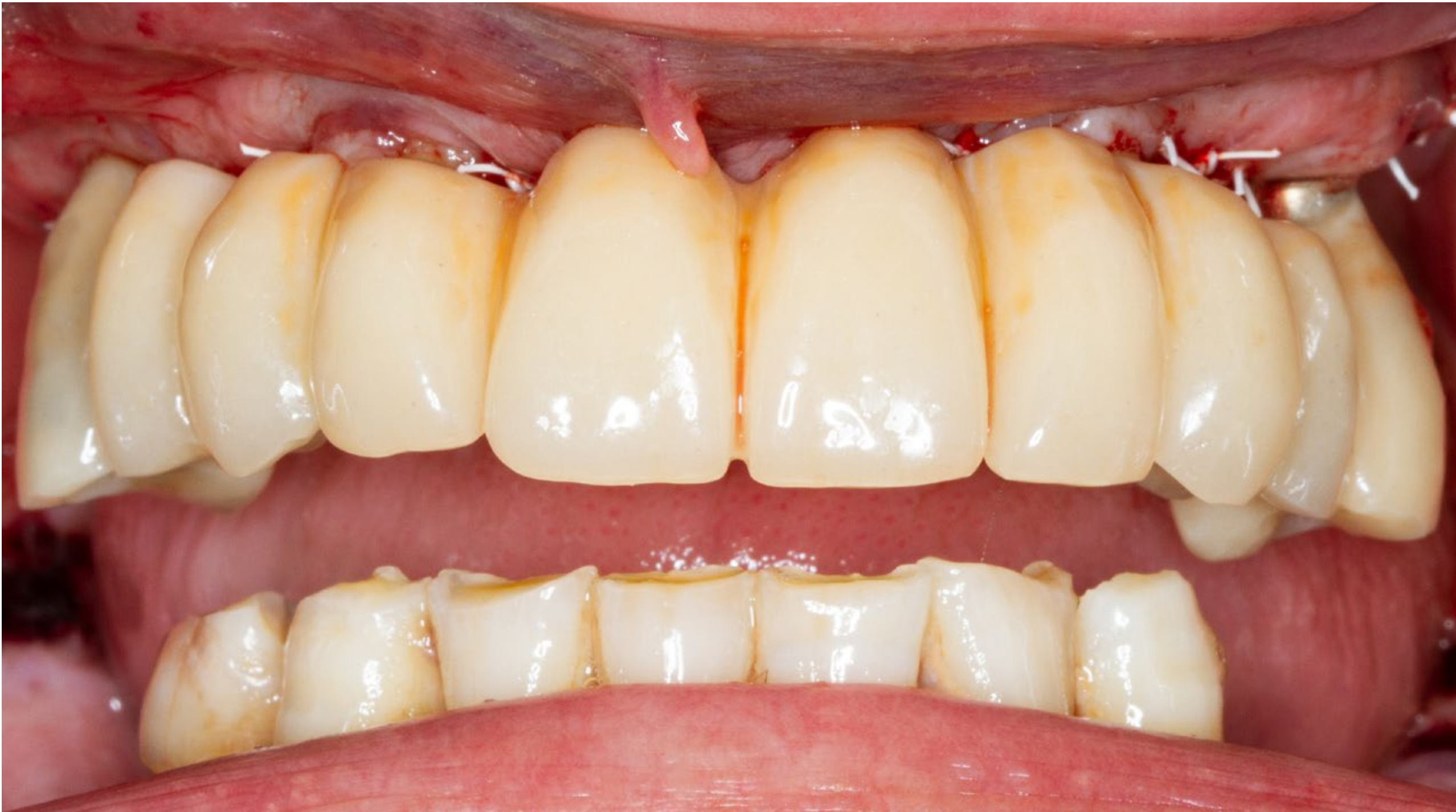Clinical case



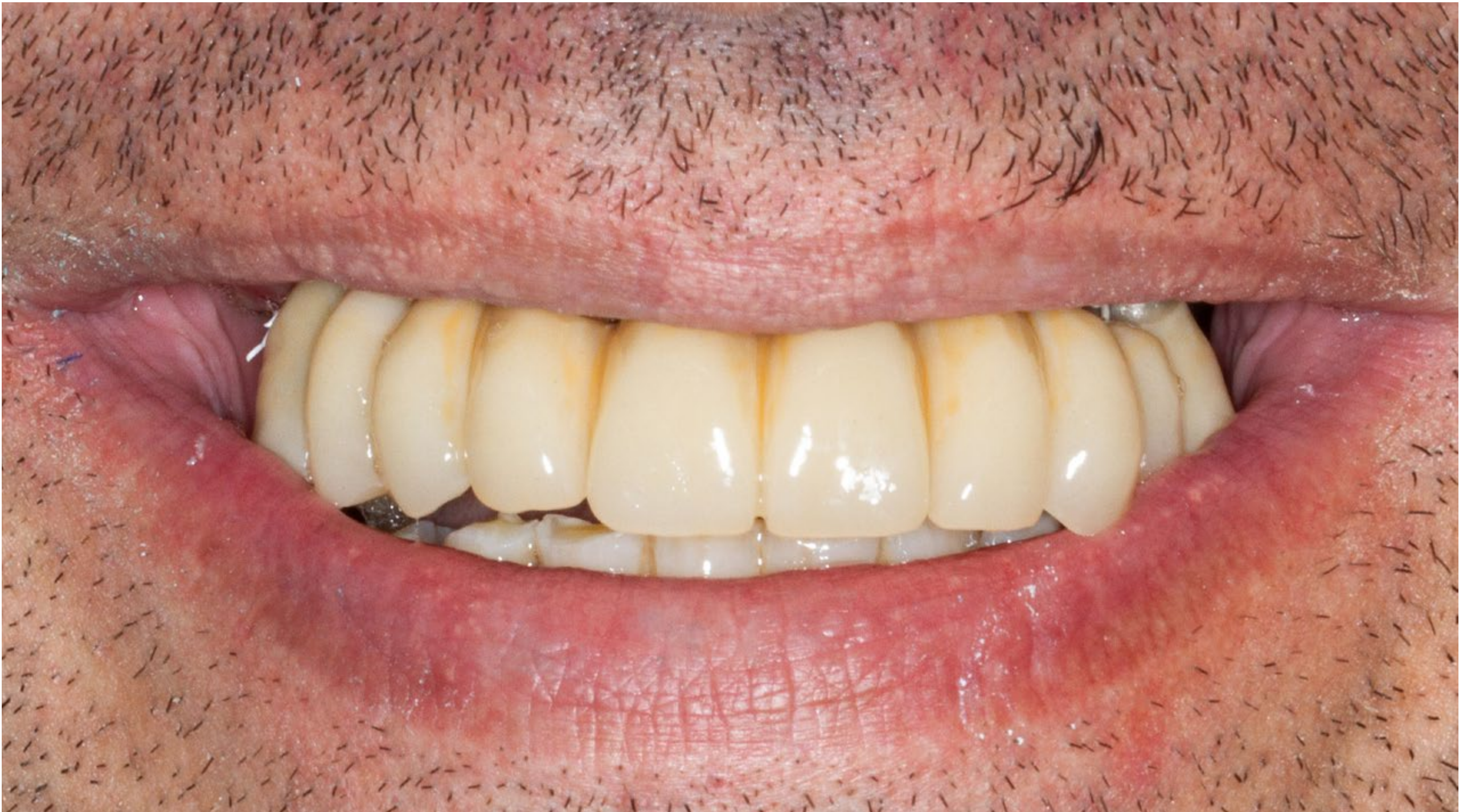Finished provisional prosthesis



Placement of the provisional prosthesis  
Occlusal view



Placement of the provisional prosthesis  
Frontal view

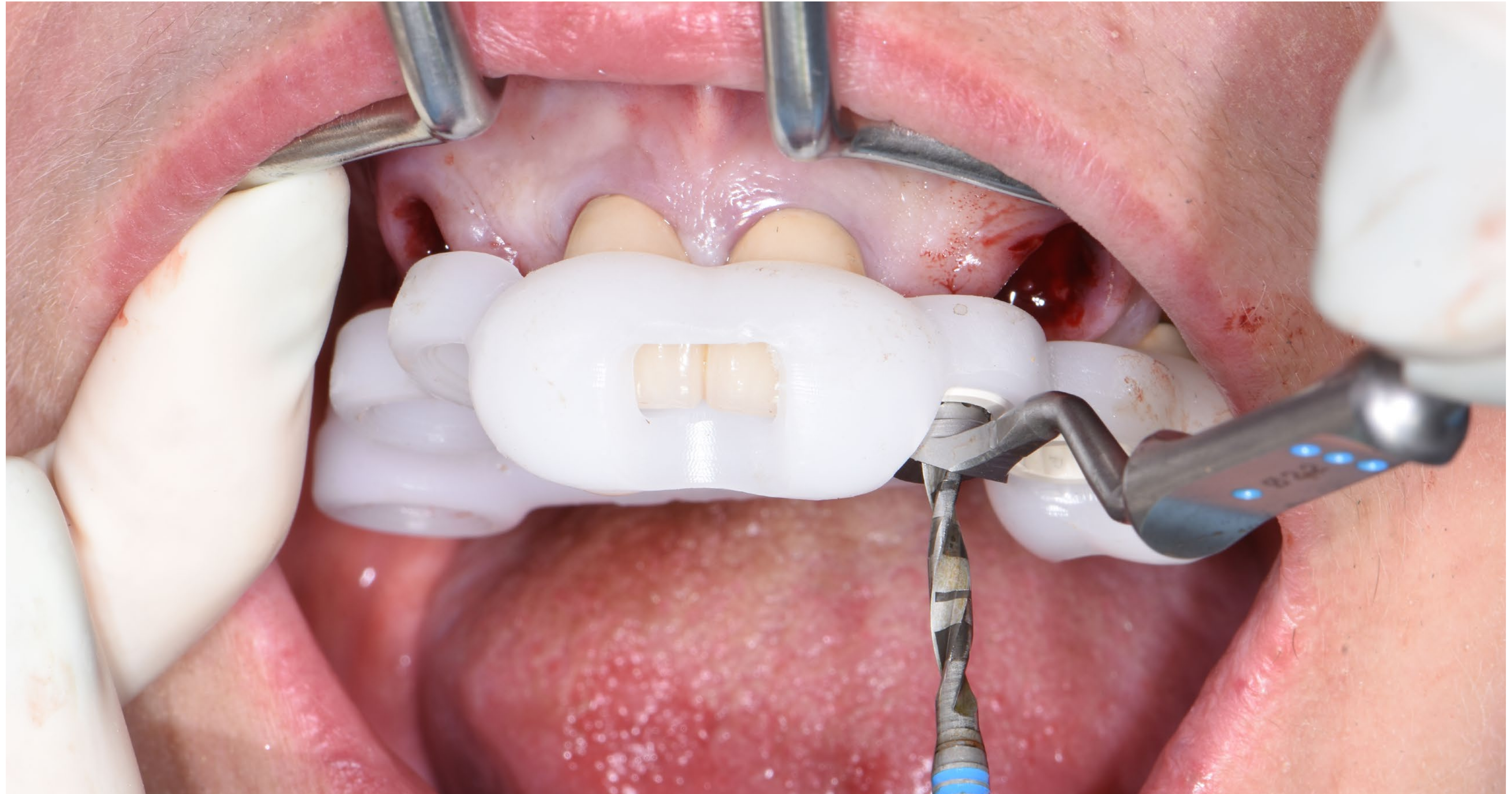

Provisional prosthesis in place  
Final prosthesis will be placed six months later



# Challenge 3: Limited posterior bone availability

General recommendations and clinical case from Dr. Barbara Sobczak





# Challenge 3: Limited posterior bone availability

General recommendations



## General recommendations from Dr. Barbara Sobczak

- Short implants
- Digital treatment planning and guided surgery for precise three-dimensional positioning of the implant
- Implants with wide threads to ensure primary stability
- Tilting of posterior implants if straight placement is not possible

Graduated from Warsaw Medical University in 2007 and the Goethe University Frankfurt in 2017. ITI Fellow, ITI Study Club Mazovia Director, Medical Consultant for Straumann in Poland. Center of Advanced Education in Oral Implantology. Owner of several clinics in Poland: Dr. Sobczak Klinika Radosc, Dr. Sobczak Klinika Babice and Dr. Sobczak Junior Wilanow



Dr. Barbara Sobczak,  
DDS, MSc  
Warsaw, Poland

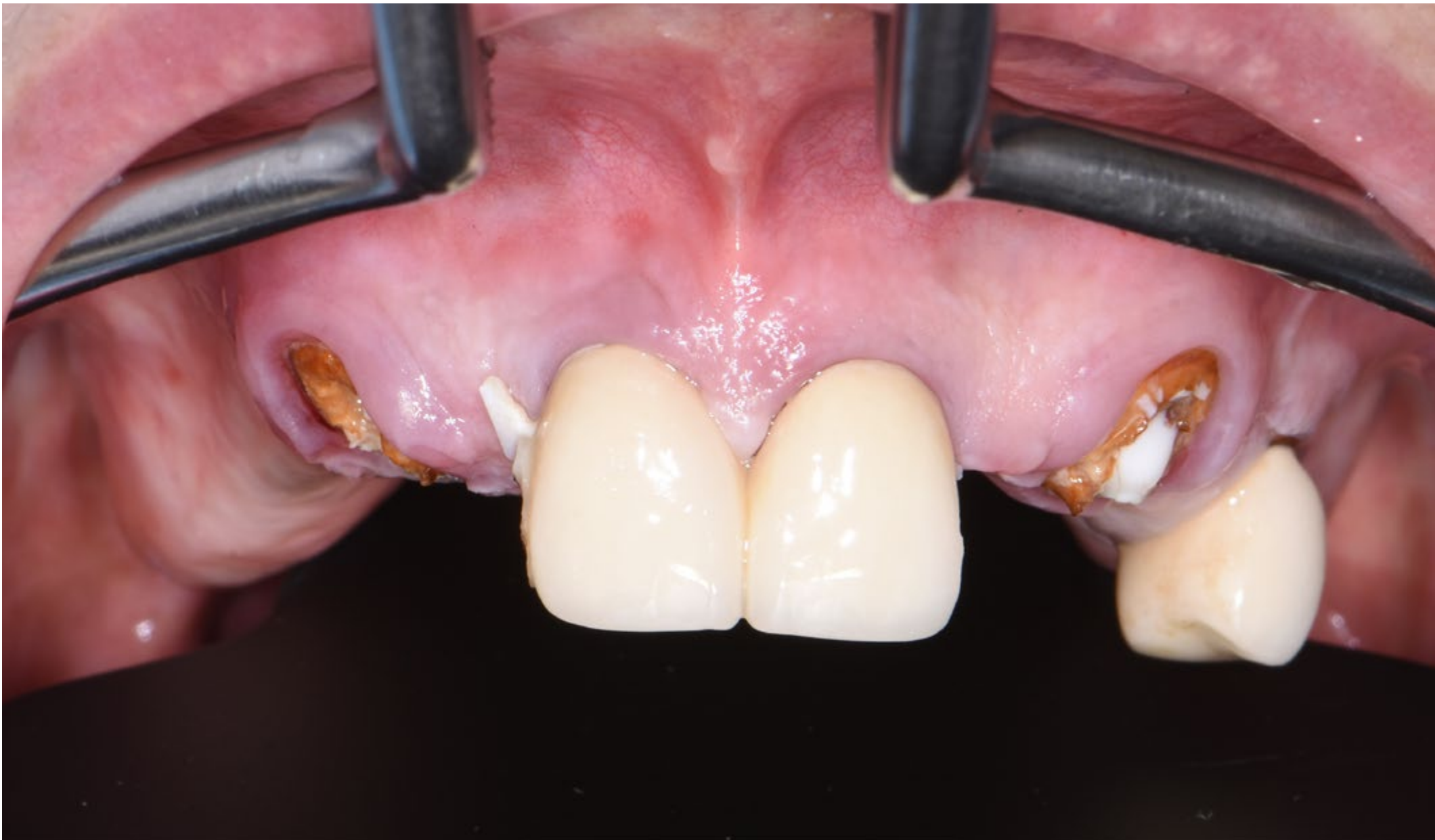

# Challenge 3: Limited posterior bone availability

Clinical case



## Initial situation



## Patient information

Age	62
Jaw	Maxilla
Health status	Good
Height of smile line	Low
Bone type	Soft
Infections at implantation site	No
Bone anatomy defects	Resorption in the posterior area
Risks	No

## Additional difficulties

Soft bone quality
Limited bone availability in the posterior area

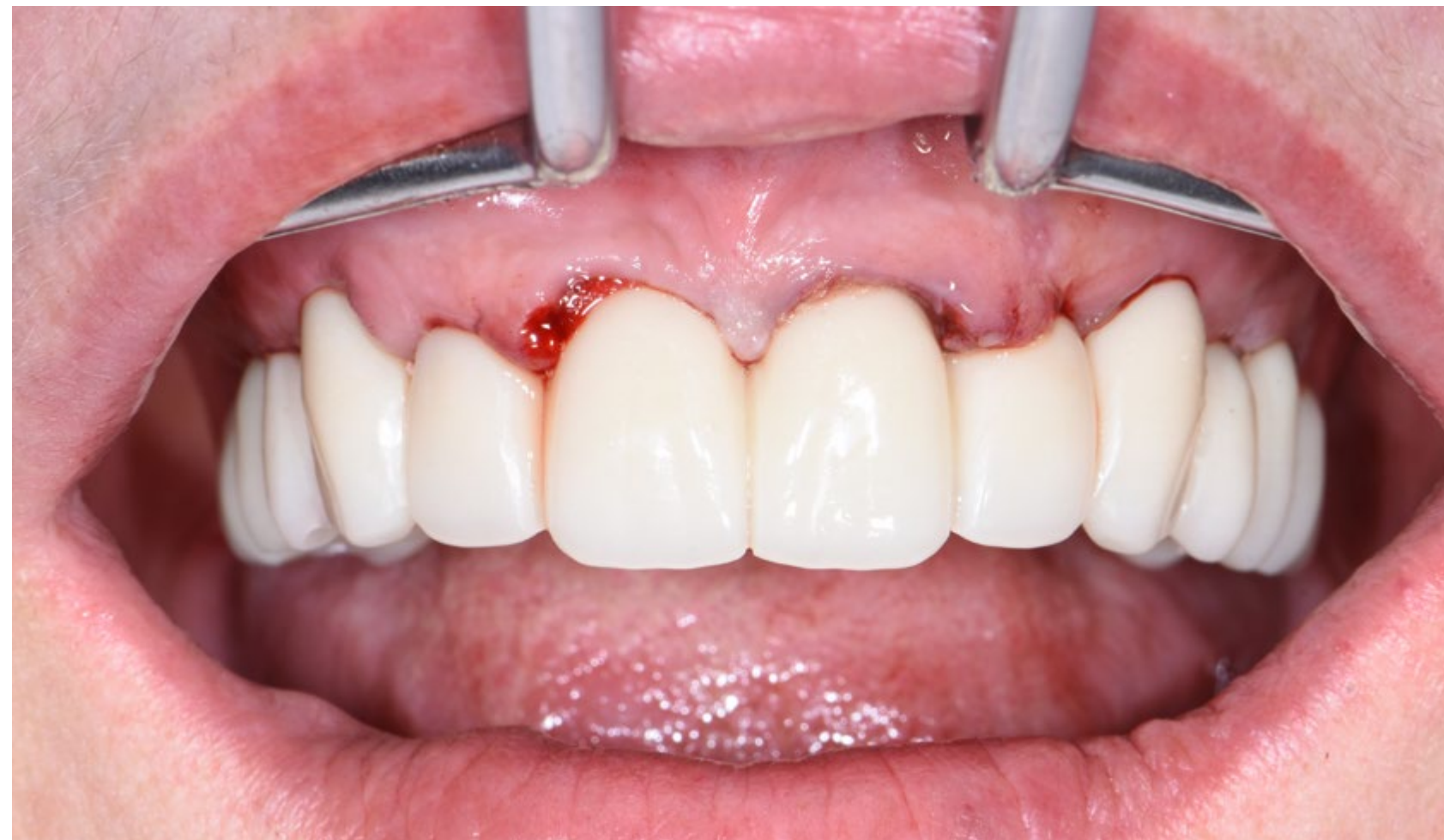

# Challenge 3: Limited posterior bone availability

Clinical case



## Provisional prosthesis



## Treatment

- Fixed immediate rehabilitation on six implants
- Use of short implants because of low bone availability in the posterior region
- Fully digital workflow

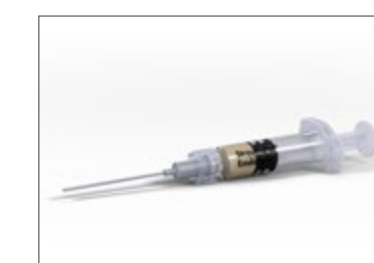**Temporary restoration:** PMMA milled bridge

**Planned final prosthesis:** final screw-retained zirconia bridge, full contour multilayer 1200 MPa strength

## Materials used



Straumann® BLX Ø 3.75 mm  
RB SLActive® 6 mm, 8 mm,  
10 mm, 12mm, Roxolid®



Straumann® Emdogain®



Screw-retained abutments,  
straight, GH 2.5 mm  
Screw-retained abutments,  
30° angled, GH 4.5 mm



cerabone® granules  
0.5–1.0 mm



Variobase® for Bridge/Bar  
Cylindrical Coping



# Challenge 3: Limited posterior bone availability

Clinical case



## My experience



Dr. Barbara Sobczak  
DDS, MSc

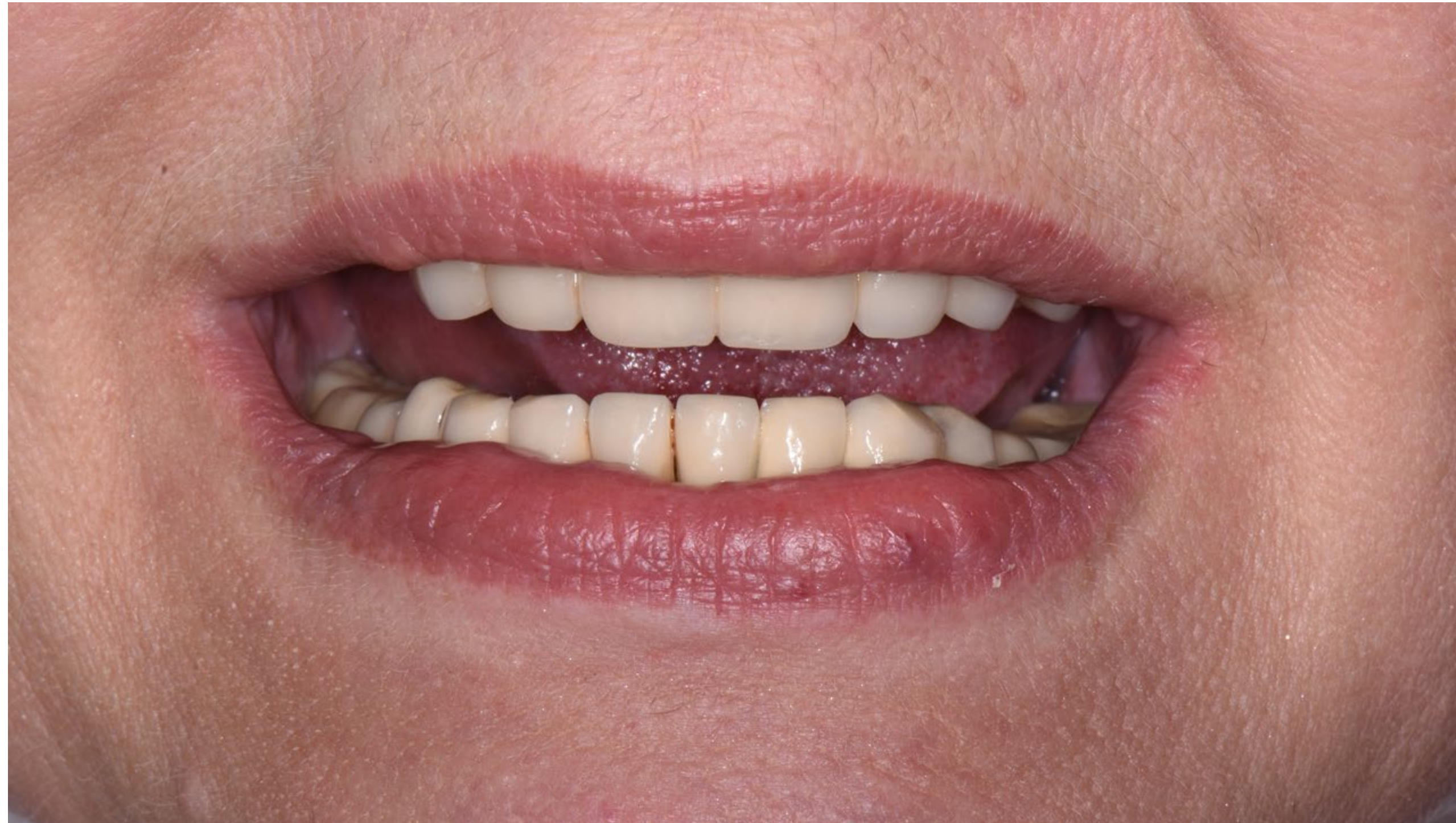*“In my opinion the only and easiest way to maintain the tissues after extractions is immediate implant placement and immediate loading. That is why I developed a concept that not only allows the tissues under the temporary bridge to be preserved and shaped, but also lets the patient experience and enjoy non-removable teeth, like a properly designed and functioning full-arch bridge made of multilayer PMMA with proper design and function.*

*For that concept I need implants that can almost guarantee primary stability of around 35 Ncm regardless of the conditions. This certainly applies to the BLX implant. I would also recommend the new, easy to handle SRAs, which are crucial to my work. I have also rediscovered the healing capacity of Emdogain®, which seems to seal the sutures and augmented areas. Just what I need in my treatment protocol.”*

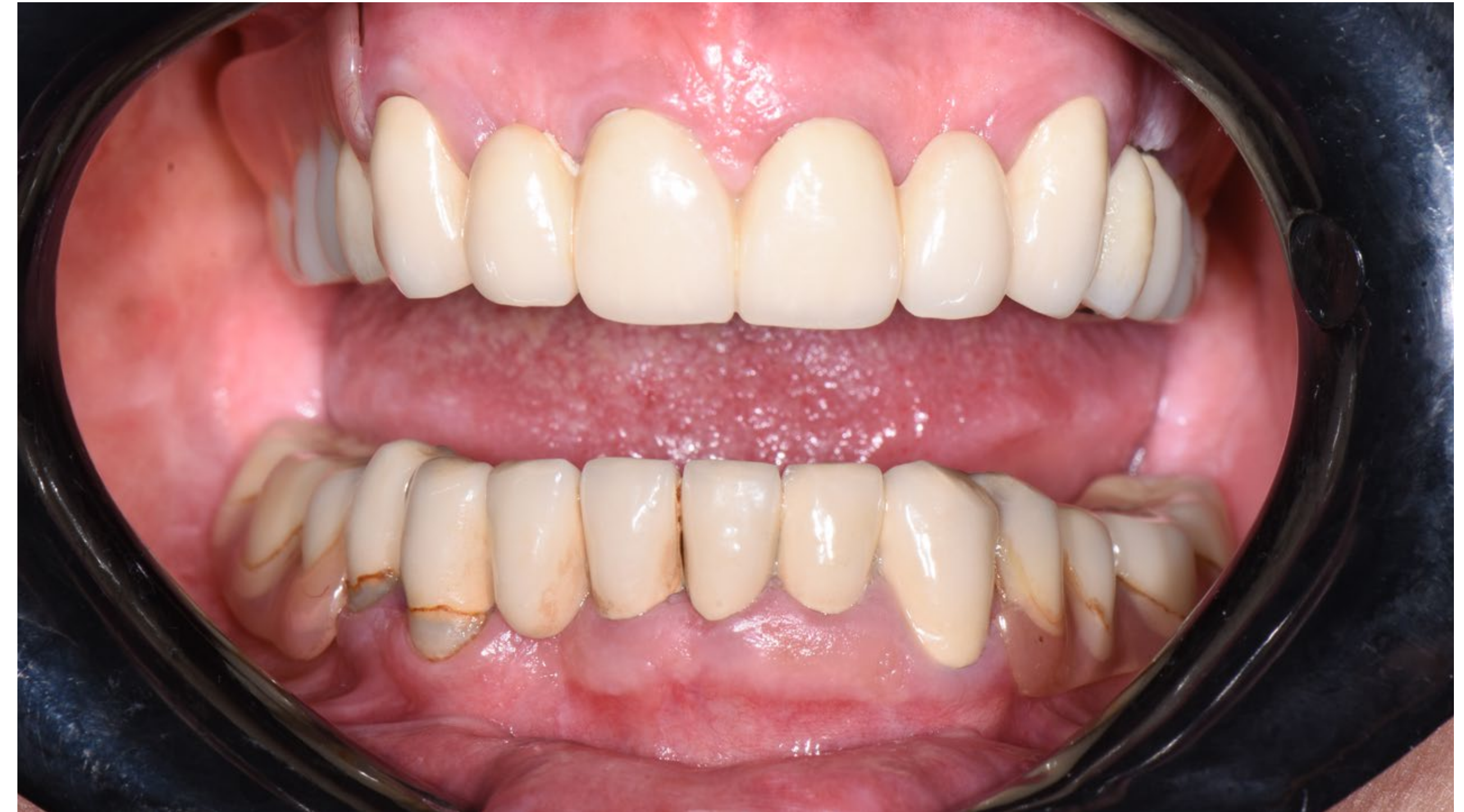

# Challenge 3: Limited posterior bone availability

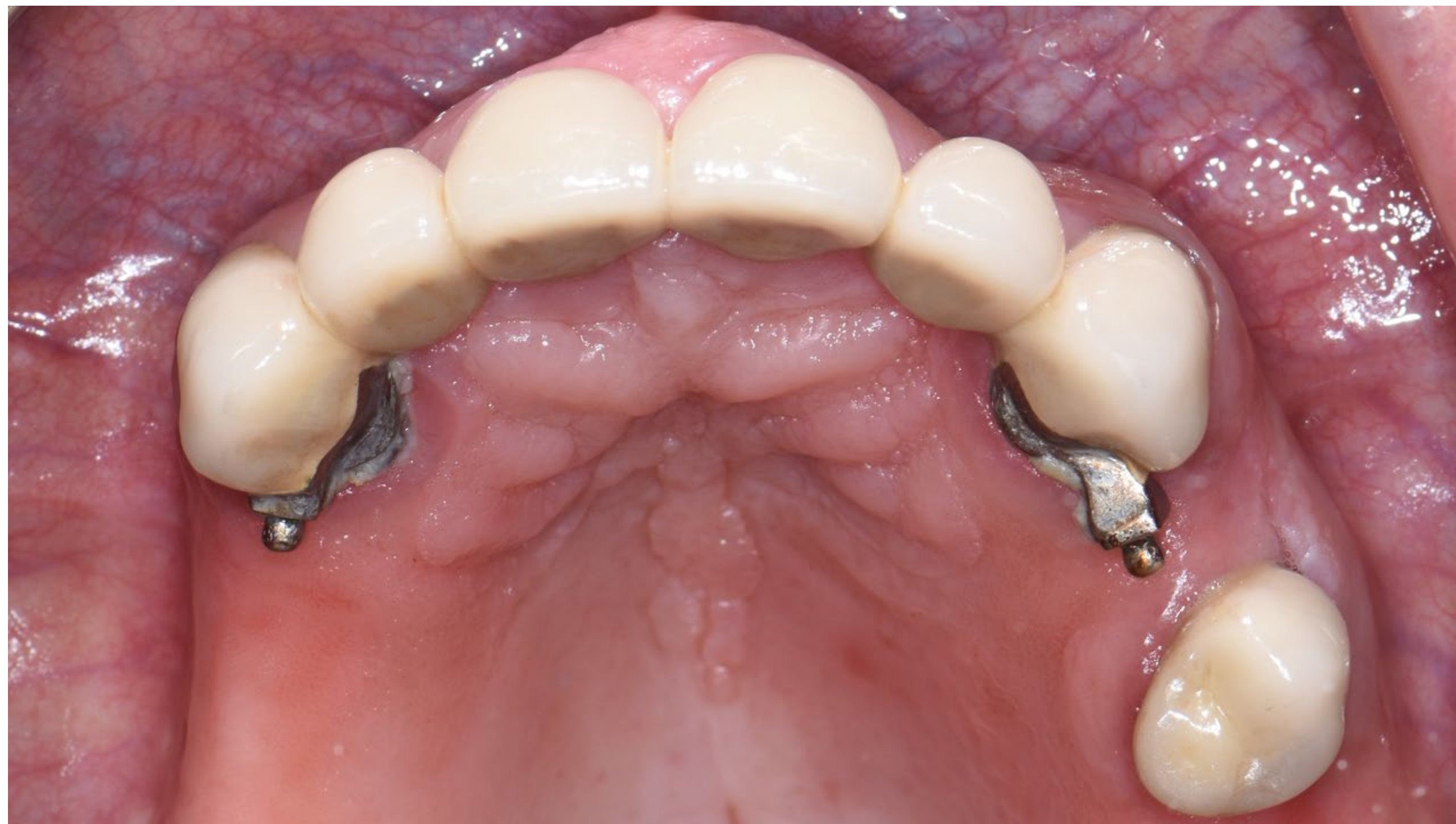Clinical case



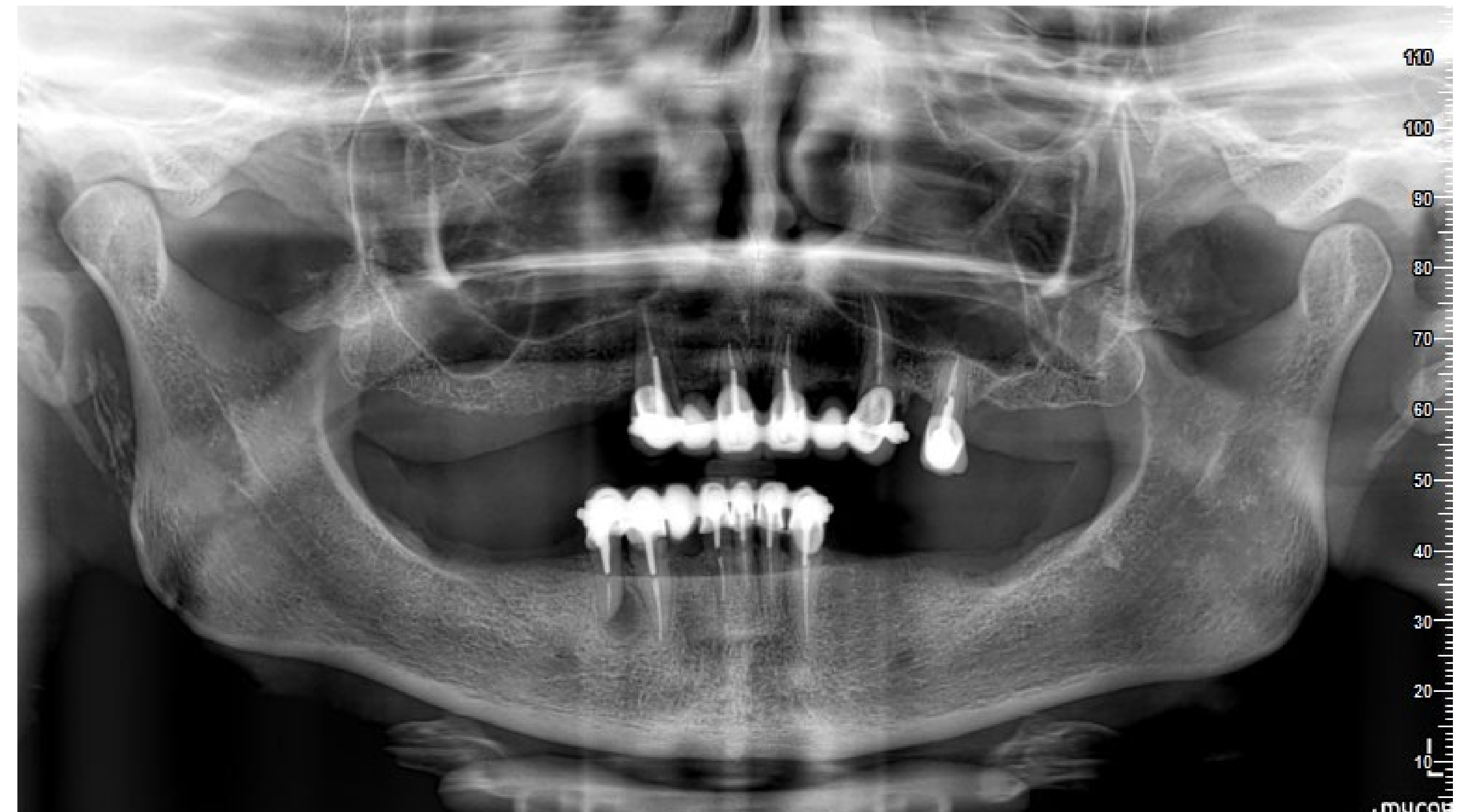Initial clinical situation



Initial clinical situation



Occlusal view  
The first intraoral scan was performed

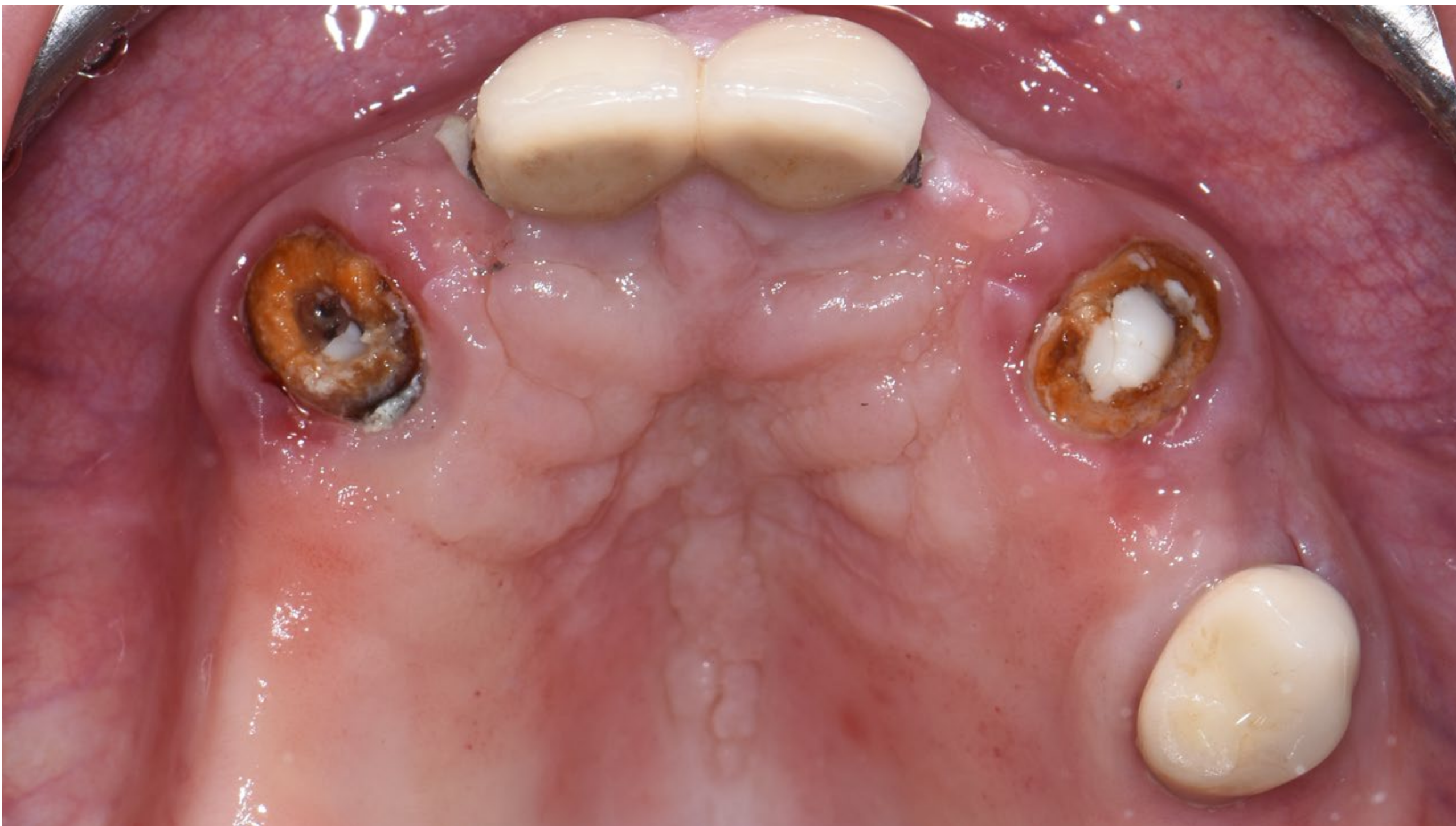

Preoperative panoramic radiograph

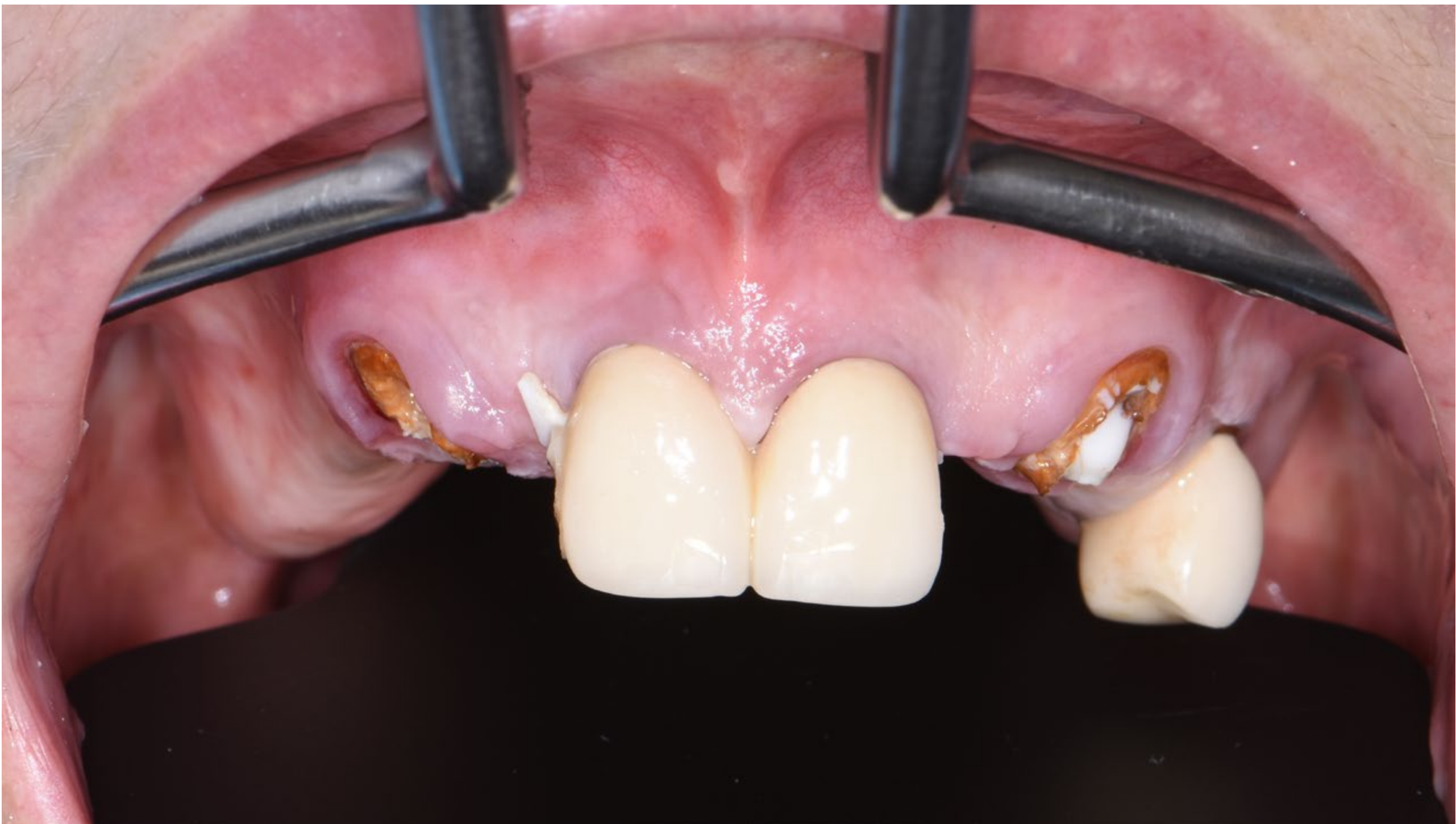

# Challenge 3: Limited posterior bone availability

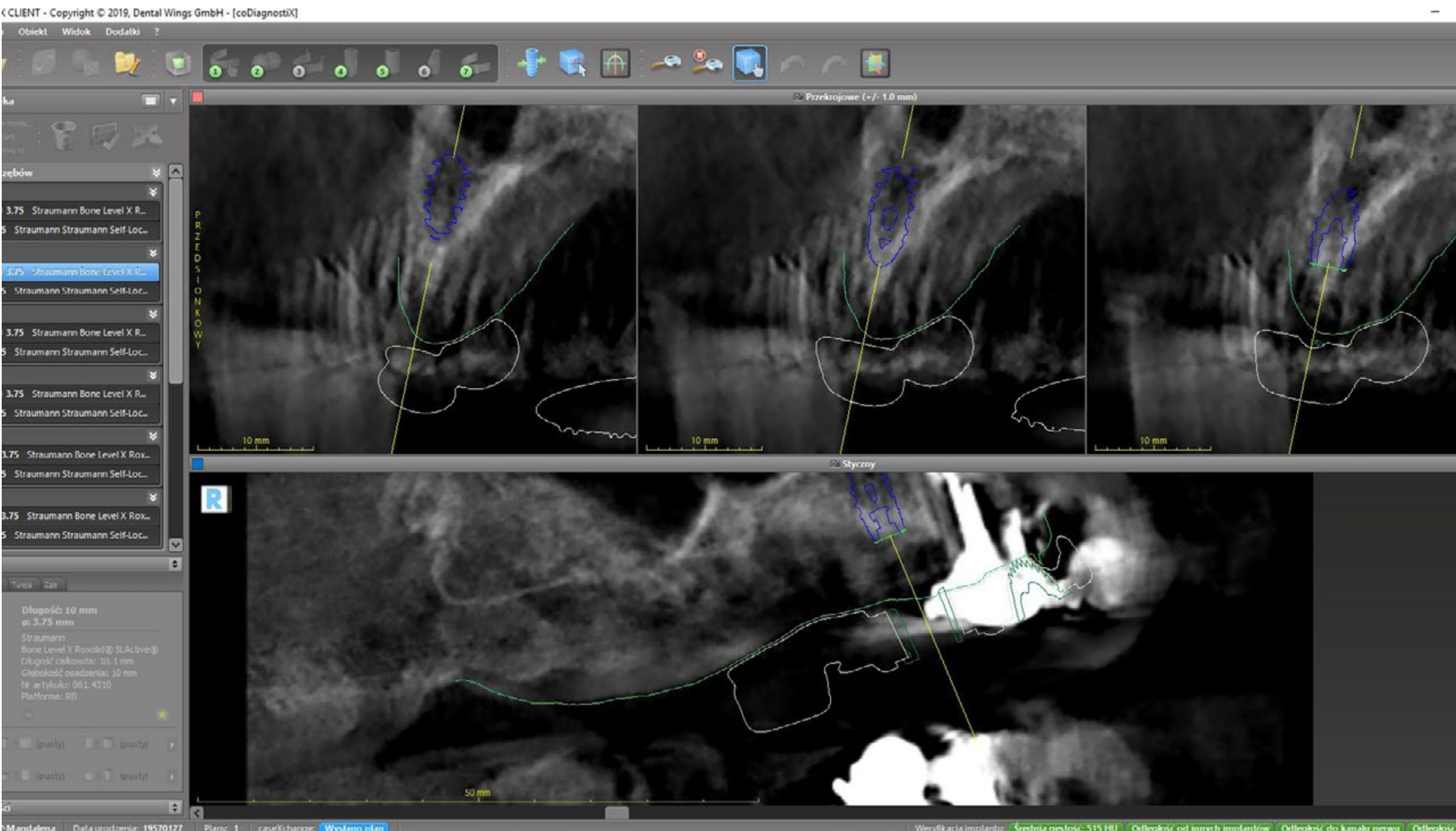
Clinical case



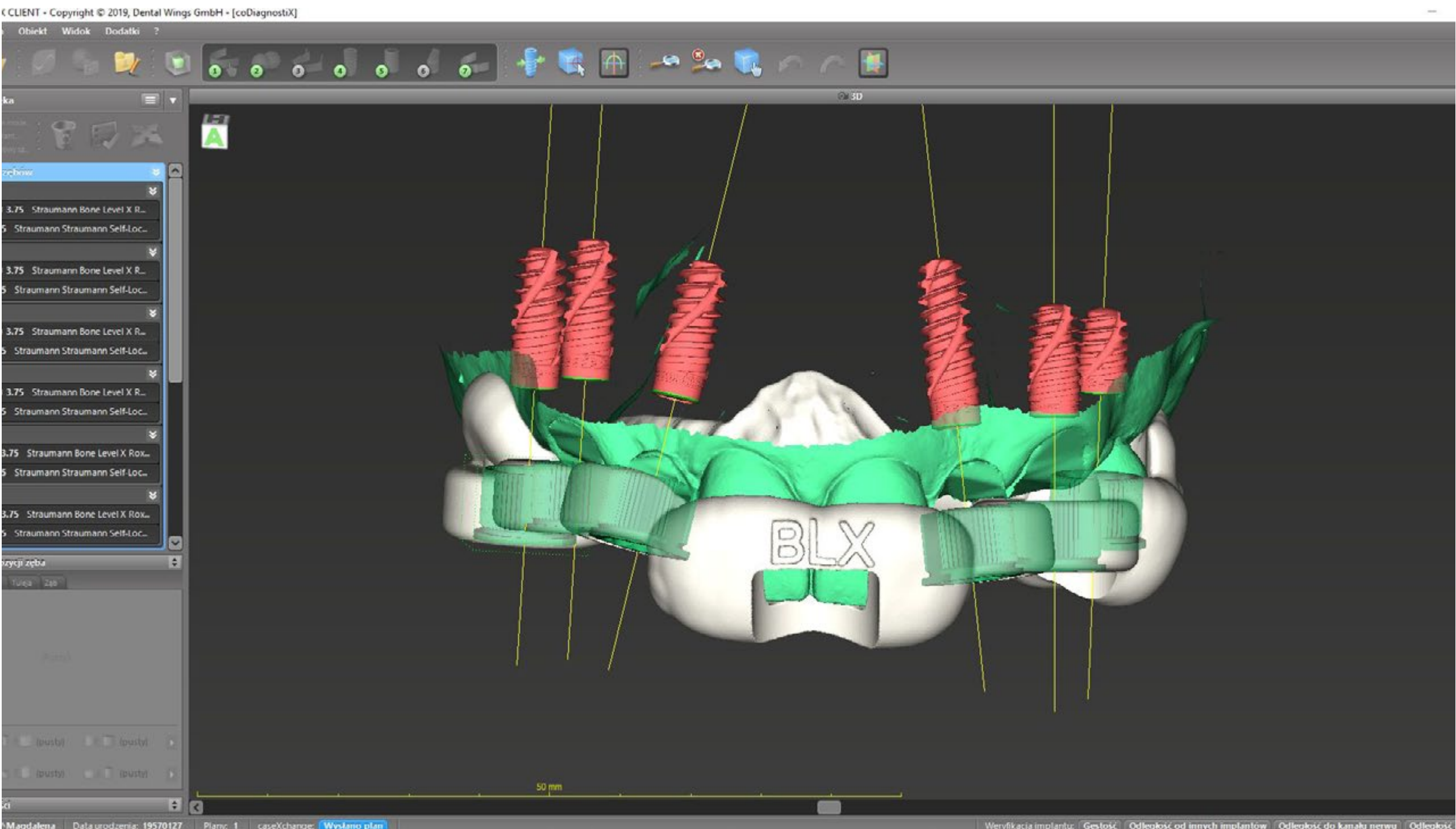
Occlusal view after removing crowns



Frontal view



Treatment planning with coDiagnostiX®

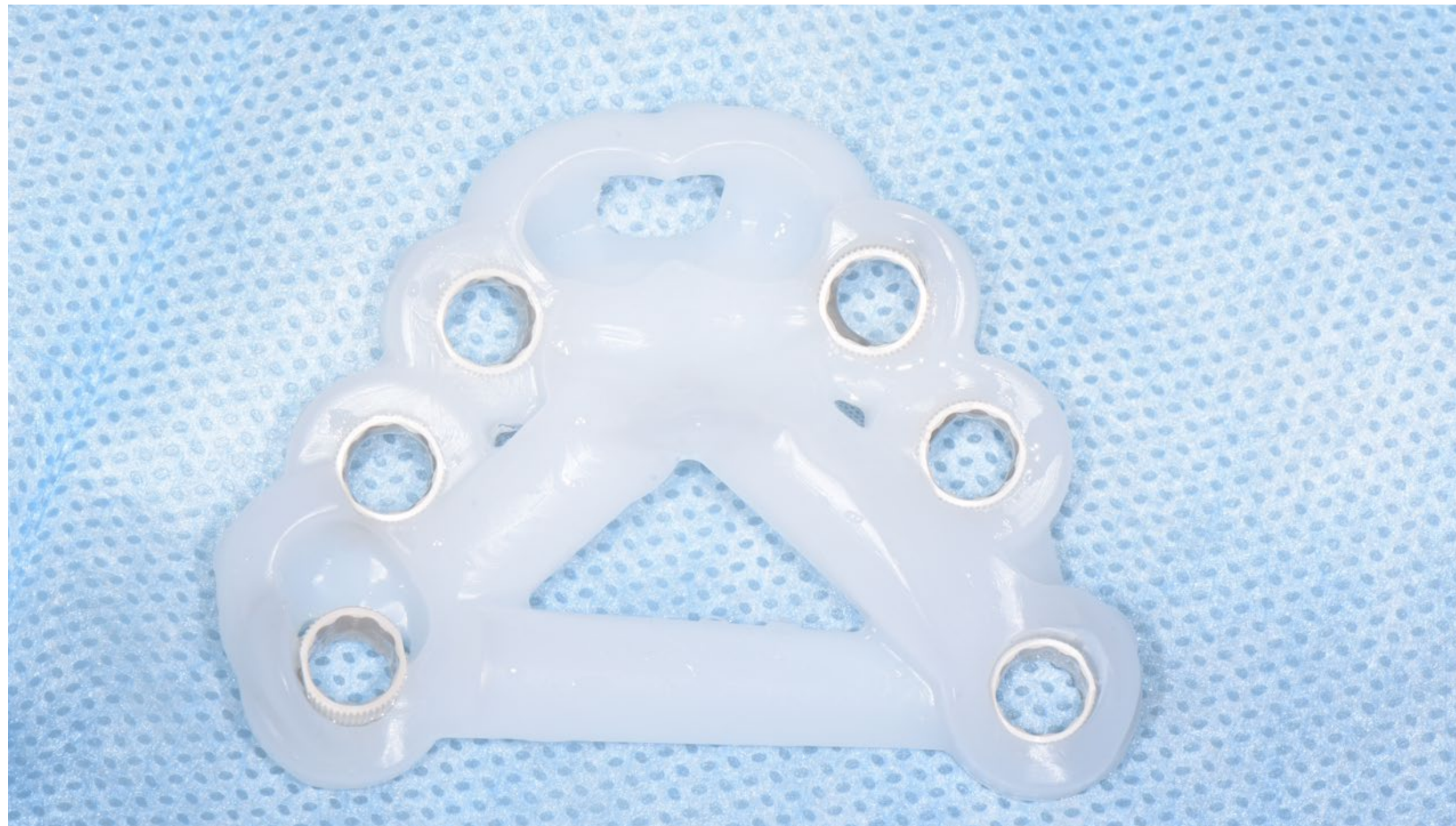

Surgical guide planned with coDiagnostiX®

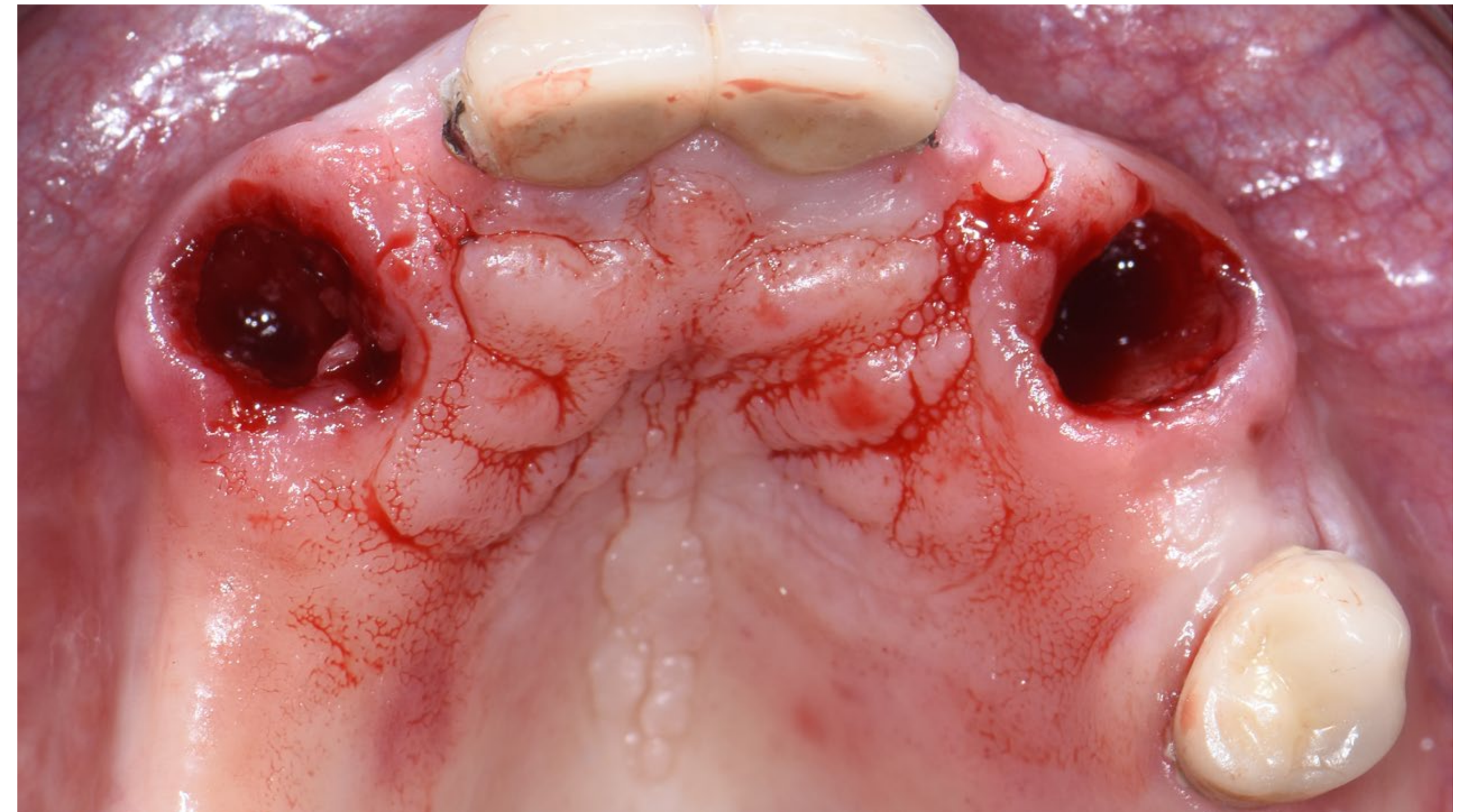


# Challenge 3: Limited posterior bone availability

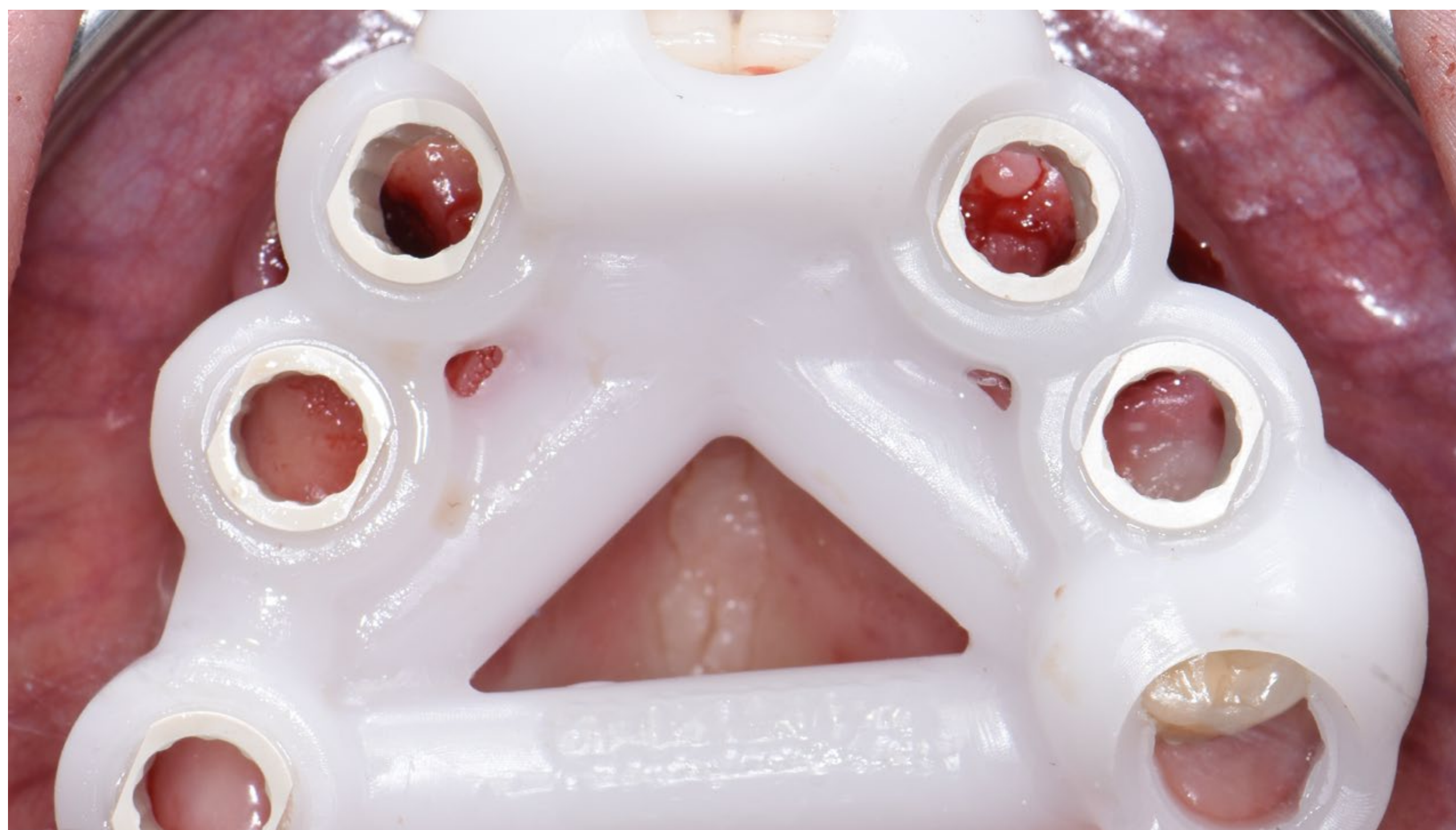Clinical case



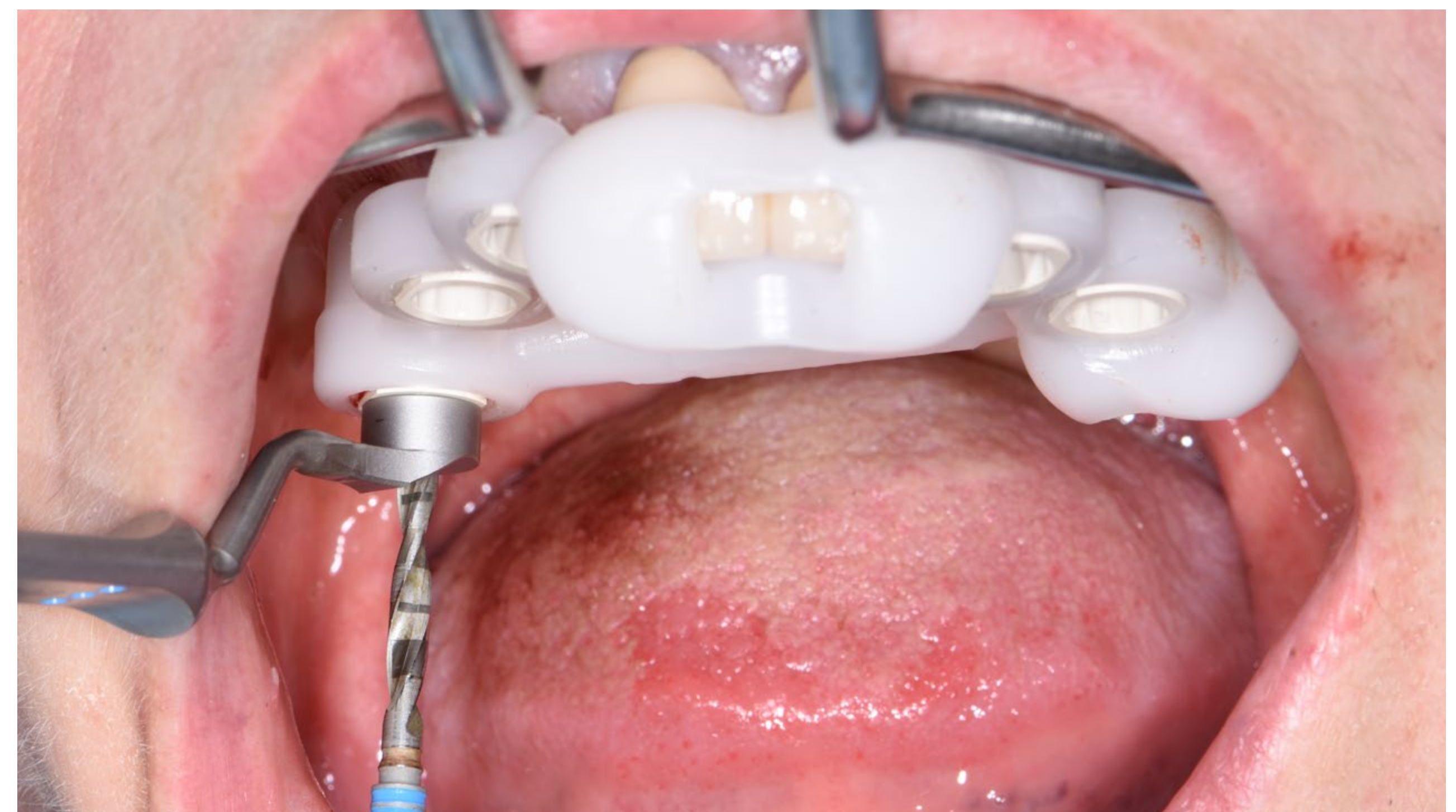
Printed surgical guide



Occlusal view after teeth extraction



Surgical guide in place

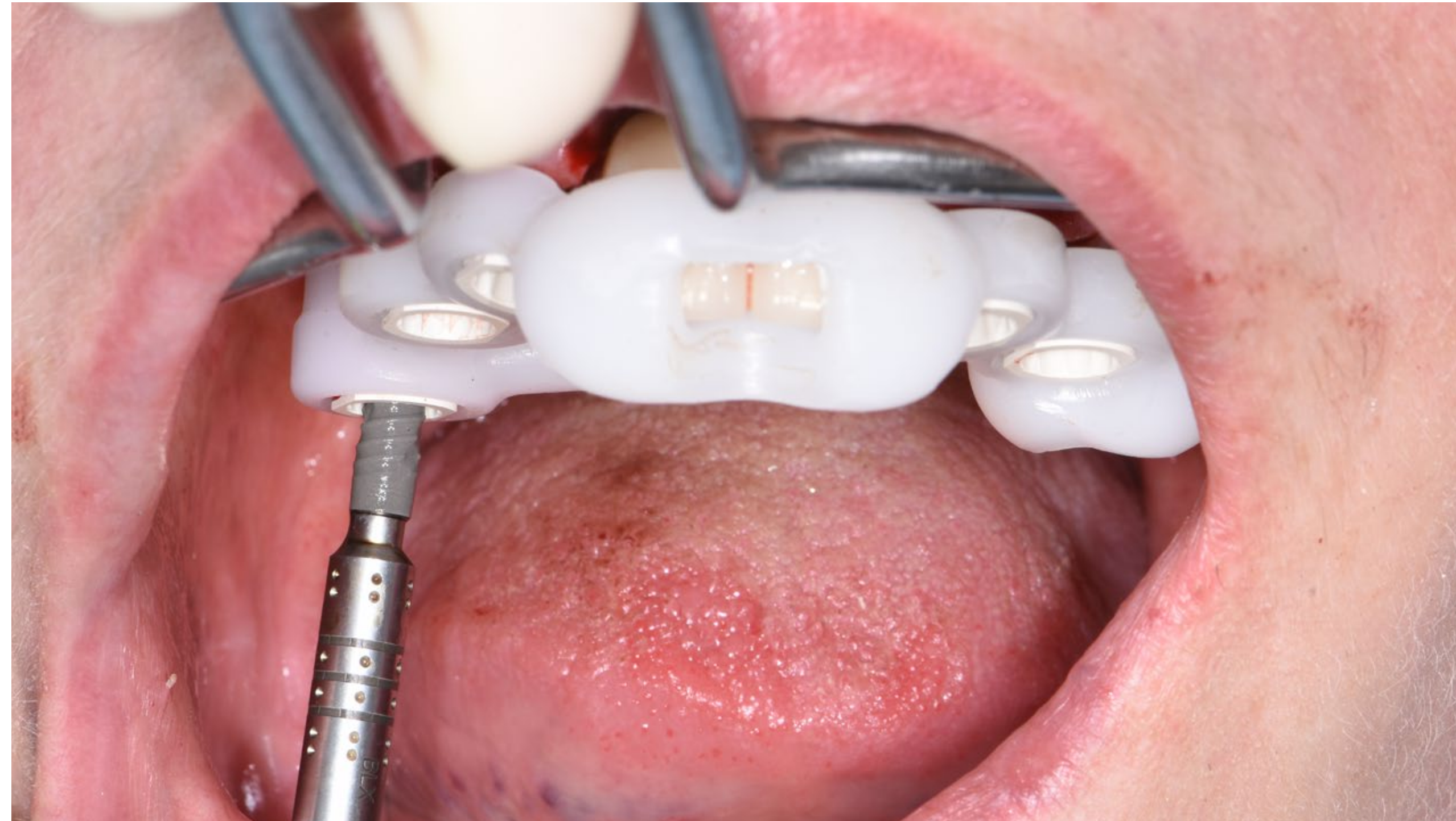

Preparation of implant sites  
All implant sites prepared with Pilot Drill  $\varnothing$  2.2 mm

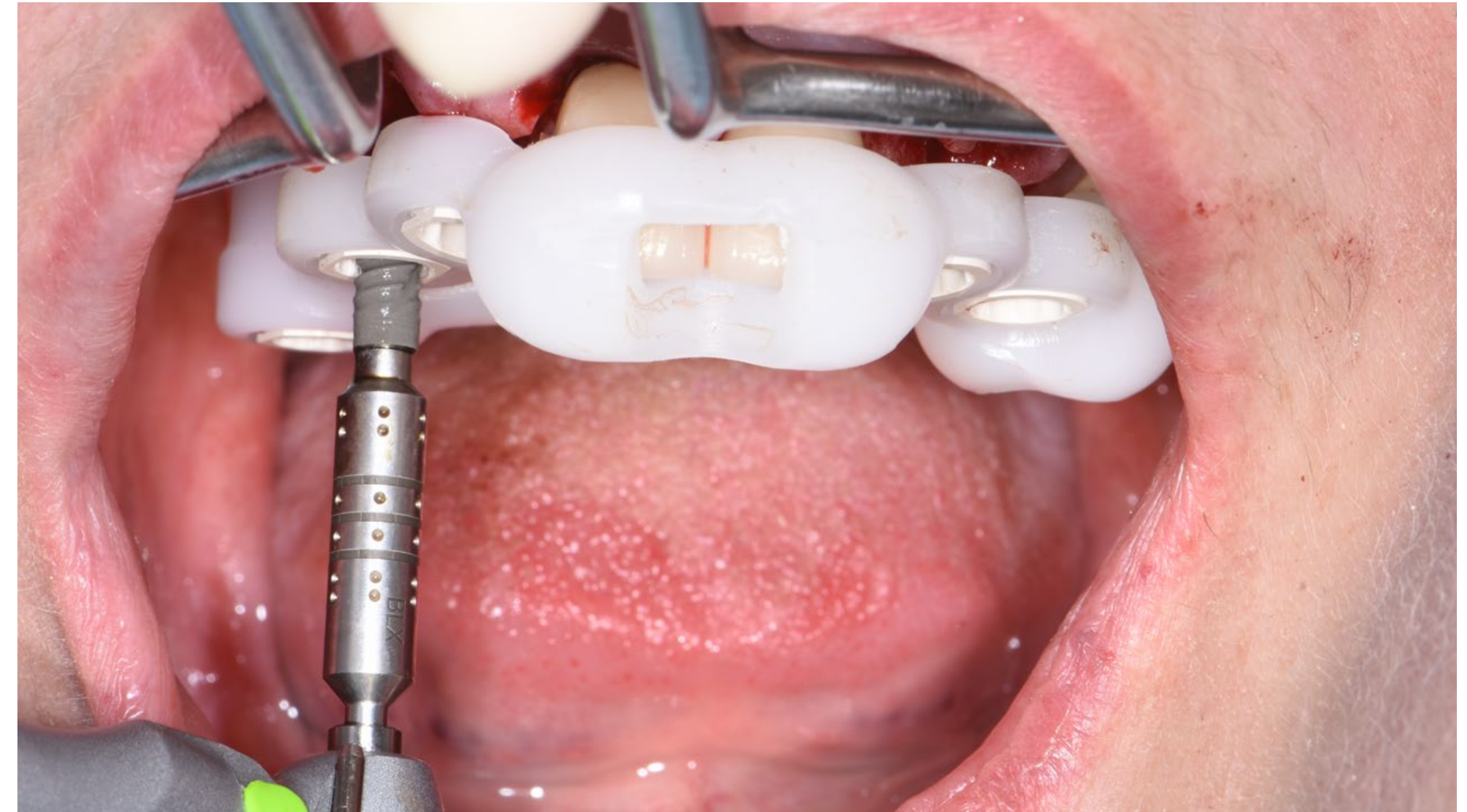

# Challenge 3: Limited posterior bone availability

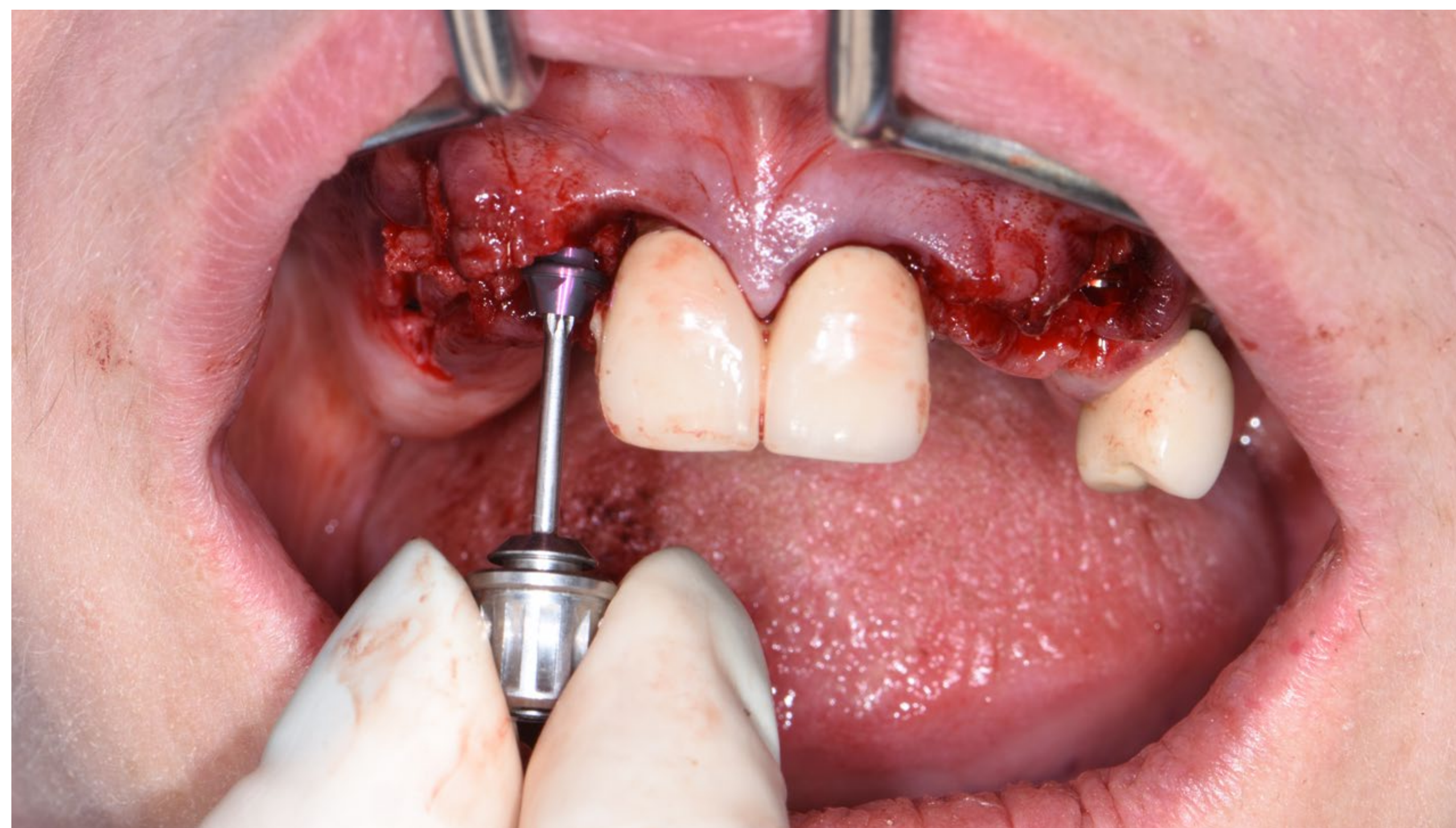
Clinical case



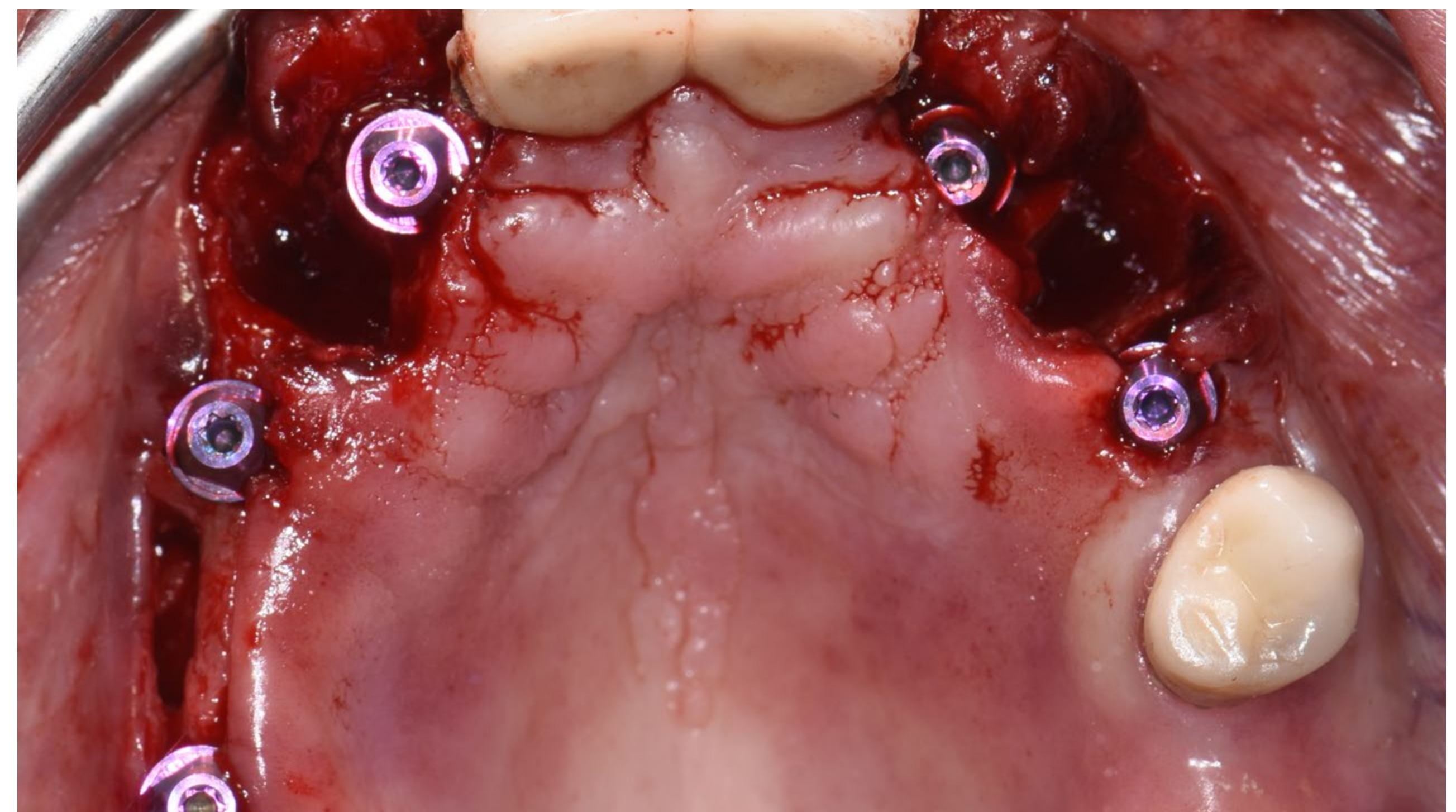
Placement of the Straumann® BLX Ø 3.75 mm RB SLActive® 10 mm Roxolid® implant with a torque of 35 Ncm



Placement of the Straumann® BLX Ø 3.75 mm RB SLActive® 10 mm Roxolid® implant with a torque of 35 Ncm



Placement of the Screw-retained Abutments

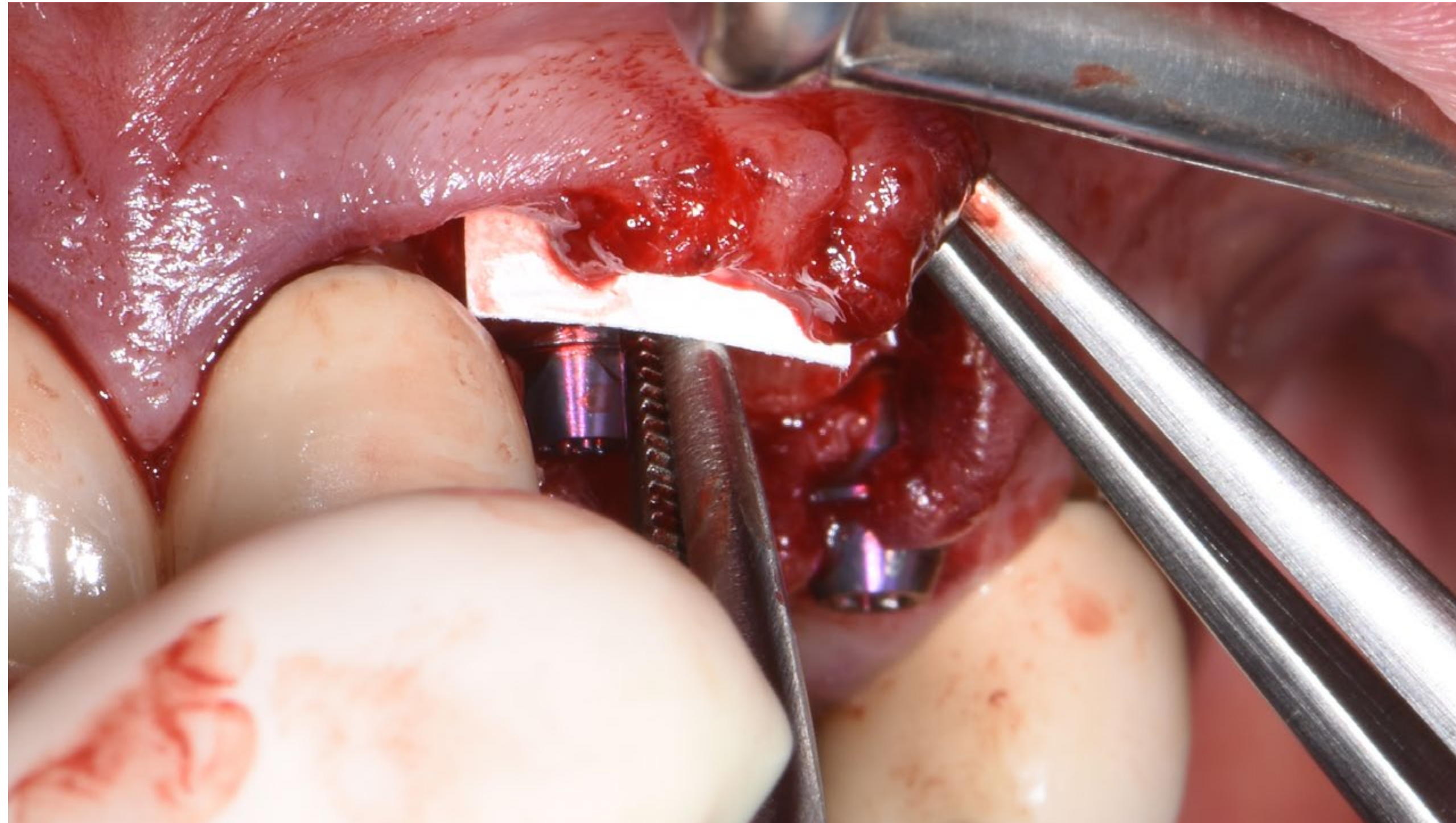


Screw-retained Abutments in place

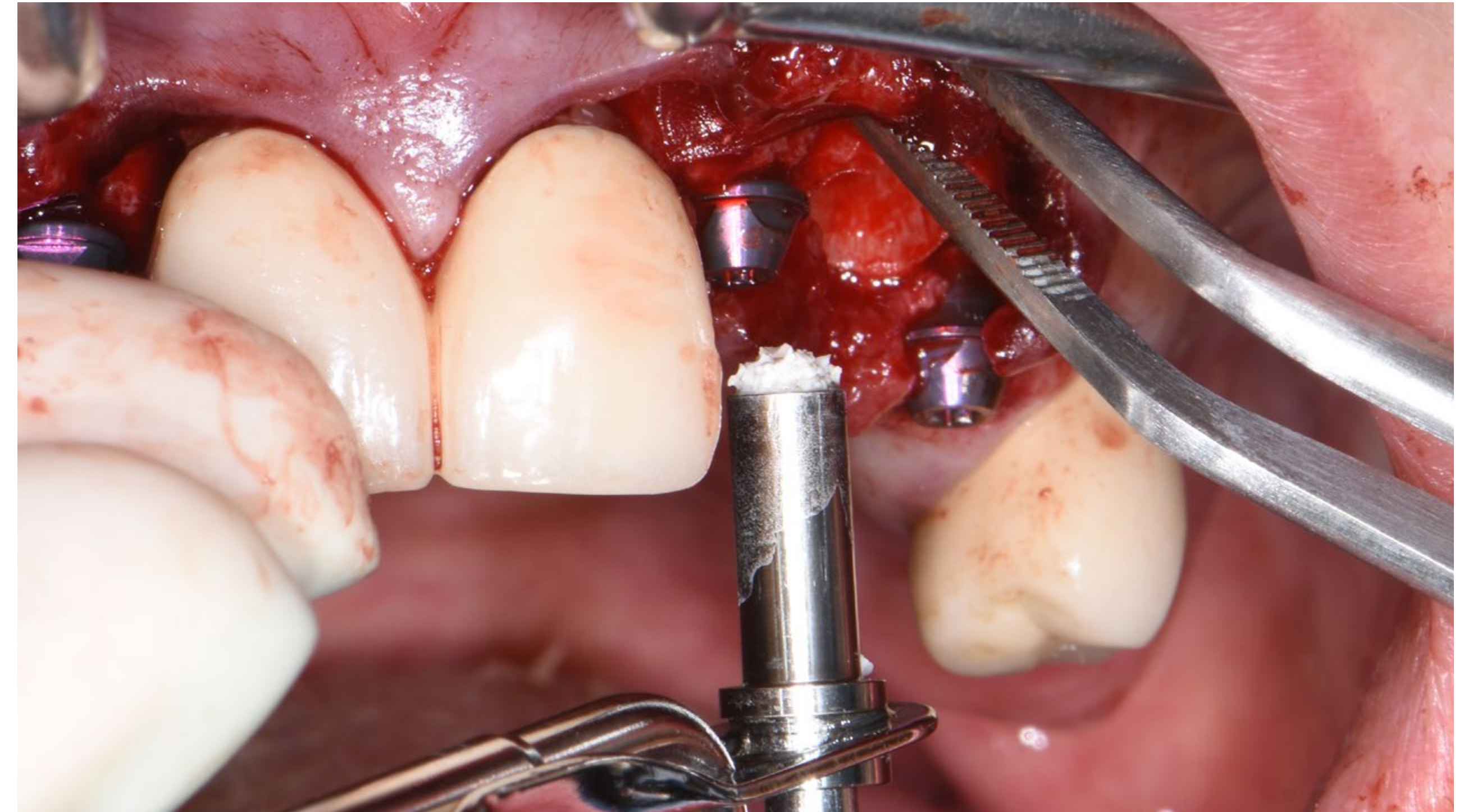


# Challenge 3: Limited posterior bone availability

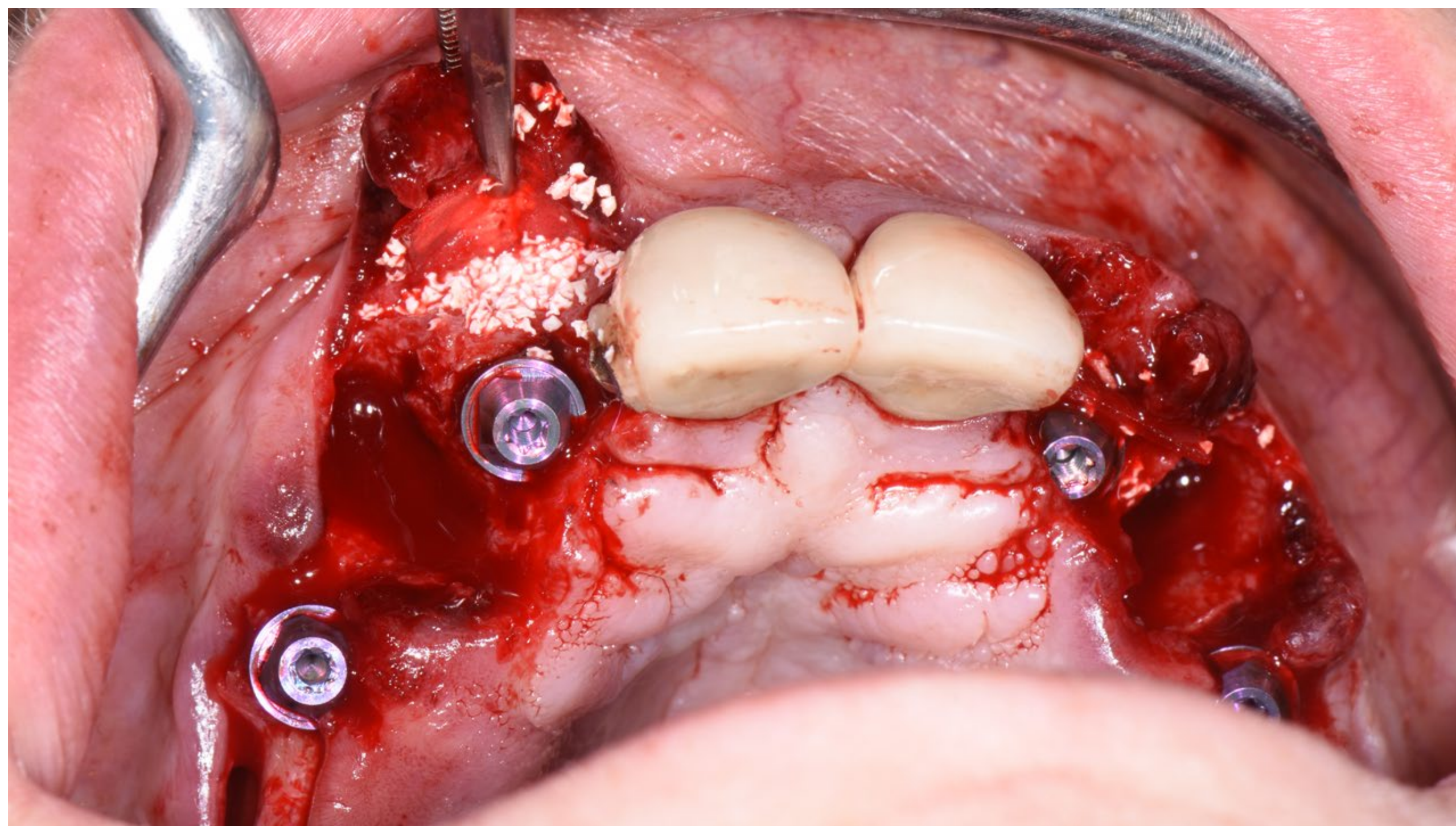
Clinical case



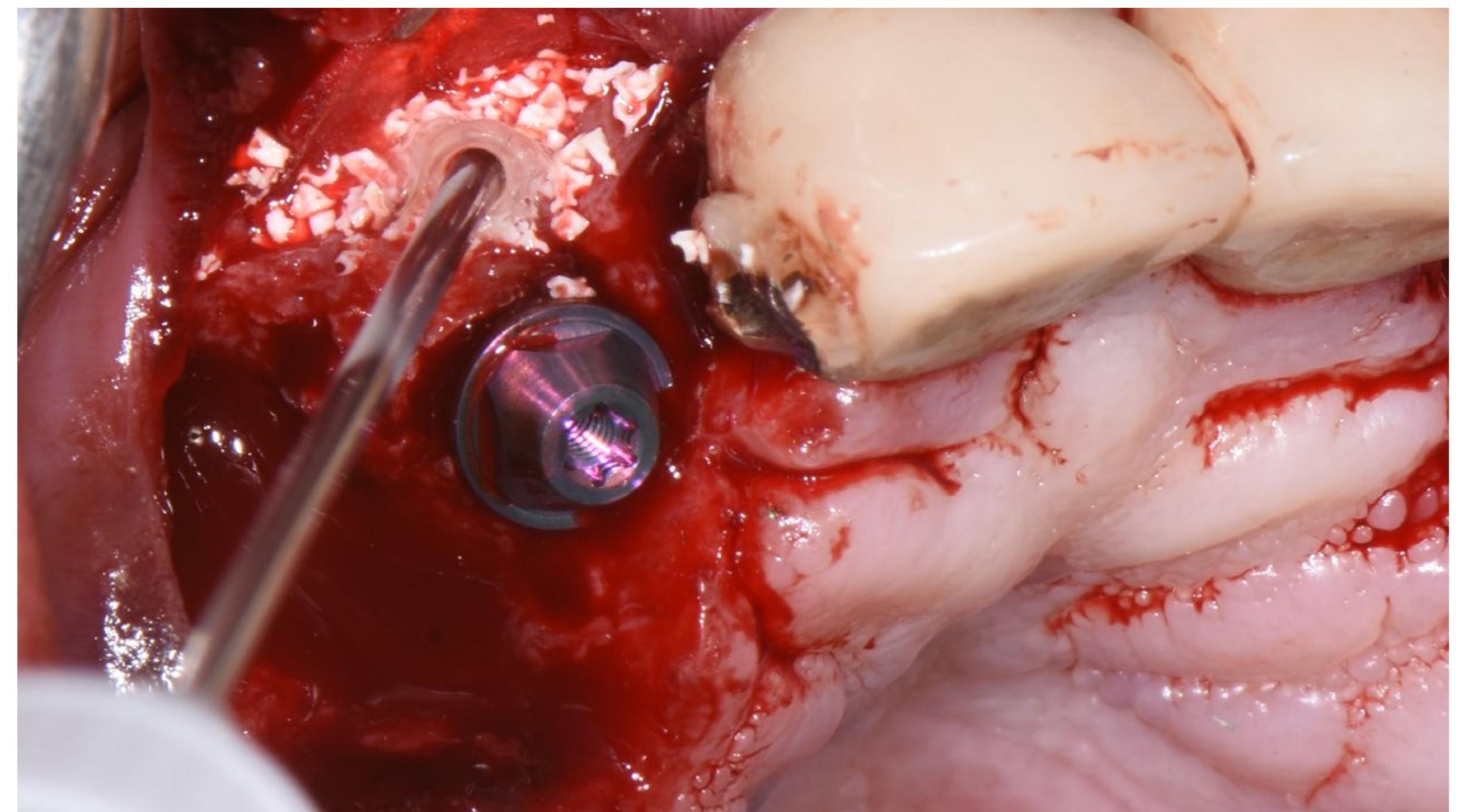
Placement of the collagen membrane



Placement of the cerabone® granules 0.5–1.0 mm



Placement of the cerabone® granules 0.5–1.0 mm

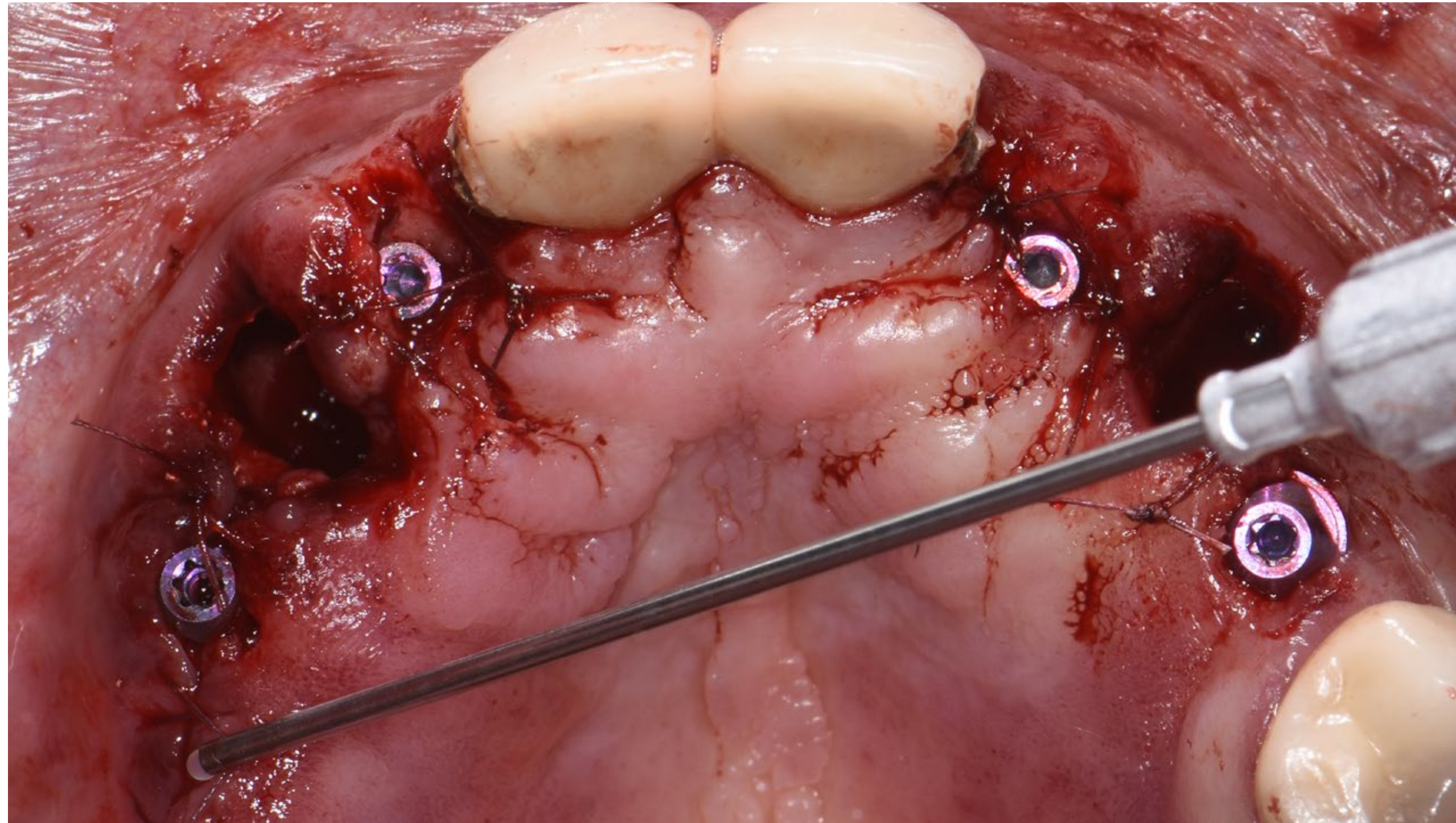


Placement of Straumann® Emdogain® around implants

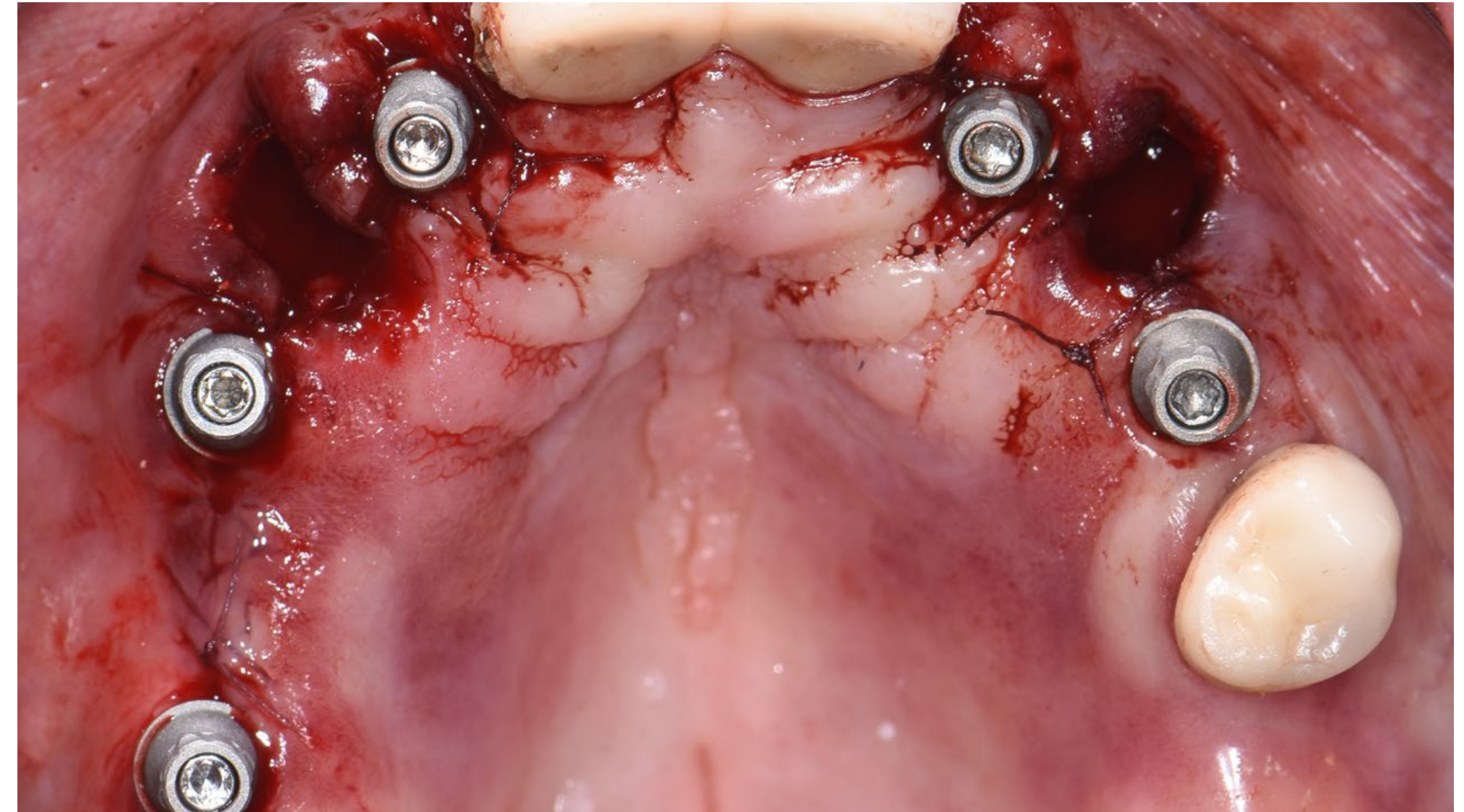


# Challenge 3: Limited posterior bone availability

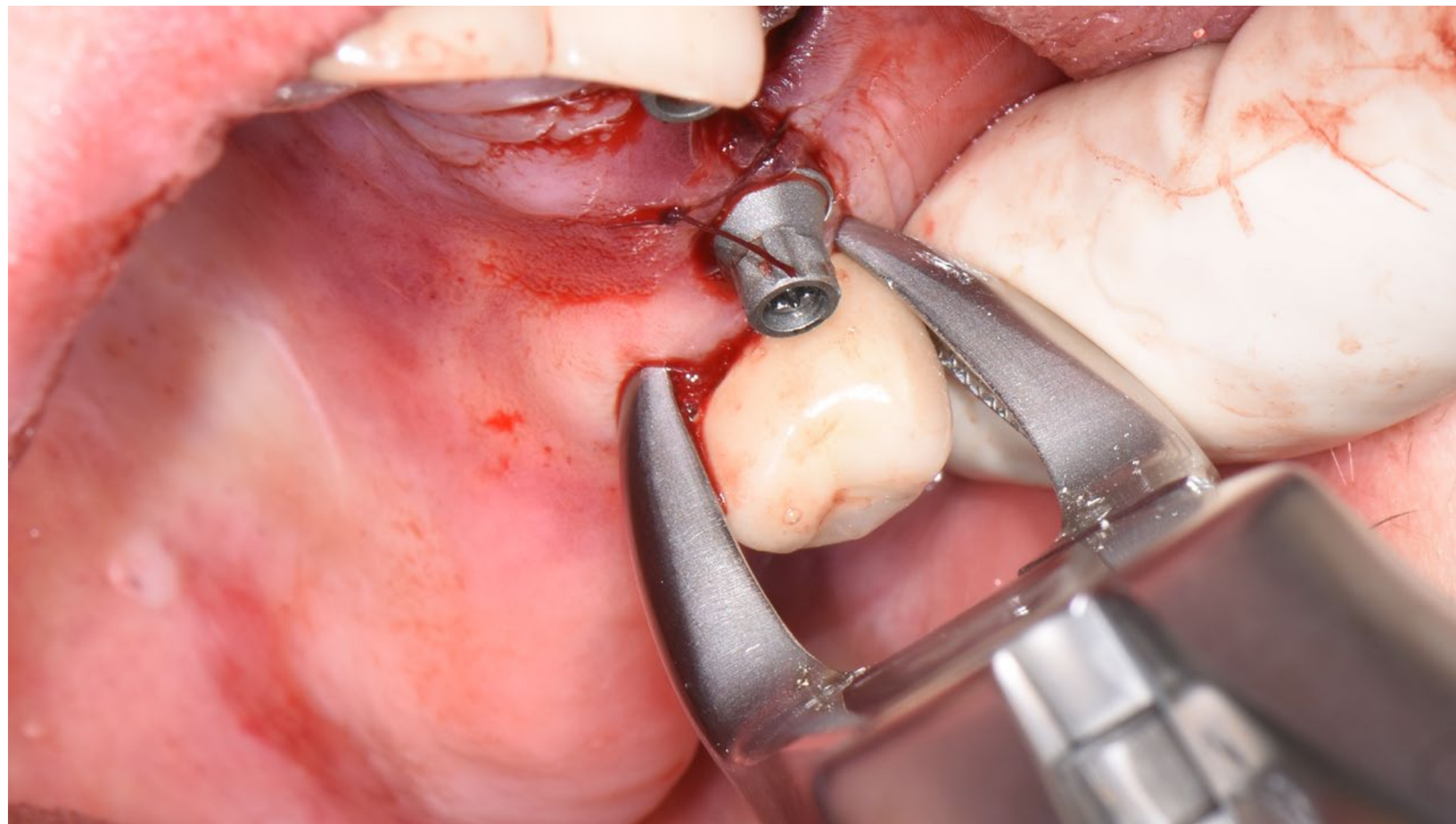
Clinical case



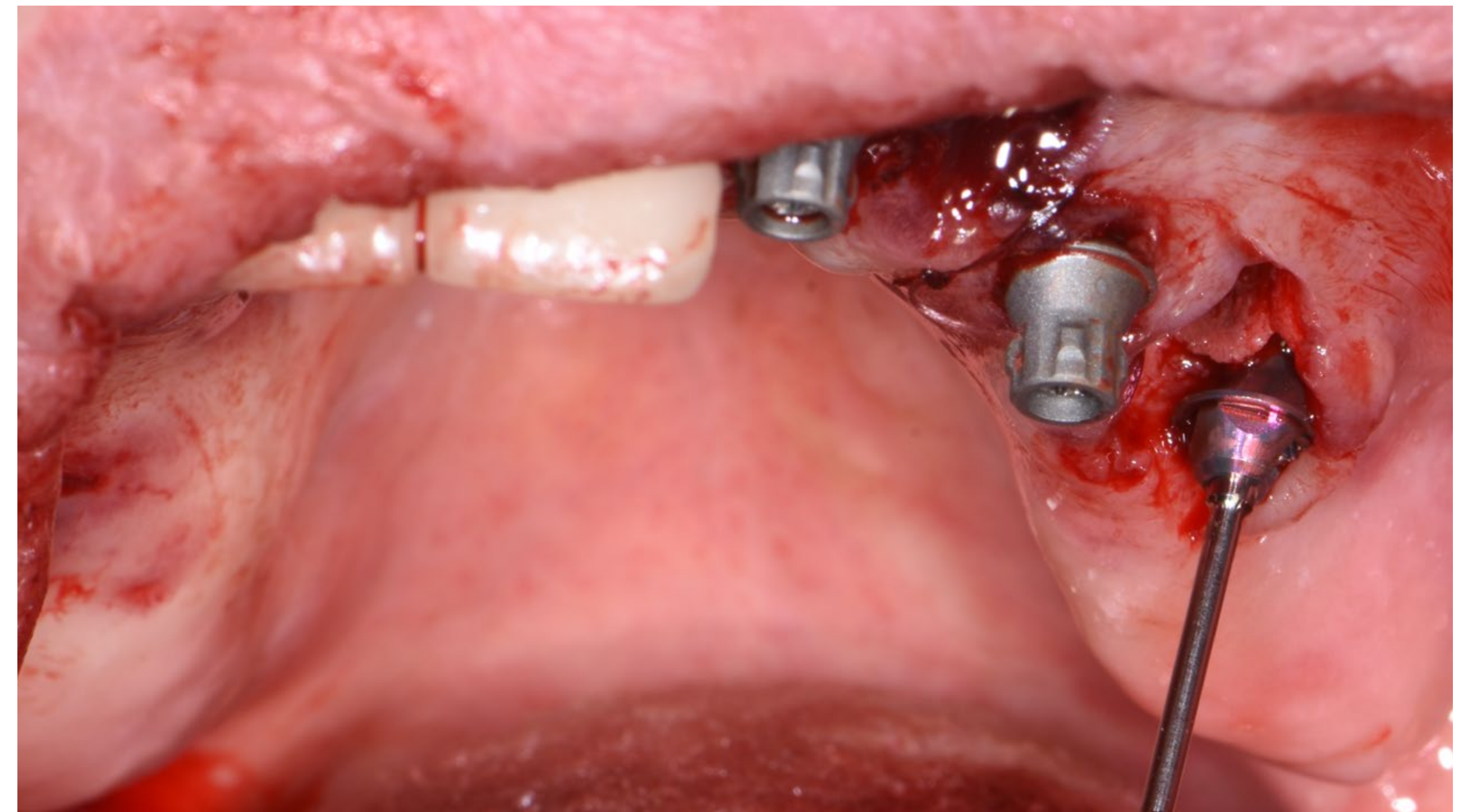
Placement Straumann® Emdogain after flap closure



Sutured site with Variobase® copings in place  
Second intraoral scan was performed



Extraction of the hopeless teeth

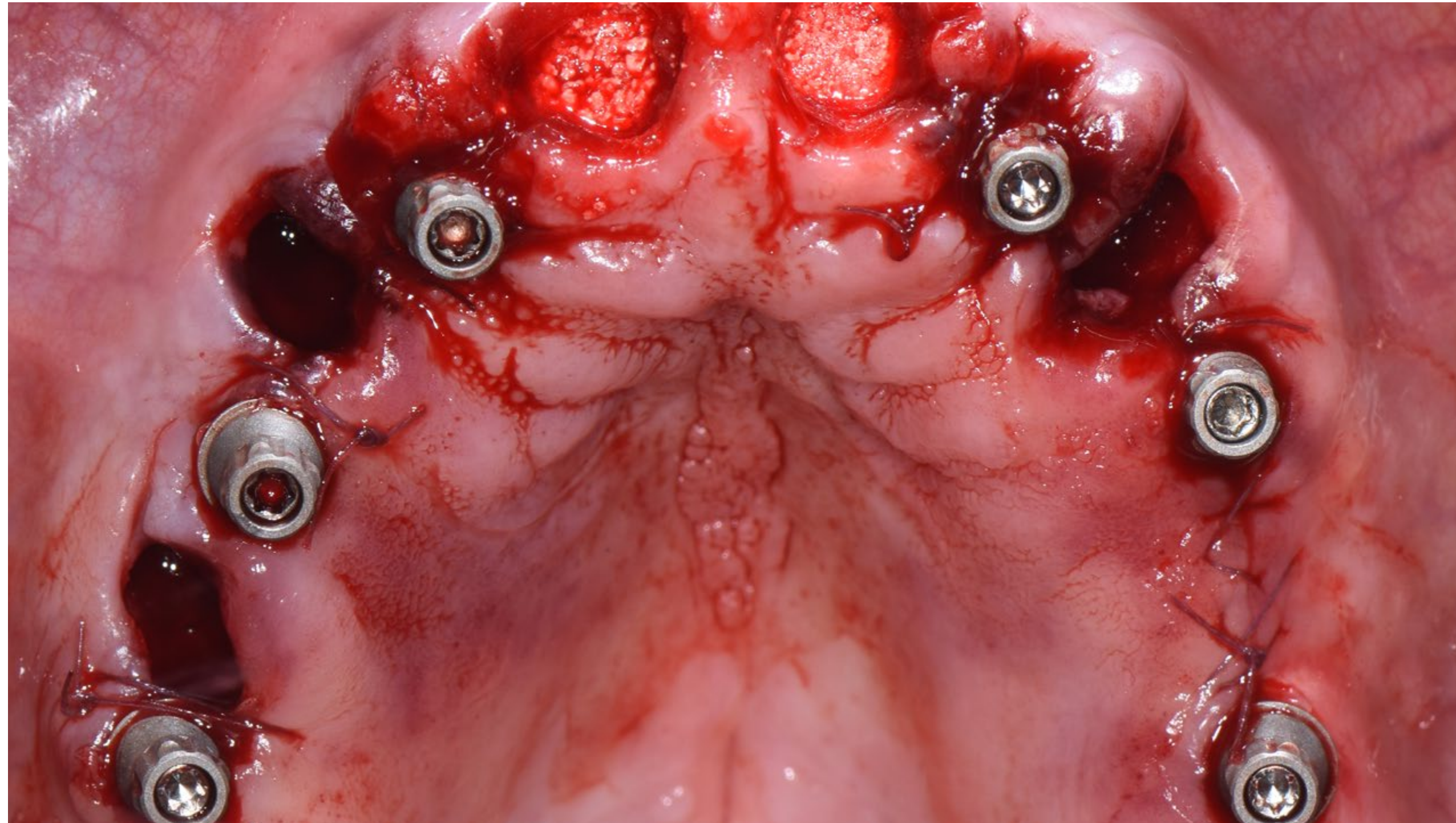


Placement of the Screw-retained Abutment

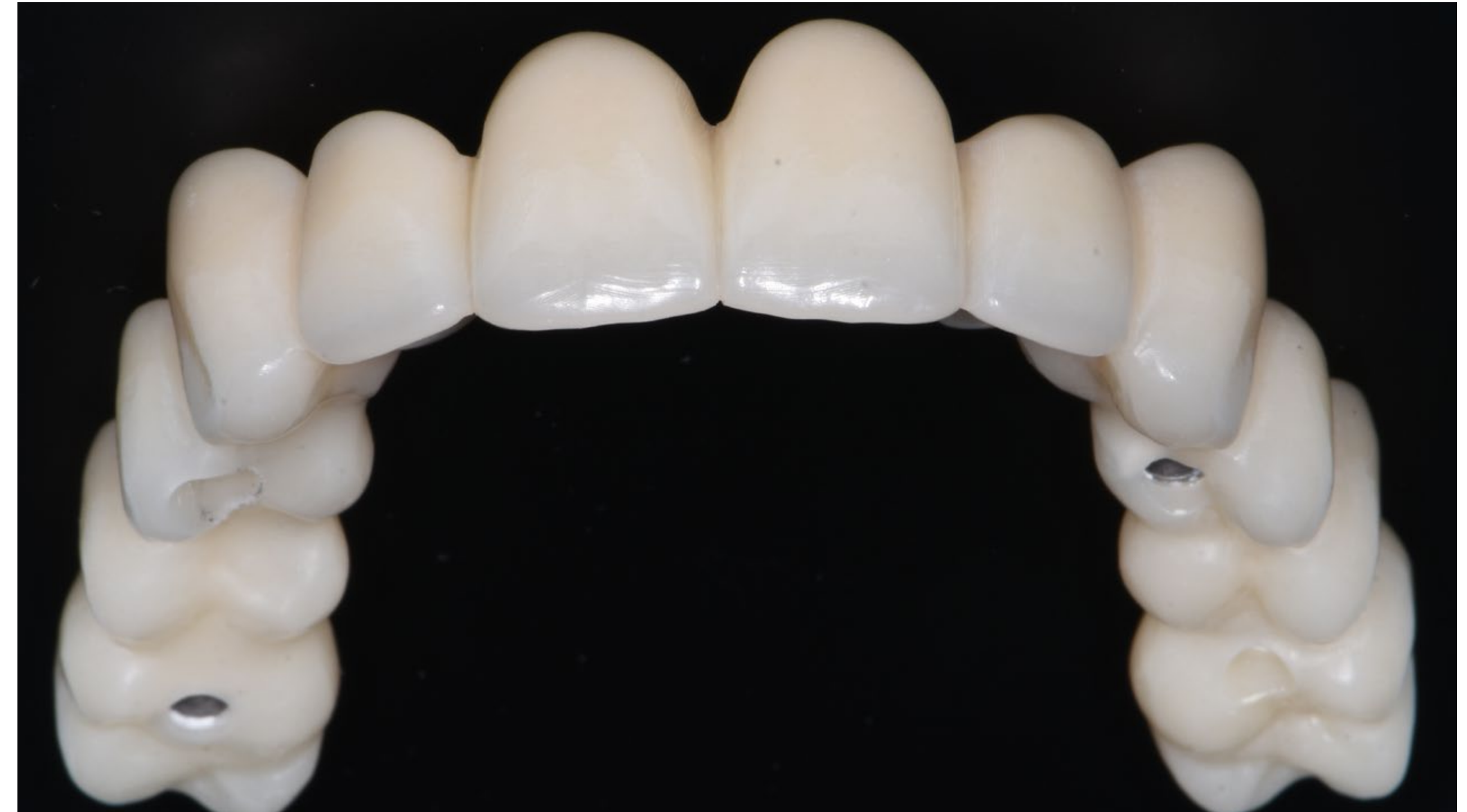

# Challenge 3: Limited posterior bone availability

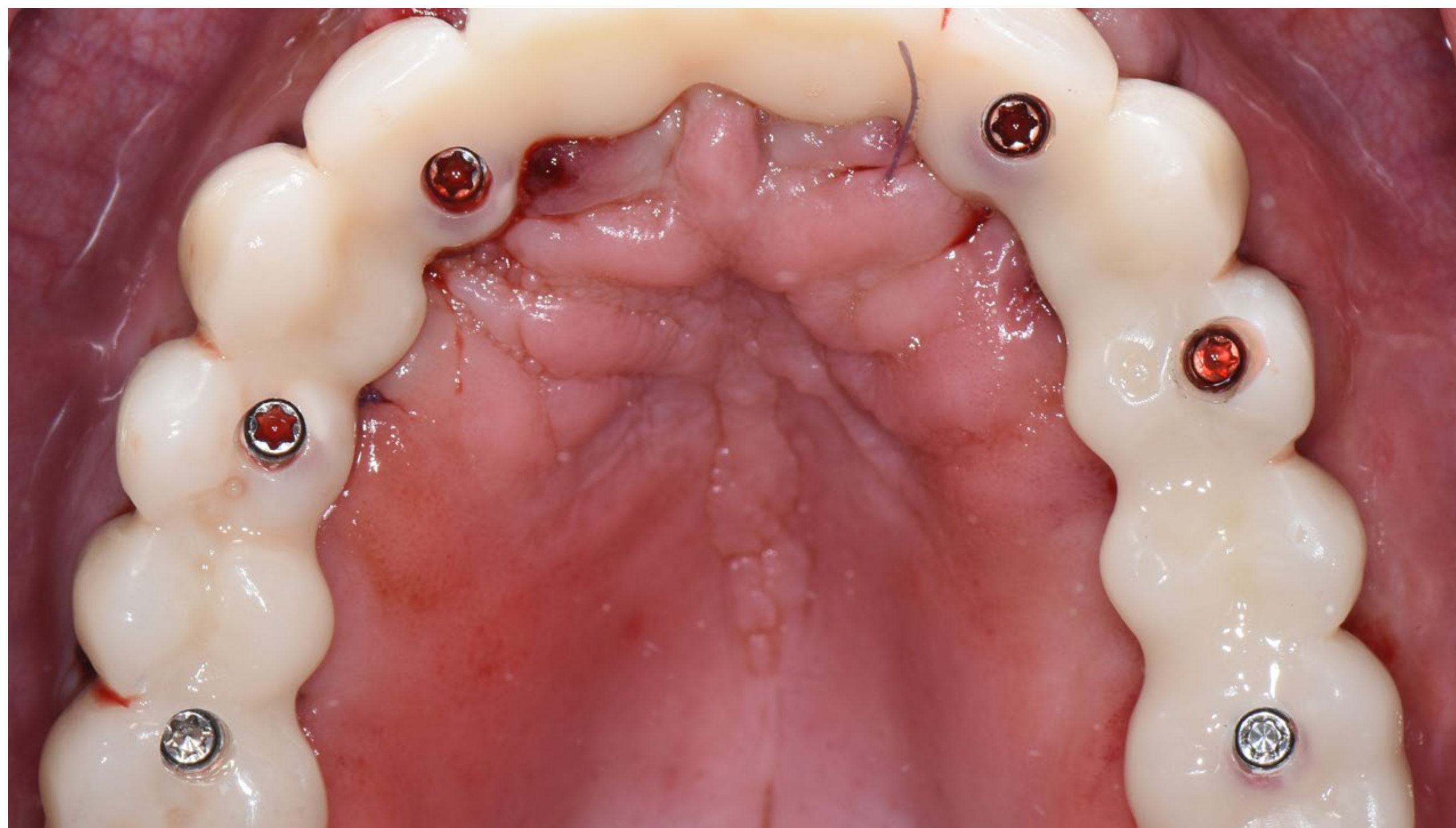
Clinical case



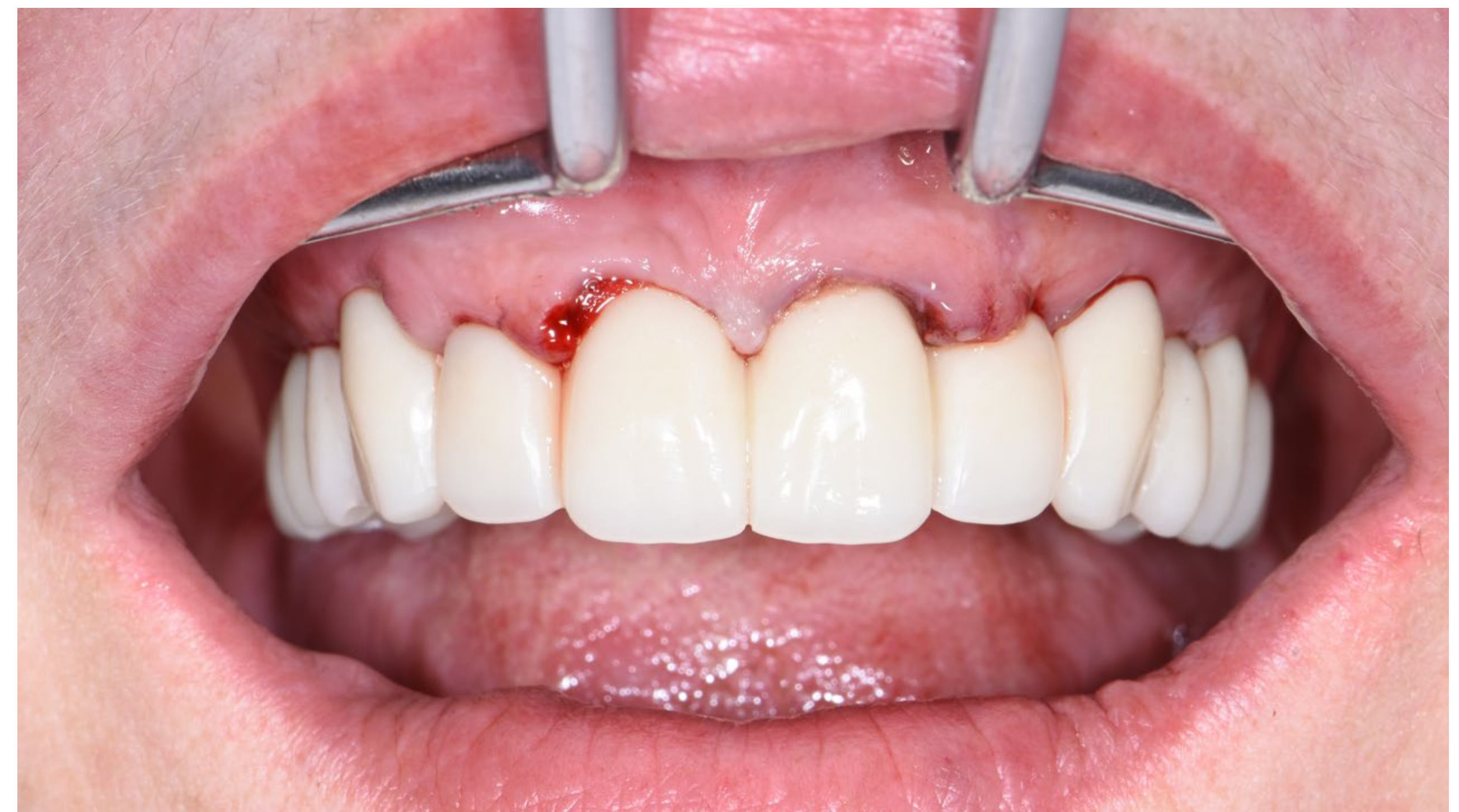Variobase® copings in place  
The third intraoral scan was performed



Finished provisional bridge



Placement of the provisional bridge

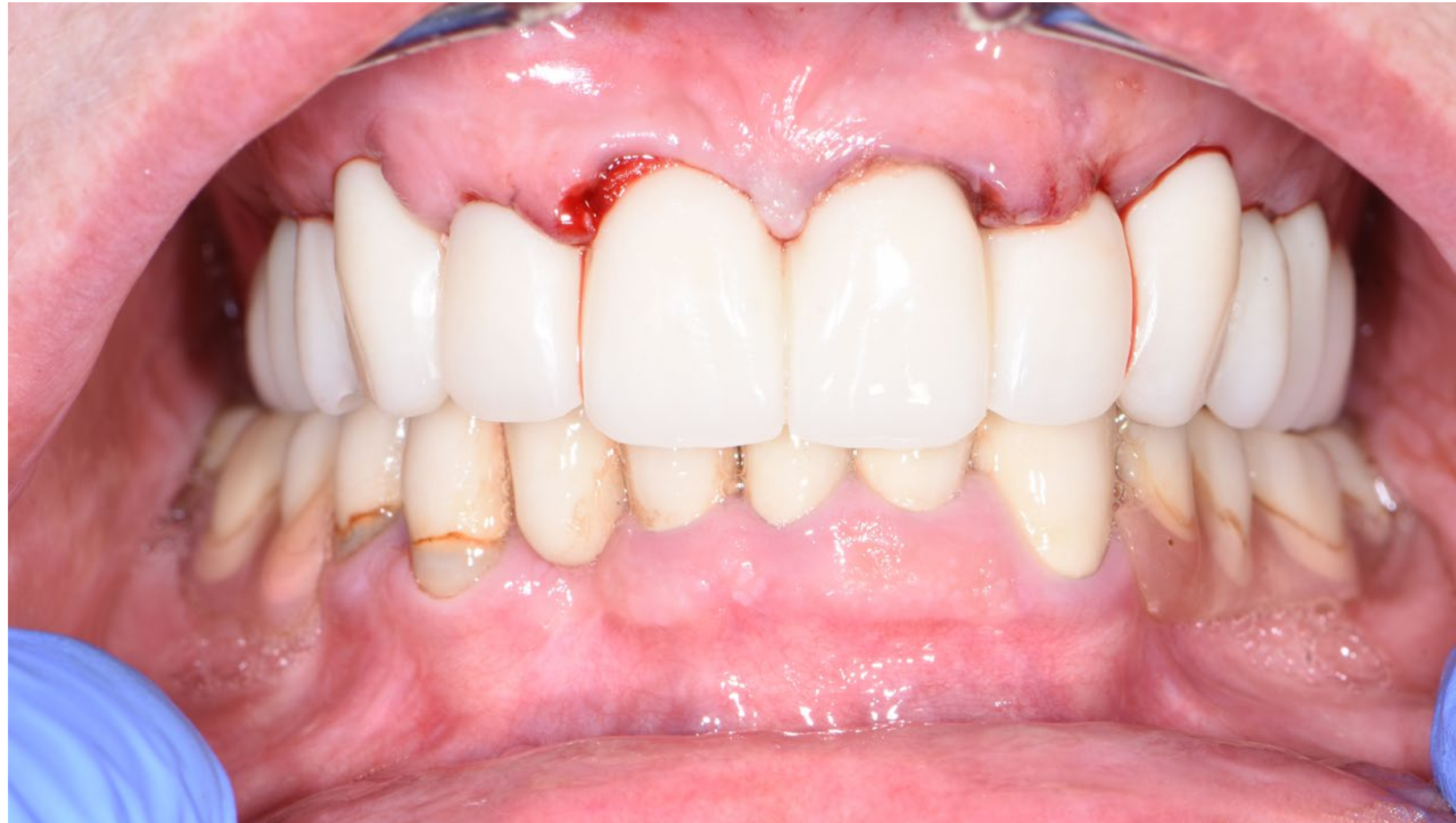

Placement of the provisional bridge

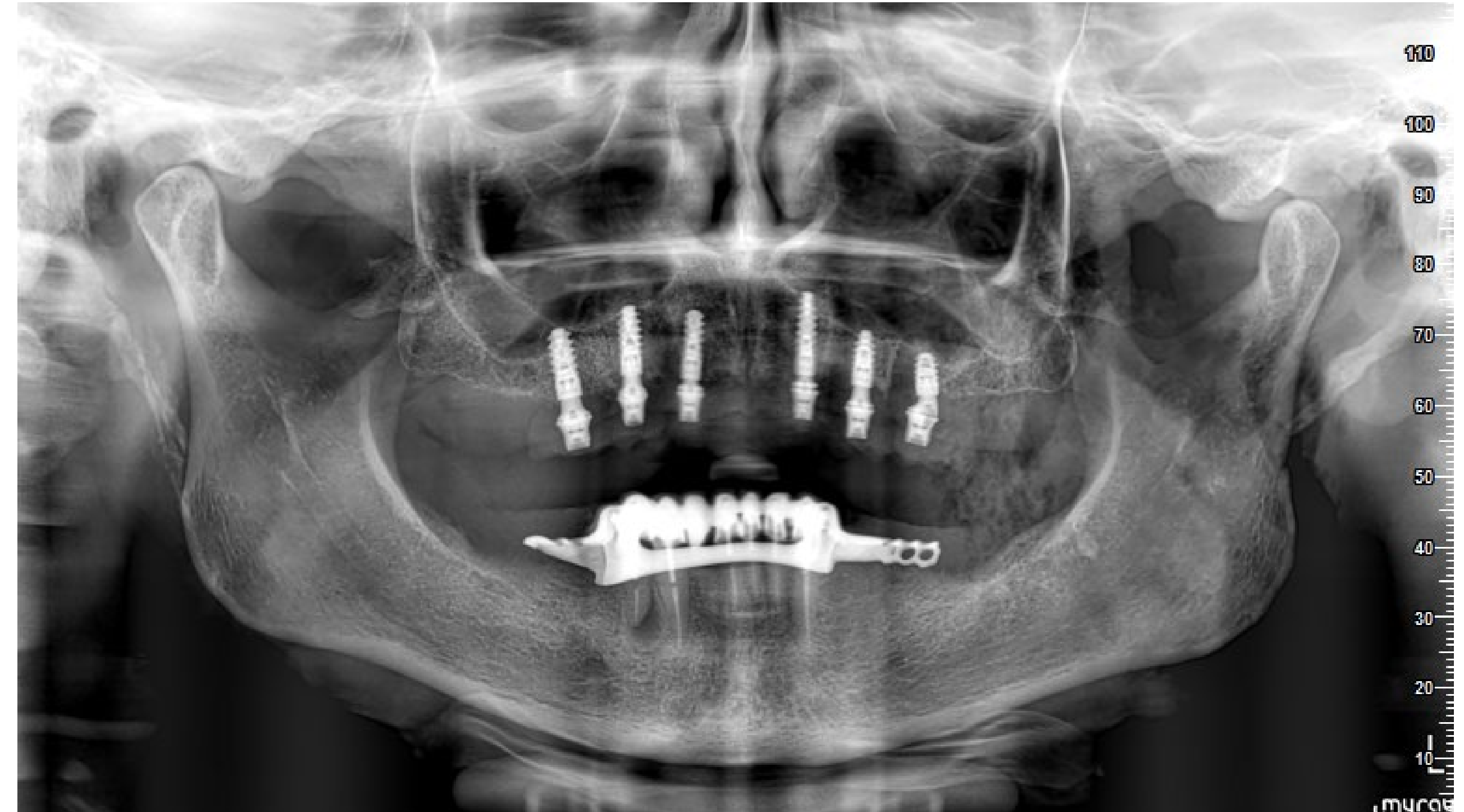

# Challenge 3: Limited posterior bone availability

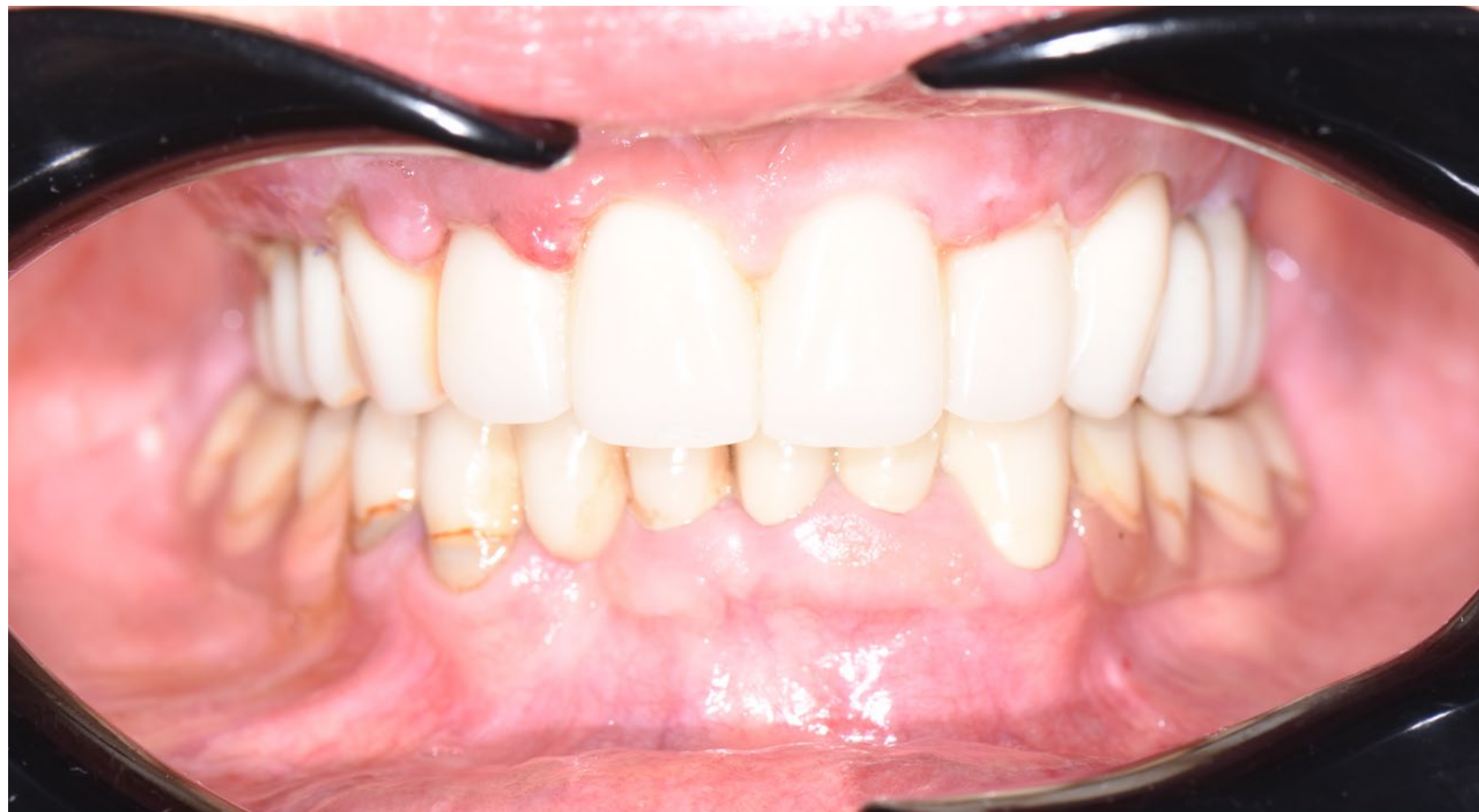Clinical case



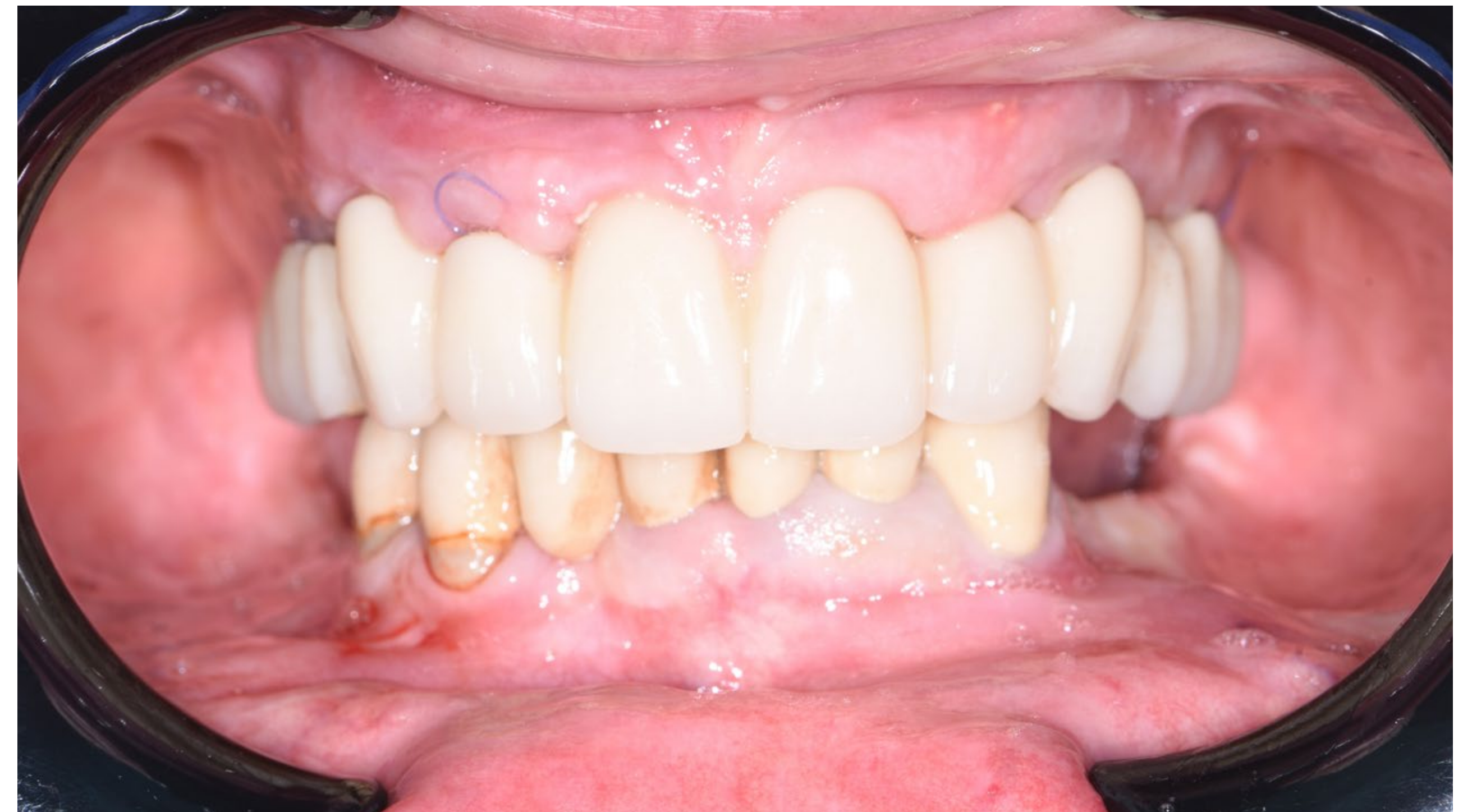Provisional restoration in place  
Final bridge will be placed in six months



Postoperative panoramic radiograph



Two days healing after the surgery

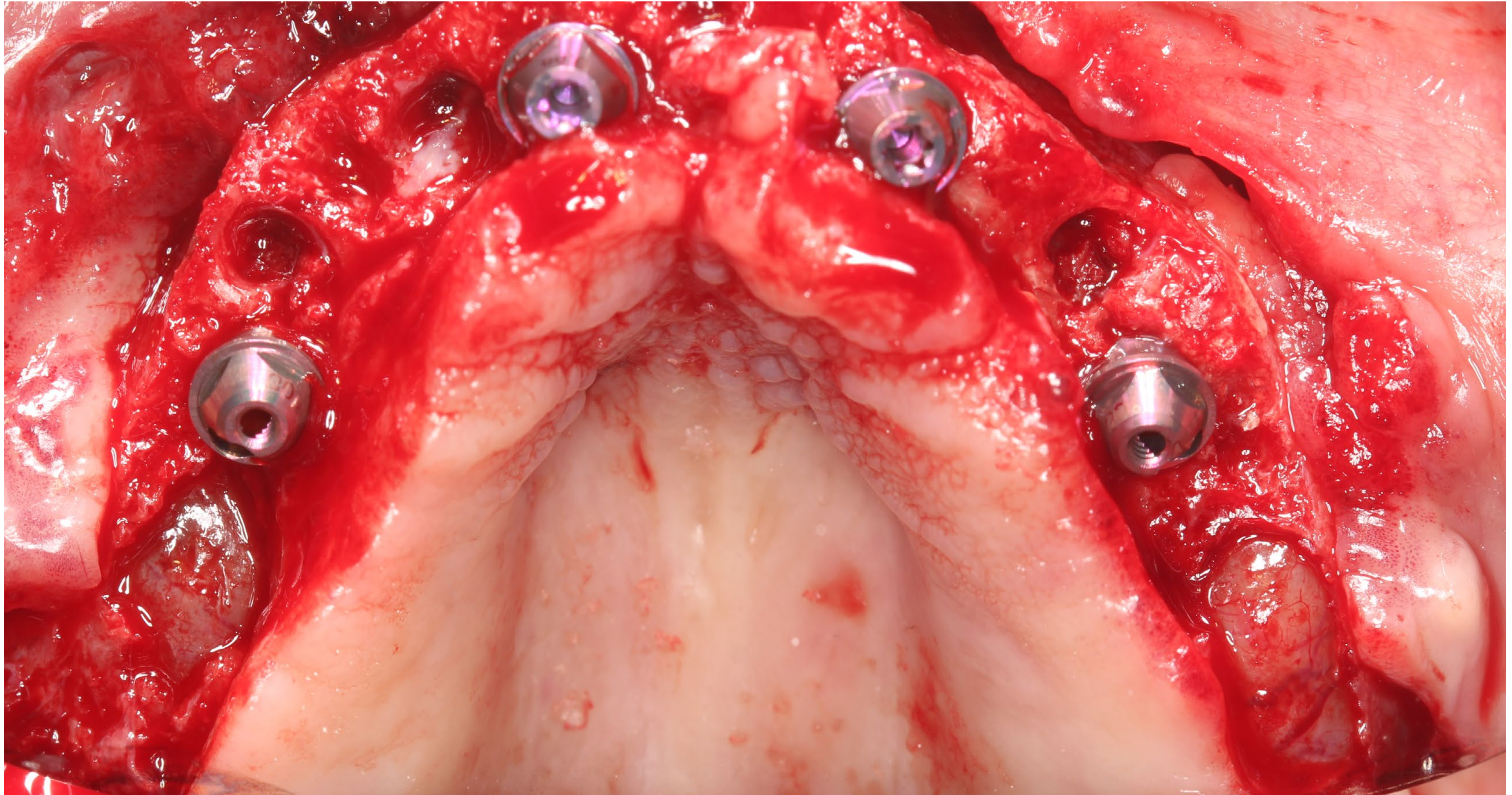


One week healing after the surgery



# Challenge 4: Rework of failed implants

General recommendations and clinical case from Dr. Pedro Rodrigues





# Challenge 4: Rework of failed implants

## General recommendations



### General recommendations from Dr. Pedro Rodrigues

- Remove implants as atraumatically as possible
- Remove contaminations
- Bone reduction (sinus lift if necessary)
- All steps should be prosthetic driven
- Platelet-rich fibrin (PRF) to improve soft tissue healing conditions

Dr. Rodrigues graduated in 2002 and earned a master's degree in oral rehabilitation in 2010. Additionally, Dr. Rodrigues spent four years working in the Dr. Paulo Malo clinic in Porto. Since 2010 Dr. Rodrigues has given international courses, with live surgeries and training in implantology. Dr. Rodrigues has treated more than 1,000 full-arch cases with immediate rehabilitation on four implants and has developed his own treatment approach.



**Dr. Pedro Rodrigues**  
BChD, MChD (MFOS),  
Private practice,  
Porto, Portugal

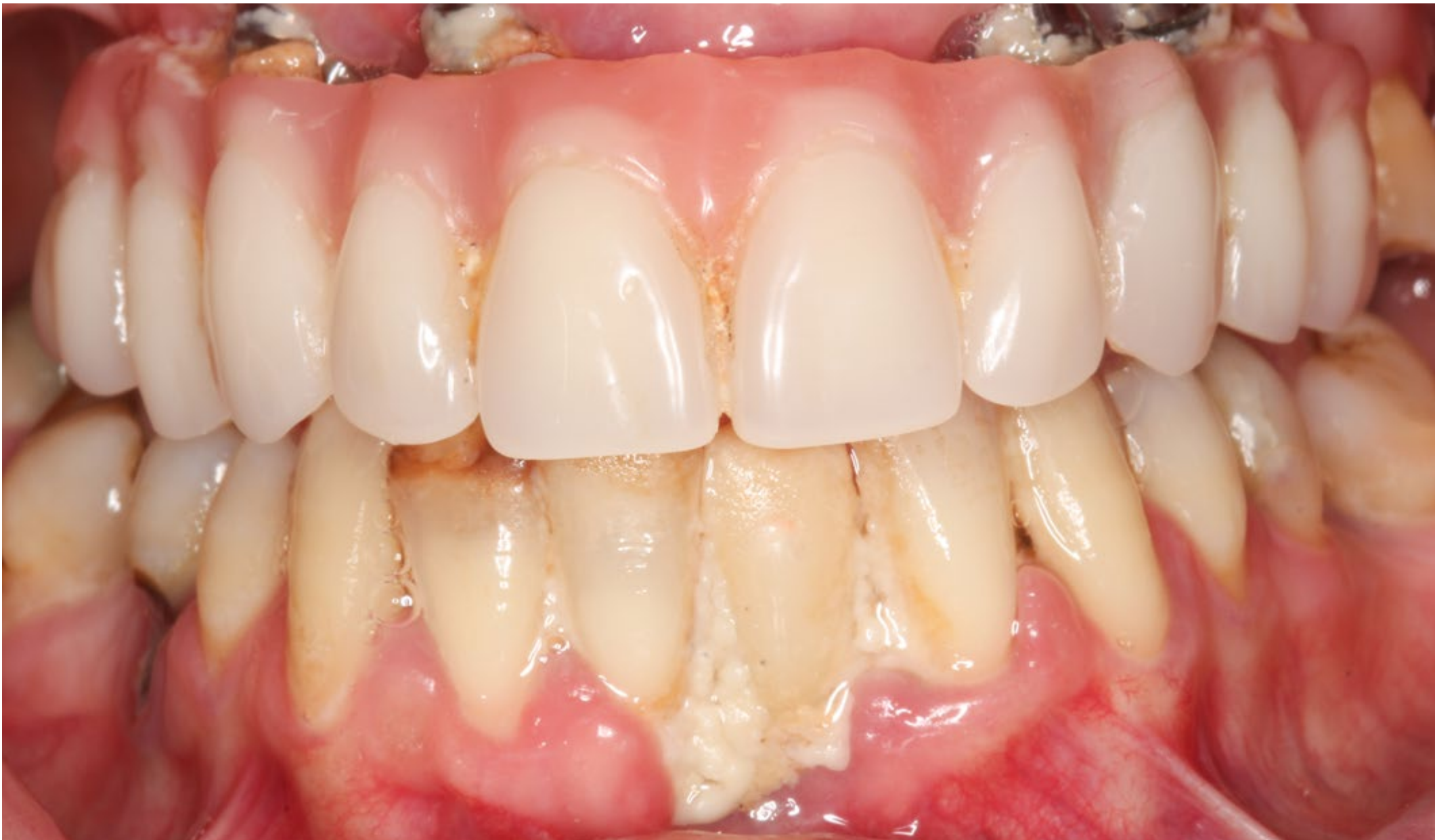

# Challenge 4: Rework of failed implants

Clinical case



## Initial situation



## Patient information

Age	46
Jaw	Maxilla
Health status	Good
Height of smile line	High
Bone type	Soft
Infections at implantation site	Yes
Bone anatomy defects	Very atrophic because of a previous reduction
Risks	No

## Additional difficulties

Moderate resorption in the maxilla and limited bone due to the failed treatment
Soft bone quality
Augmented vertical dimension

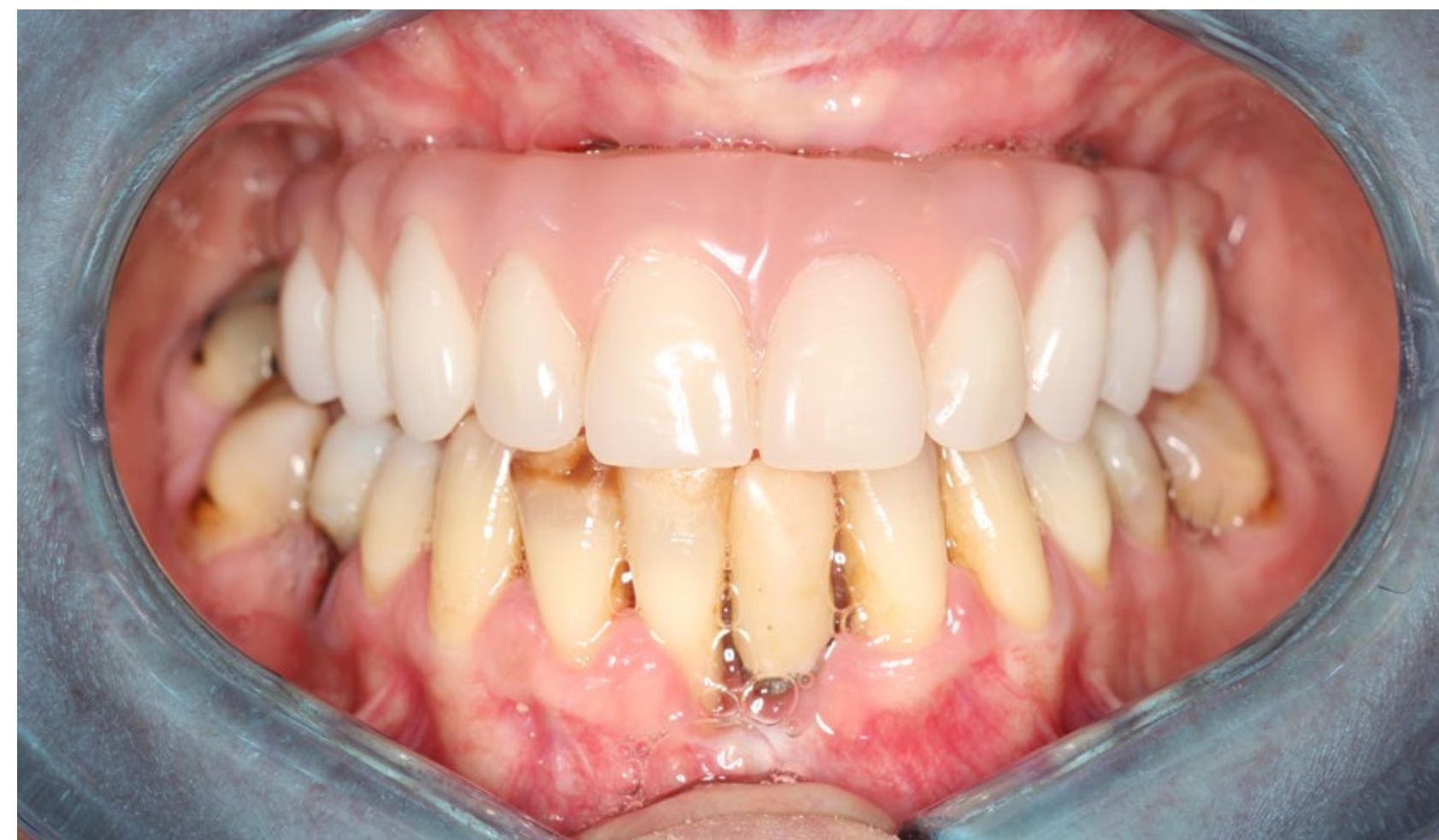

# Challenge 4: Rework of failed implants

Clinical case



## Provisional prosthesis



## Treatment

- Fixed immediate rehabilitation on four implants
- Bone reduction
- Tilting of the implant due to lack of posterior bone height

**Temporary restoration:** acrylic provisional prosthesis

**Planned final prosthesis:** one-piece titanium milled bar with acrylic teeth

## Materials used



Straumann® BLX Ø 4.5 mm  
RB SLActive® 10 mm, 16 mm,  
Roxolid®



Screw-retained abutments,  
straight, GH 2.5 mm  
Screw-retained abutments,  
30° angled, GH 4.5 mm



# Challenge 4: Rework of failed implants

Clinical case



## My experience



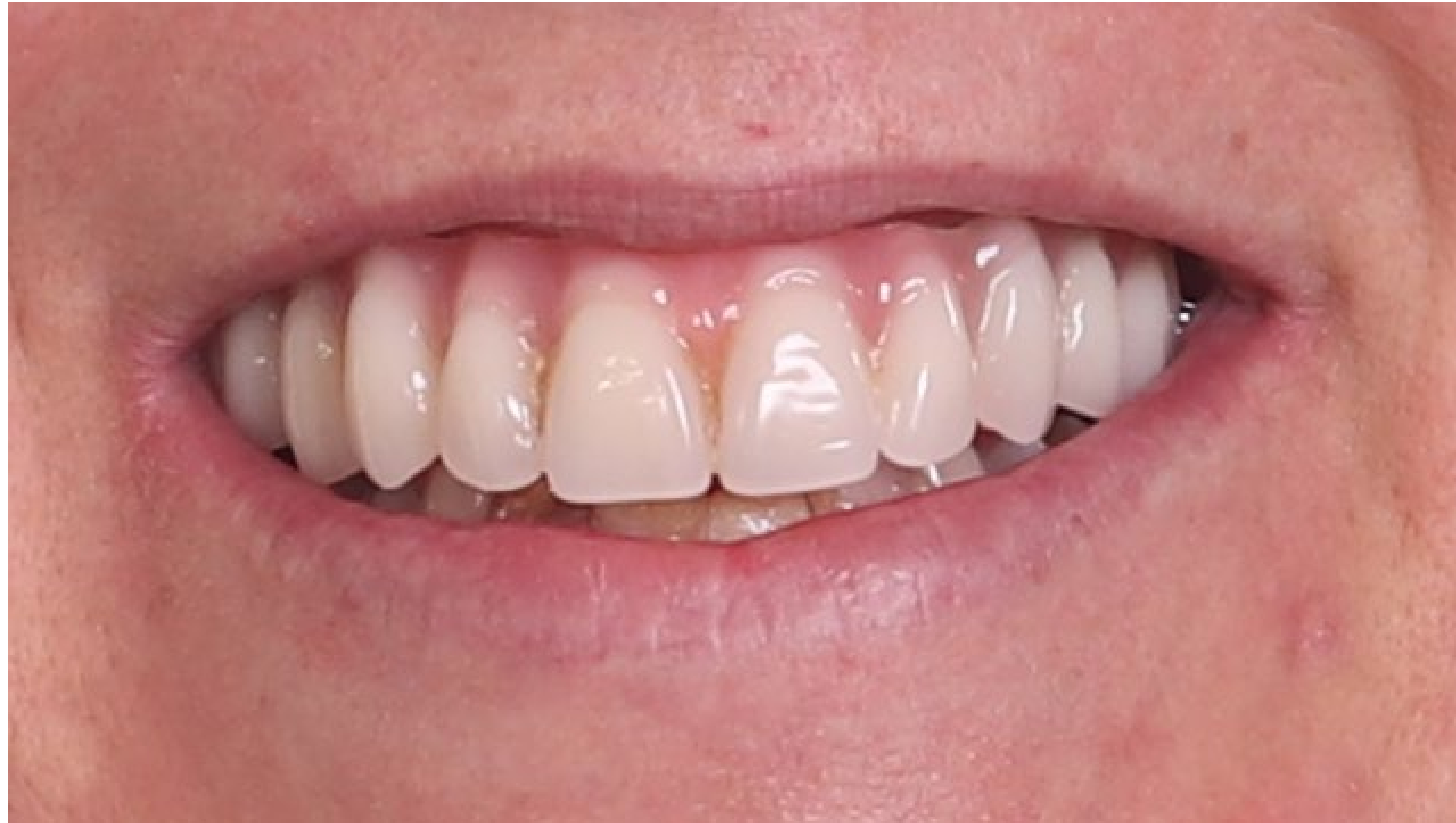Dr. Pedro Rodrigues  
BChD, MChD (MFOS)

*“I’m very impressed by the simplicity of the surgical protocol, the implant behavior in soft and hard bone, very easy to handle, and the possibility to obtain high primary stability even in softer bone types. Making the treatment even more repeatable and predictable, offering the possibility to expand the number of patients.”*

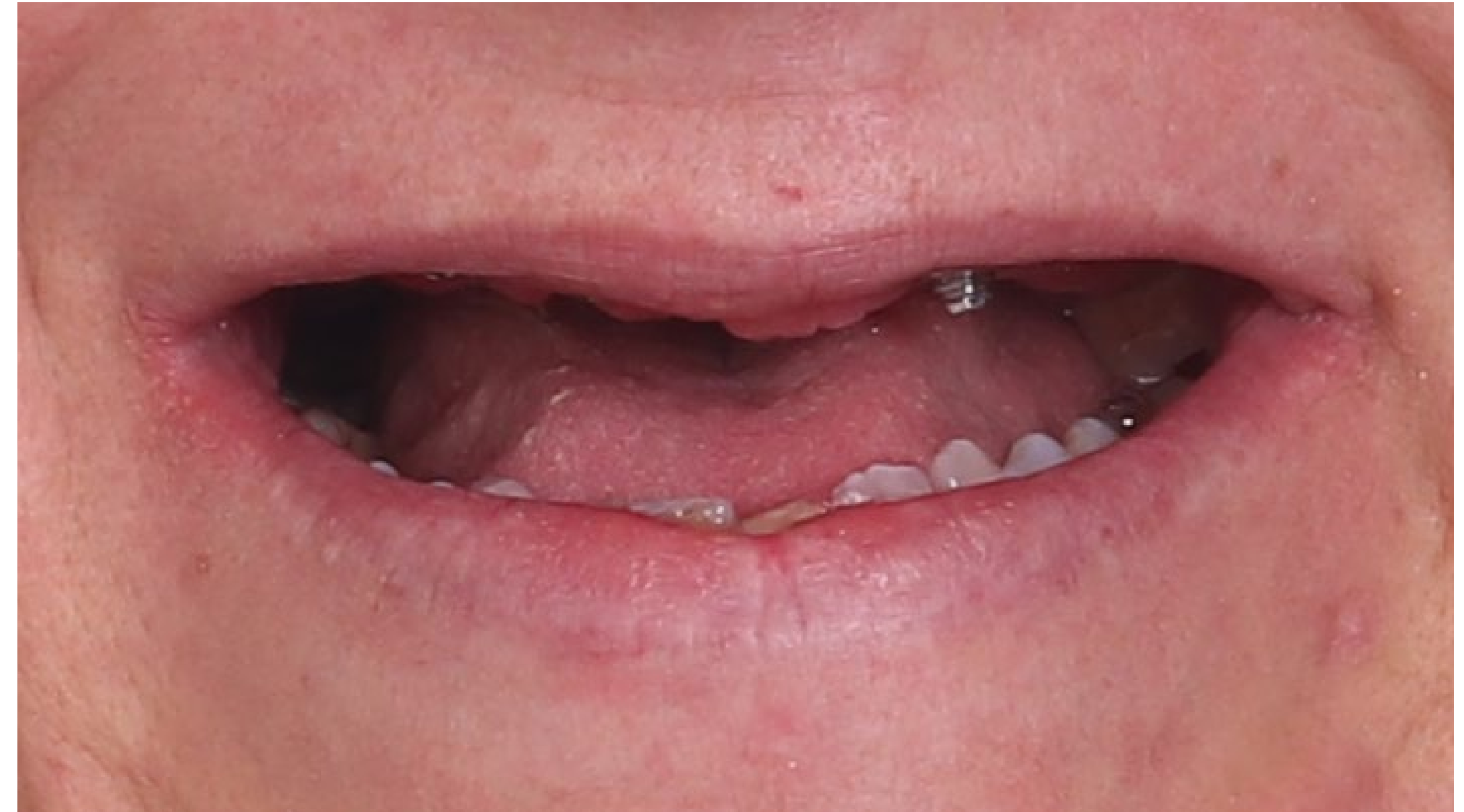

# Challenge 4: Rework of failed implants

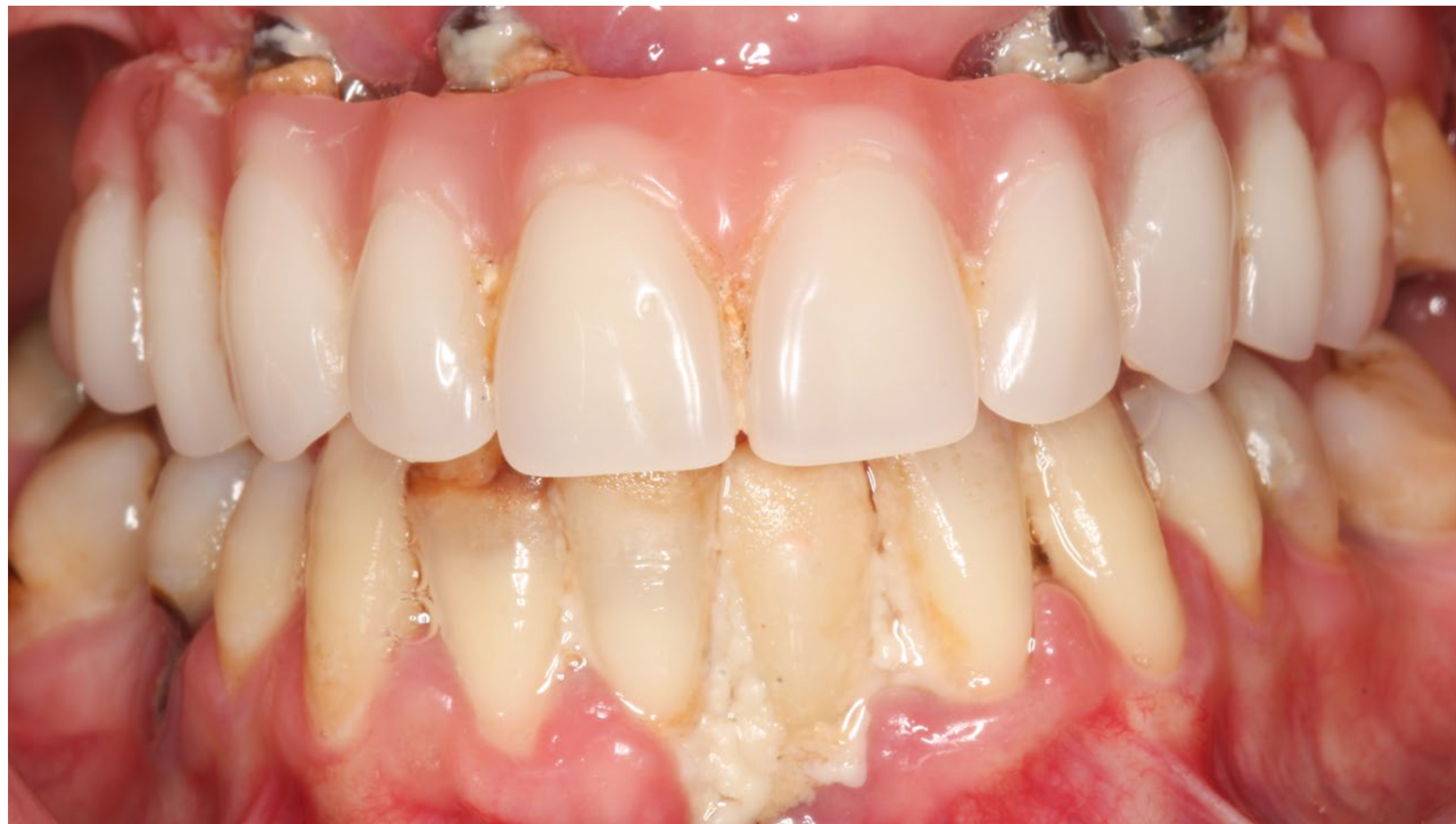Clinical case



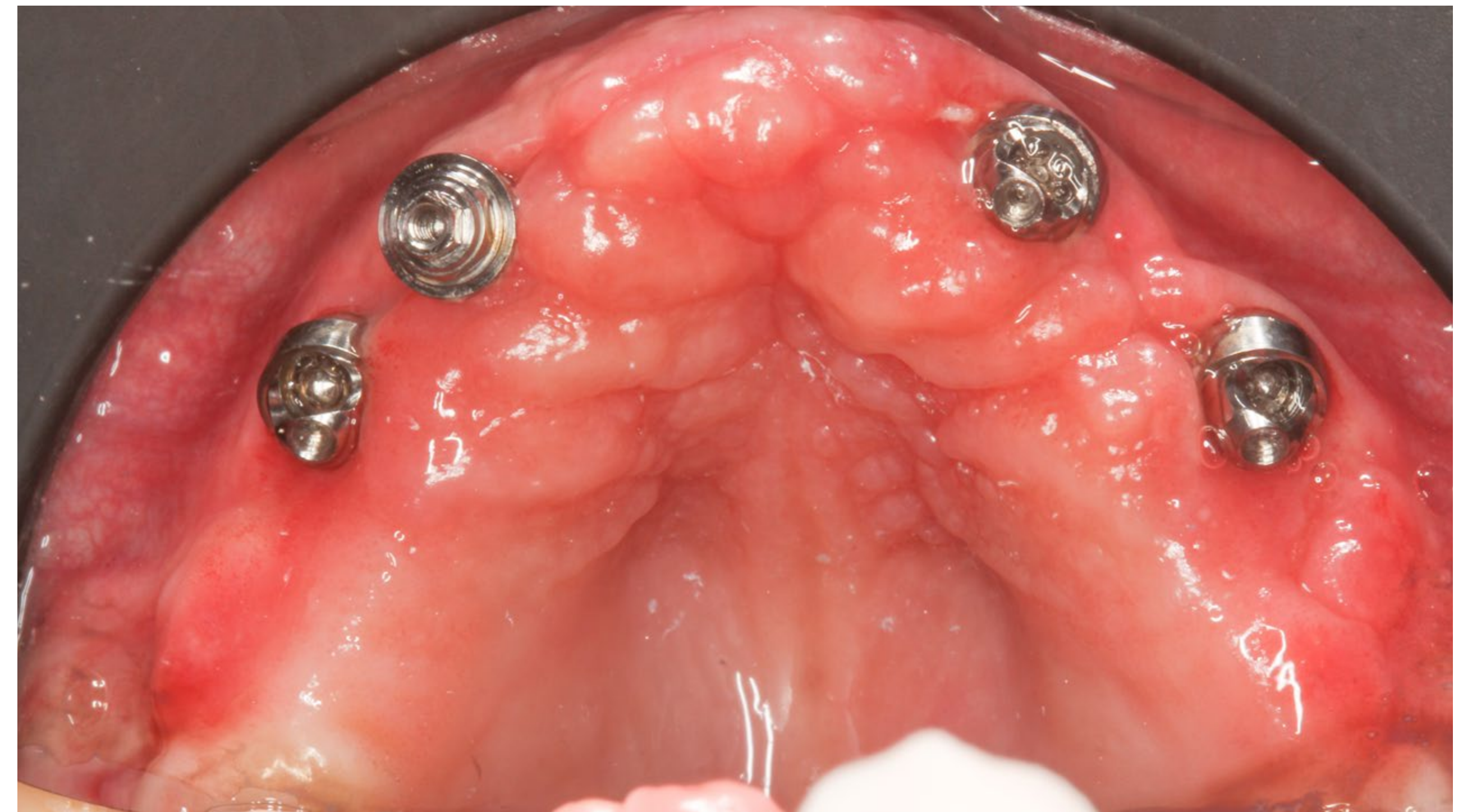Initial clinical situation  
Transition line is visible while smiling



Initial clinical situation without fixed prosthesis



Initial clinical situation with fixed prosthesis

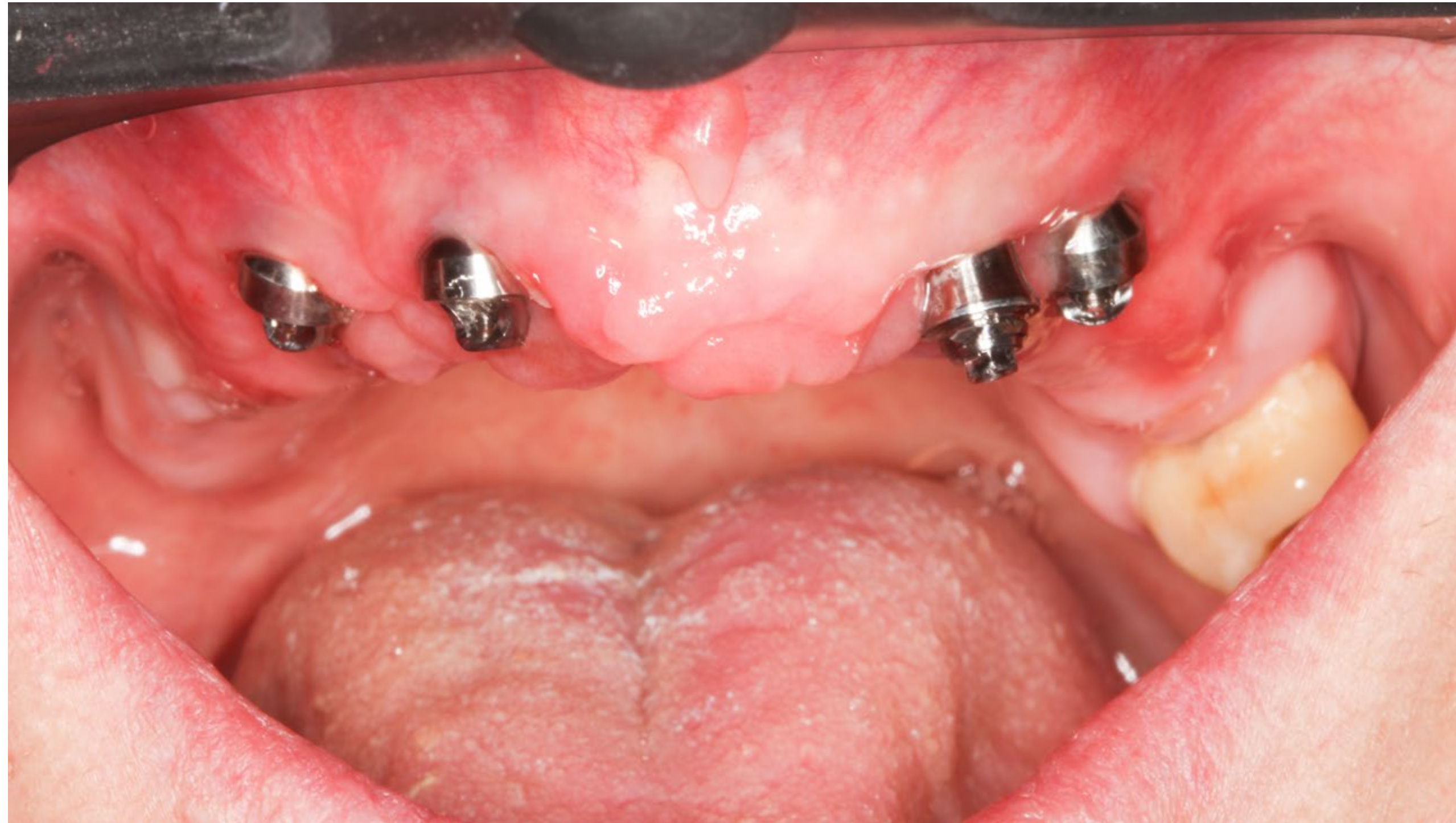


Occlusal view

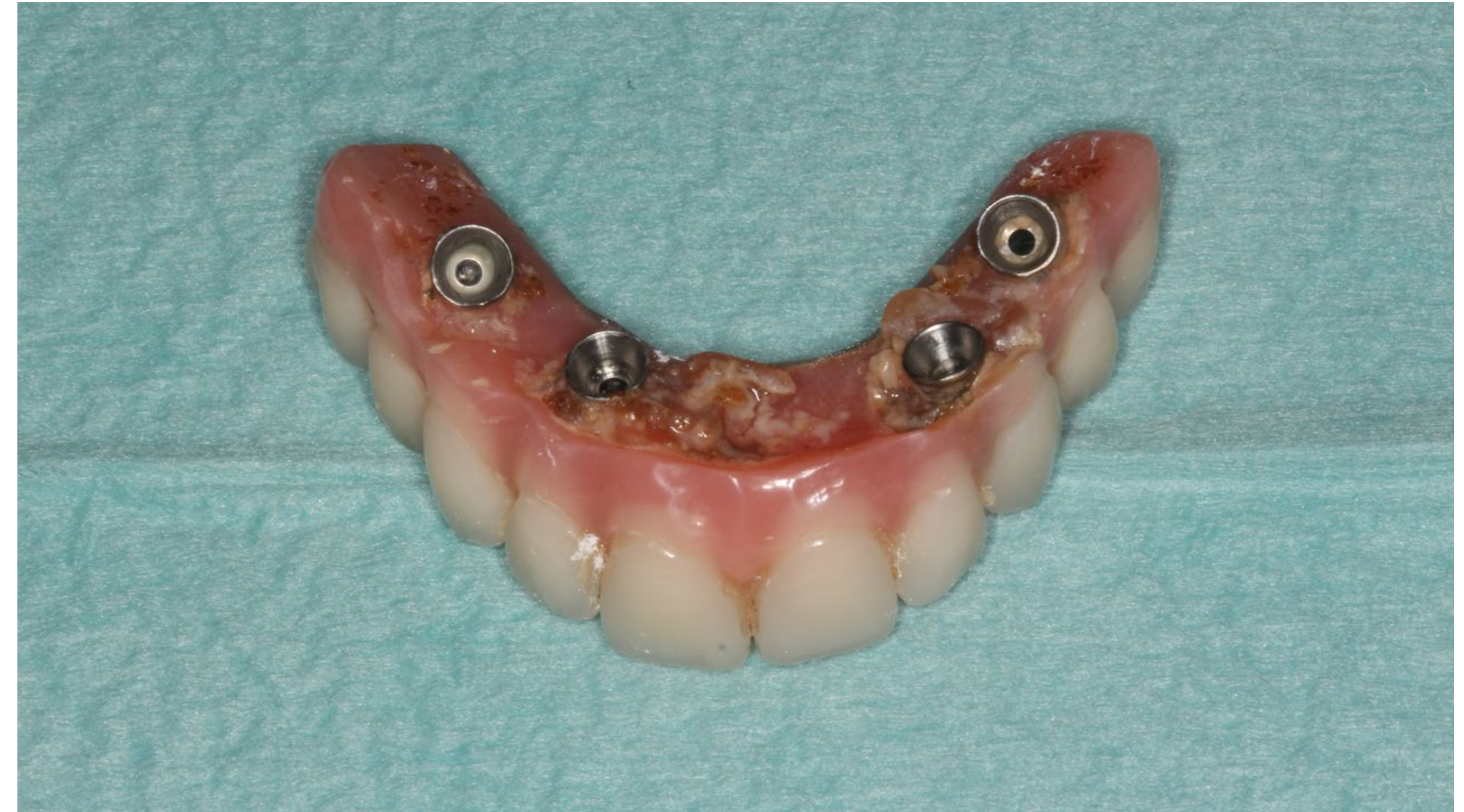

# Challenge 4: Rework of failed implants

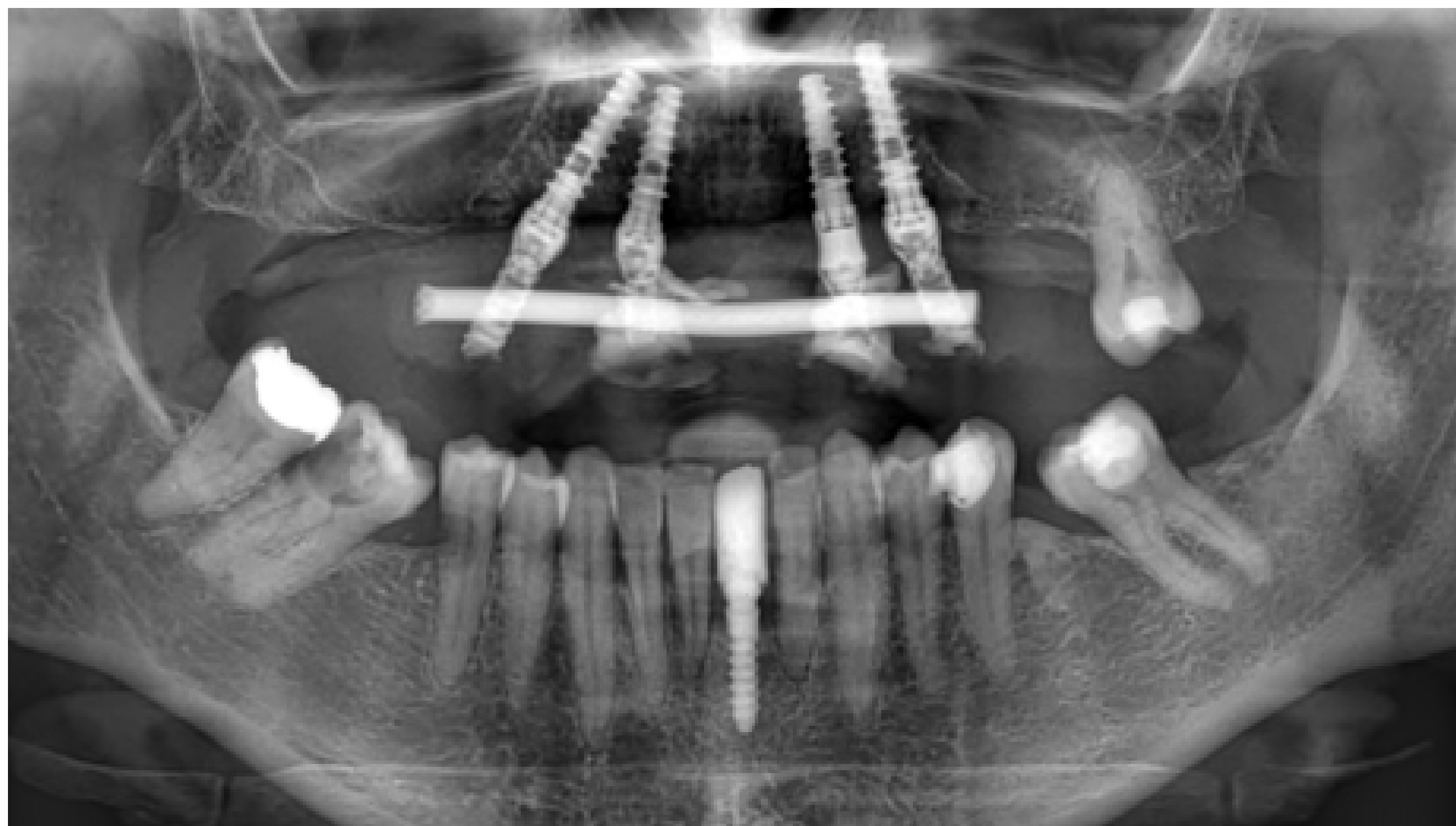Clinical case



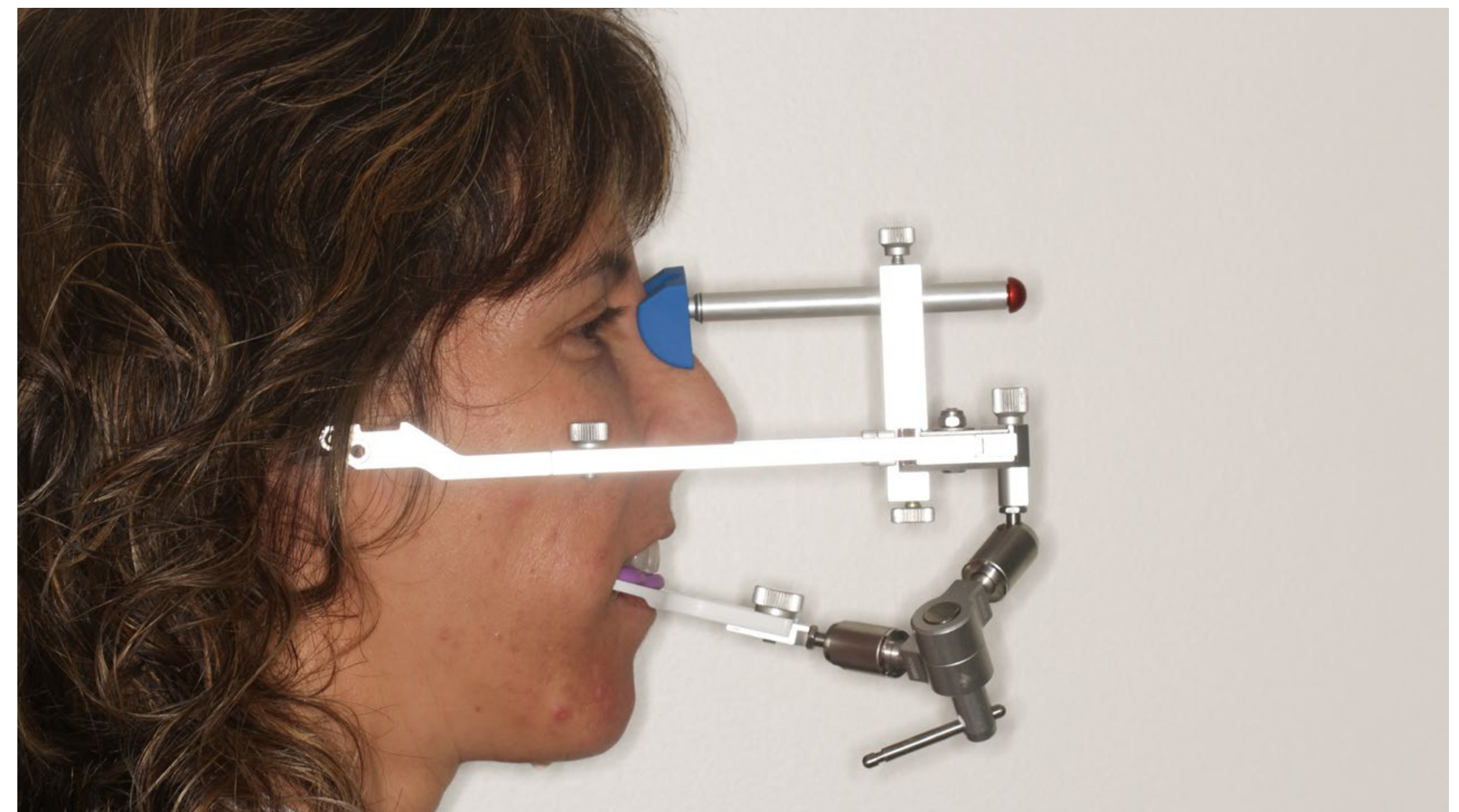
Initial clinical situation  
Frontal view



Old prosthesis



Initial clinical situation  
Preoperative panoramic radiograph



Treatment planning

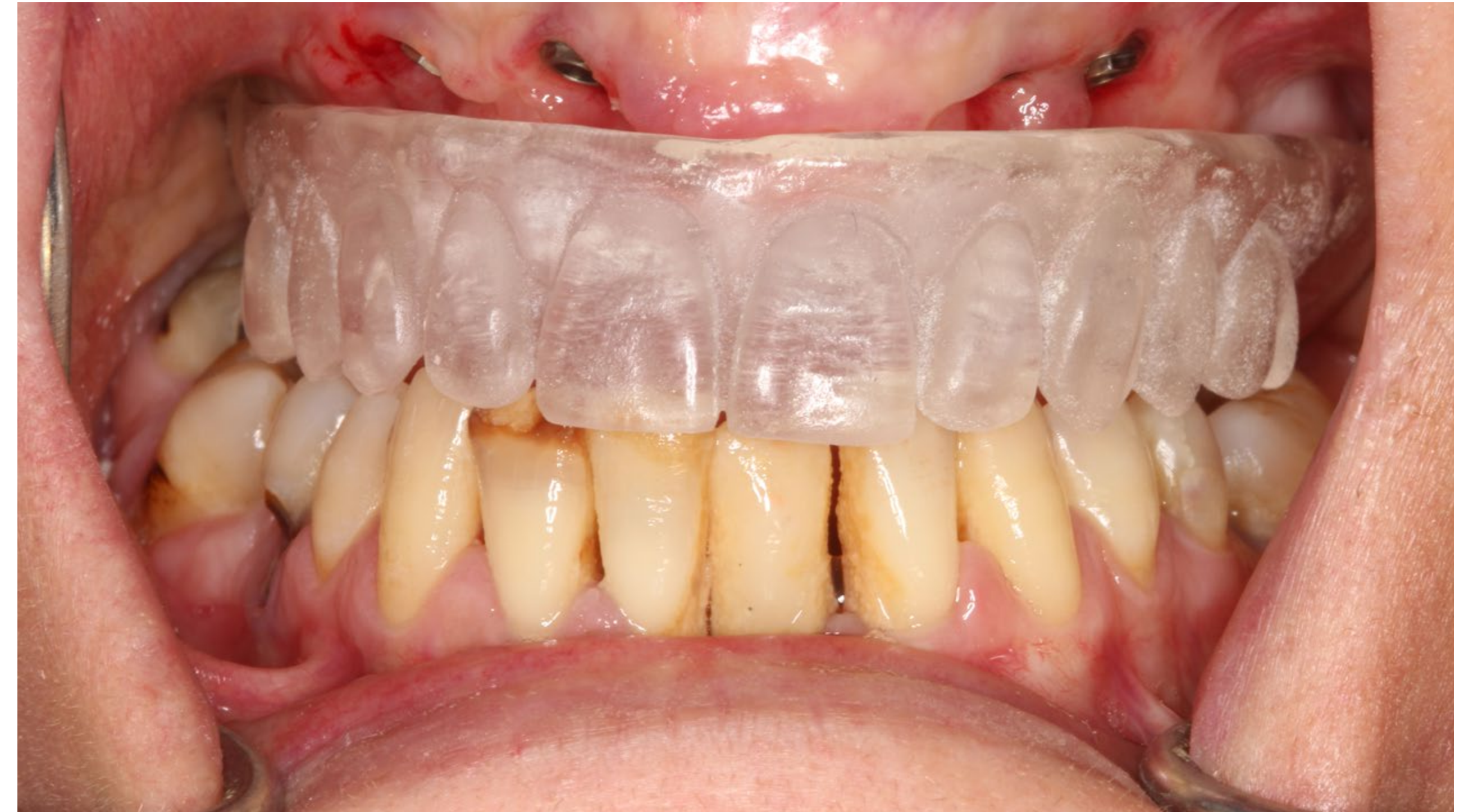

# Challenge 4: Rework of failed implants

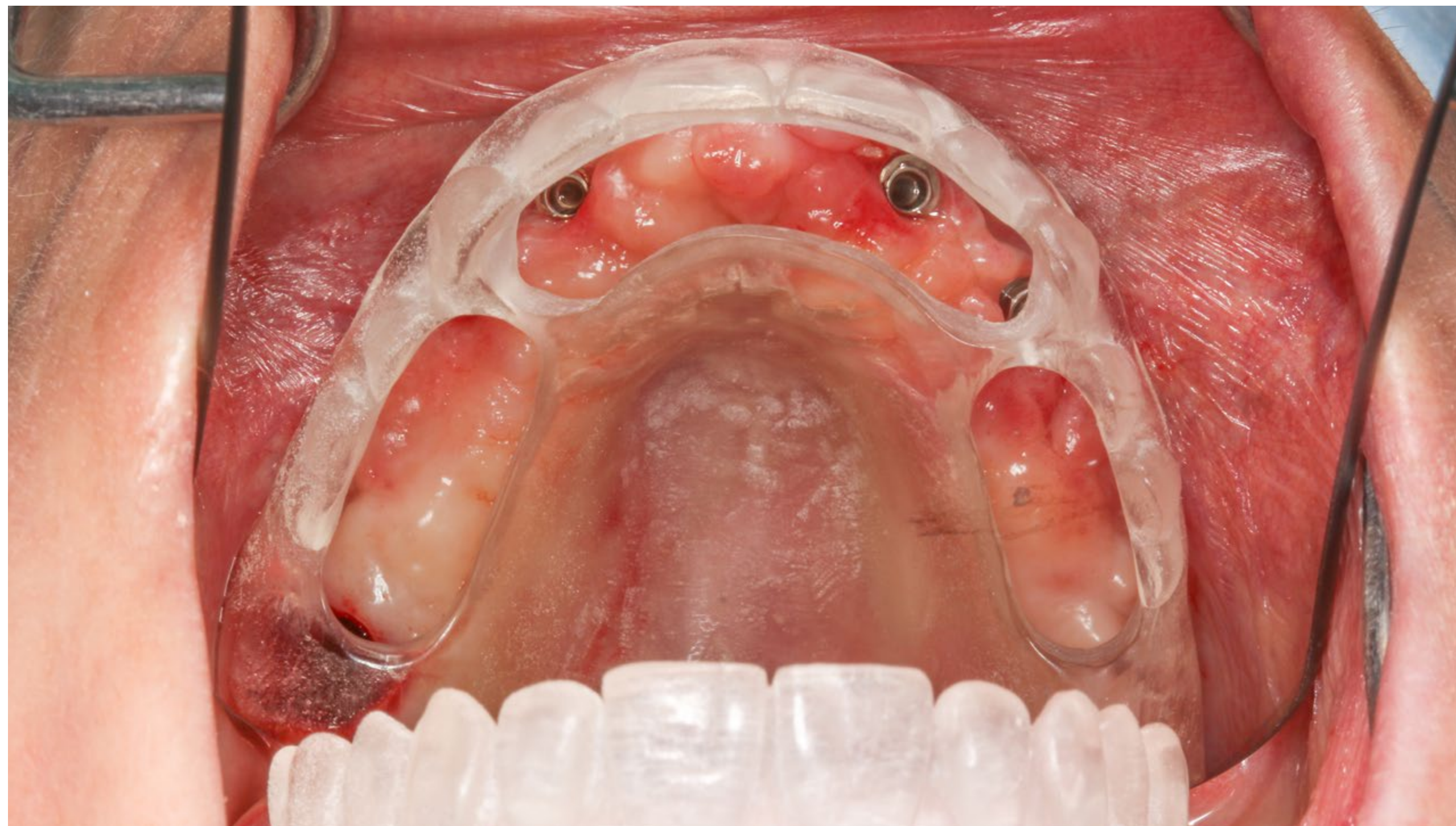Clinical case



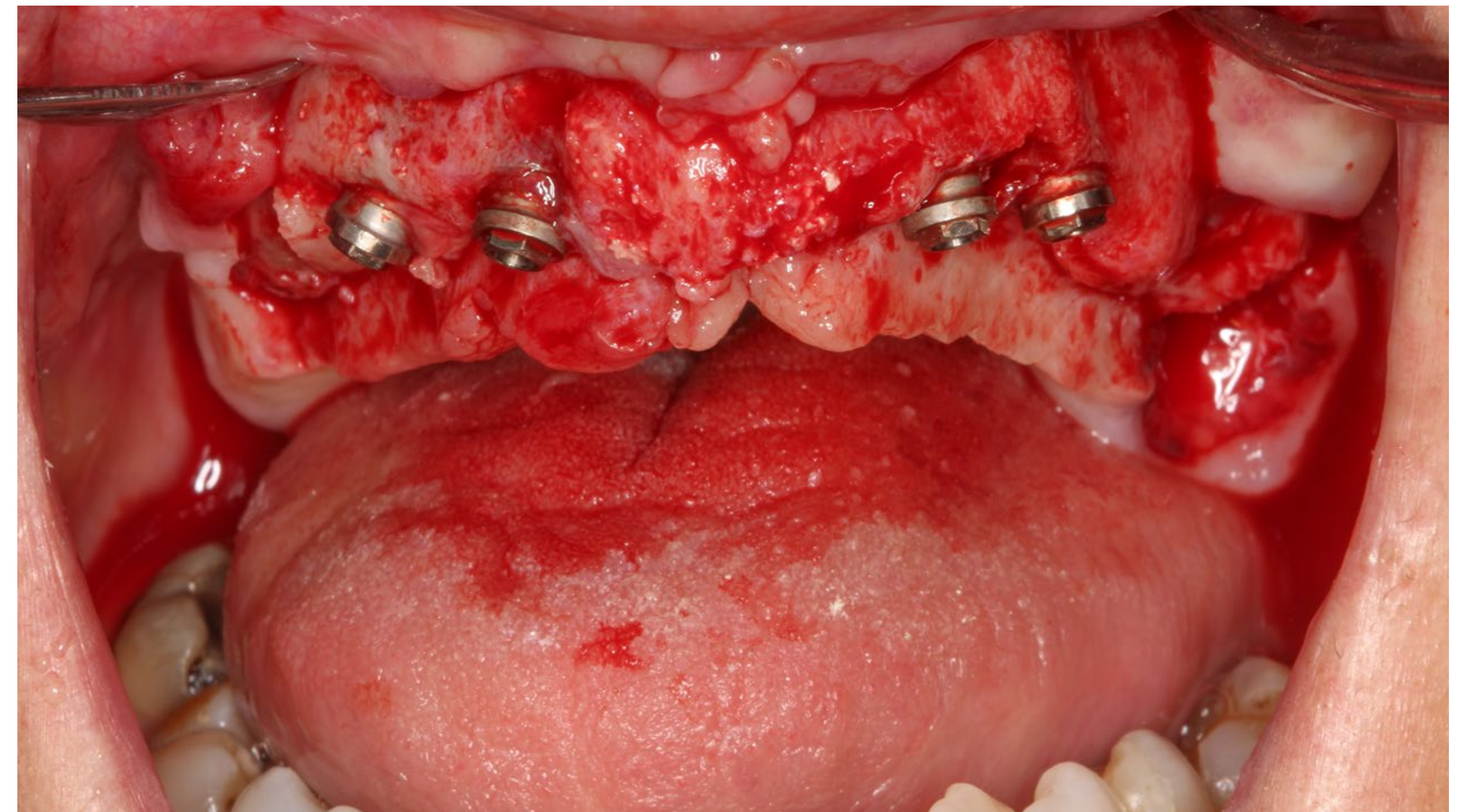
Treatment planning



Transparent guide for testing vertical dimension and occlusal relations



Transparent guide for testing vertical dimension and occlusal relations

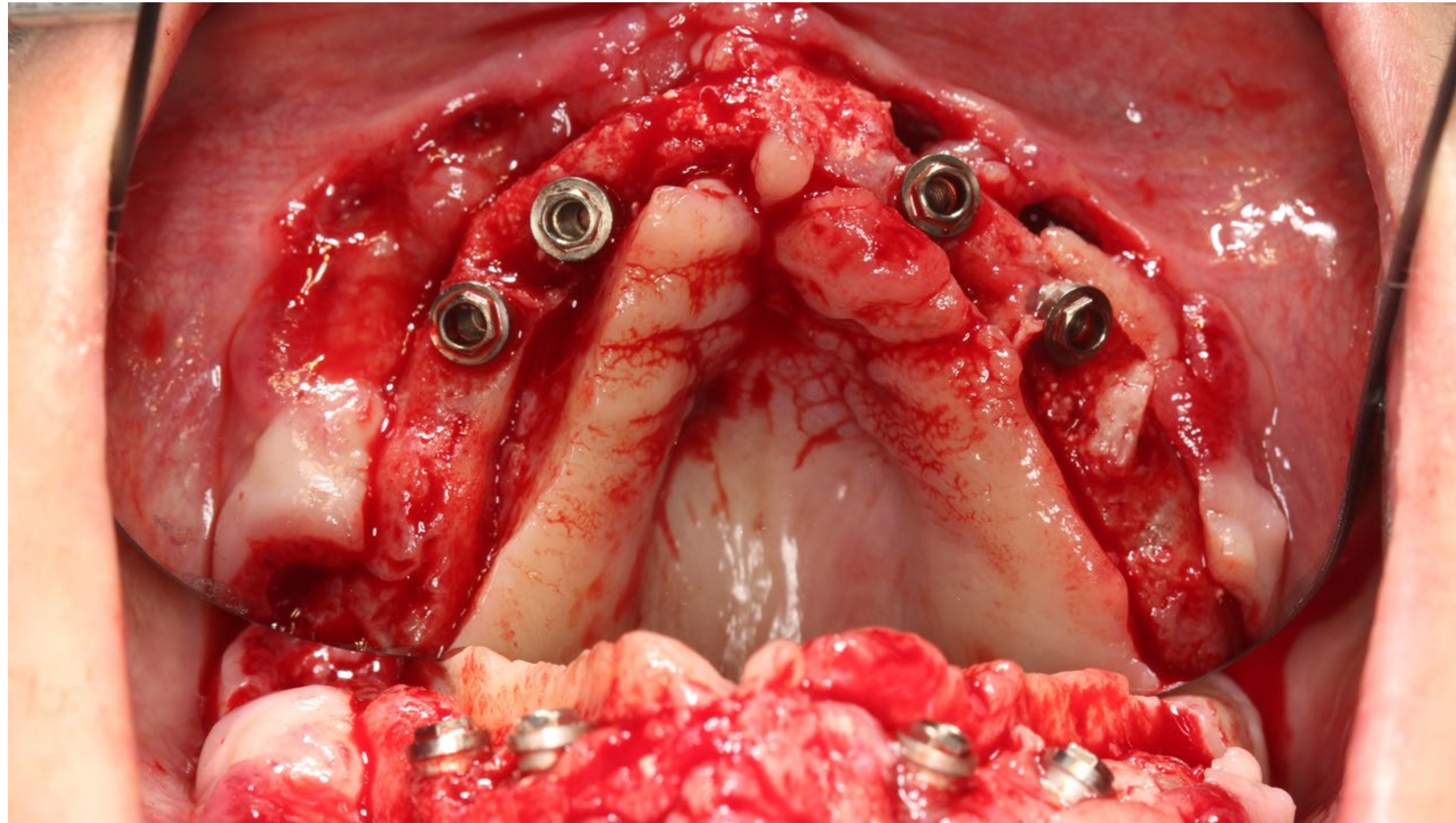


Gingival flap elevated



# Challenge 4: Rework of failed implants

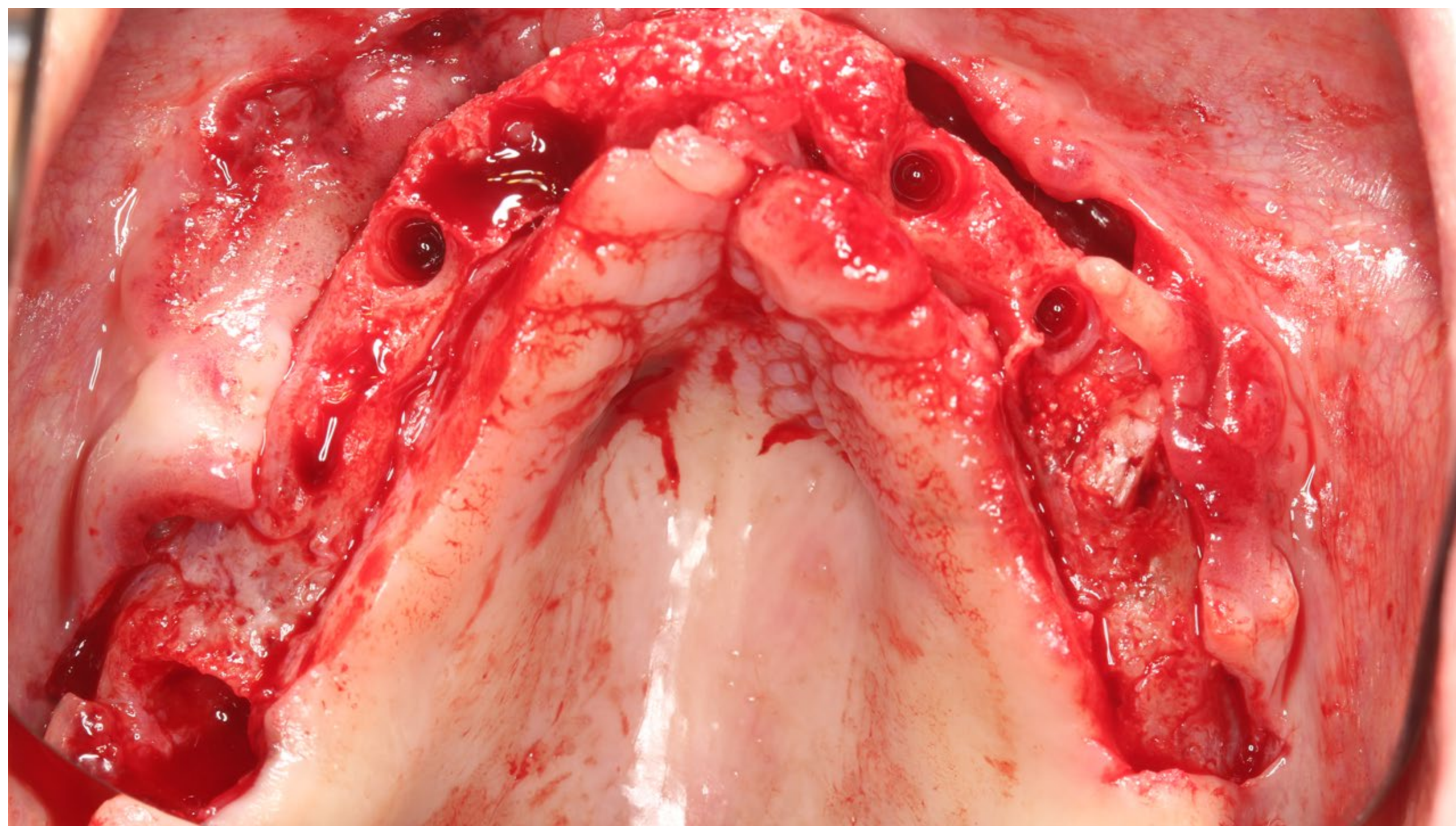
Clinical case



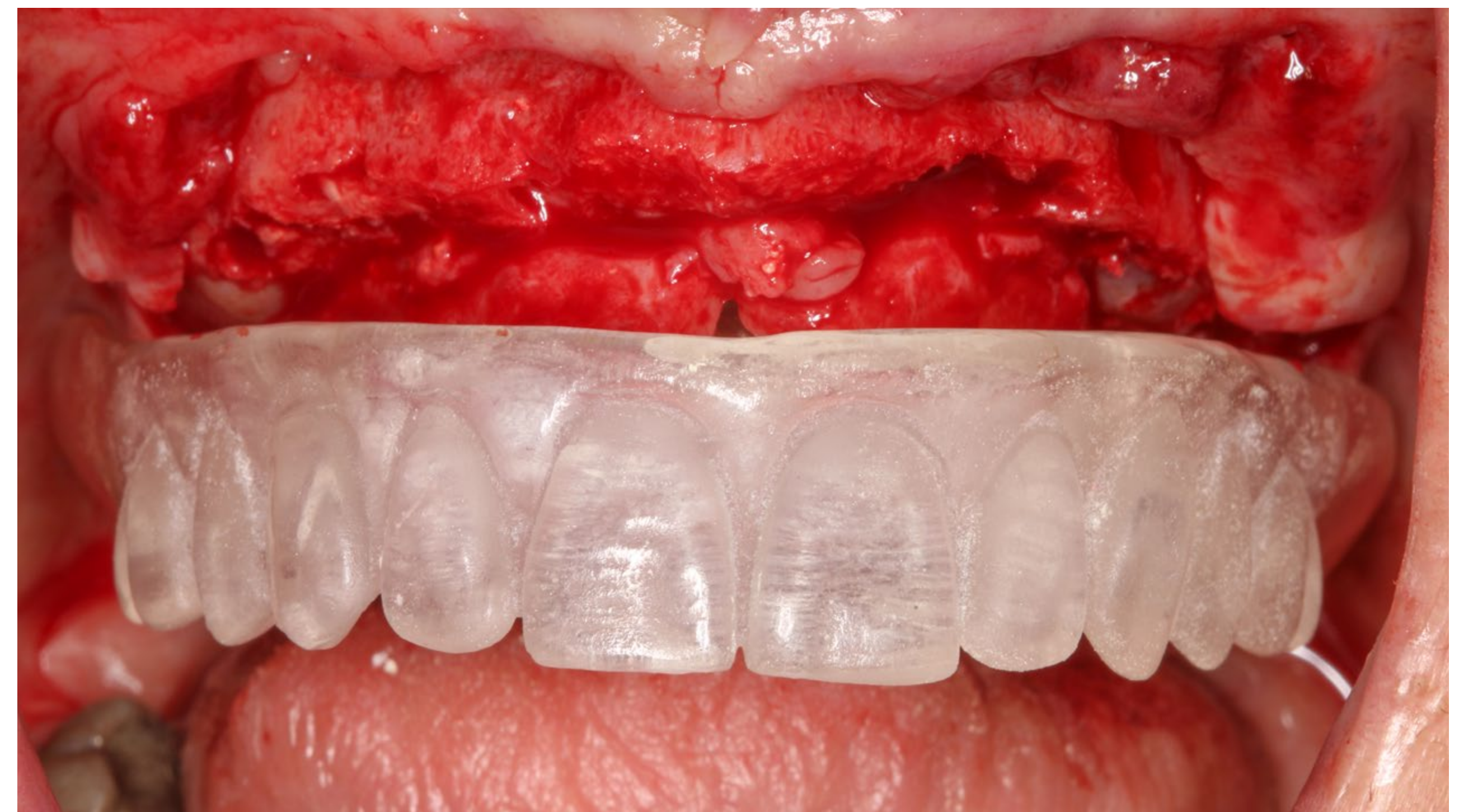Gingival flap elevated



Extracted failed implants



Occlusal view after the extraction of the failed implants

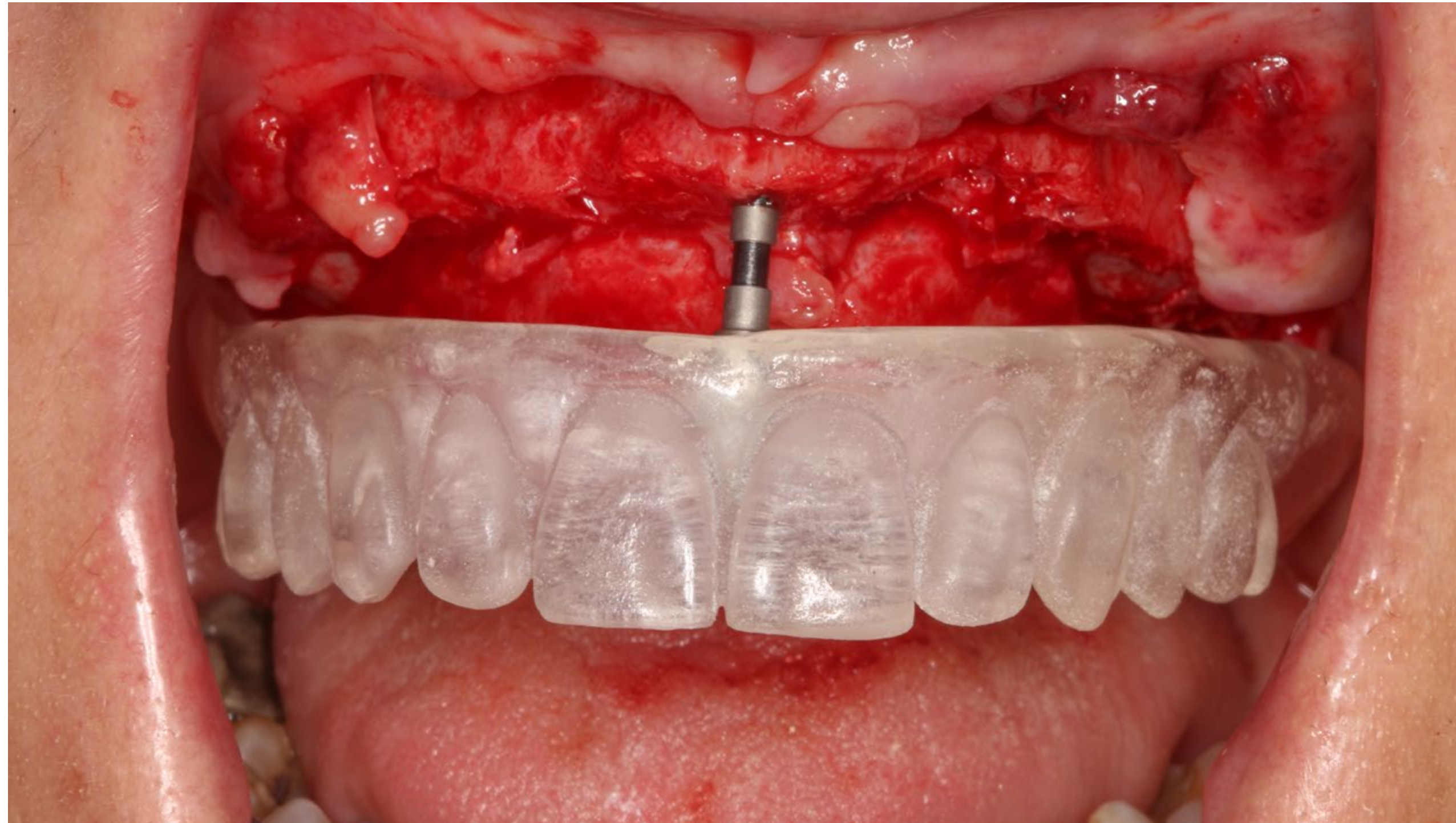


Transparent guide to measure the bone reduction

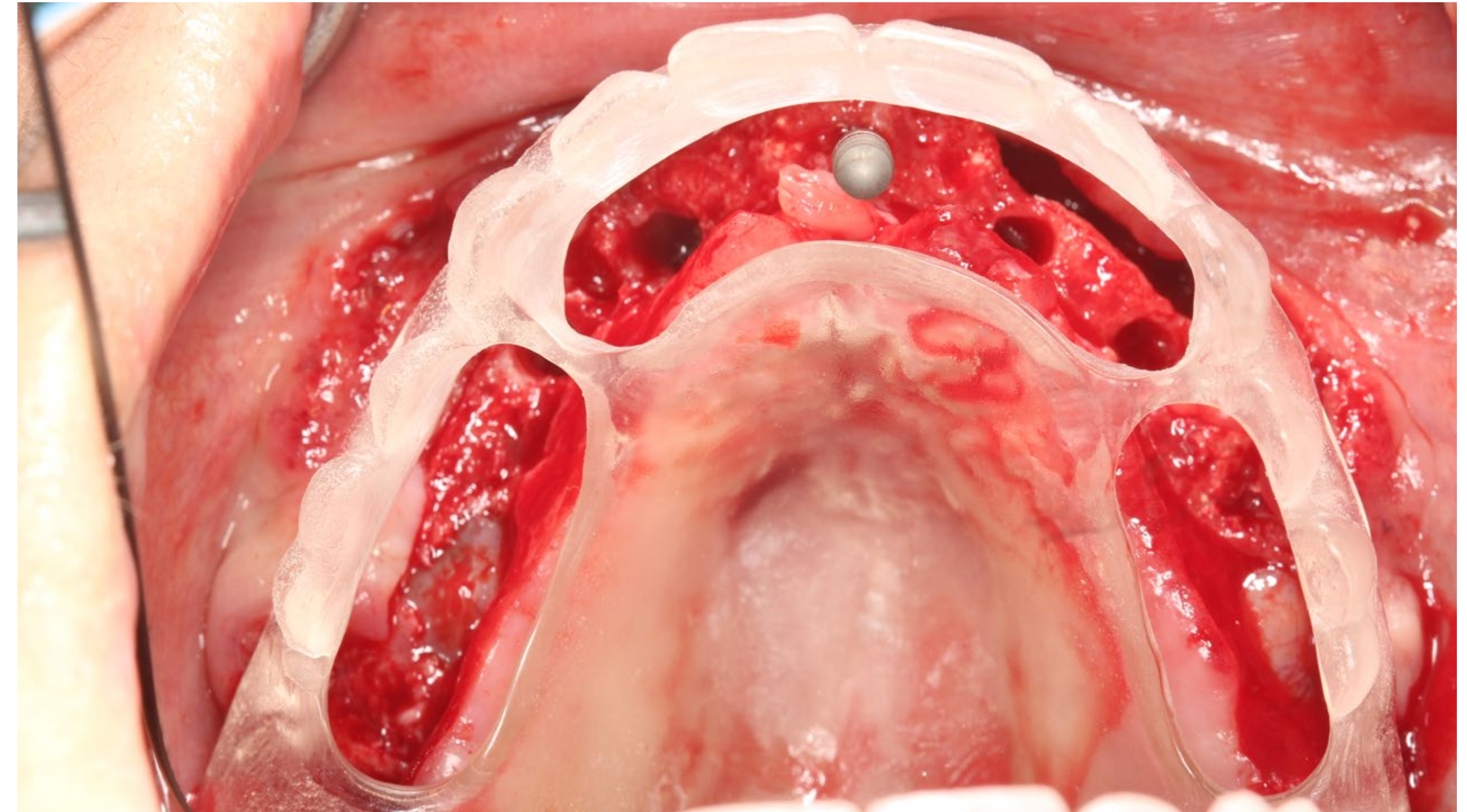


# Challenge 4: Rework of failed implants

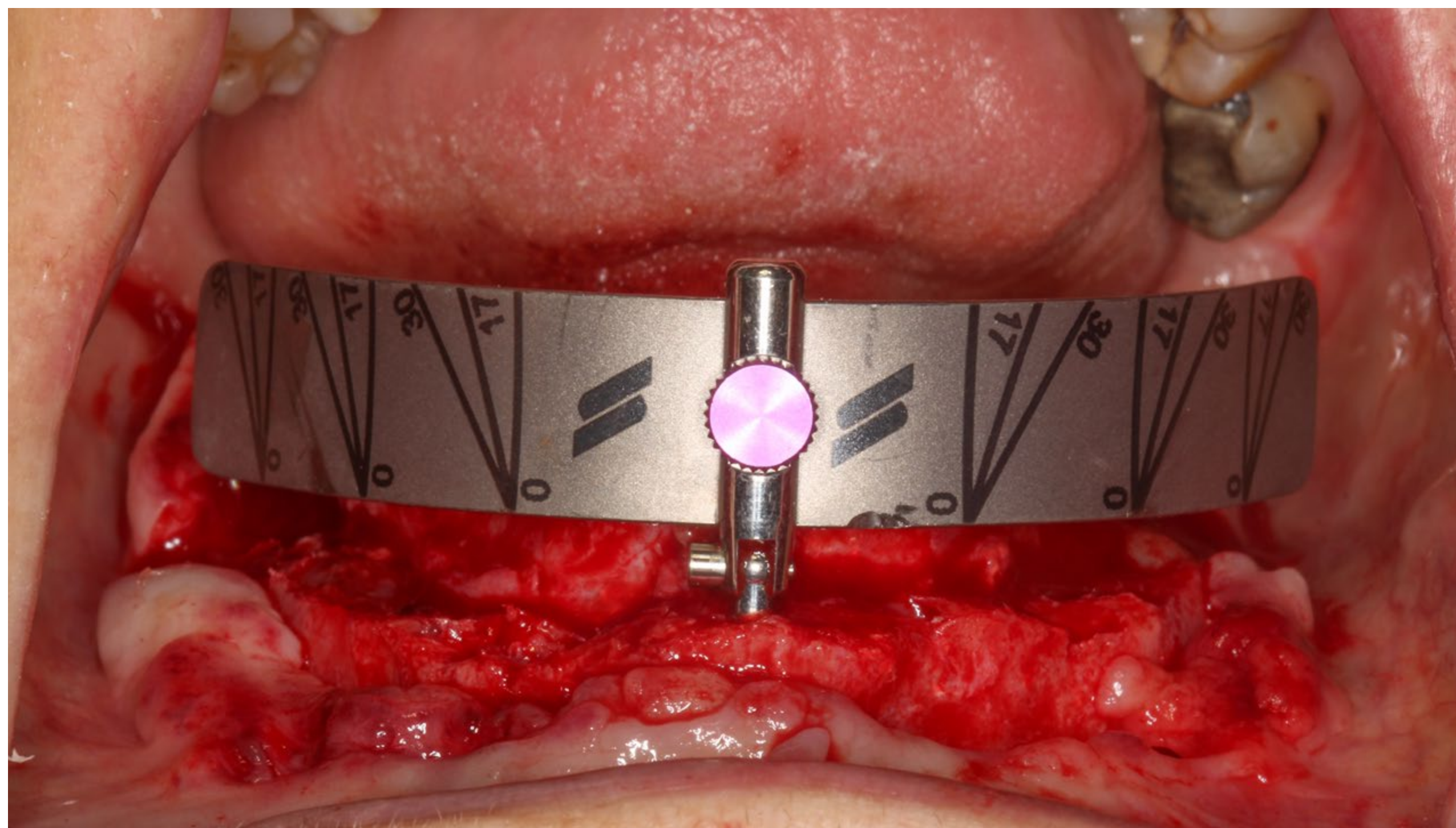
Clinical case



Transparent guide after the bone reduction



Transparent guide after the bone reduction



Straumann® Pro Arch Guide in place

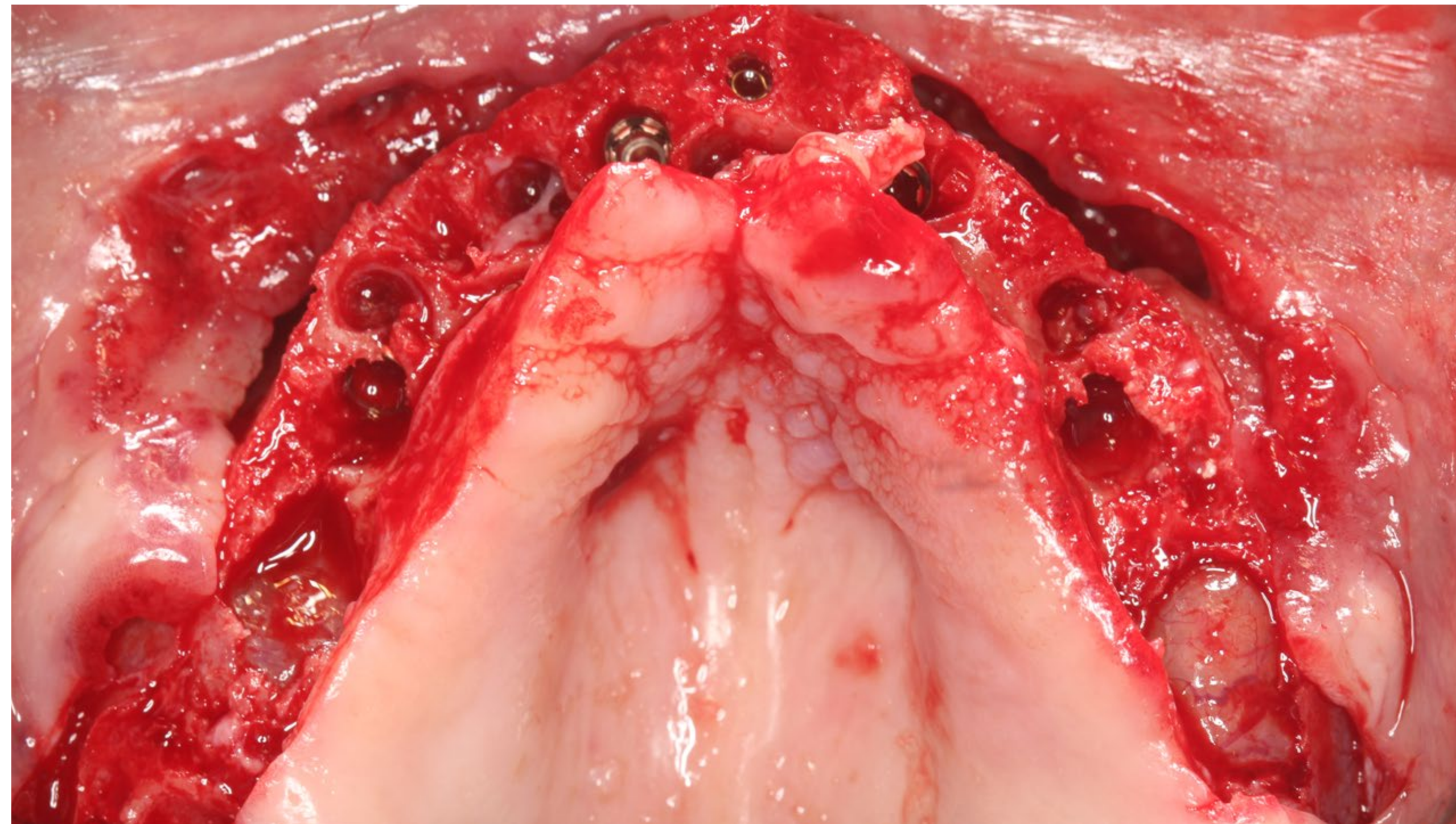


Four Straumann® BLX Ø 3.75 mm RB SLActive® 16 mm Roxolid® implants

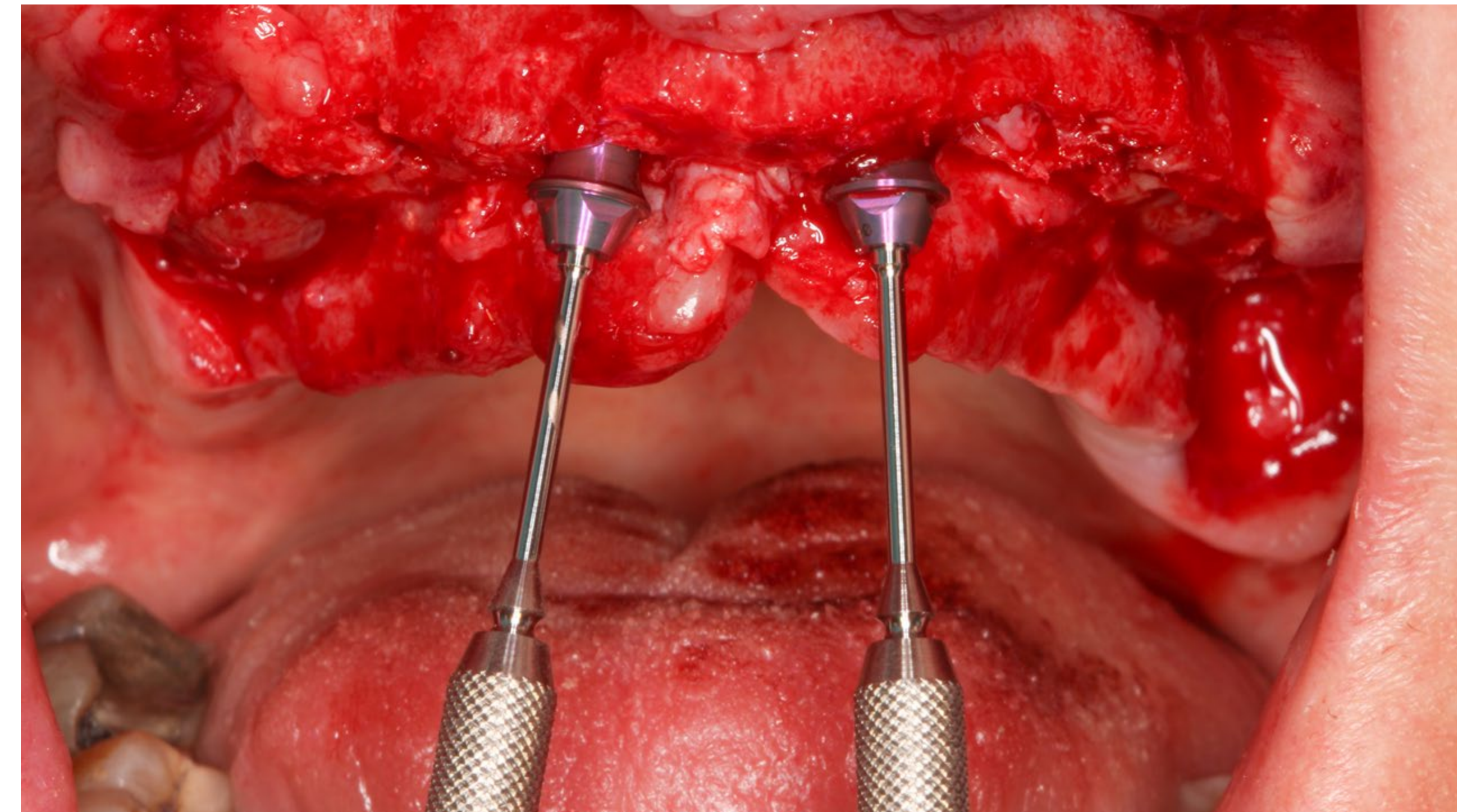


# Challenge 4: Rework of failed implants

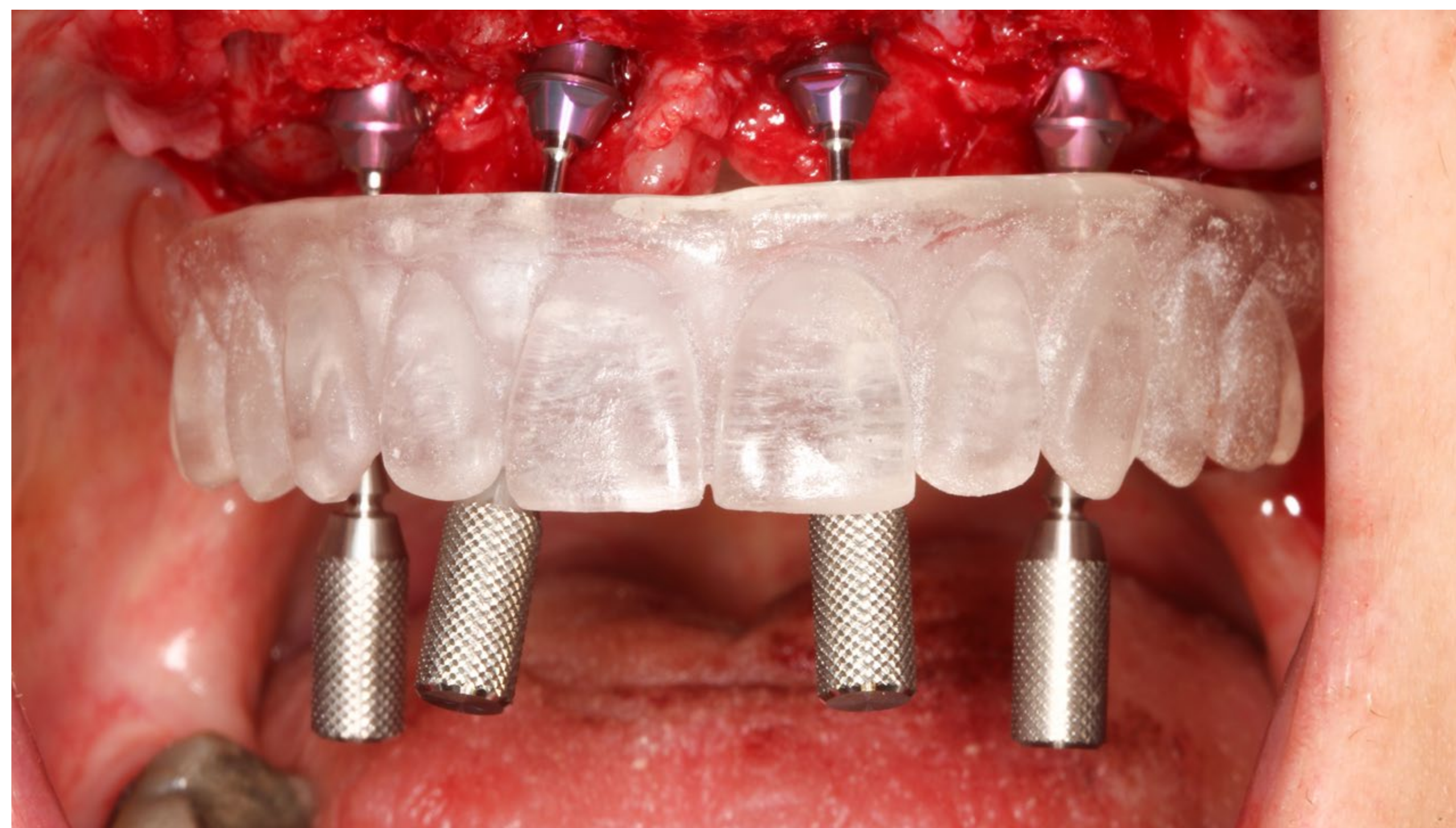
Clinical case



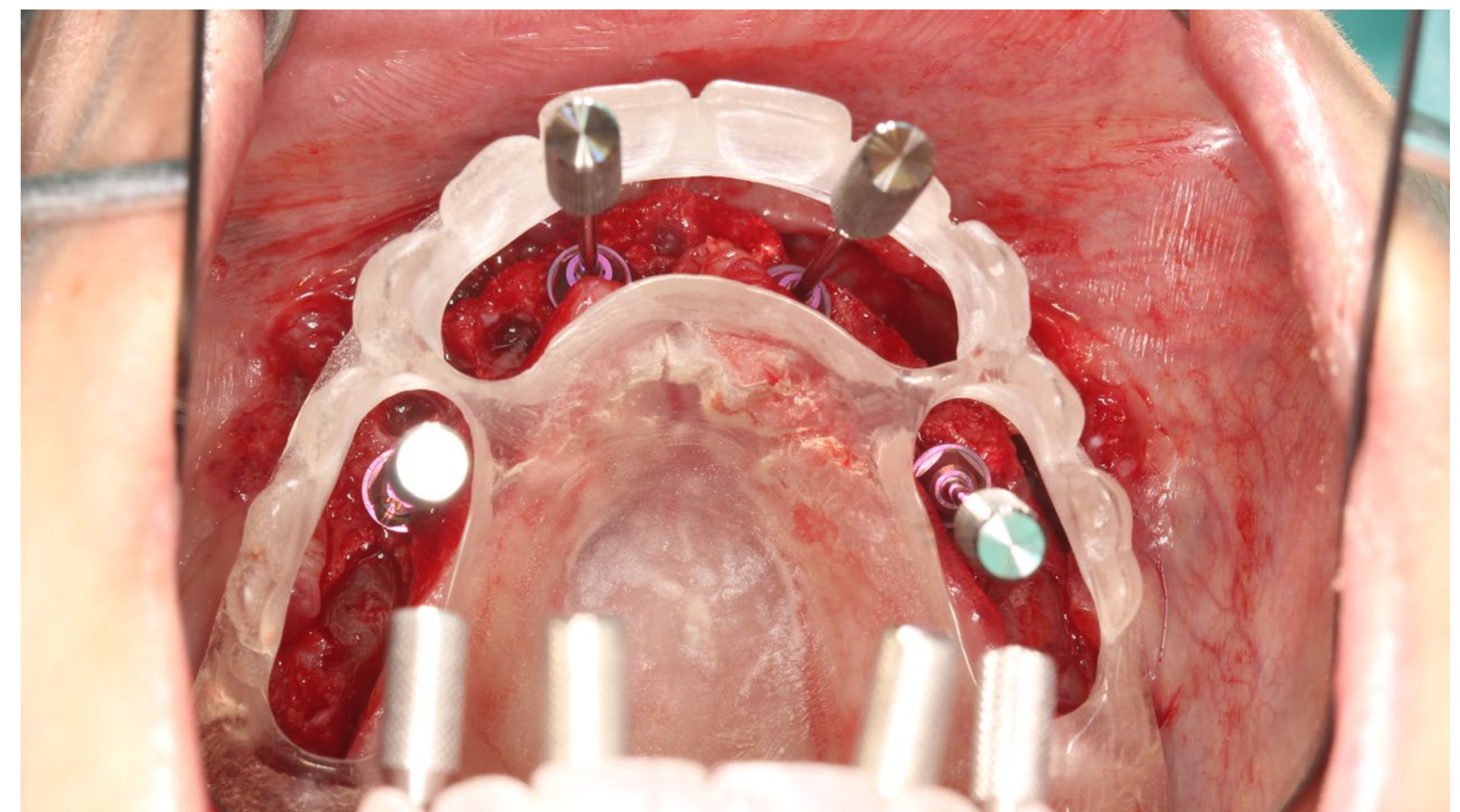
Four Straumann® BLX Ø 3.75 mm RB SLActive® Roxolid® implants in place



Placement of the anterior Screw-retained Abutments



Screw-retained Abutments in place  
Alignment with the transparent guide

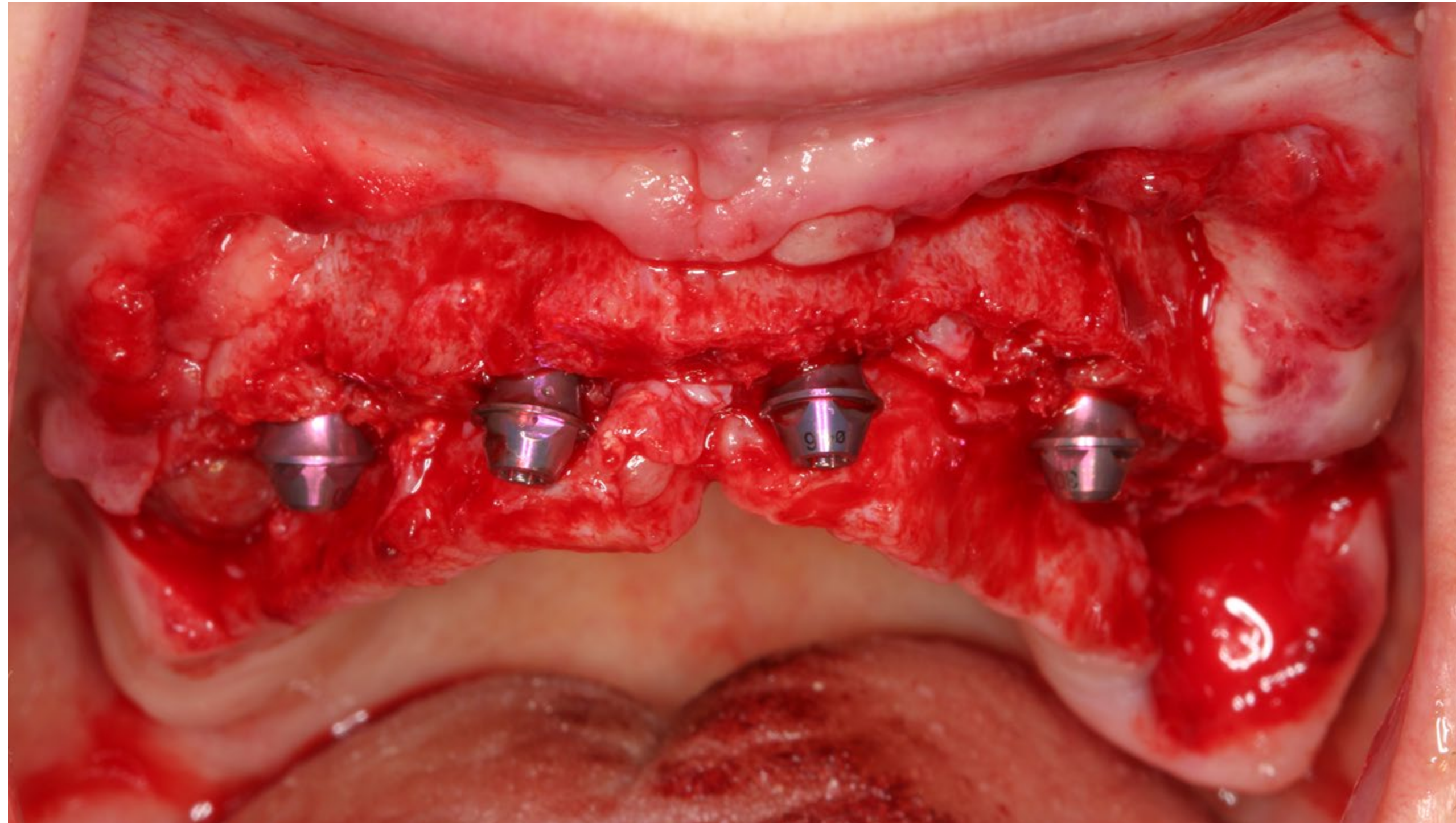


Screw-retained Abutments in place Alignment with the transparent guide

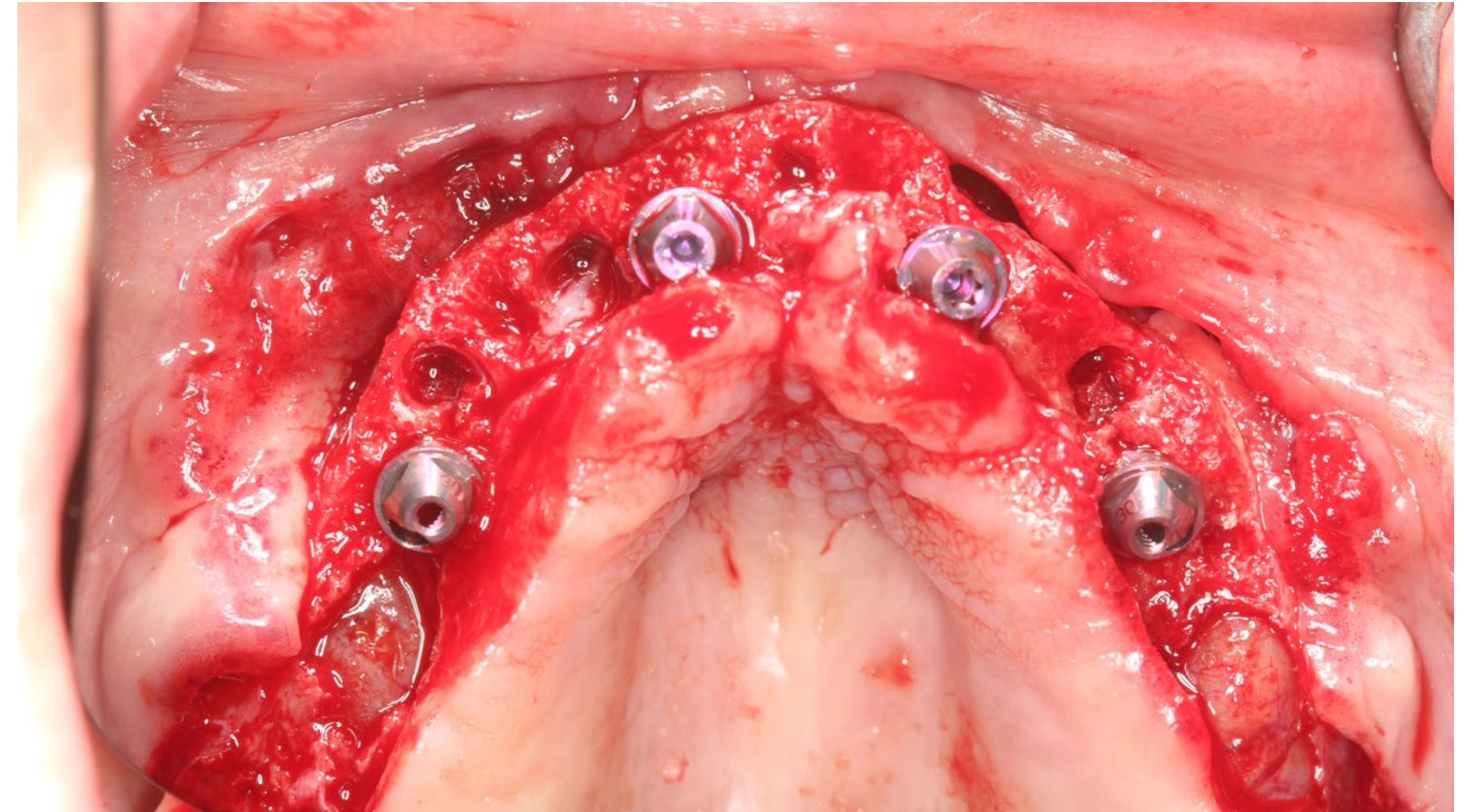


# Challenge 4: Rework of failed implants

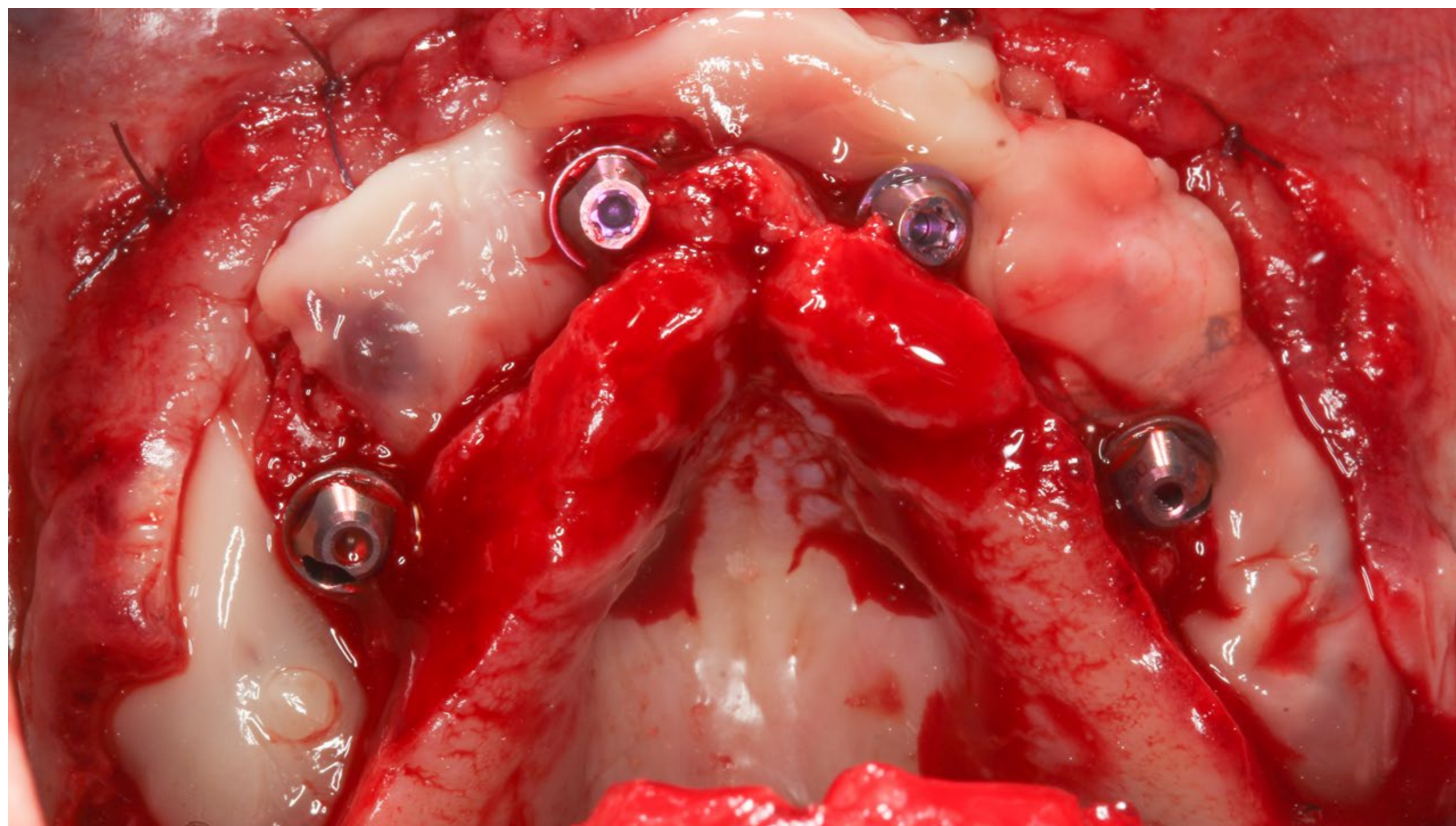
Clinical case



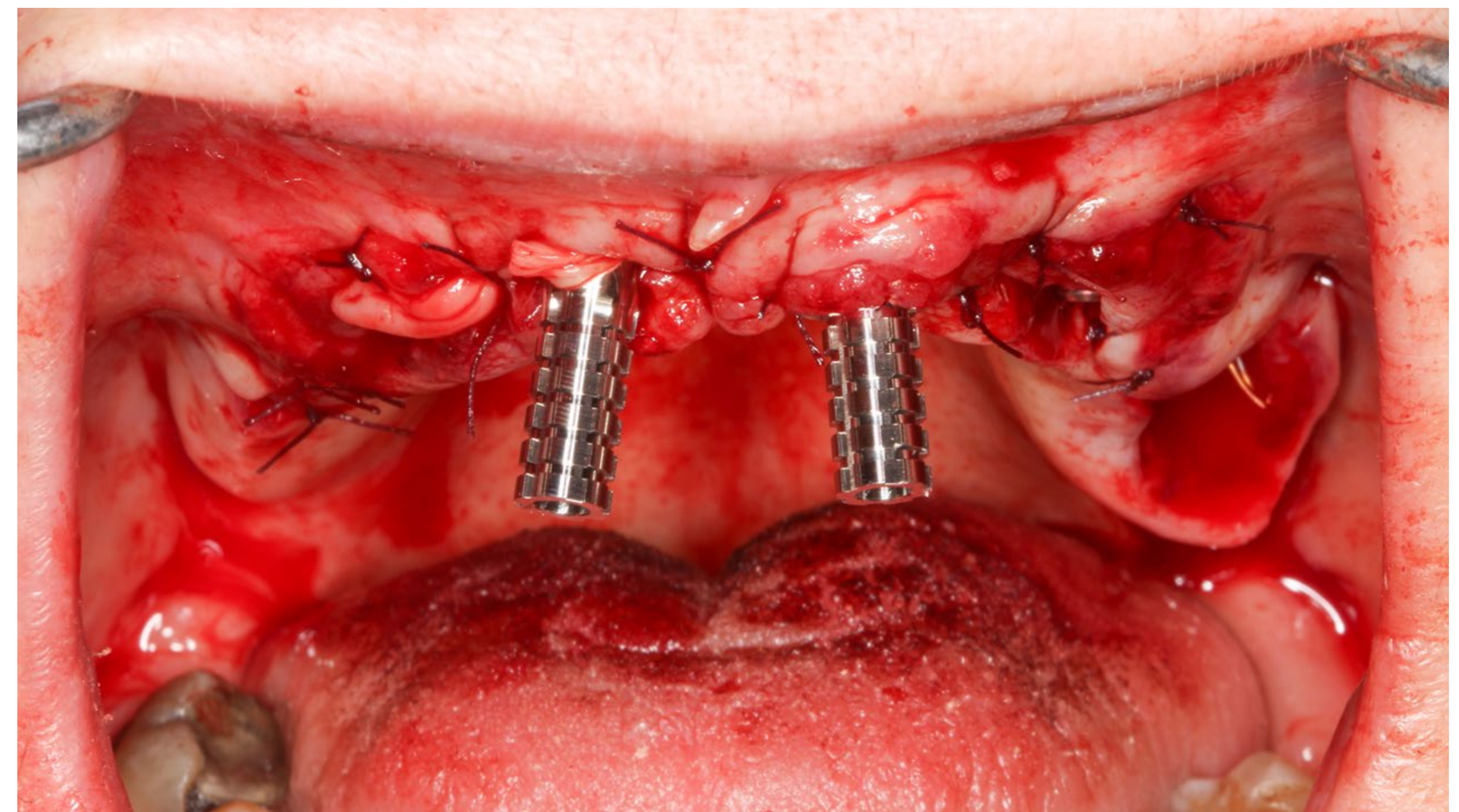
Screw-retained Abutments in place  
Frontal view



Screw-retained Abutments in place  
Occlusal view



Platelet-rich fibrin (PRF) placement

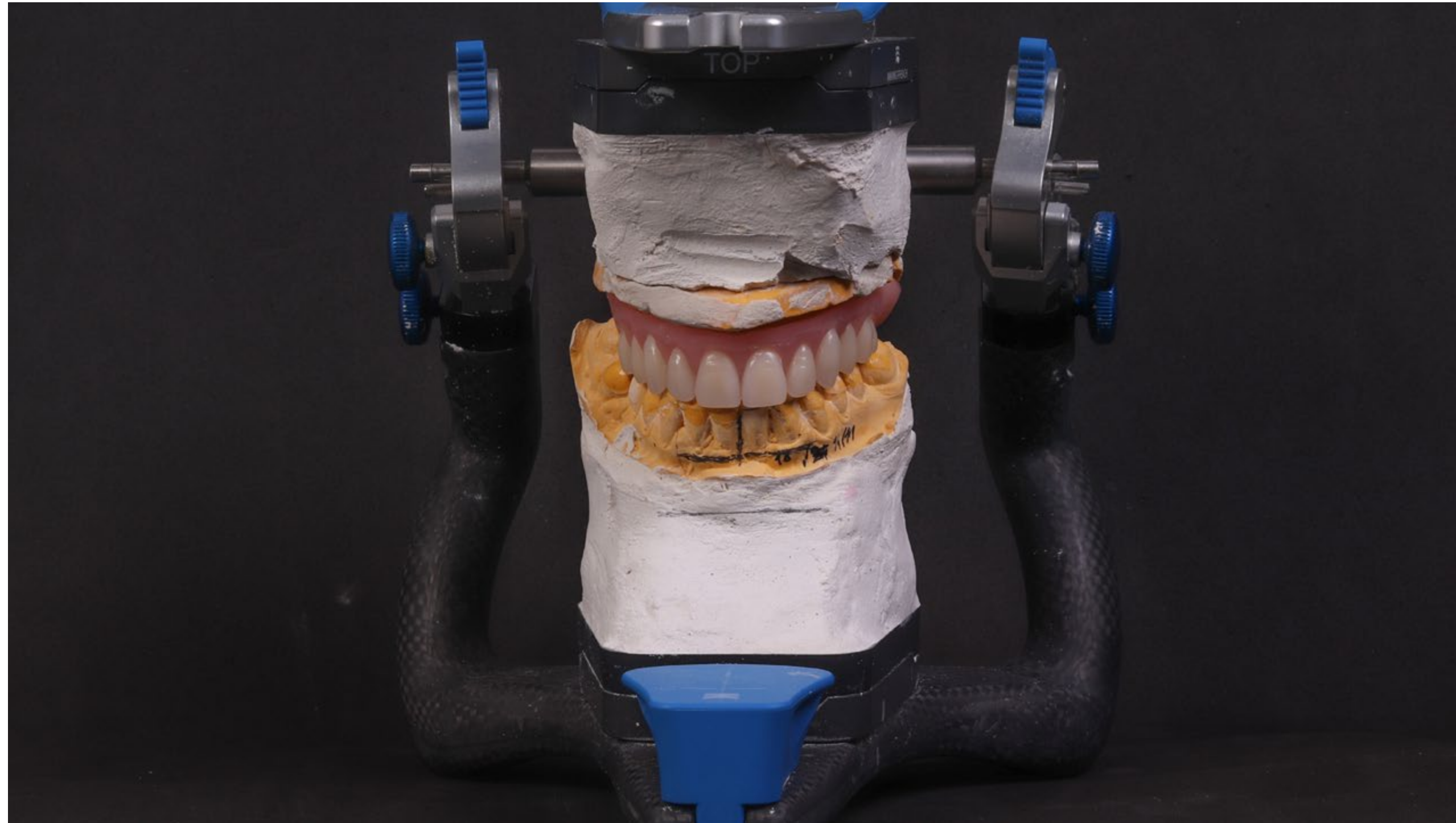


Placement of non-engaging Titanium Copings on the anterior and posterior abutments.

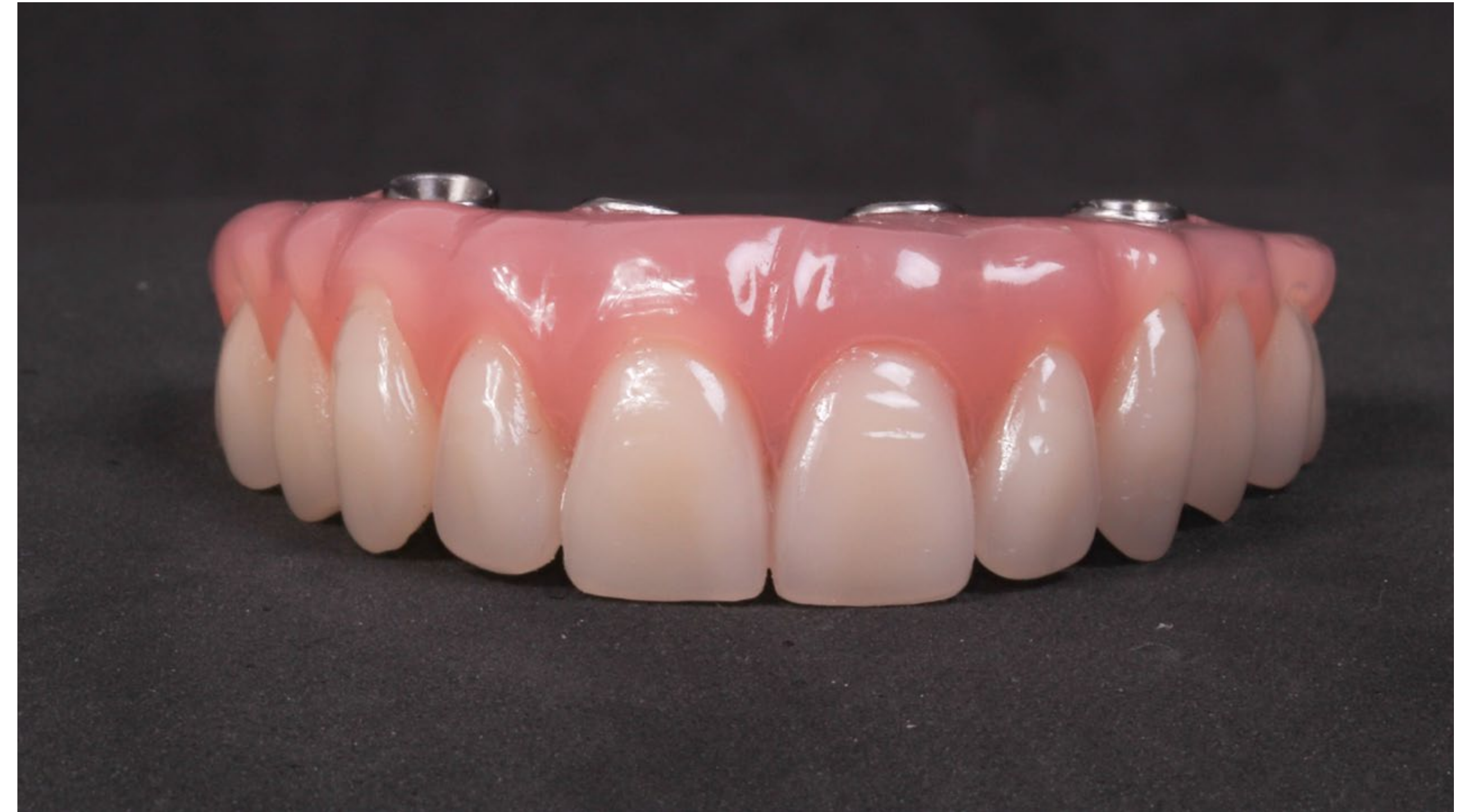

# Challenge 4: Rework of failed implants

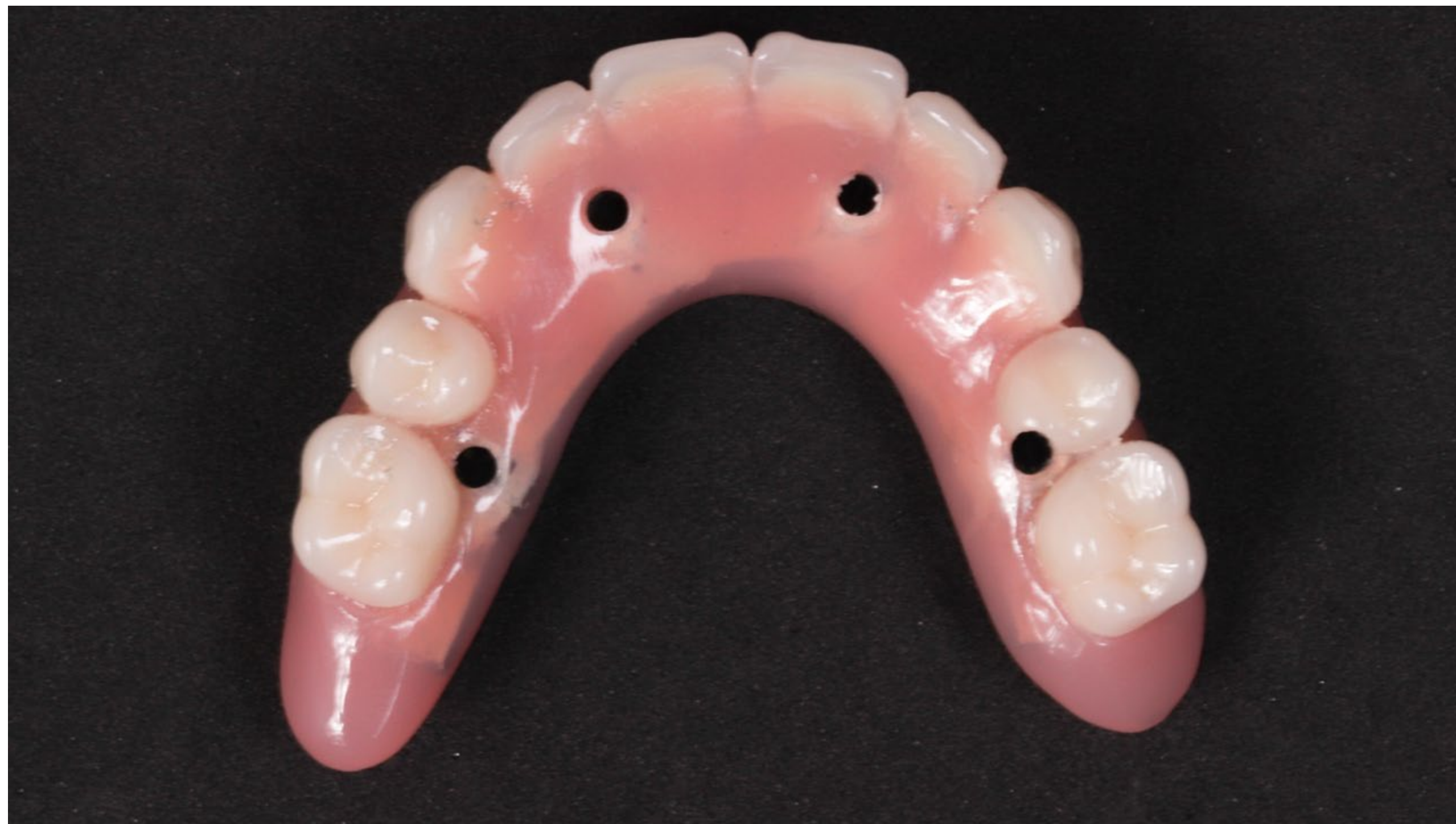Clinical case



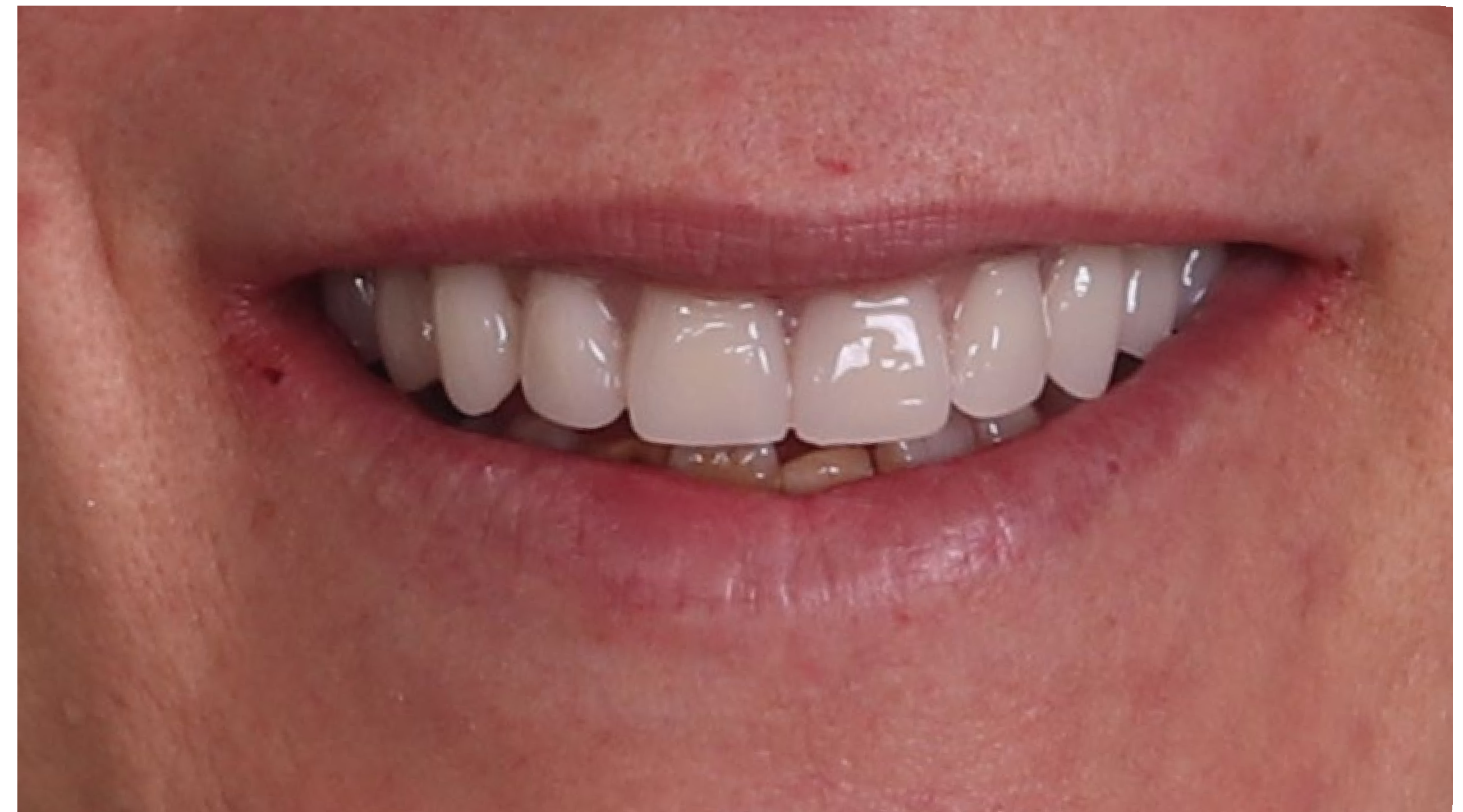Provisional prosthesis on the articulator



Finished provisional prosthesis



Finished provisional prosthesis

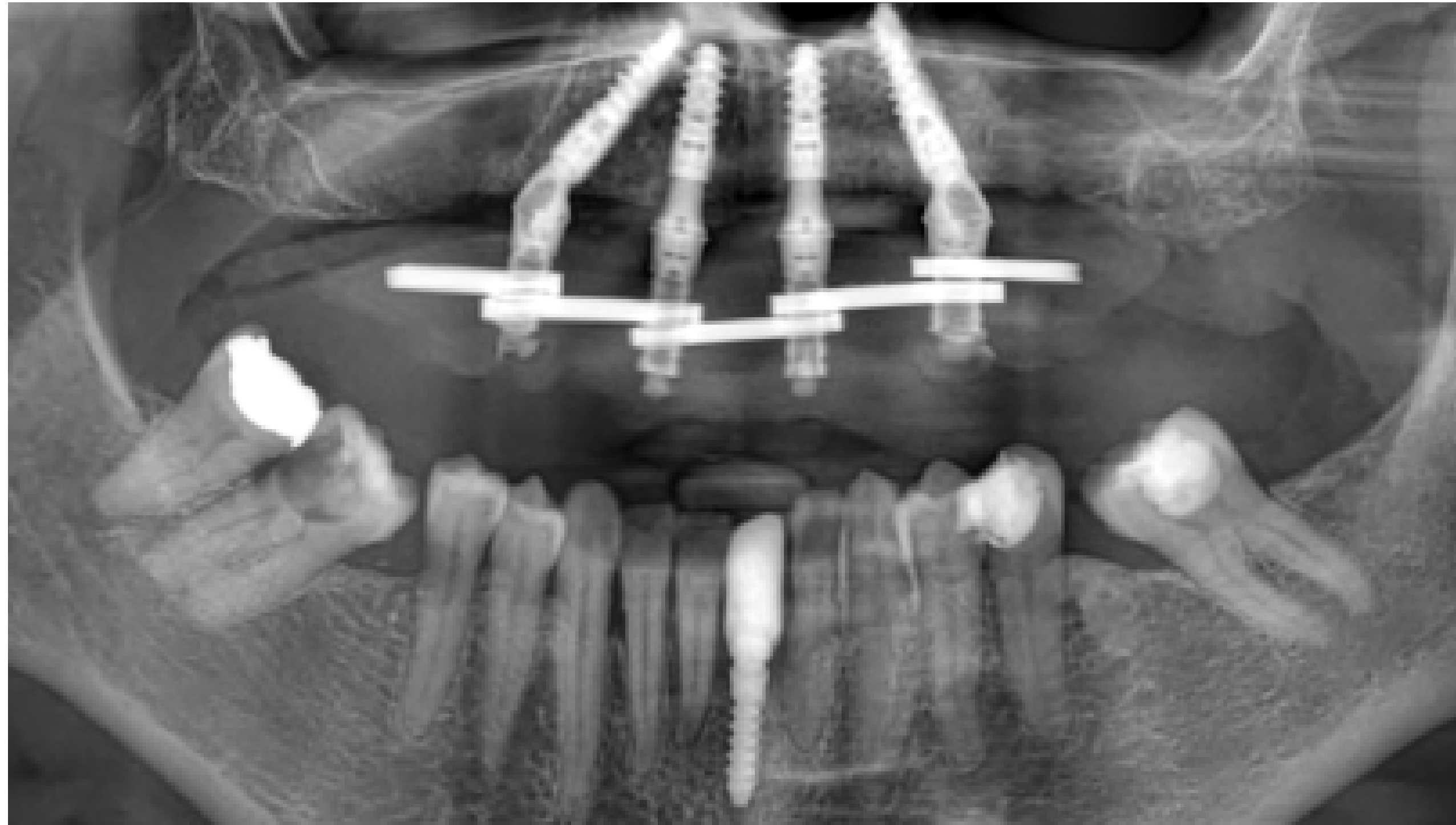

Provisional prosthesis in place  
Final prosthesis will be placed six months later

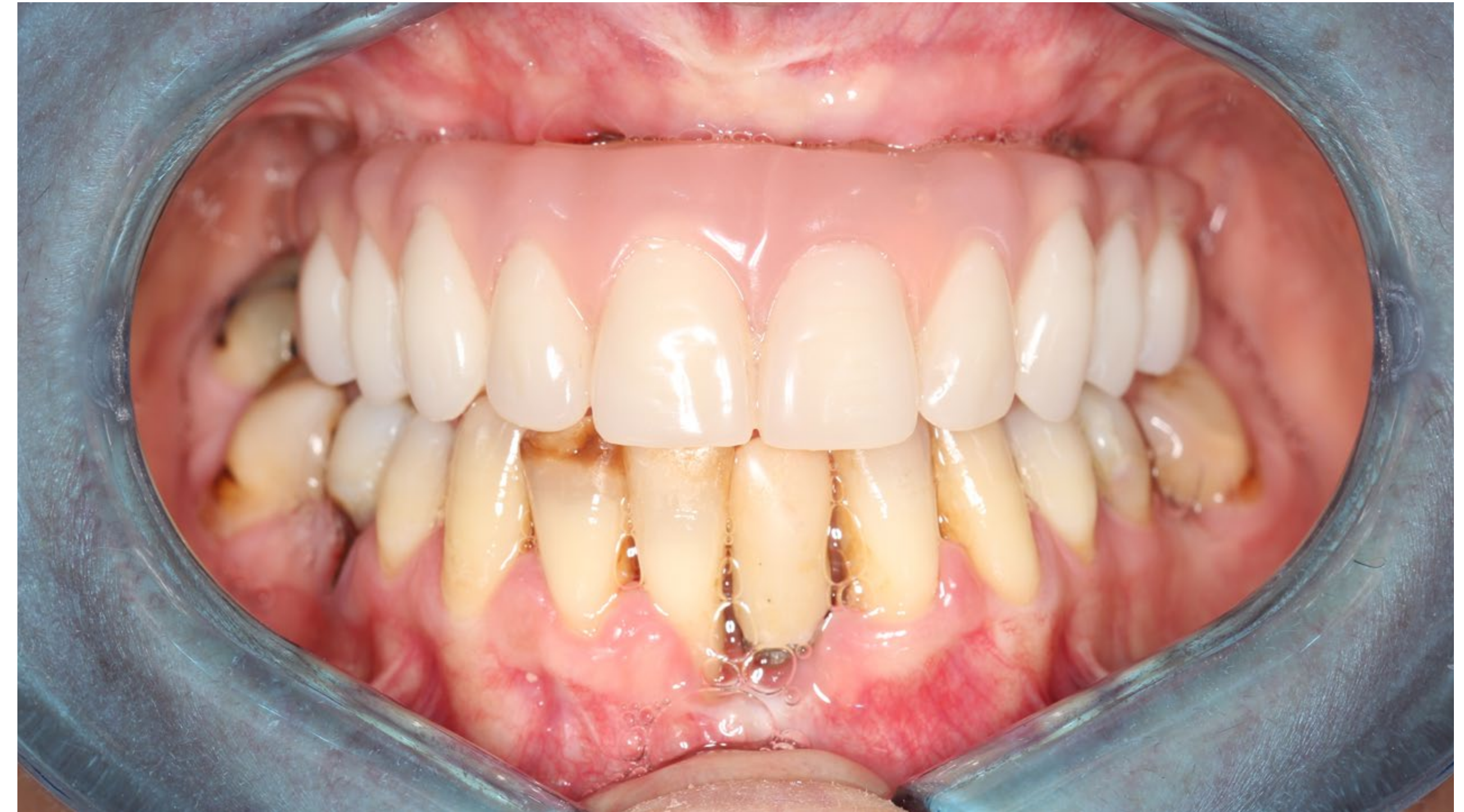

# Challenge 4: Rework of failed implants

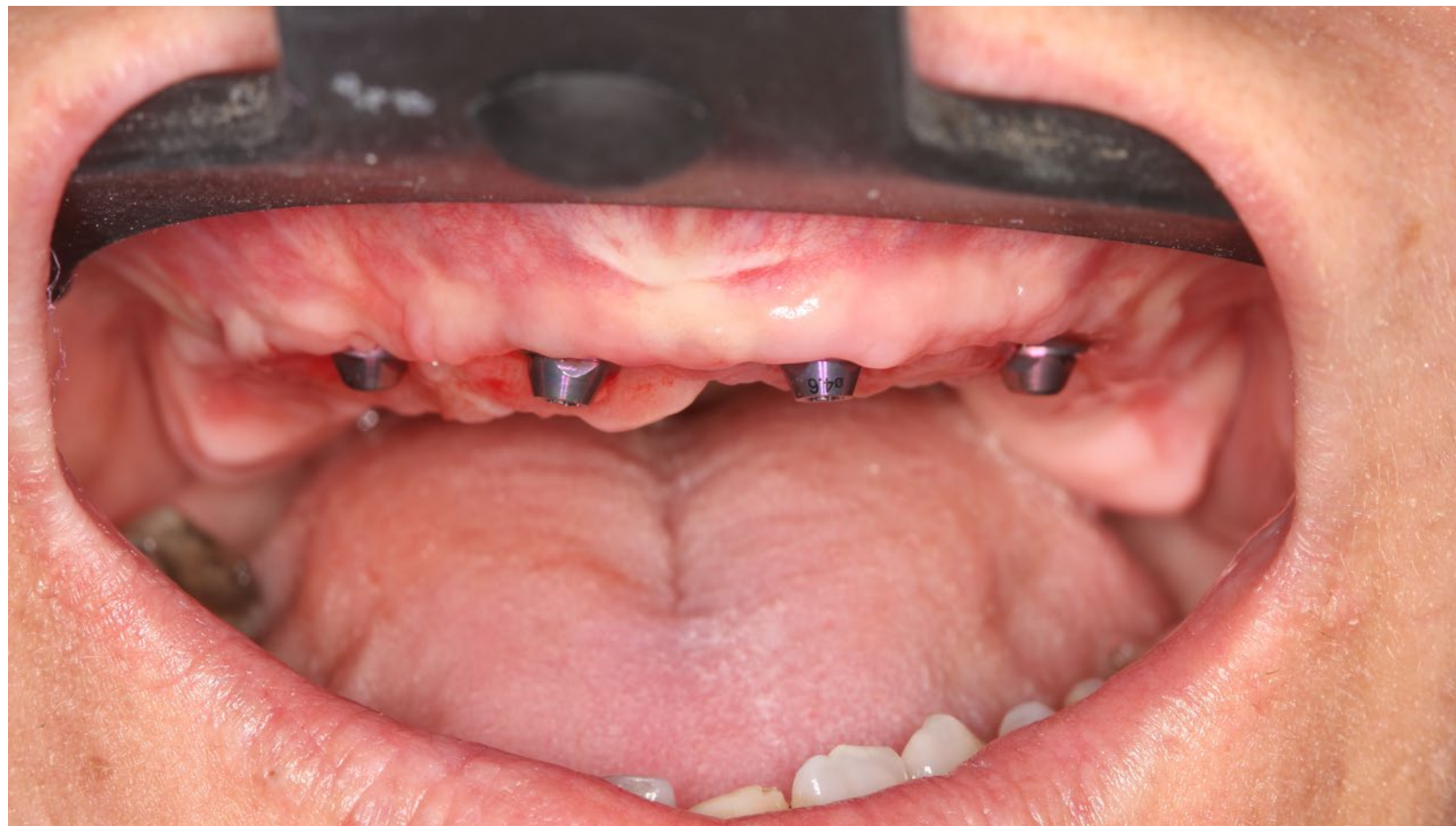Clinical case



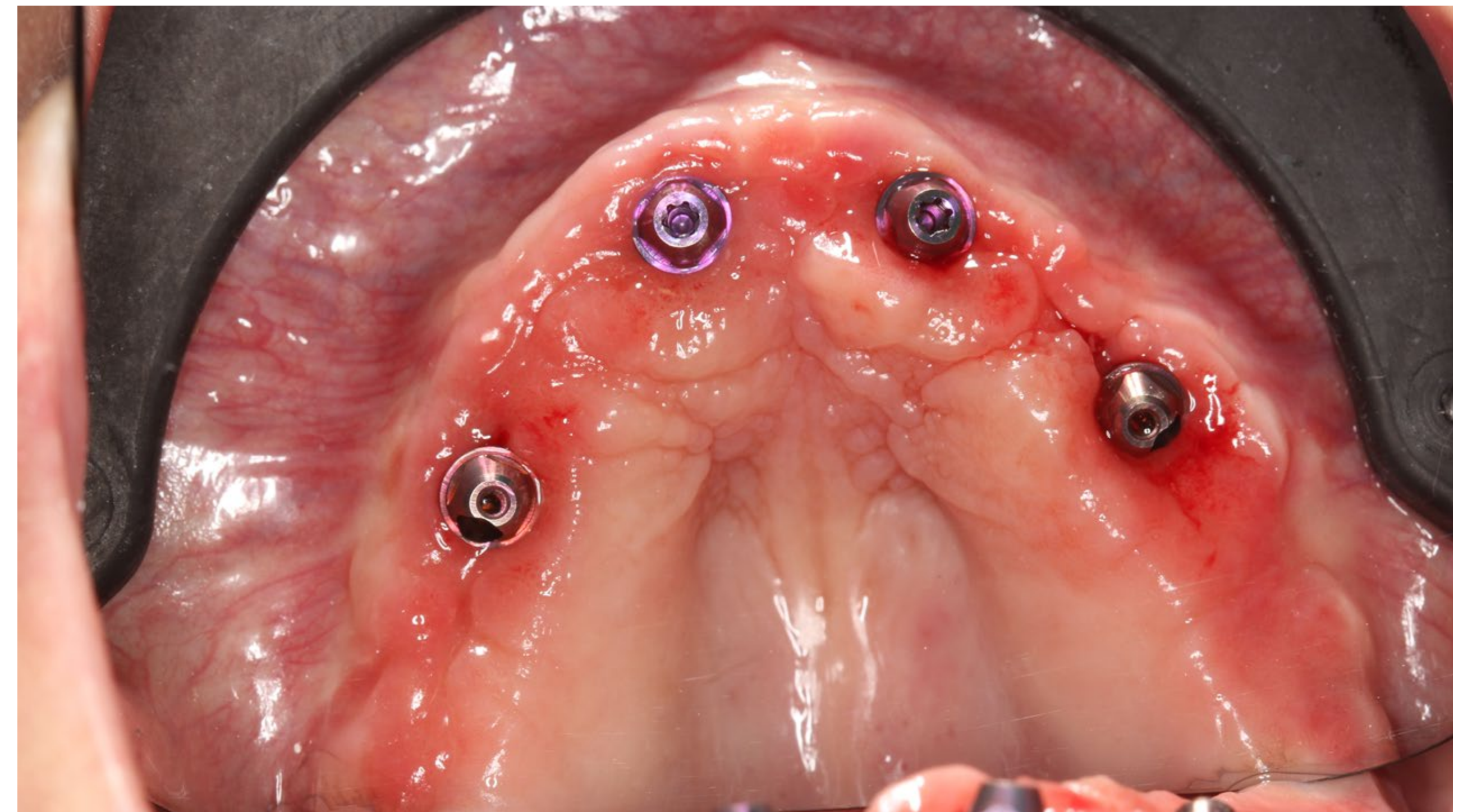
Postoperative radiograph



One month after the surgery



One month after the surgery

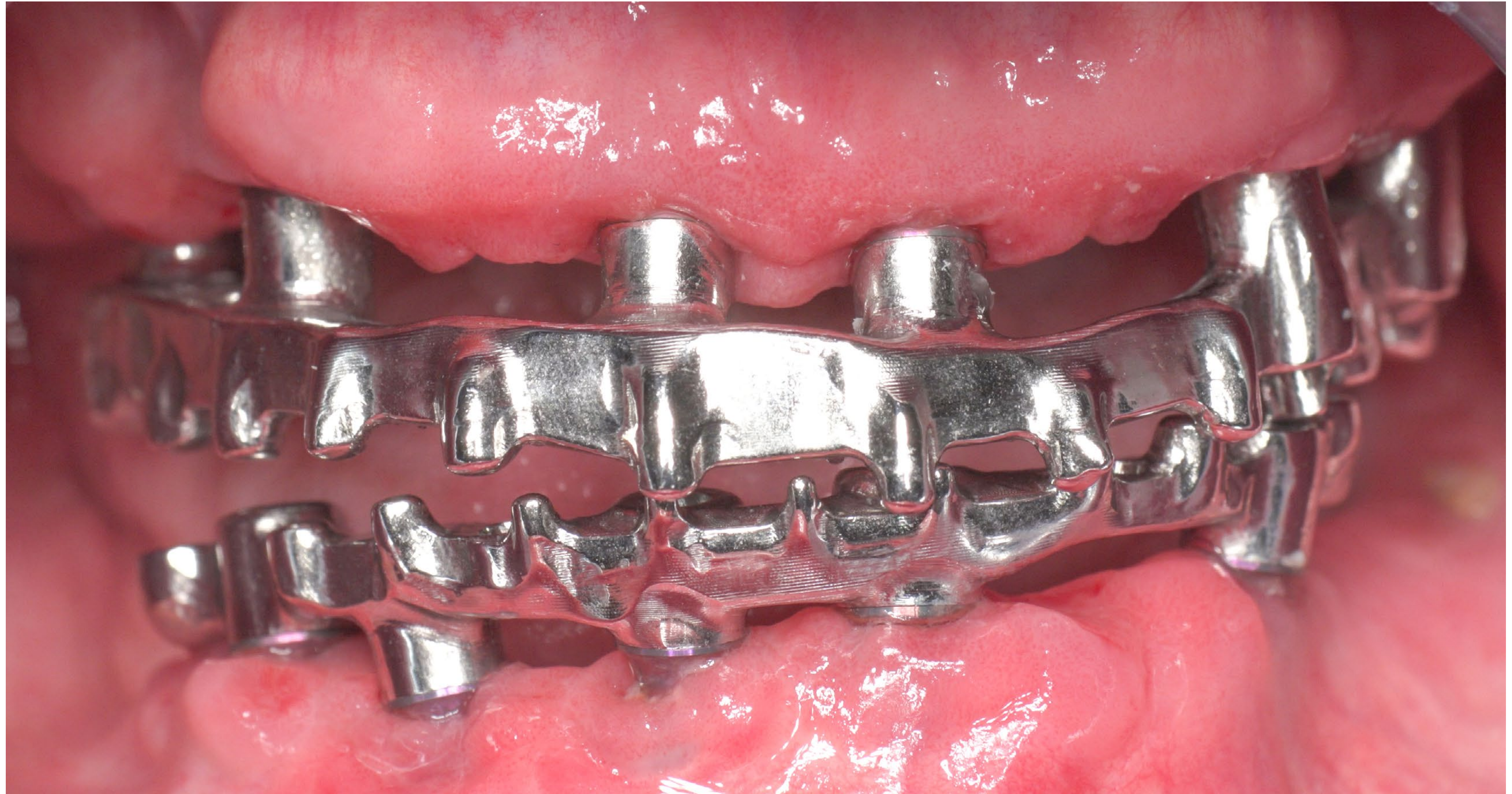

One month after the surgery



# Challenge 5: Cross-bite occlusion

General recommendations and clinical case from Dr. Luis Cuadrado





# Challenge 5: Cross-bite occlusion

## General recommendations



### General recommendations from Dr. Luis Cuadrado

- Correction of the right occlusal scheme
- Correction of the curve of Spee
- Correction of the buccal corridor

Plastic, reconstructive and esthetic surgeon. Director of Clinical Training Center i2 Implantología. Director of Postgraduate Training Program in Implantology UDIMA, University of Madrid. Member of AO, EAO, SEI, SECIB, SECPRE, ITI. Over 200 national and international courses and conferences. More than 100 scientific articles. Practice in oral implantology, extraoral and reconstructive surgery. Member of the 3Shape World Advisory Board.



**Dr. Luis Cuadrado**  
MD, DMD, Private practice,  
Madrid, Spain

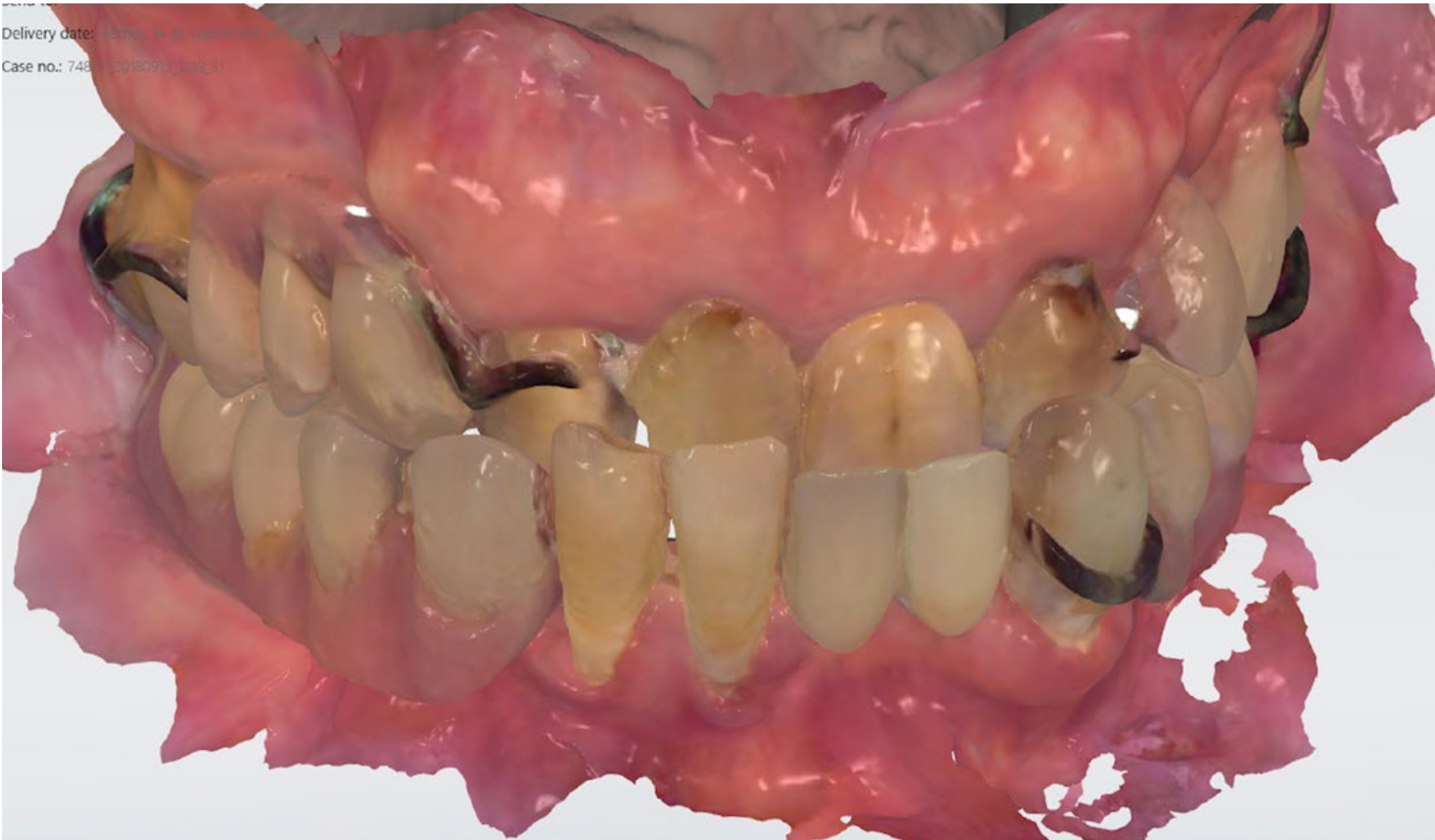

# Challenge 5: Cross-bite occlusion

Clinical case



## Initial situation



## Patient information

Age	84
Jaw	Maxilla/mandible
Health status	Good
Height of smile line	High
Bone type	Soft
Infections at implantation site	No
Bone anatomy defects	No defects
Risks	Yes

## Additional difficulties

Bone quality D2/D3
Limited bone availability in the posterior mandible
Moderate resorption in the maxilla
Type 2 diabetes
84 years old

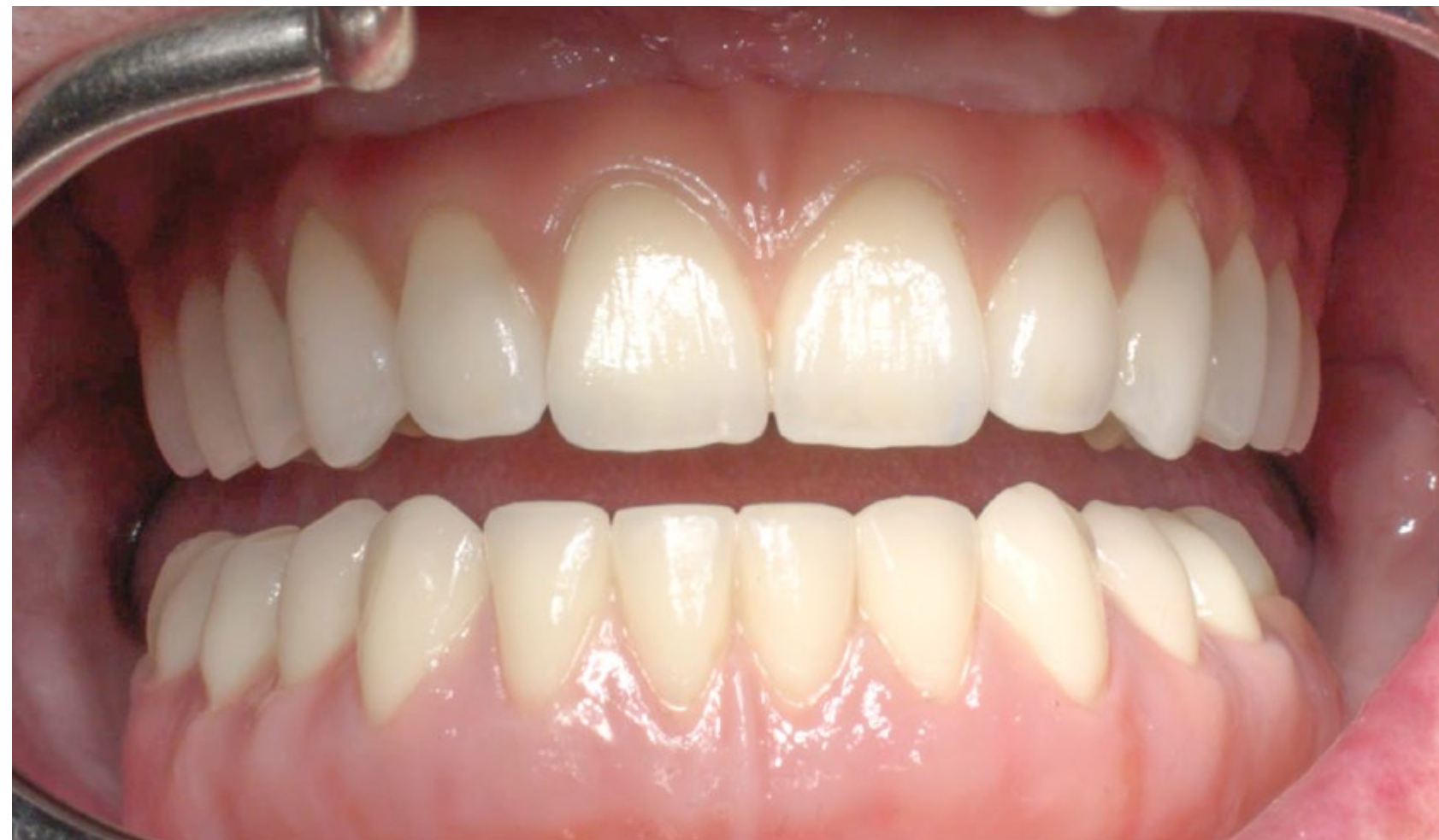

# Challenge 5: Cross-bite occlusion

Clinical case



## Provisional prosthesis



## Treatment

- **Step 1:** Fixed immediate rehabilitation on five BLX implants in the lower jaw
- **Step 2:** Two months later: Fixed immediate rehabilitation on six BLX implants in the upper jaw. Tilting of the posterior implants because of low bone availability in the posterior region
- Straumann® Pro Arch fully digital workflow

**Temporary prosthesis:** PMAA bridge

**Final prosthesis:** two fixed hybrid prostheses on Createch milled CrCo frameworks

## Materials used



Straumann® BLX Ø 4.5 mm,  
Ø 3.75 mm RB SLActive®  
12 mm, 14 mm, Roxolid®



Screw-retained abutments,  
straight, GH 2.5 mm  
Screw-retained abutments,  
30° angled, GH 4.5 mm



# Challenge 5: Cross-bite occlusion

Clinical case



## Our experience



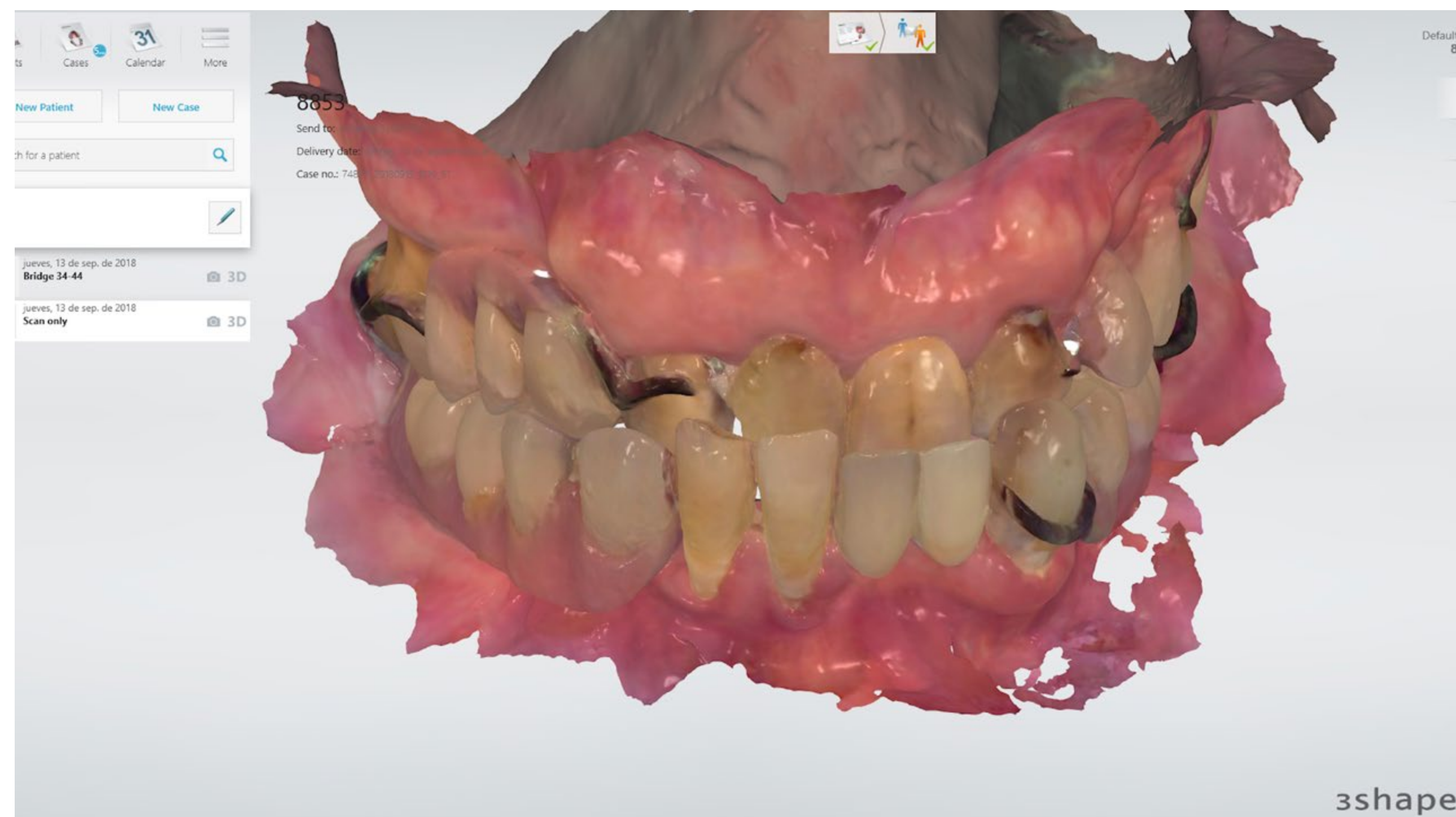Dr. Luis Cuadrado  
MD, DMD, Private practice

*“Immediacy is driven by tools and protocols. In this case, based on the patient’s medical and dental data I decided to use BLX implants and take advantage of its immediate loading capability and the combination of Roxolid® and SLActive® surface. The implant system fits the fully digital workflow, if we are dealing with same day restorations on both the implant and abutment levels. Trios3 gives us the accuracy needed in this kind of treatment, supported by the Straumann® CARES® digital environment and Createch precision of the milled framework. Last but not least, Emdogain® helps us improve the healing site and remain confident when treating compromised patients.”*

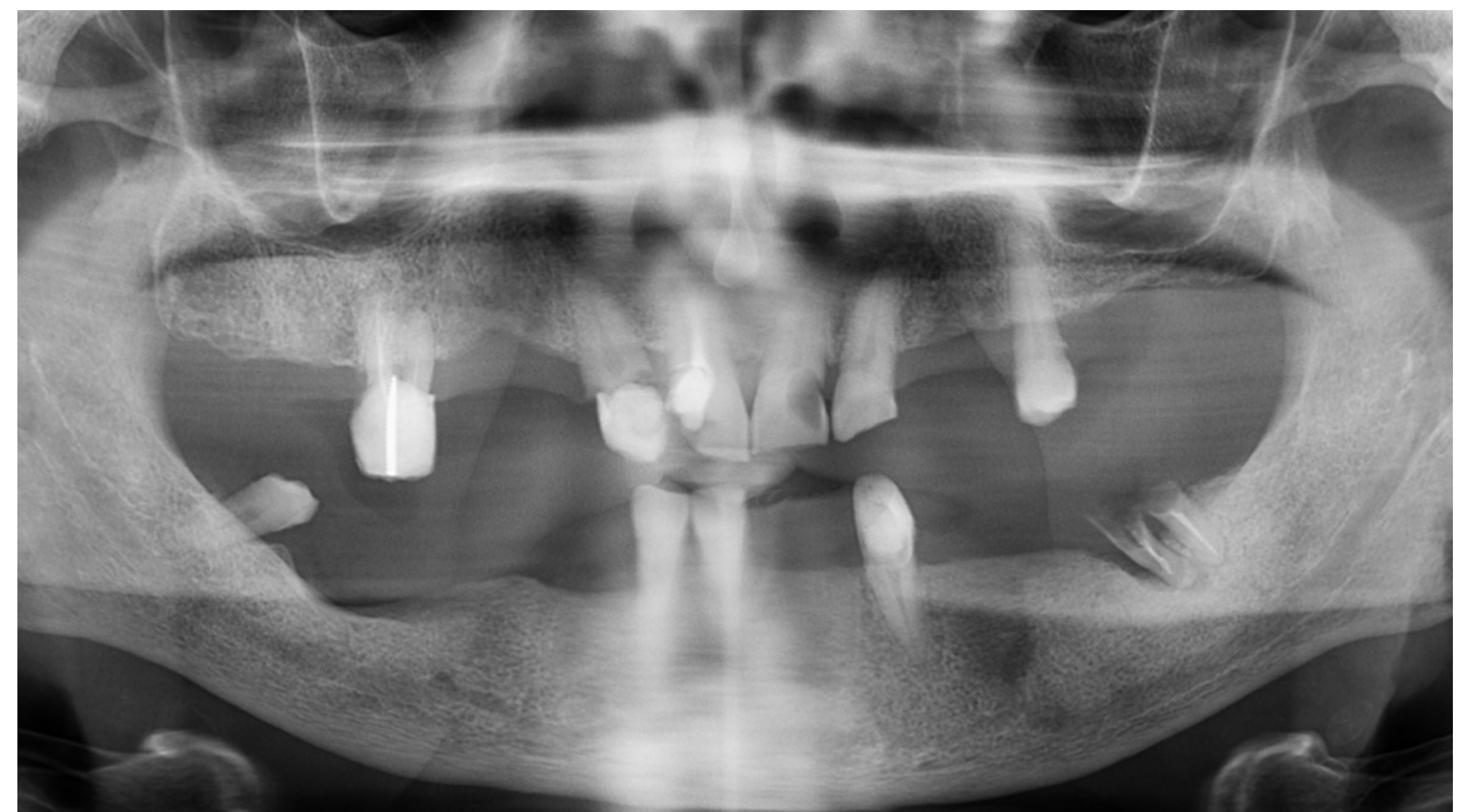

# Challenge 5: Cross-bite occlusion

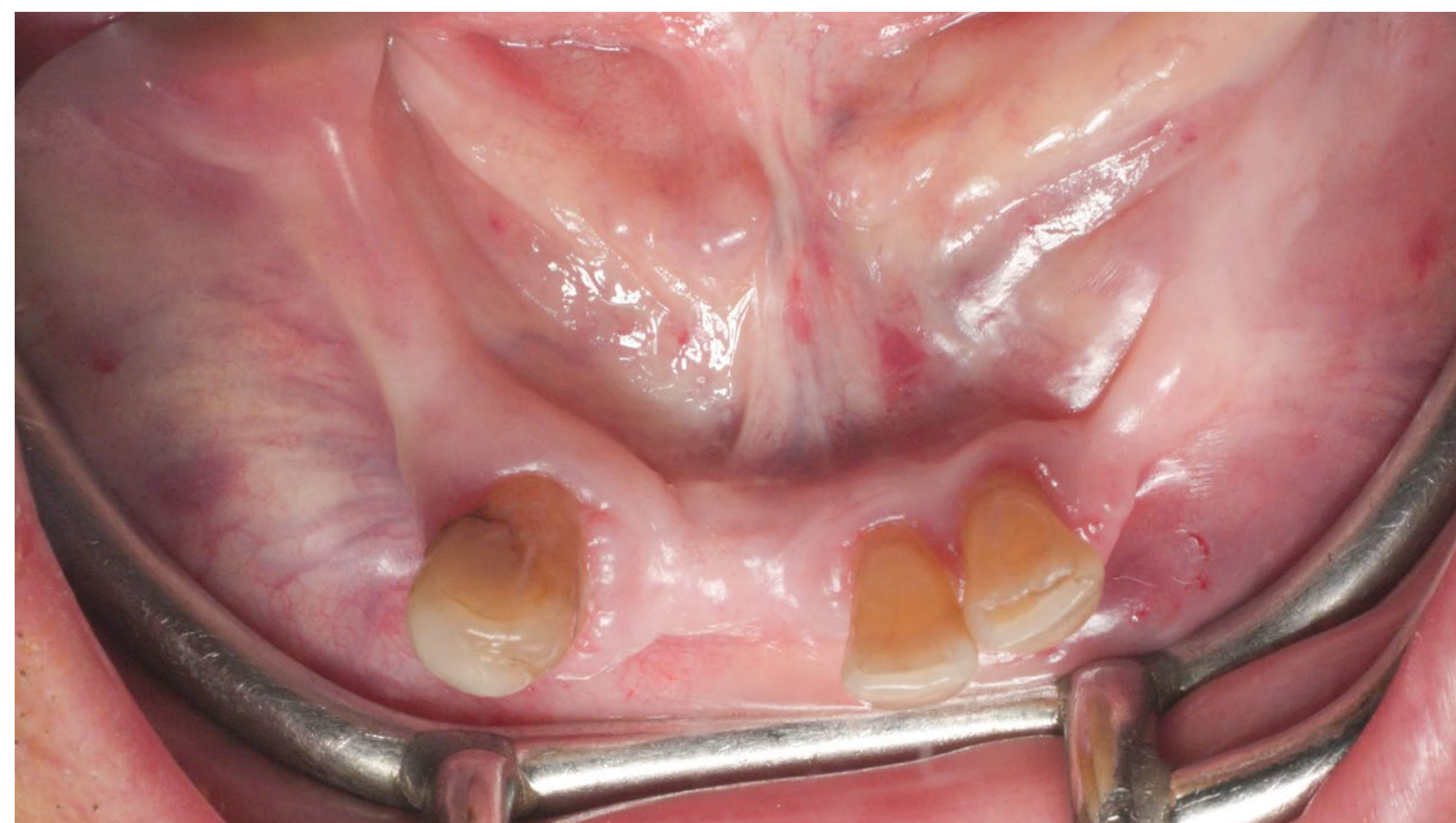## Clinical case



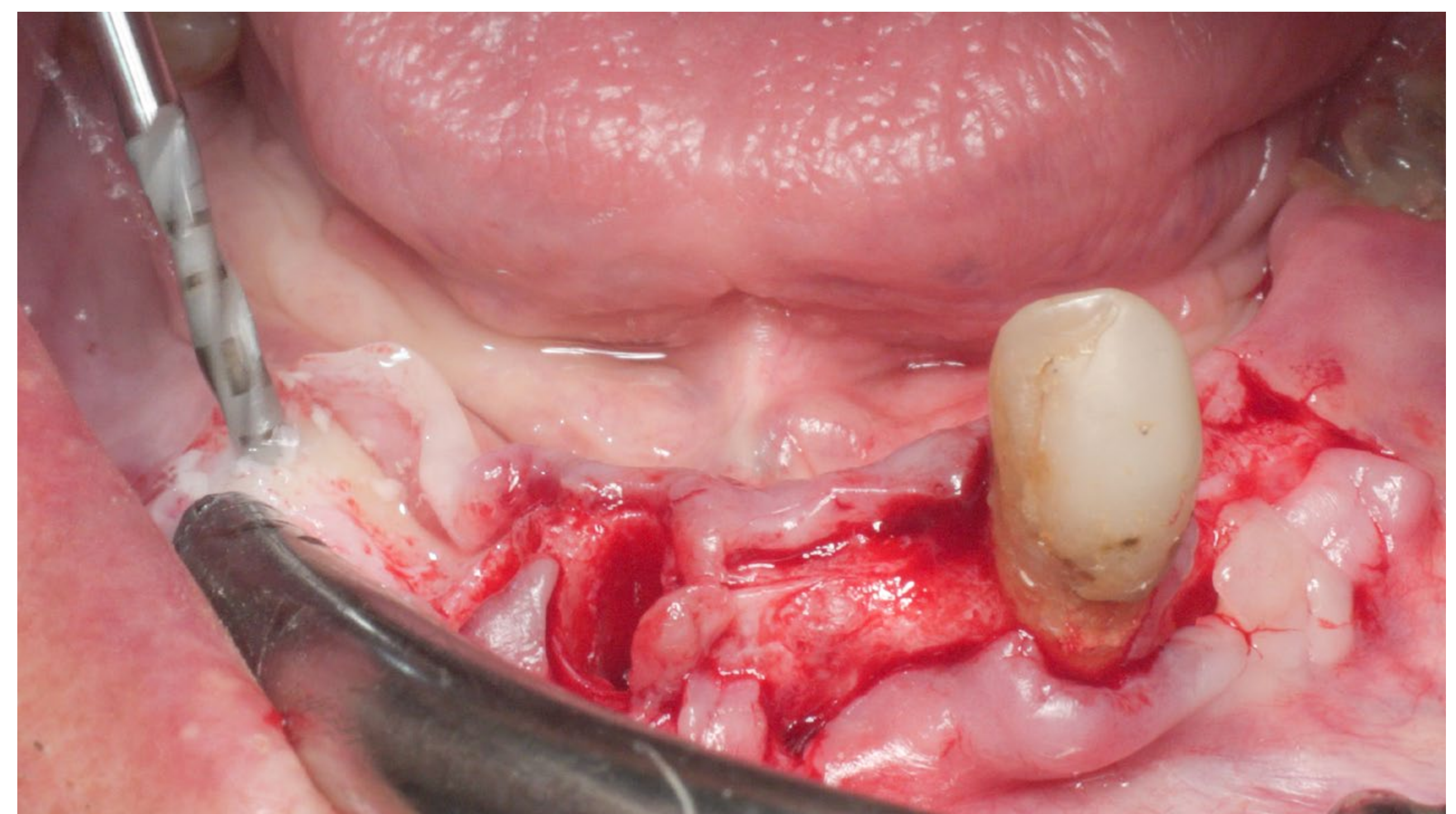
Initial clinical situation  
Intraoral scan



Panoramic preoperative radiograph



Occlusal view

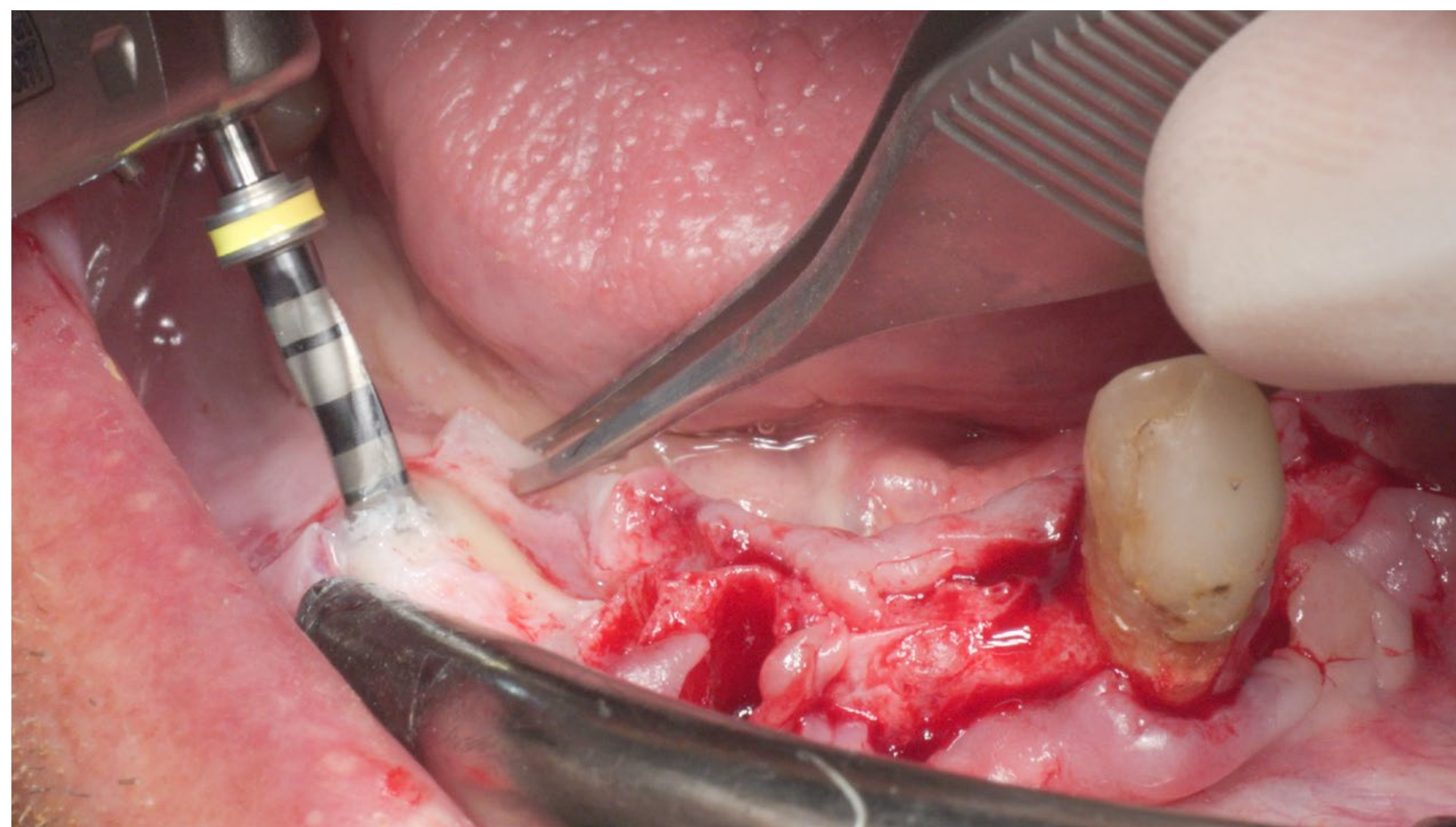


Preparation of posterior implant sites  
Pilot Drill Ø 2.2mm

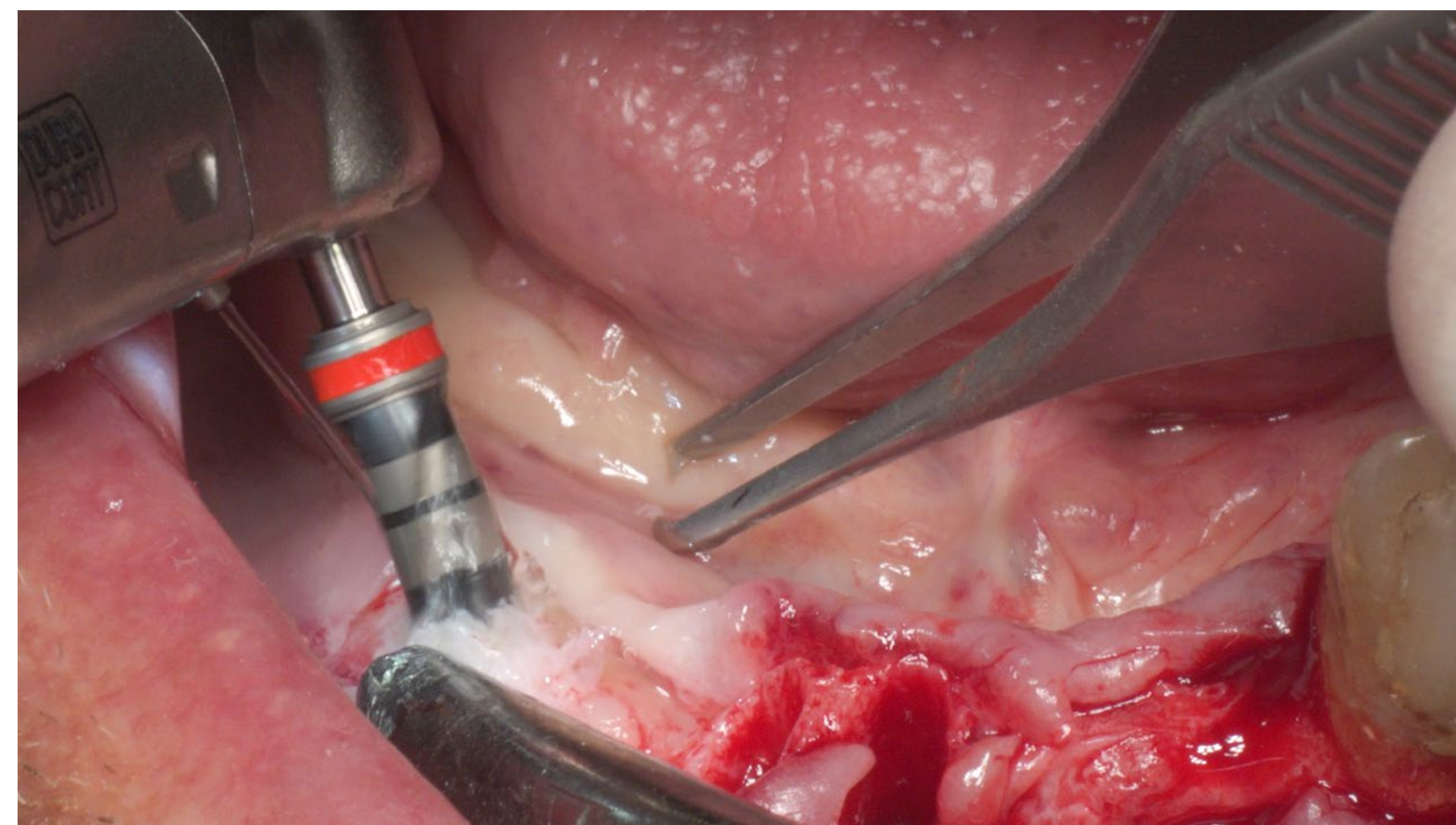


# Challenge 5: Cross-bite occlusion

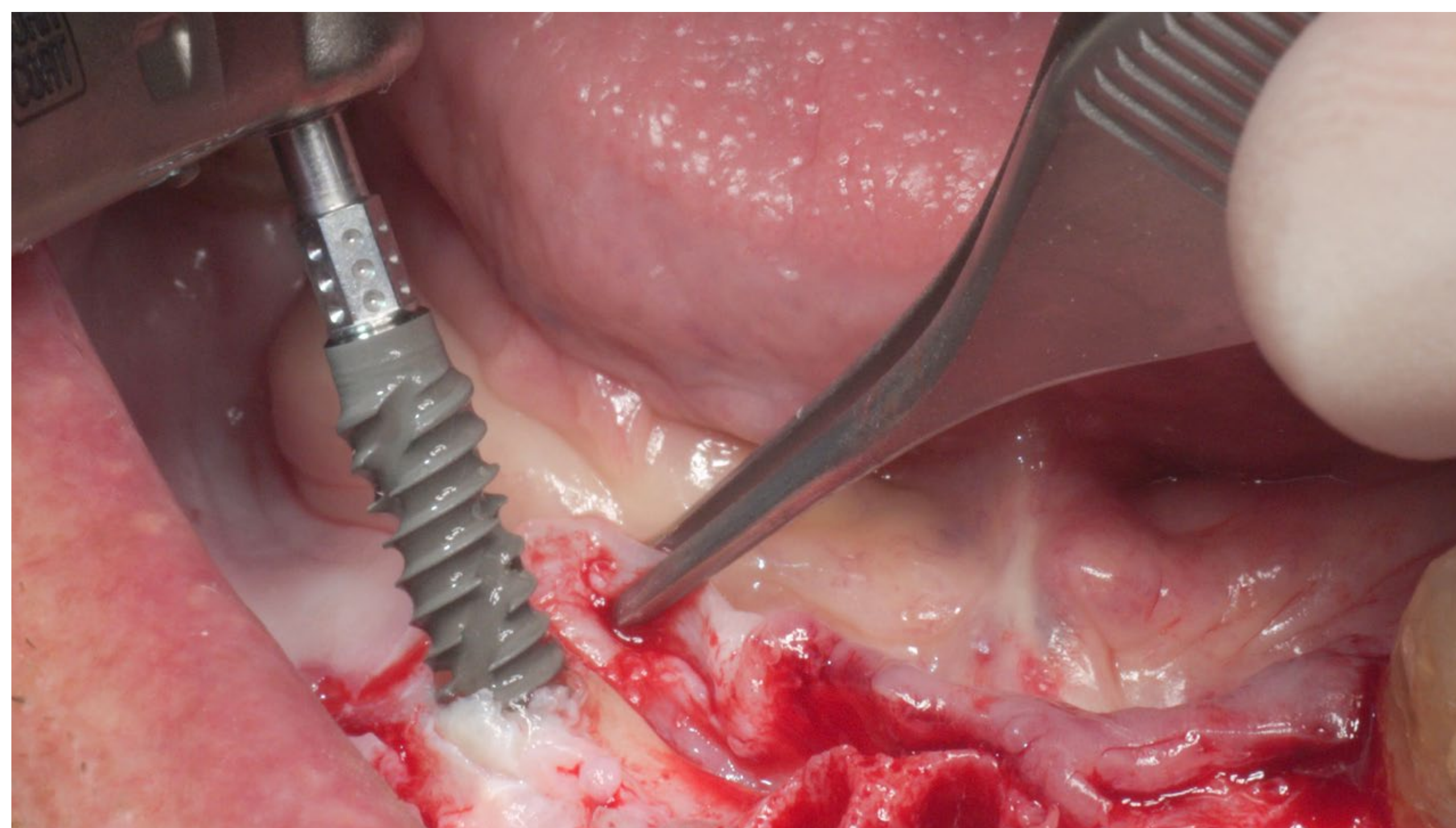
Clinical case



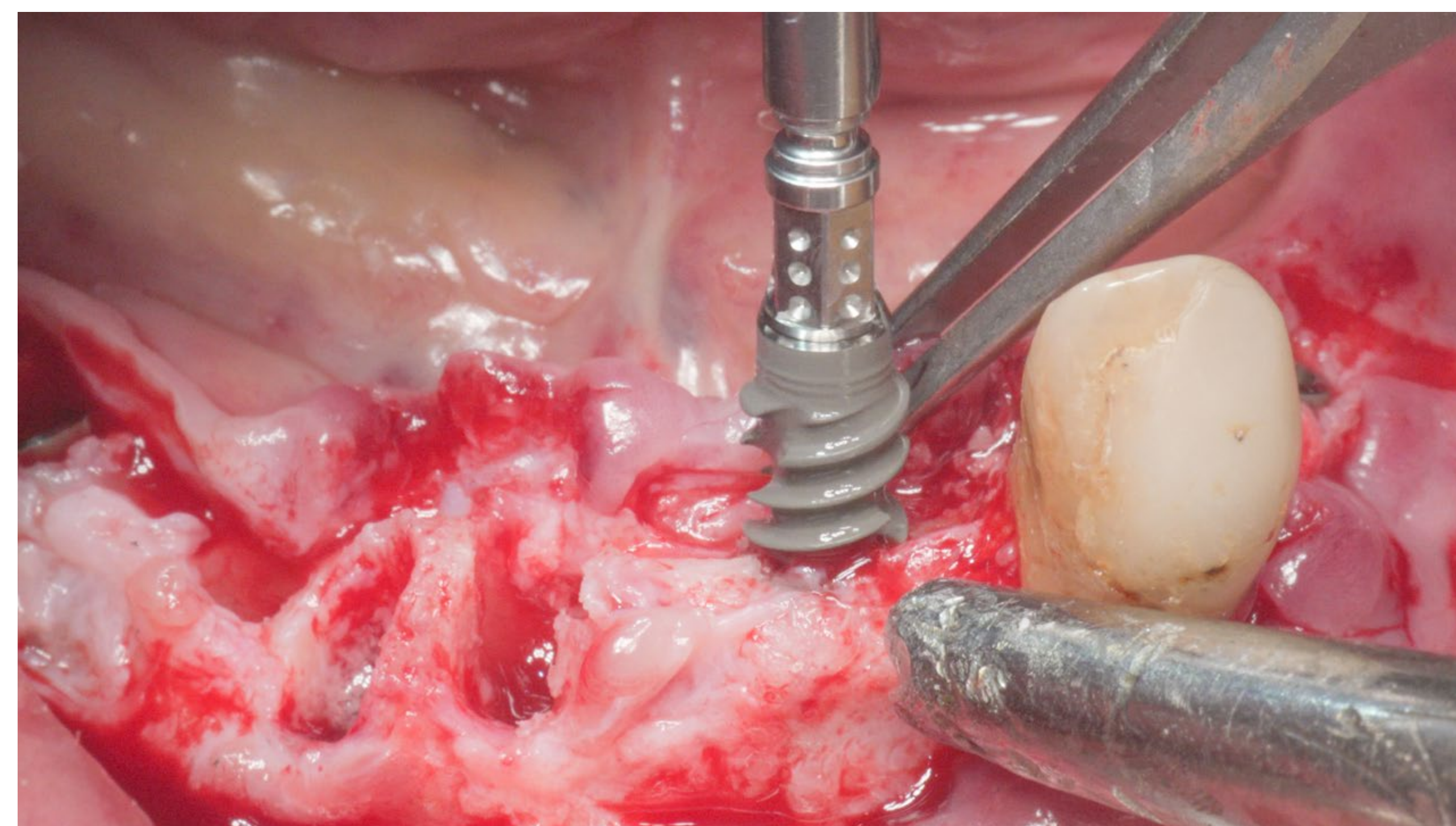
Preparation of posterior implant sites  
Drill Ø 2.8 mm



Preparation of posterior implant sites  
Drill Ø 3.5 mm



Placement of the Straumann® BLX Ø 3.75 mm RB SLActive® 14 mm Roxolid® implant with a torque of 35 Ncm

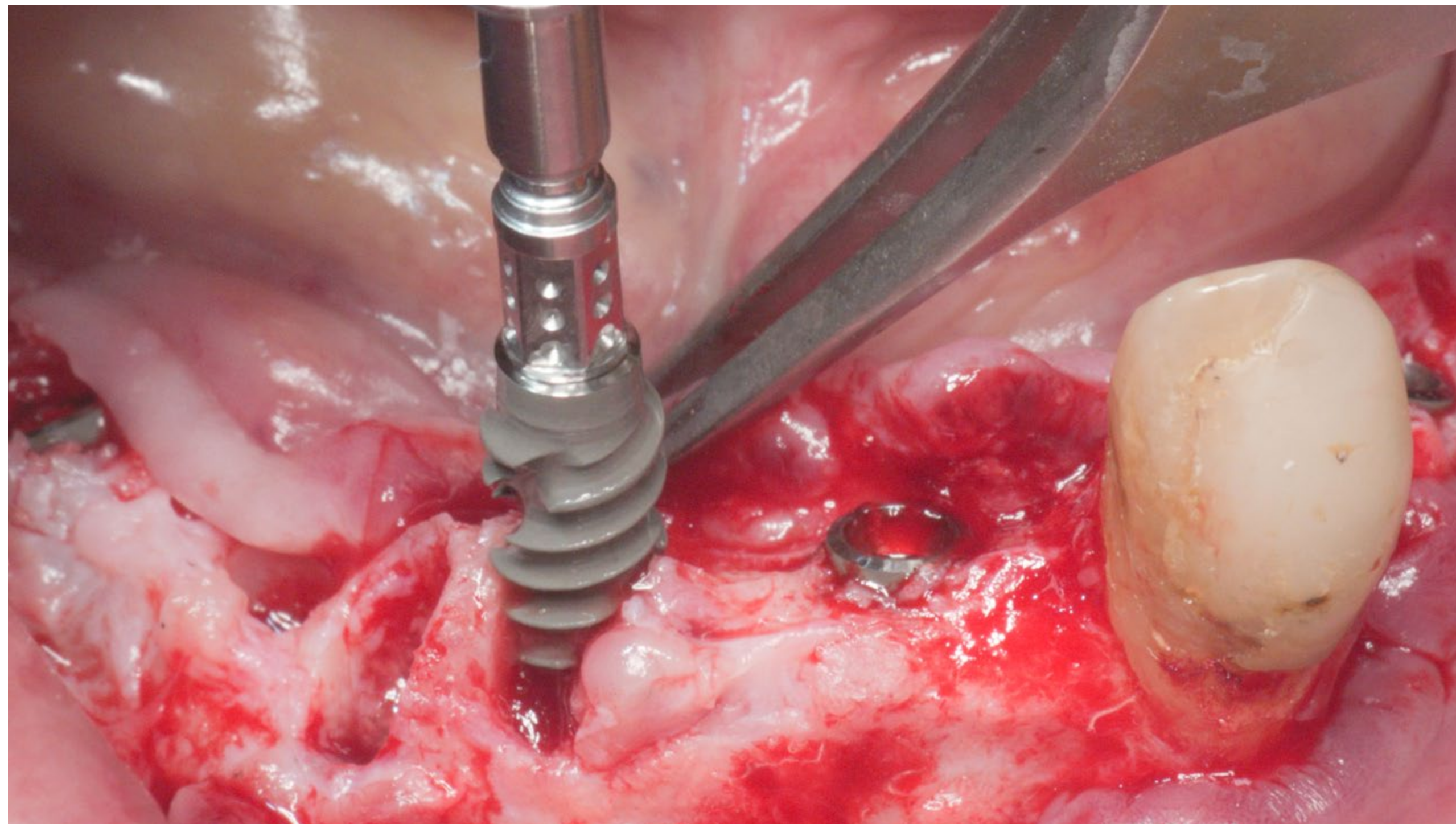


Placement of the Straumann® BLX Ø 4.5 mm RB SLActive® 12 mm Roxolid® implant with a torque of 35 Ncm

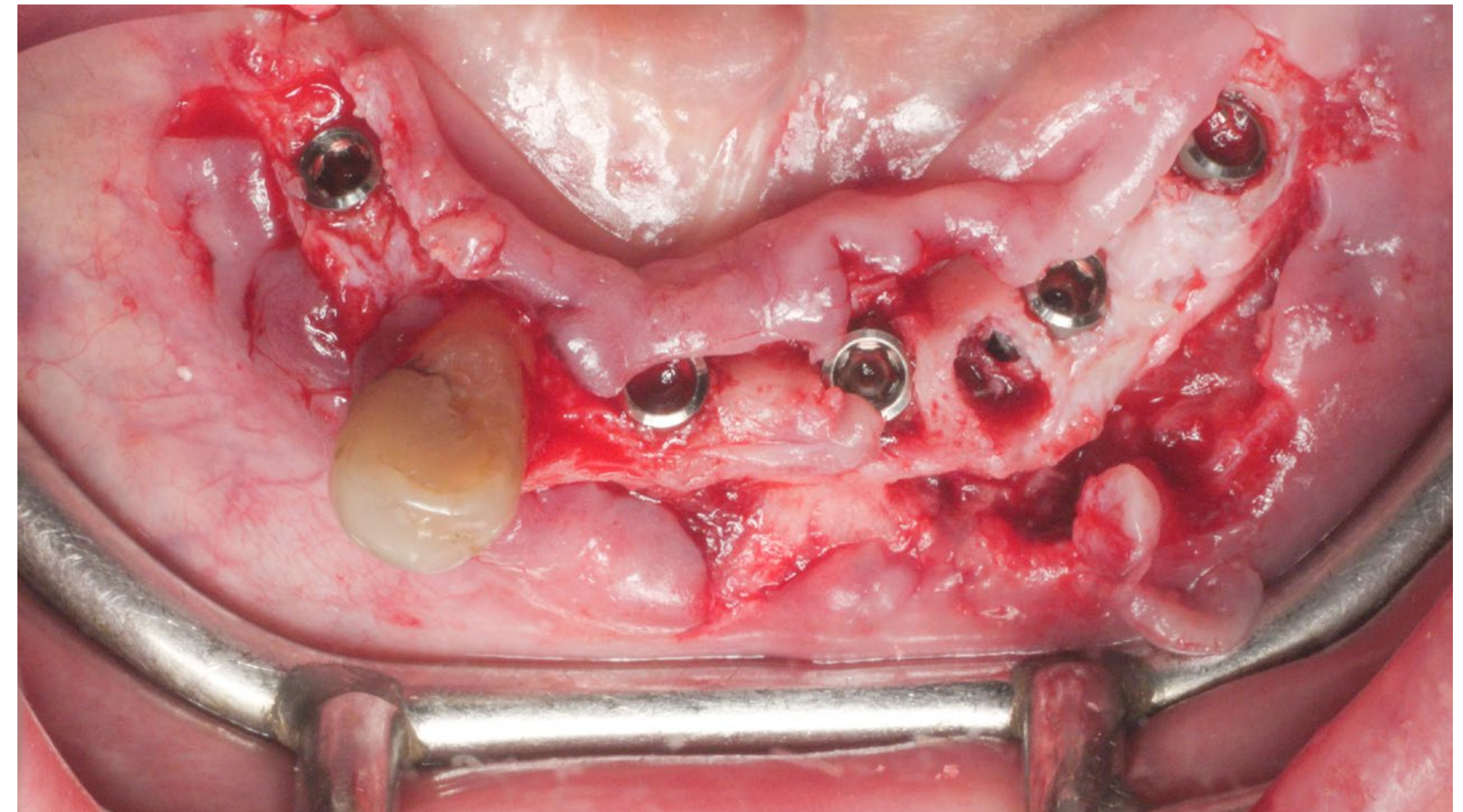

# Challenge 5: Cross-bite occlusion

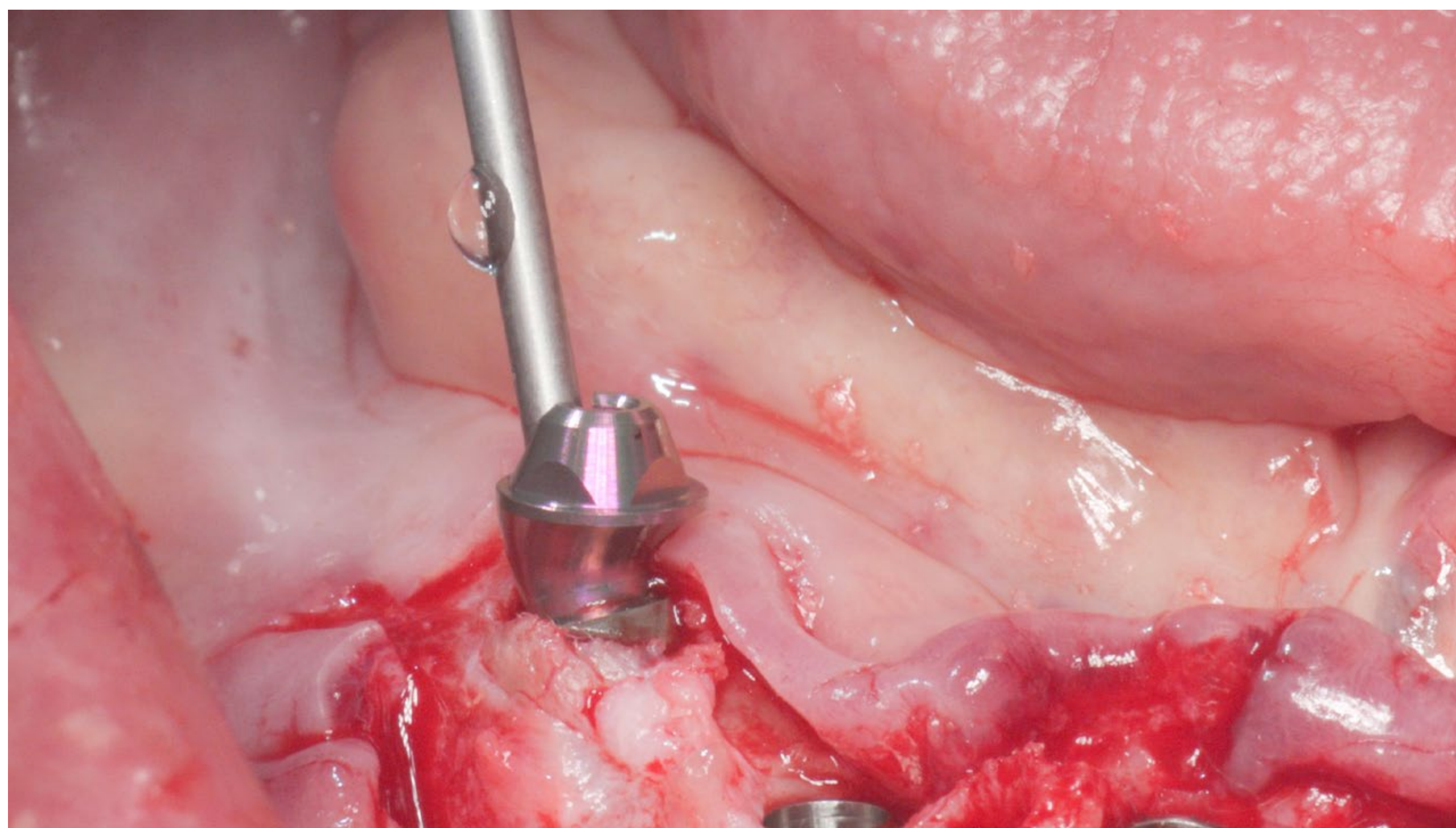
Clinical case



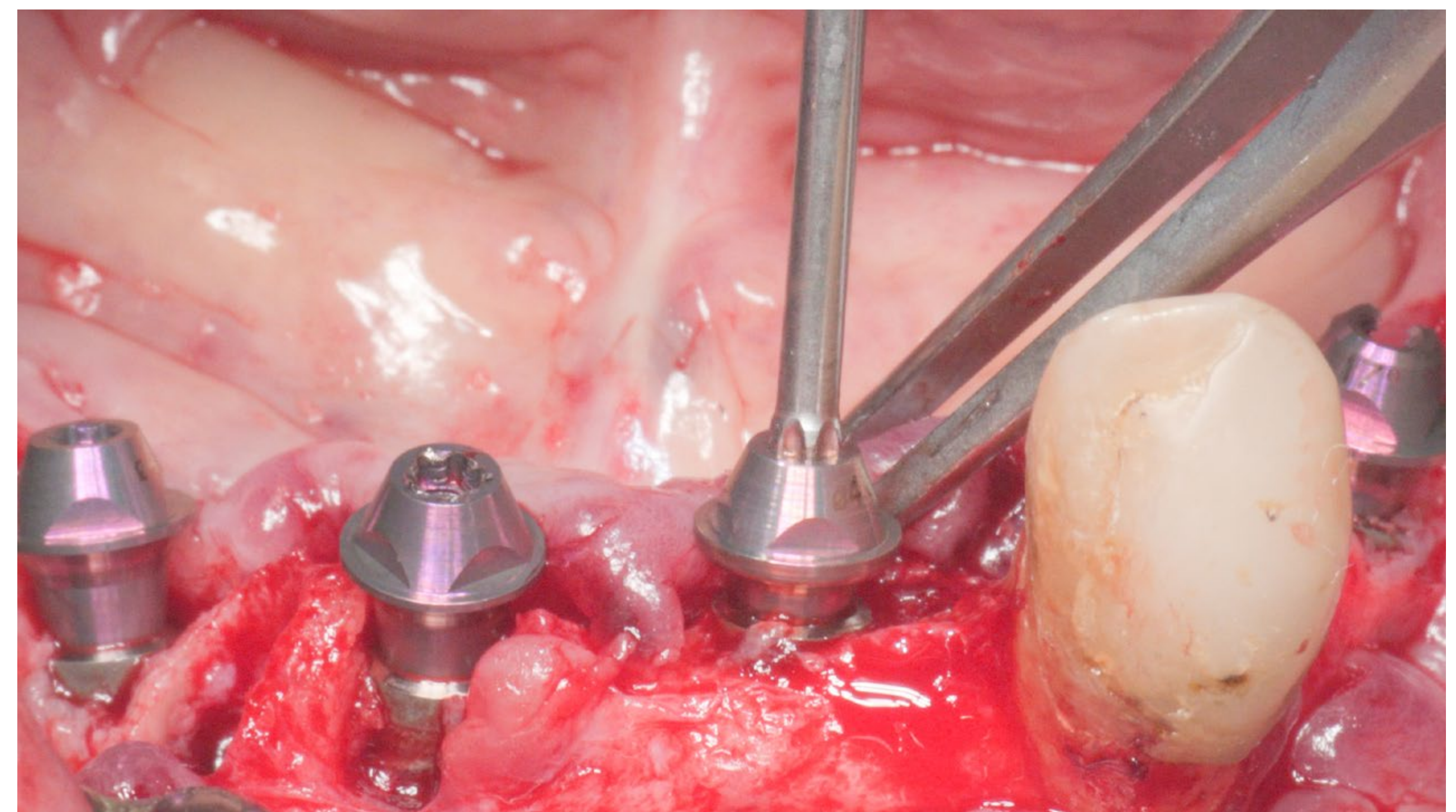
Placement of the Straumann® BLX Ø 4.5 mm RB SLActive® 12 mm Roxolid® implant with a torque of 35 Ncm



All implants in place



Placement of the Screw-retained Abutments

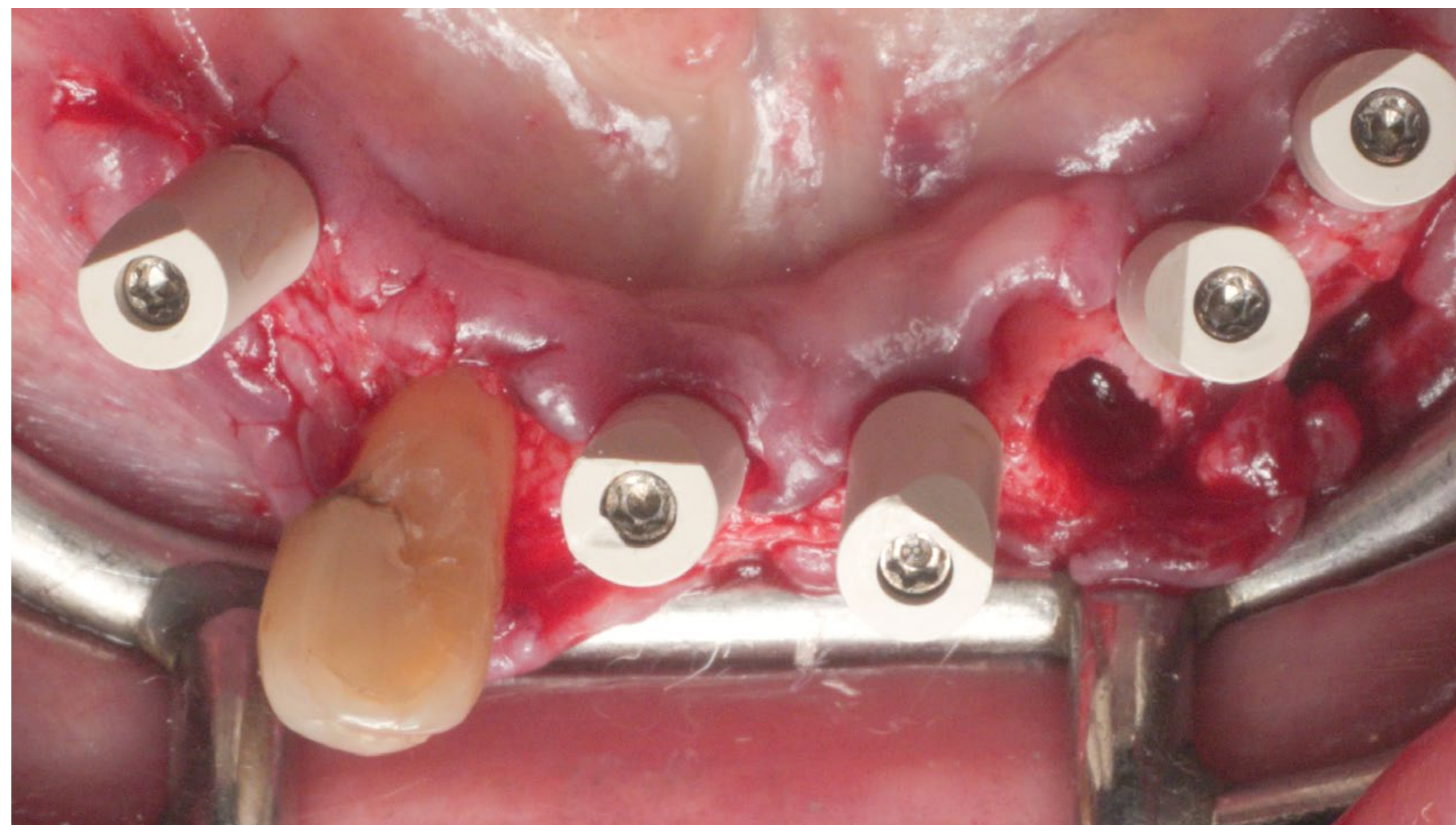


Screw-retained Abutments in place

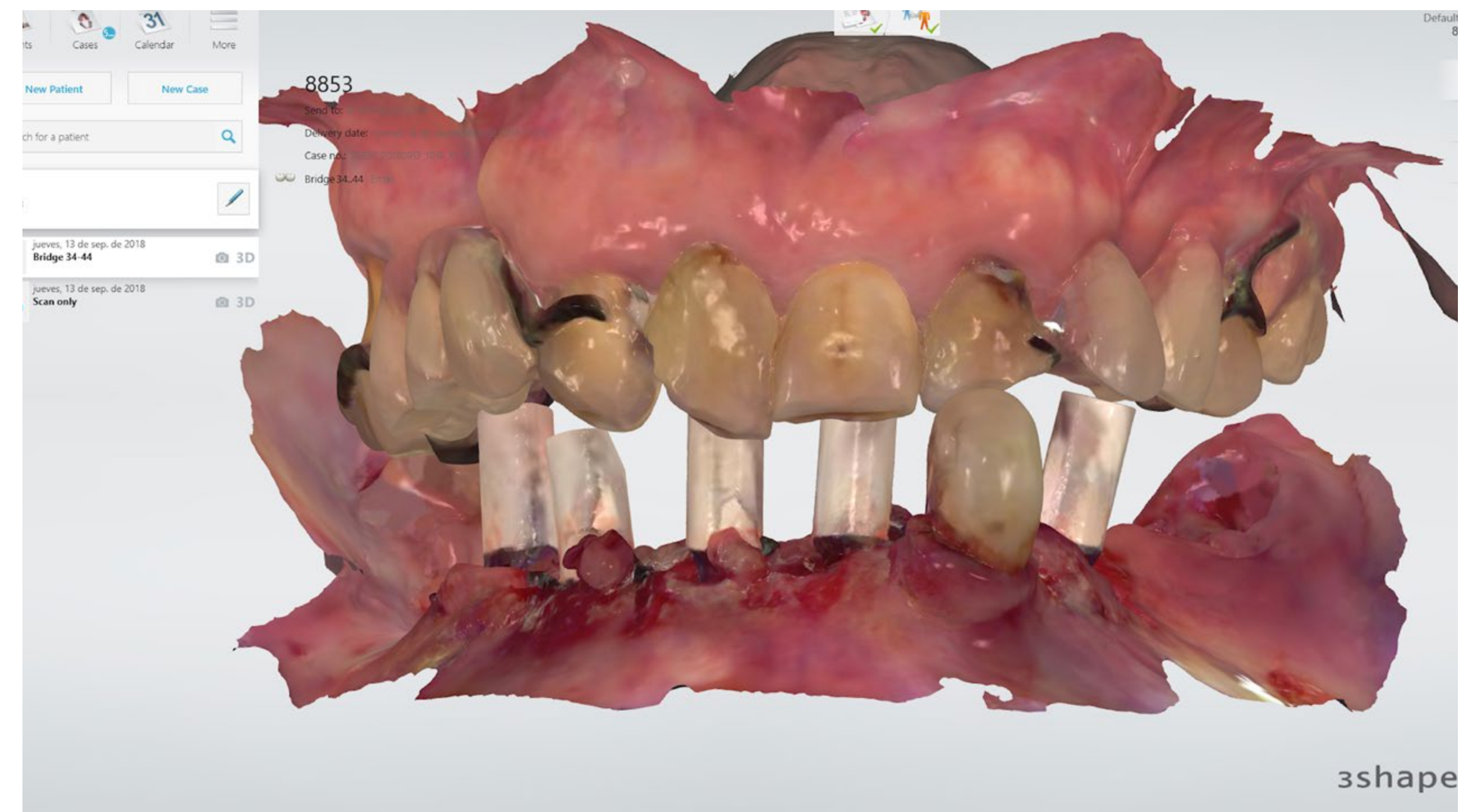

# Challenge 5: Cross-bite occlusion

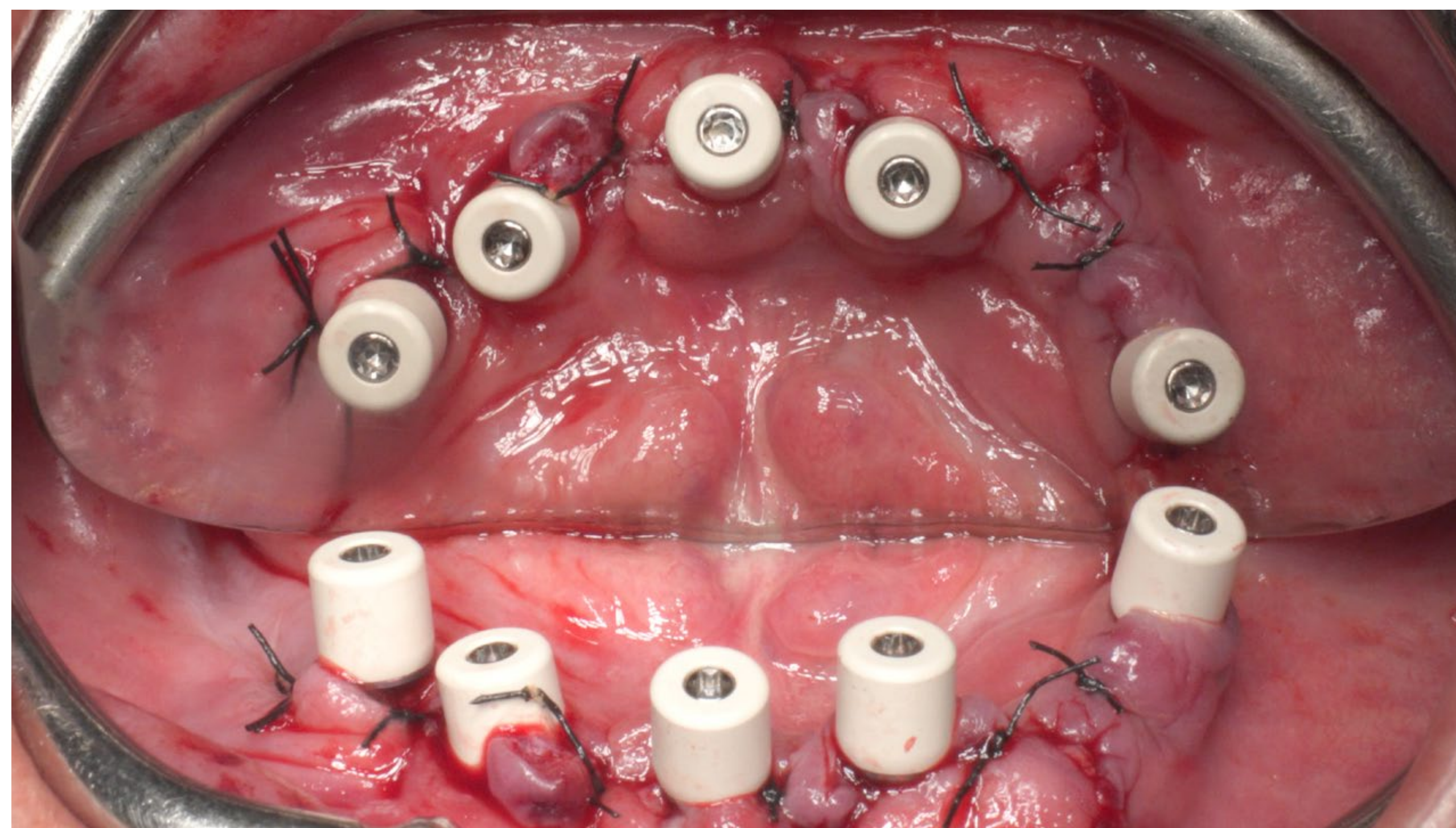
Clinical case



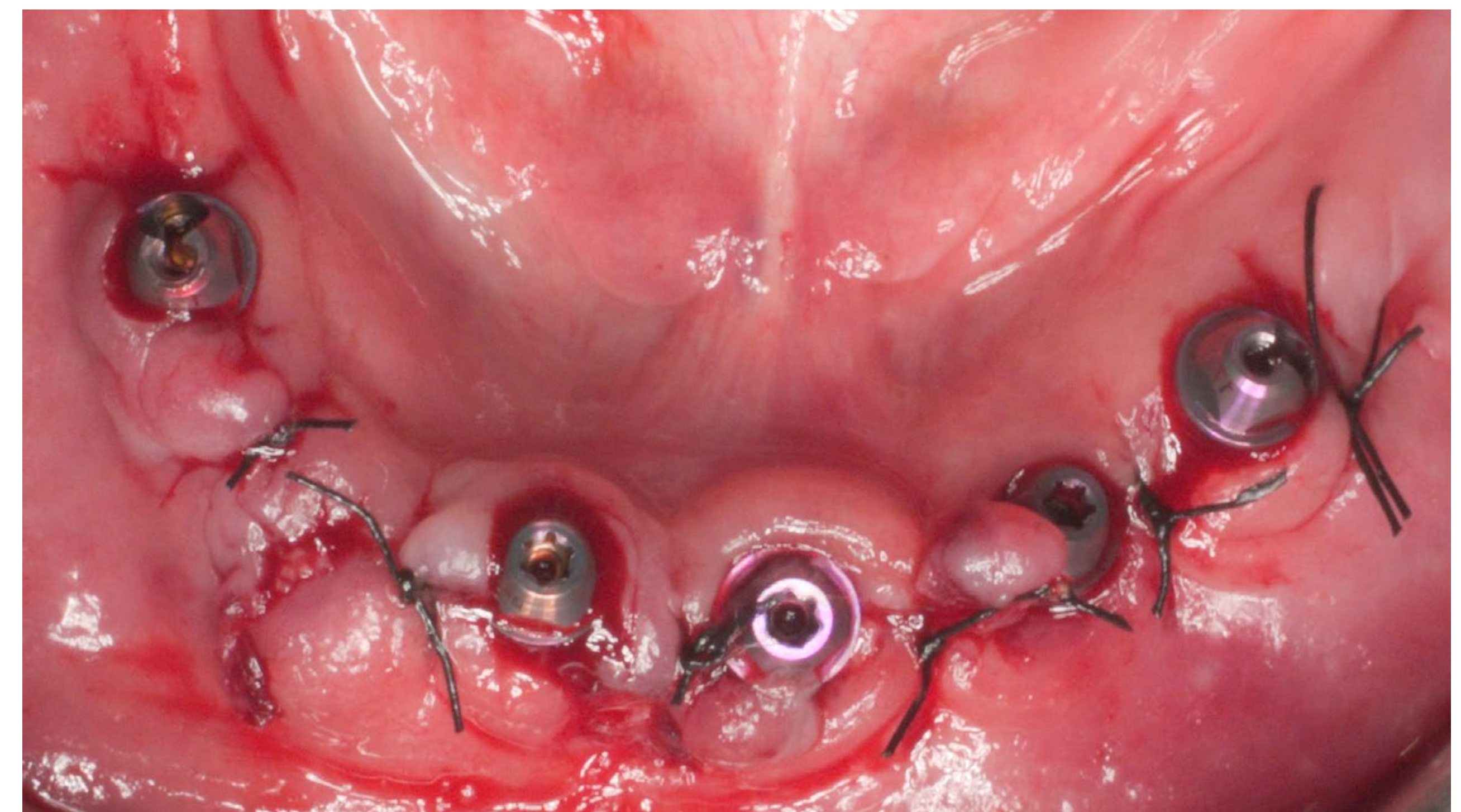
Scanbodies in place



Intraoral scan



Protective Caps  $\varnothing$  4.6 mm in place

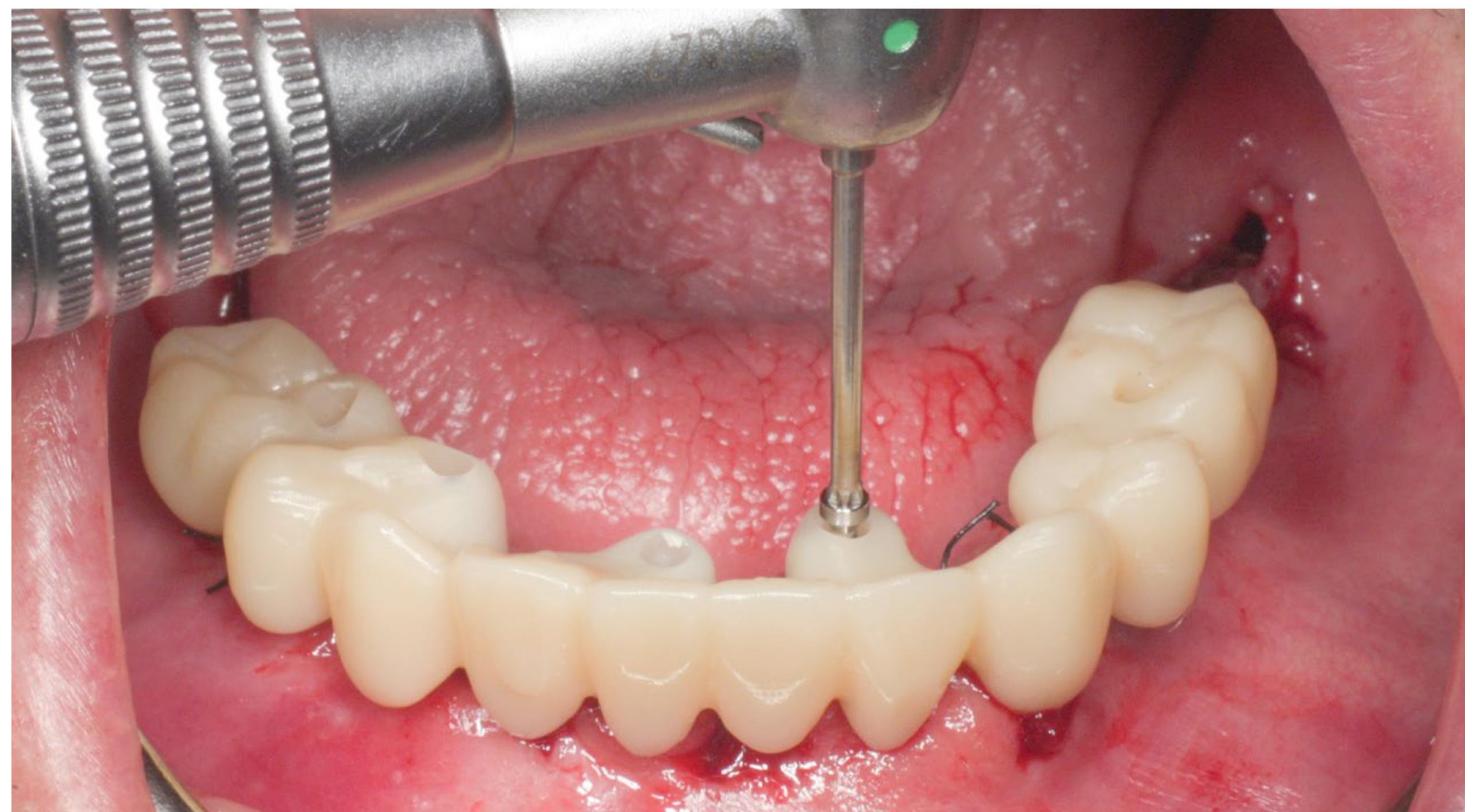

Sutured site

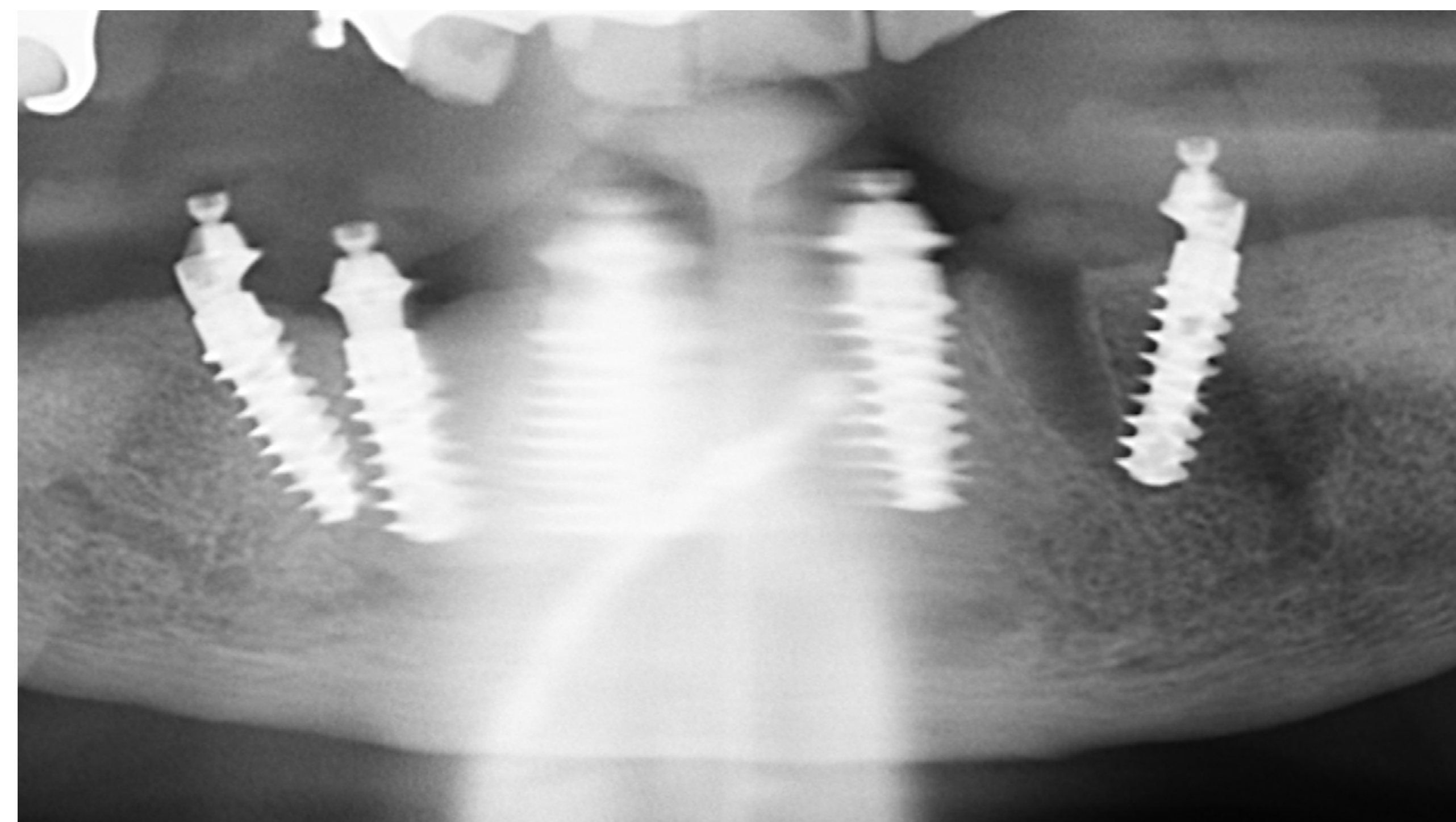


# Challenge 5: Cross-bite occlusion

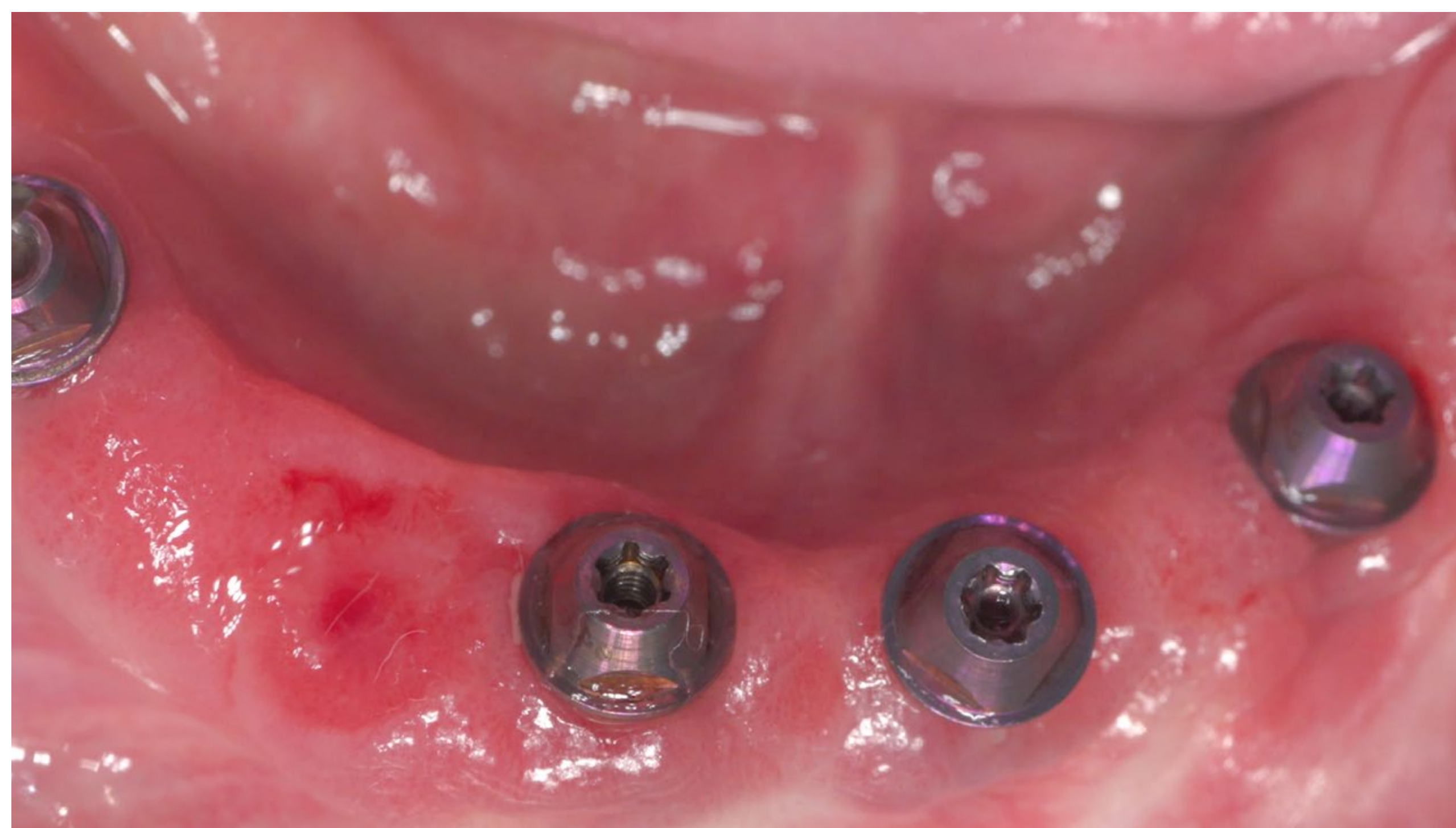
Clinical case



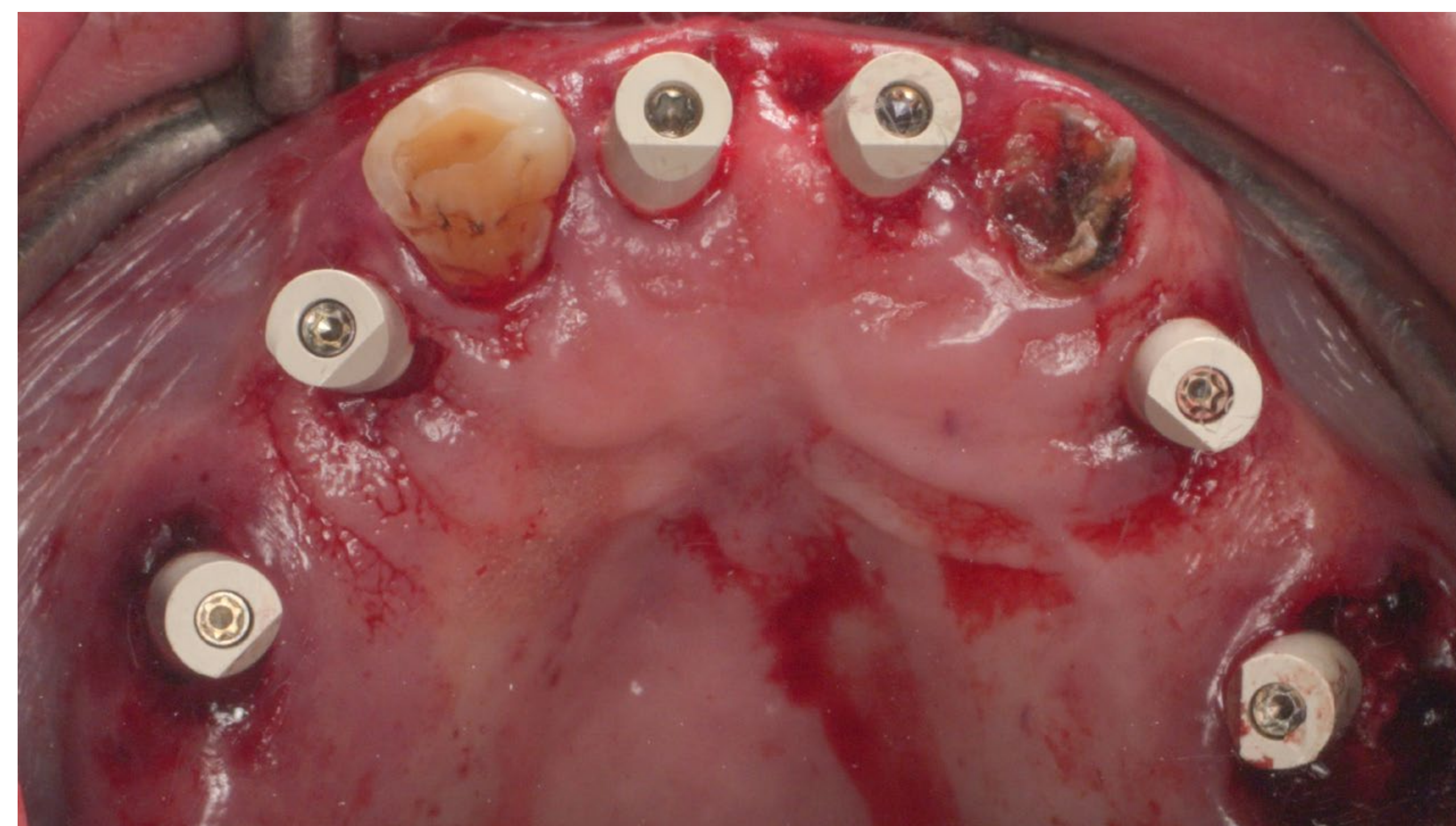
Placement of the provisional prosthesis  
Occlusal view



Panoramic postoperative radiograph with temporary prosthesis



Healed site two months after the surgery

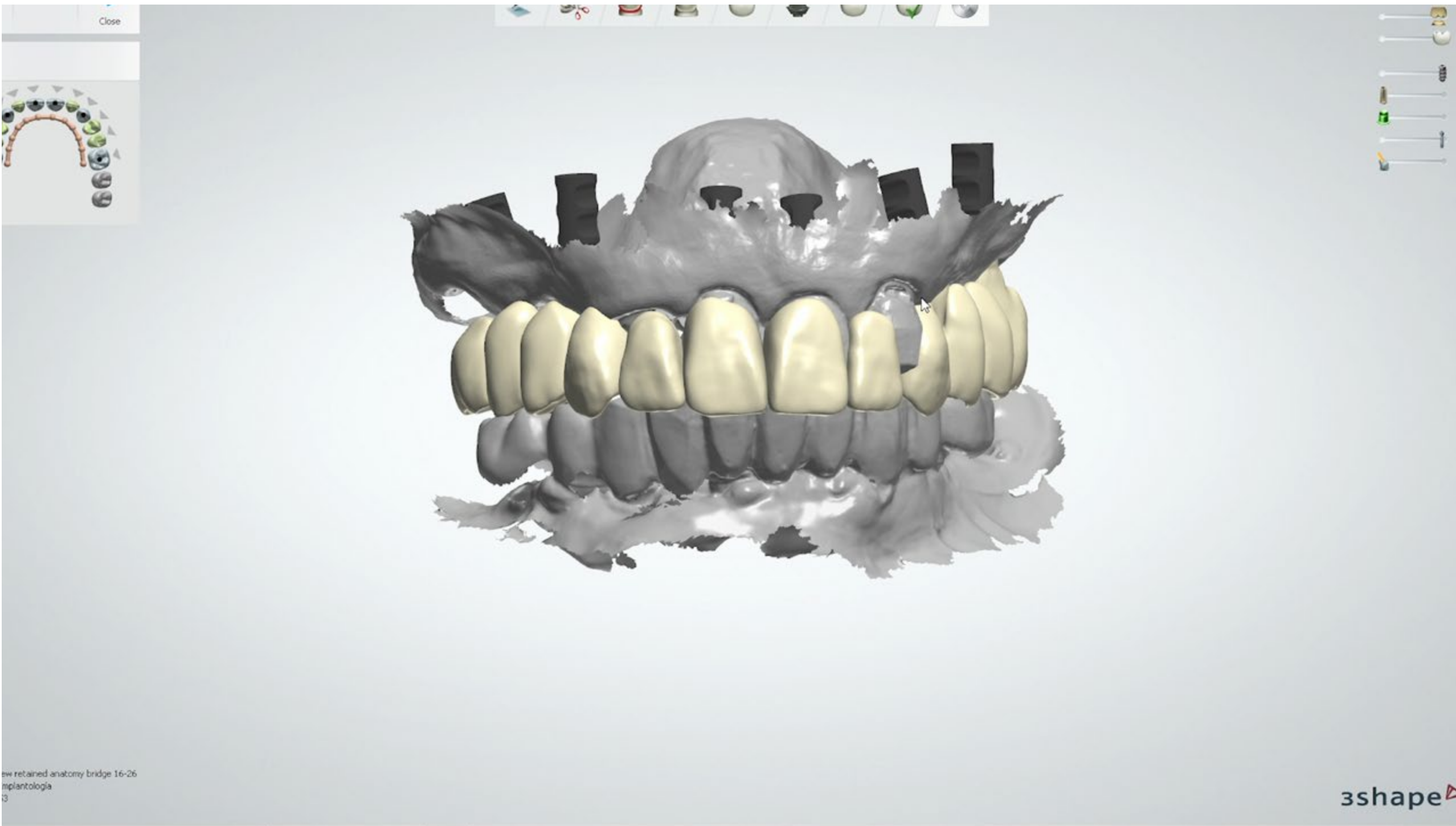


Two months after the restoration of the lower jaw, the treatment of the upper arch is initiated. Implants and Screw-retained Abutments were placed, followed by the placement of CARES® Mono Scanbody for Screw-retained Abutments.




# Challenge 5: Cross-bite occlusion

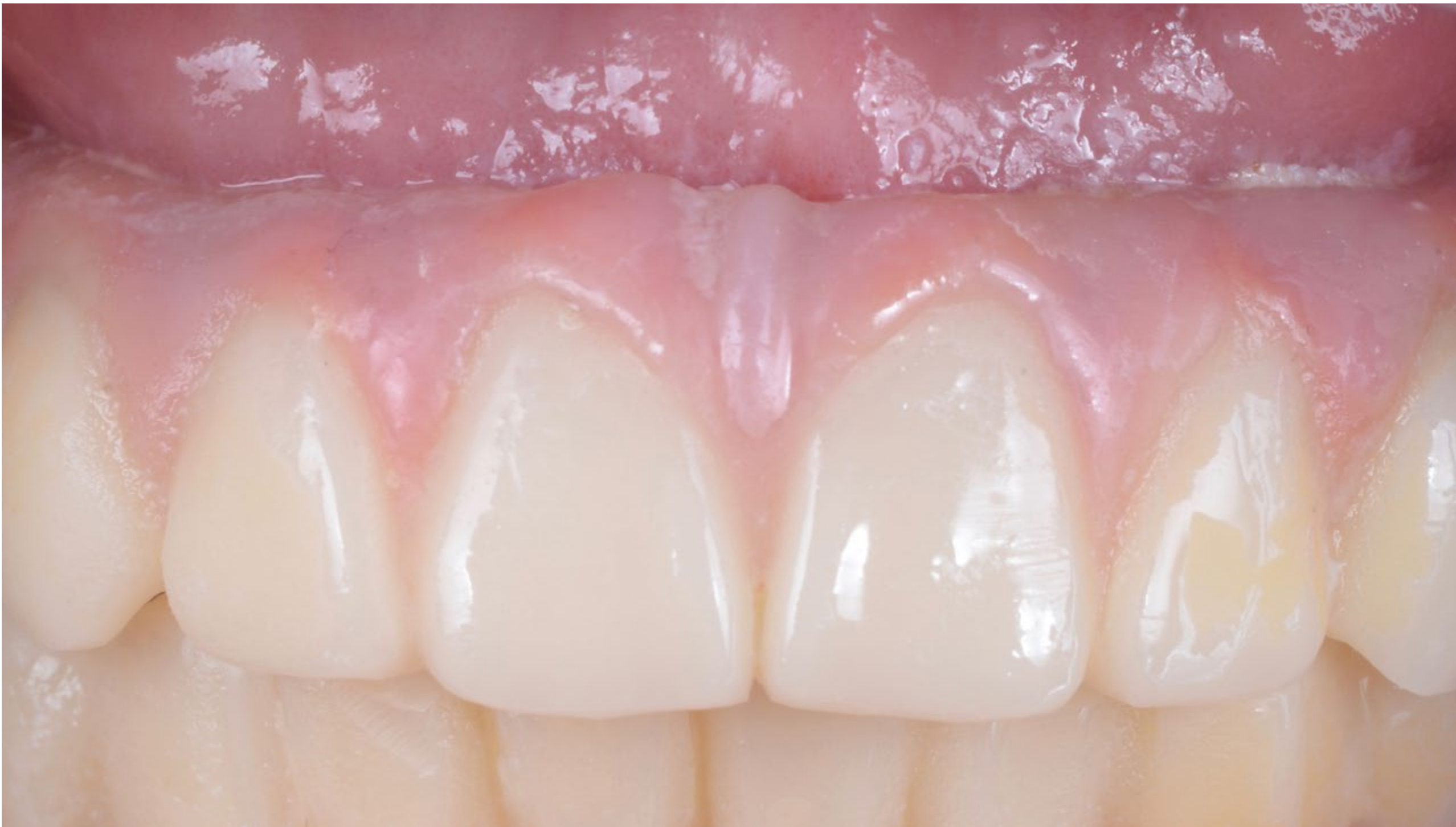Clinical case



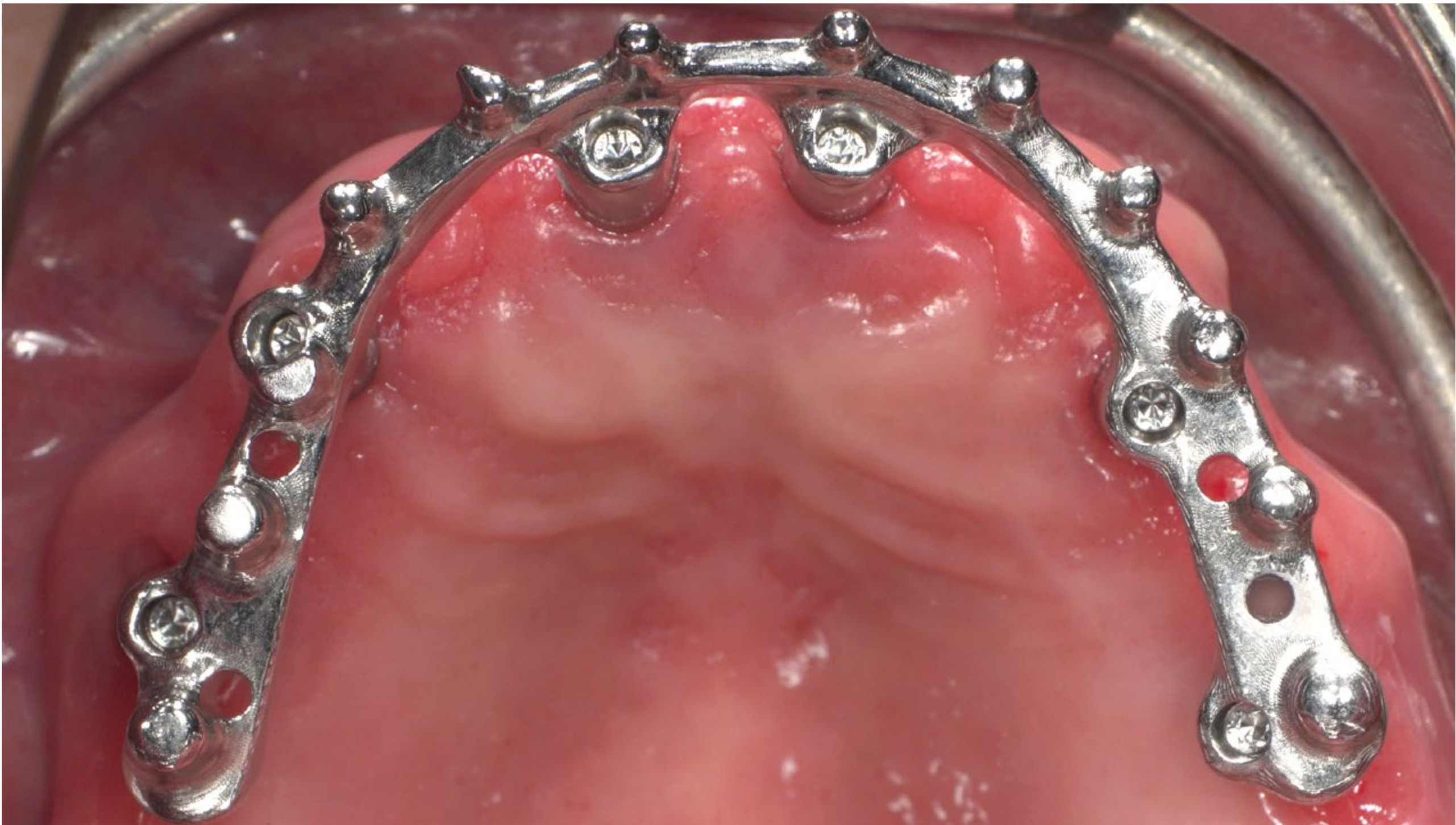Design for the manufacturing of the provisional prosthesis



Panoramic postoperative radiograph with temporary prosthesis



Placement of the provisional prosthesis in the maxilla

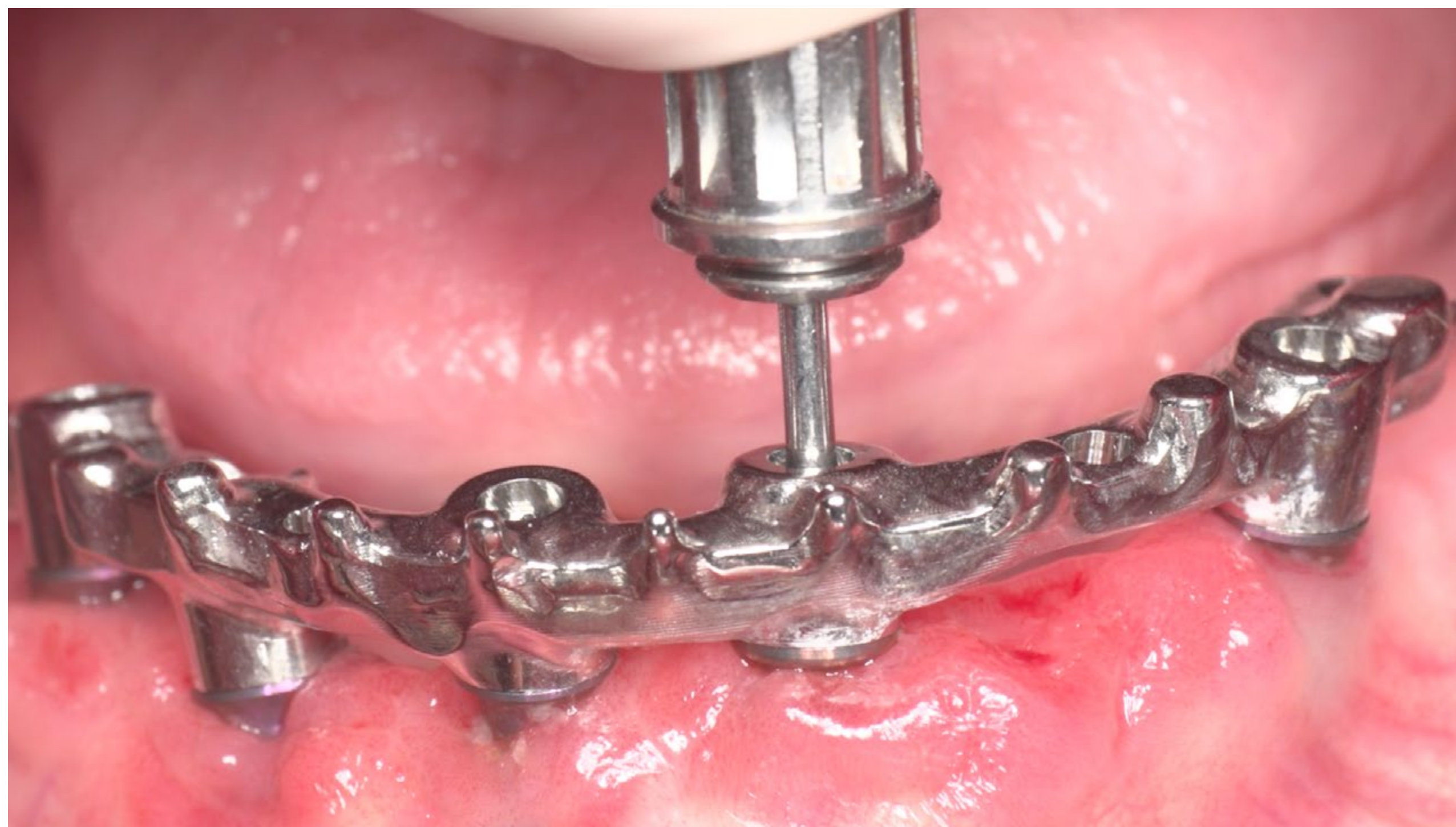

Passive fit of the Createch milled CrCo framework is assessed  
Occlusal view of upper jaw

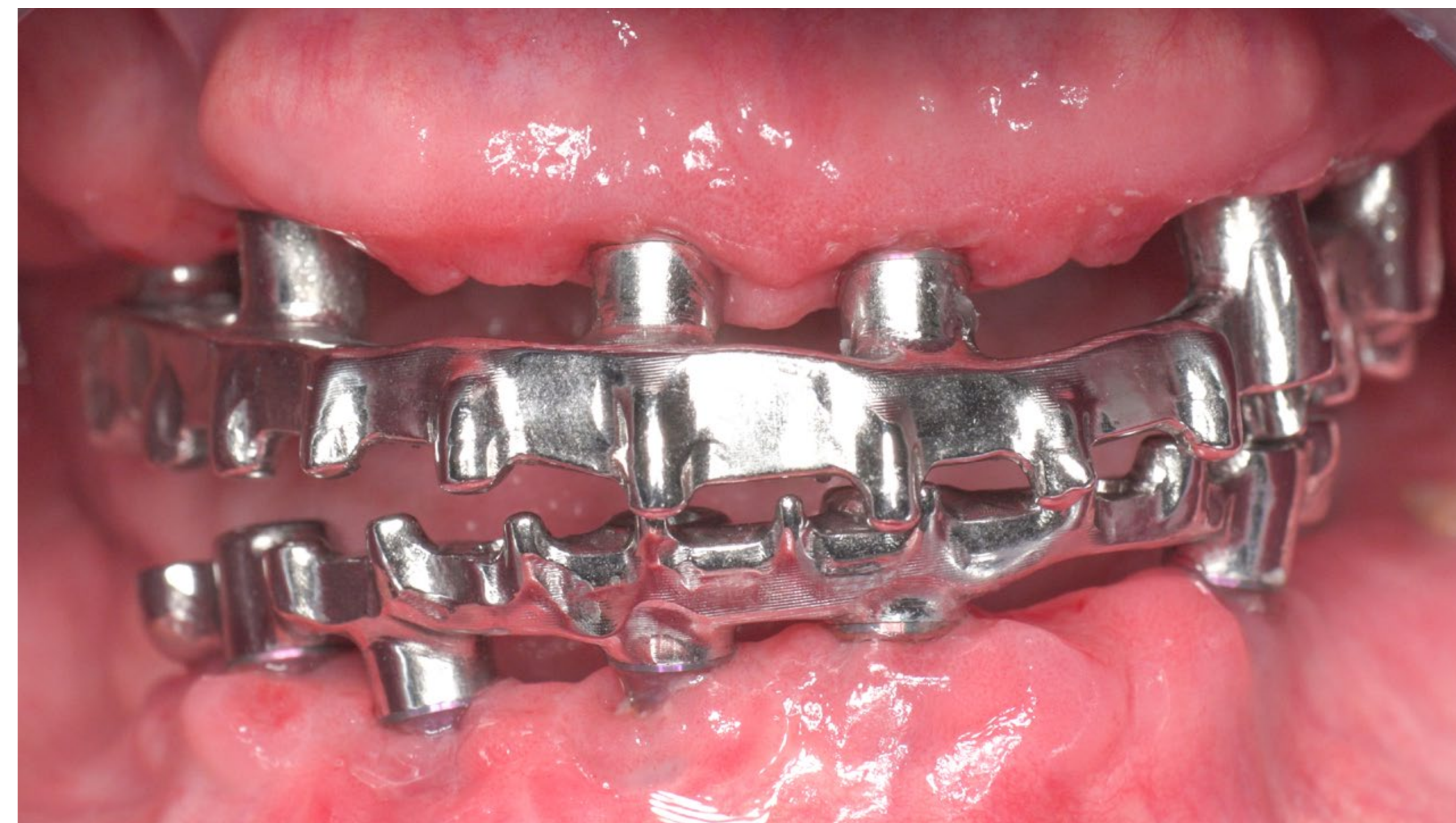

# Challenge 5: Cross-bite occlusion

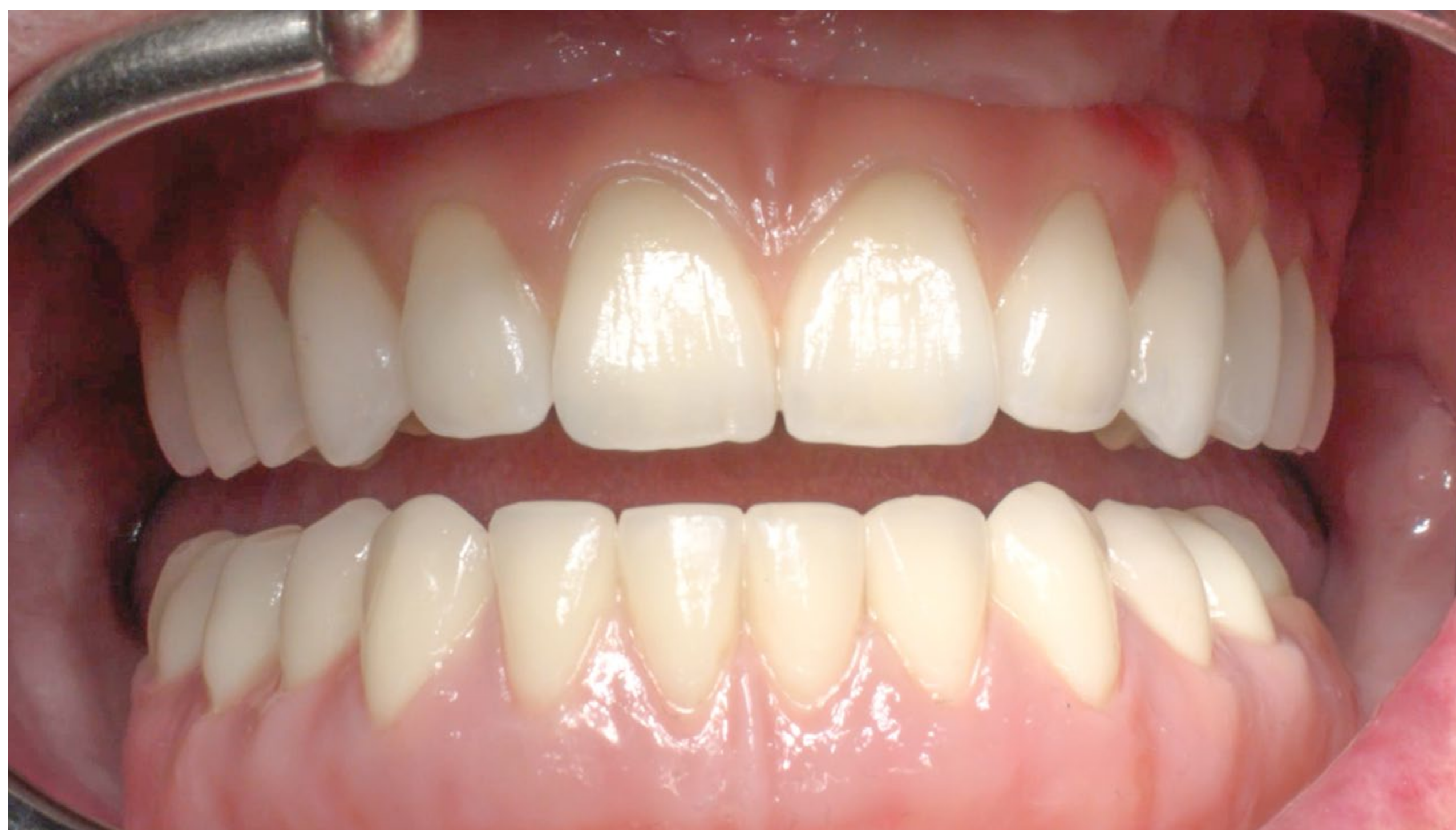Clinical case



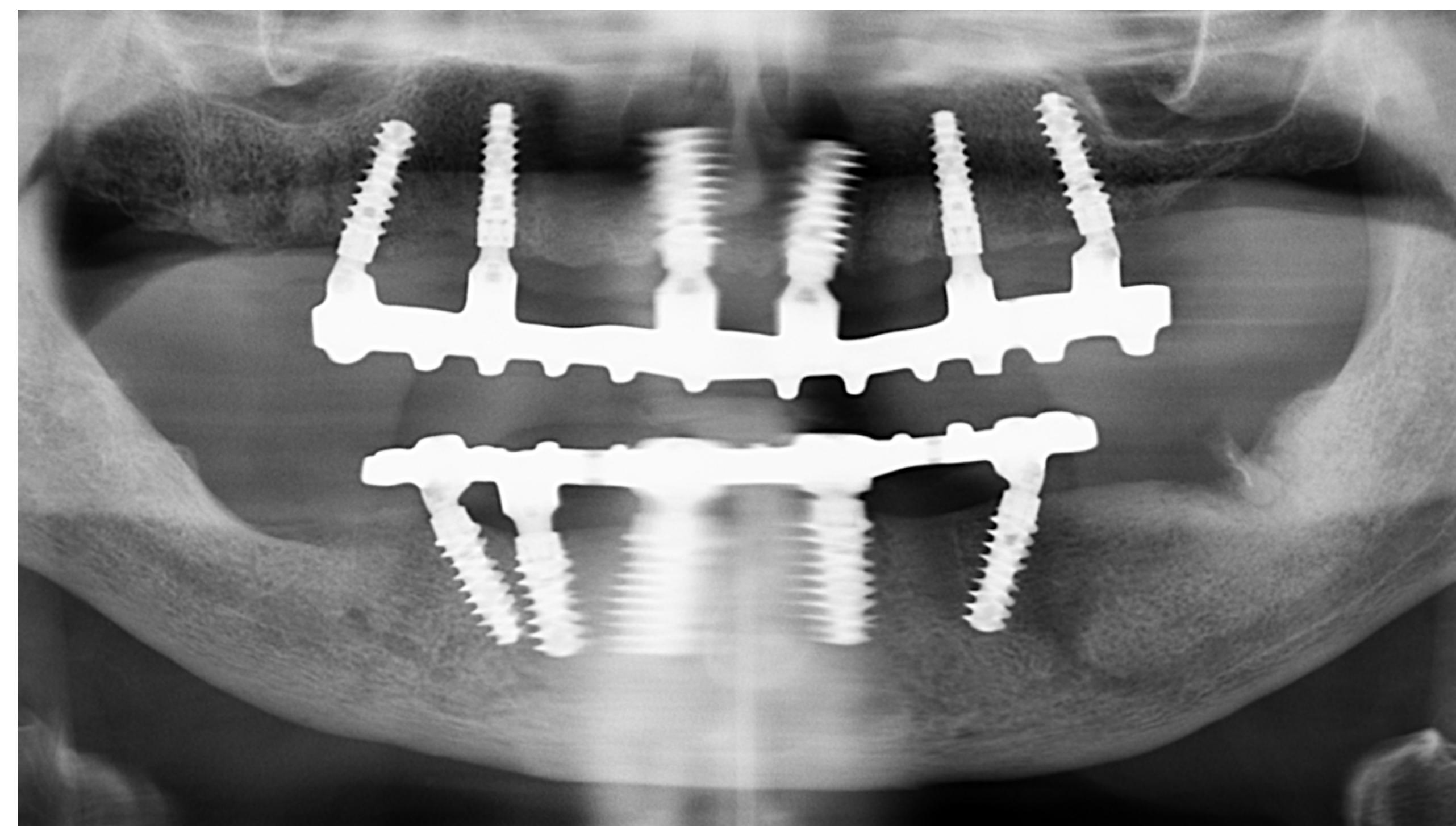
Passive fit of the Createch milled CrCo framework is assessed  
Frontal view of lower jaw



Assessment of vertical dimension in ideal space for hybrid CrCo prosthesis and resin



Final hybrid resin prosthesis hand characterized restoration in place

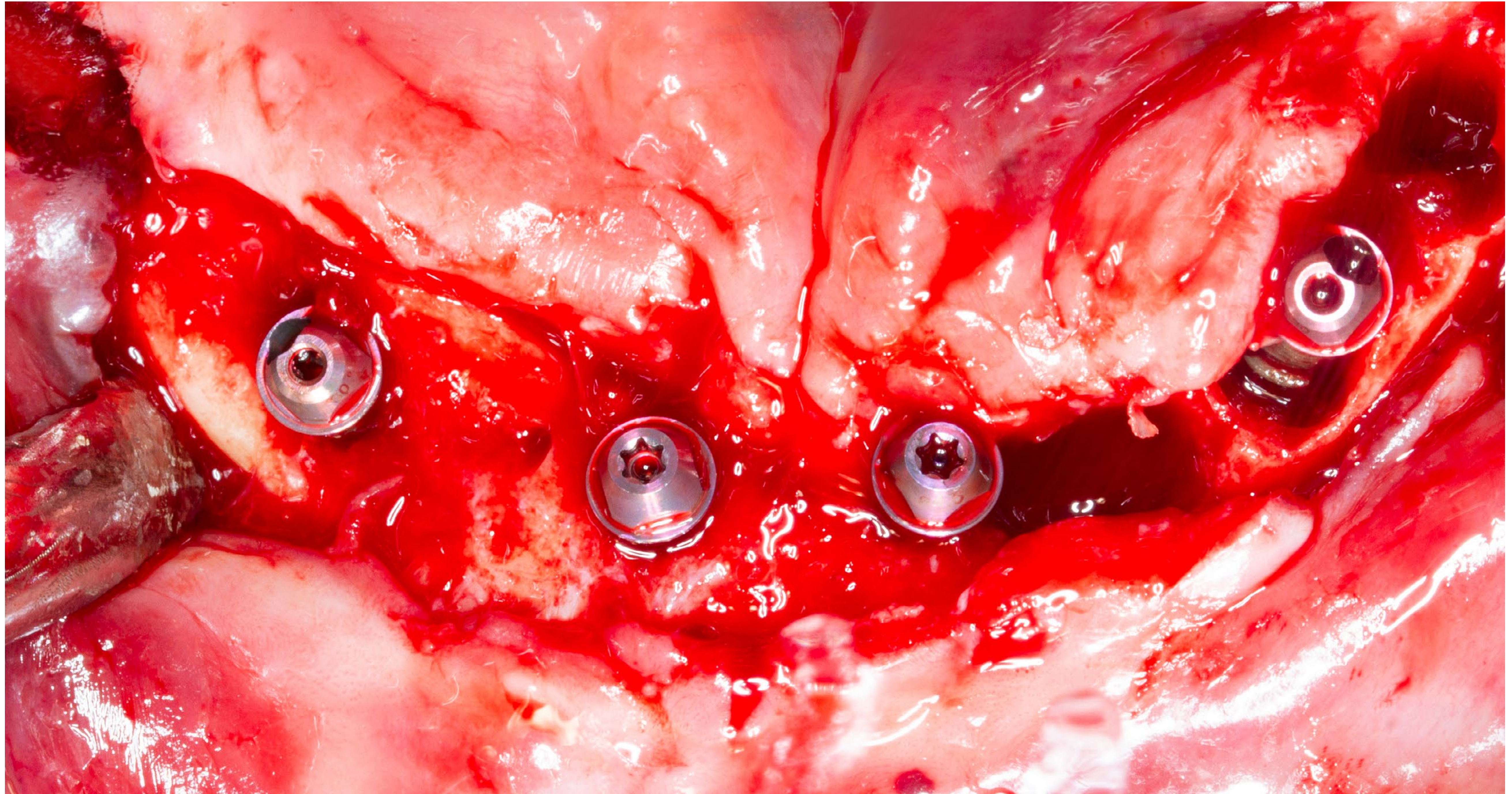


Panoramic postoperative radiograph with final hybrid resin prosthesis hand characterized restoration in place



# Challenge 6: Extraction sites and periapical cyst

General recommendations and clinical case from Dr. Inge de Latte





# Challenge 6: Extraction sites and periapical cyst

General recommendations



## General recommendations from Dr. Inge de Latte

- Use implants with wide threads for soft bone and medium bone
- Thorough removal of the cyst
- Curettage of the extraction sites
- Fill the sockets with bone grafting material

Has worked as a maxillofacial surgeon at the AZ St. Lucas Hospital in Ghent since 2005 in a team together with Dr. De Wolf, Dr. Panis and Dr. Van De Velde. Specialised in orthognathic surgery, bone augmentation and implant dentistry. Training in oral and maxillofacial surgery at the University of Leuven, the AZ St. Jan Hospital in Bruges and the Tygerberg Hospital in Cape Town. President of the local study club for maxillofacial surgery in East Flanders. Straumann Center of Advanced Education since 2019. Private practice in Ghent city center, Belgium.  
[www.mondenkaak.be](http://www.mondenkaak.be)



**Dr. Inge de Latte**  
MD, DDS  
Gent, Belgium

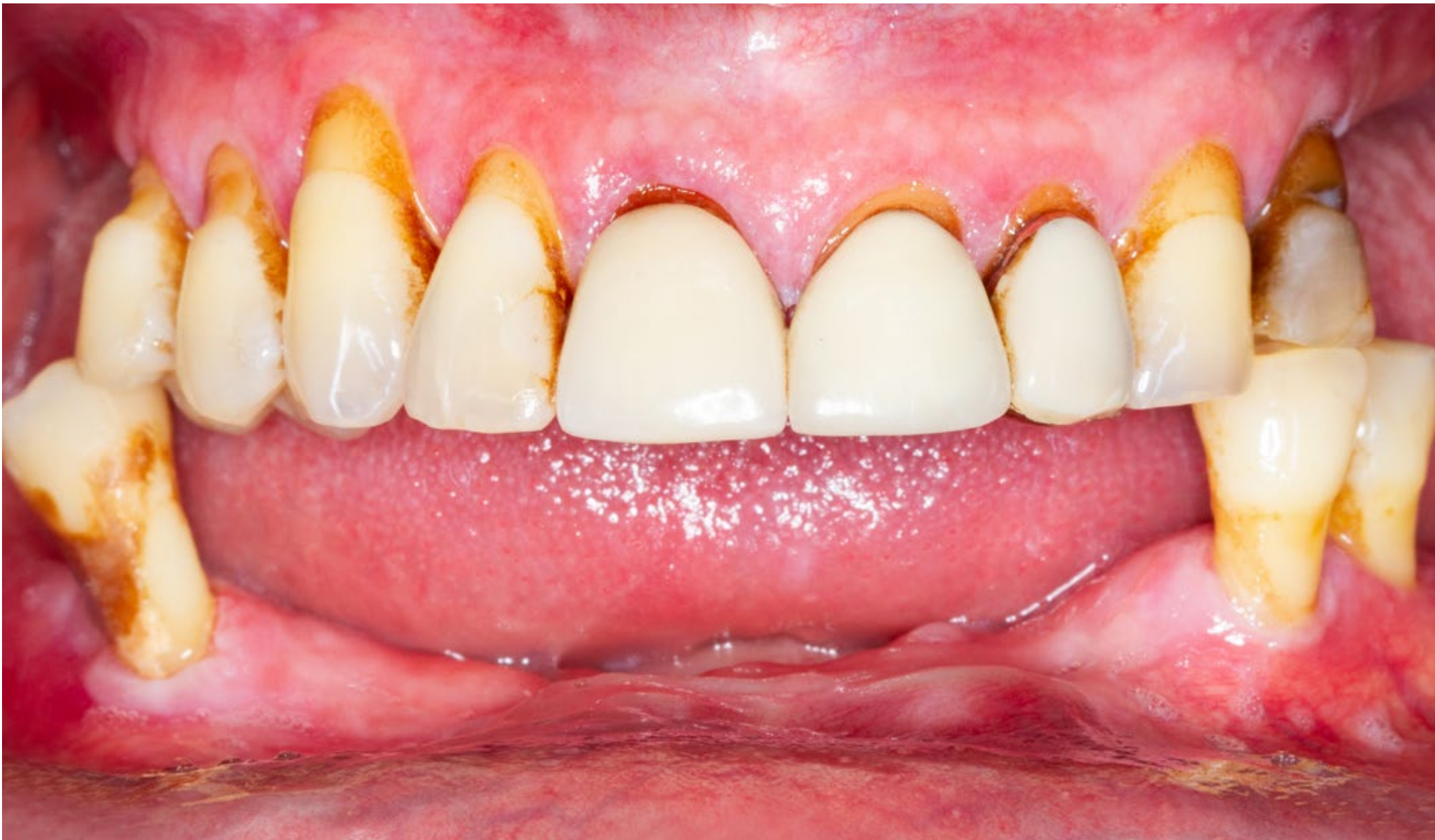

# Challenge 6: Extraction sites and periapical cyst

Clinical case



## Initial situation



## Patient information

Age	67
Jaw	Mandible
Health status	Hypertension & type 2 diabetes (both controlled)
Height of smile line	Low
Bone type	Medium
Infections at implantation site	No
Bone anatomy defects	No defects
Risks	Impaired wound healing

## Additional difficulties

Moderate resorption in the mandible
Reduced vertical dimension in the posterior region
Advanced chronic periodontitis
Periapical cyst and severe bone loss around the remaining teeth 33

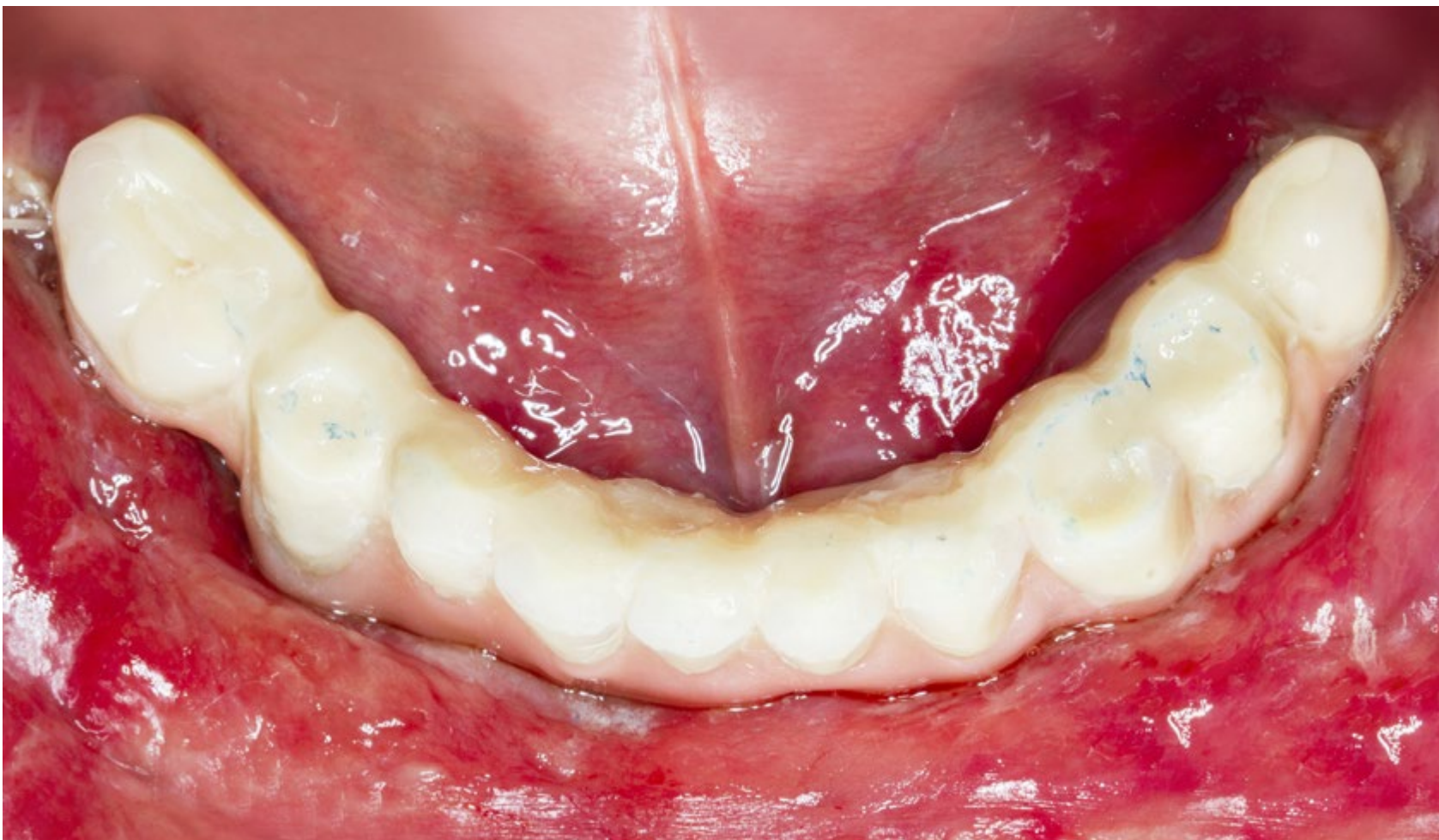

# Challenge 6: Extraction sites and periapical cyst

Clinical case



## Provisional prosthesis



## Treatment

- Fixed immediate rehabilitation on four implants
- Tilting of the posterior implants because of limited bone availability in the posterior region

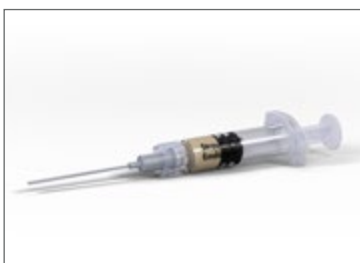**Temporary restoration:** acrylic provisional prosthesis

**Planned final prosthesis:** CrCo bridge

## Materials used



Straumann® BLX Ø 4.5 mm  
RB SLActive® 12 mm, Roxolid®



Straumann® Emdogain®



RB/WB Screw-retained Abutment, straight, angle 0°, Ø 4.6 mm, gingiva height 2.5 mm  
RB/WB Screw-retained Abutment, angle 30°, Ø 4.6 mm, gingiva height 3.5 mm



Jason® membrane



ceraBone® granules



# Challenge 6: Extraction sites and periapical cyst

Clinical case



## Our experience



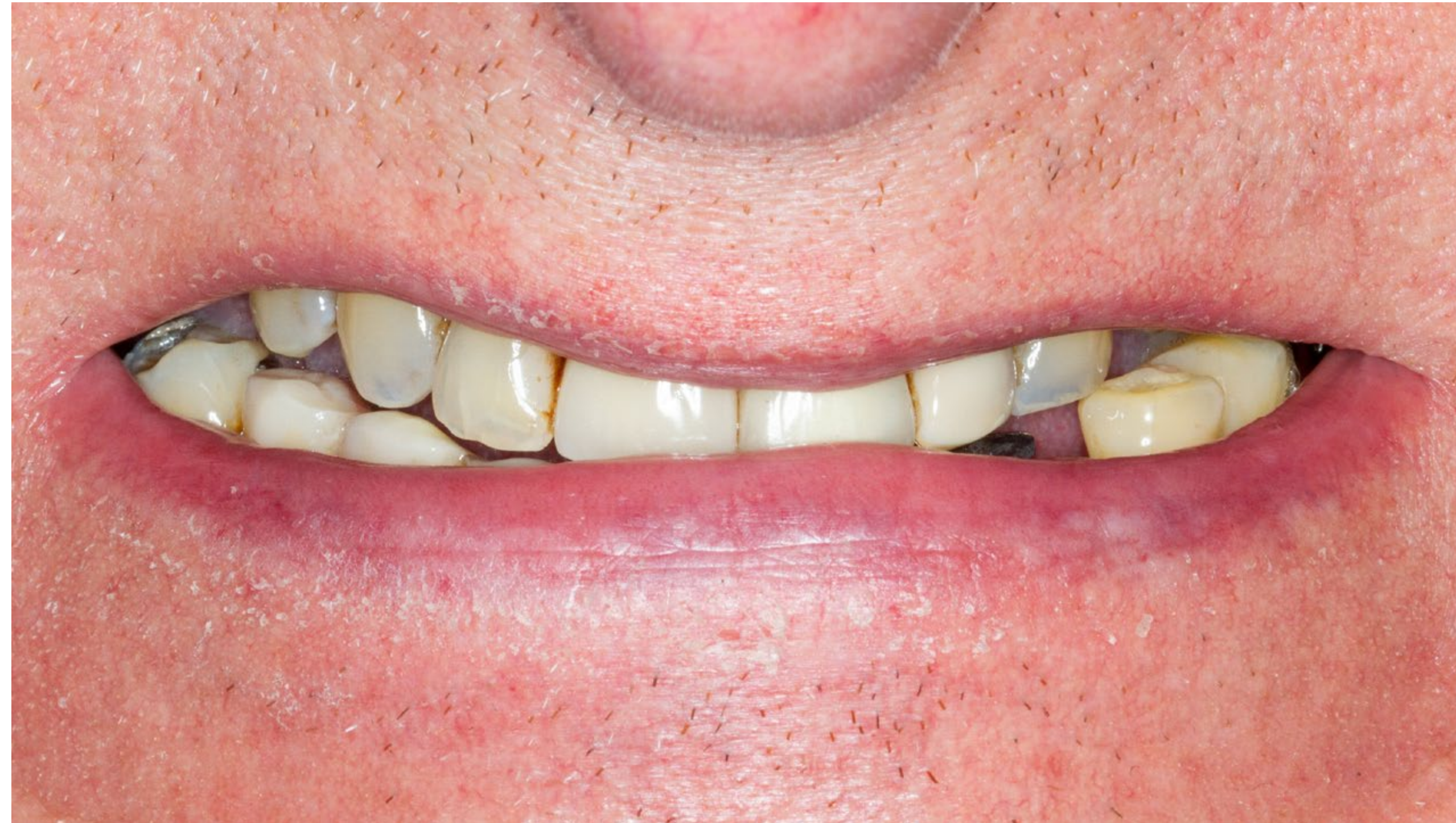Dr. Inge de Latte  
MD, DDS

*“We recently performed an exciting series of Pro Arch immediate loading cases (total of 40 implants) with the BLX implants. Even in cases of difficult extractions, atrophic jaws or patients with poor bone quality, we were able to load all implants. Due to its surface and shape, the BLX implant can transform a difficult case into an easy one. The implants are very well suited for the combination of immediate extraction sockets with immediate implant placement. In and around the extraction socket, it creates a stable, functional implant environment that enables immediate loading. The soft tissue can easily and rapidly grow around the implant surface, while maintaining the natural papilla and shape of the natural gingiva.”*

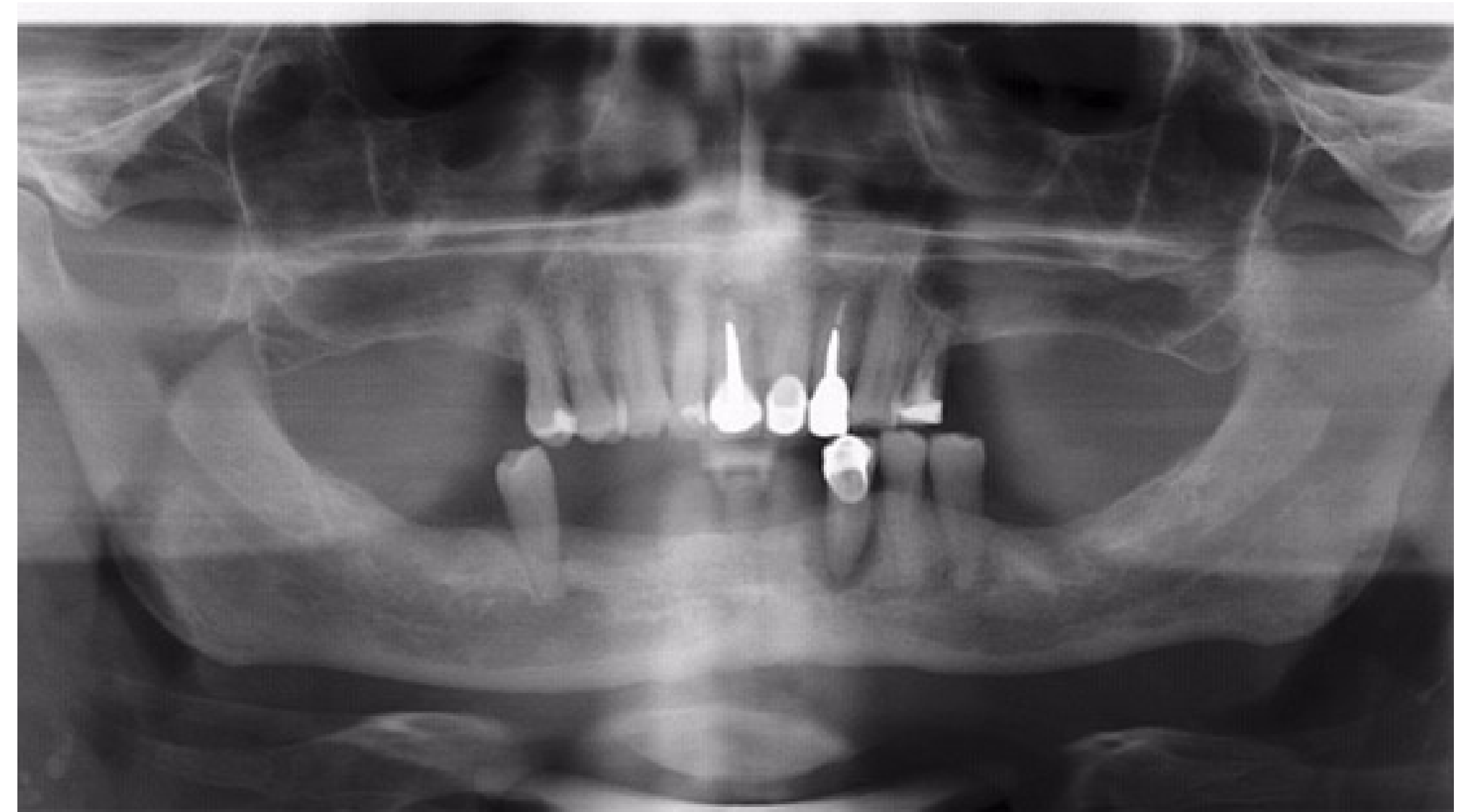

# Challenge 6: Extraction sites and periapical cyst

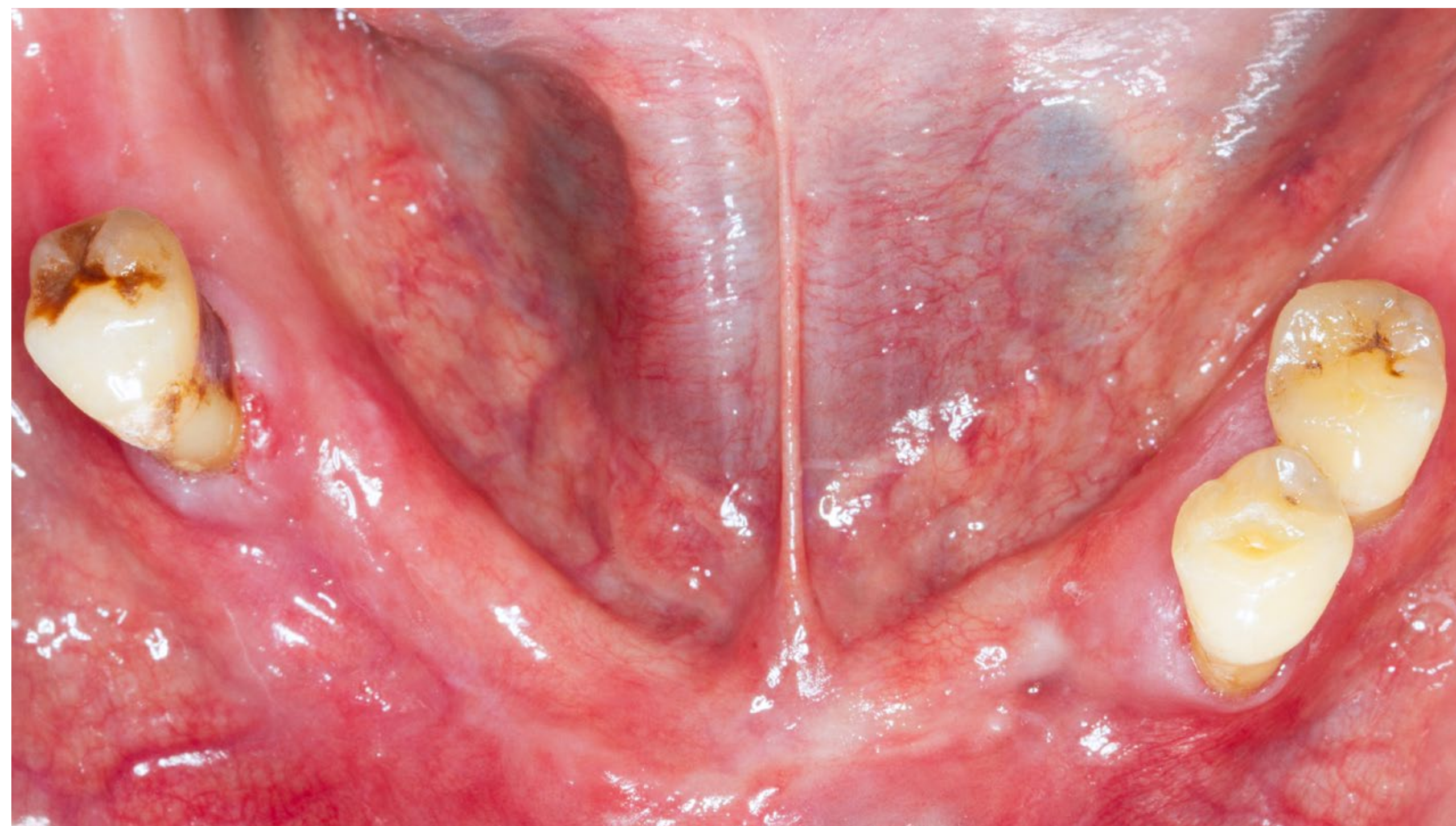
Clinical case



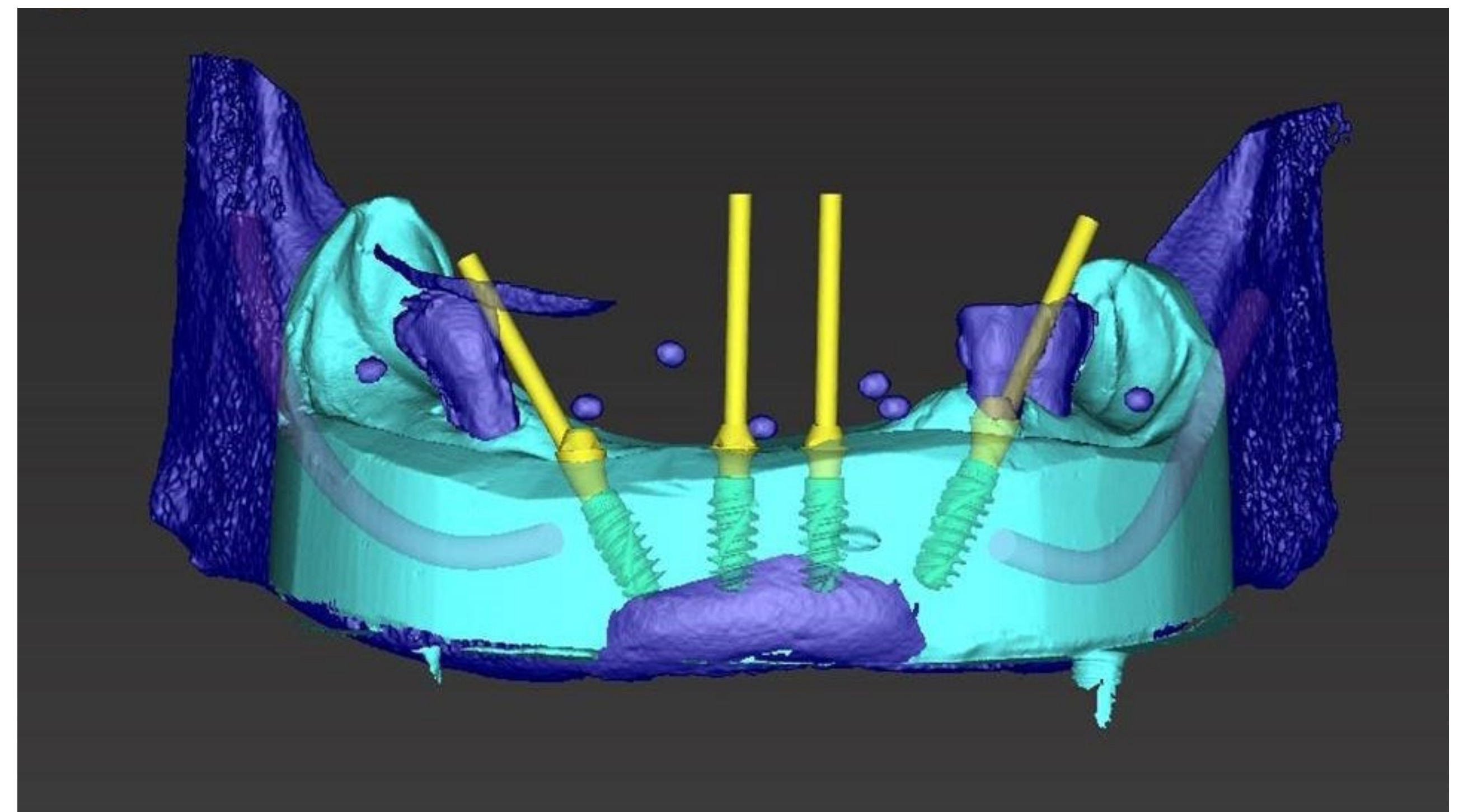
Initial clinical situation



Preoperative panoramic radiograph



Occlusal view

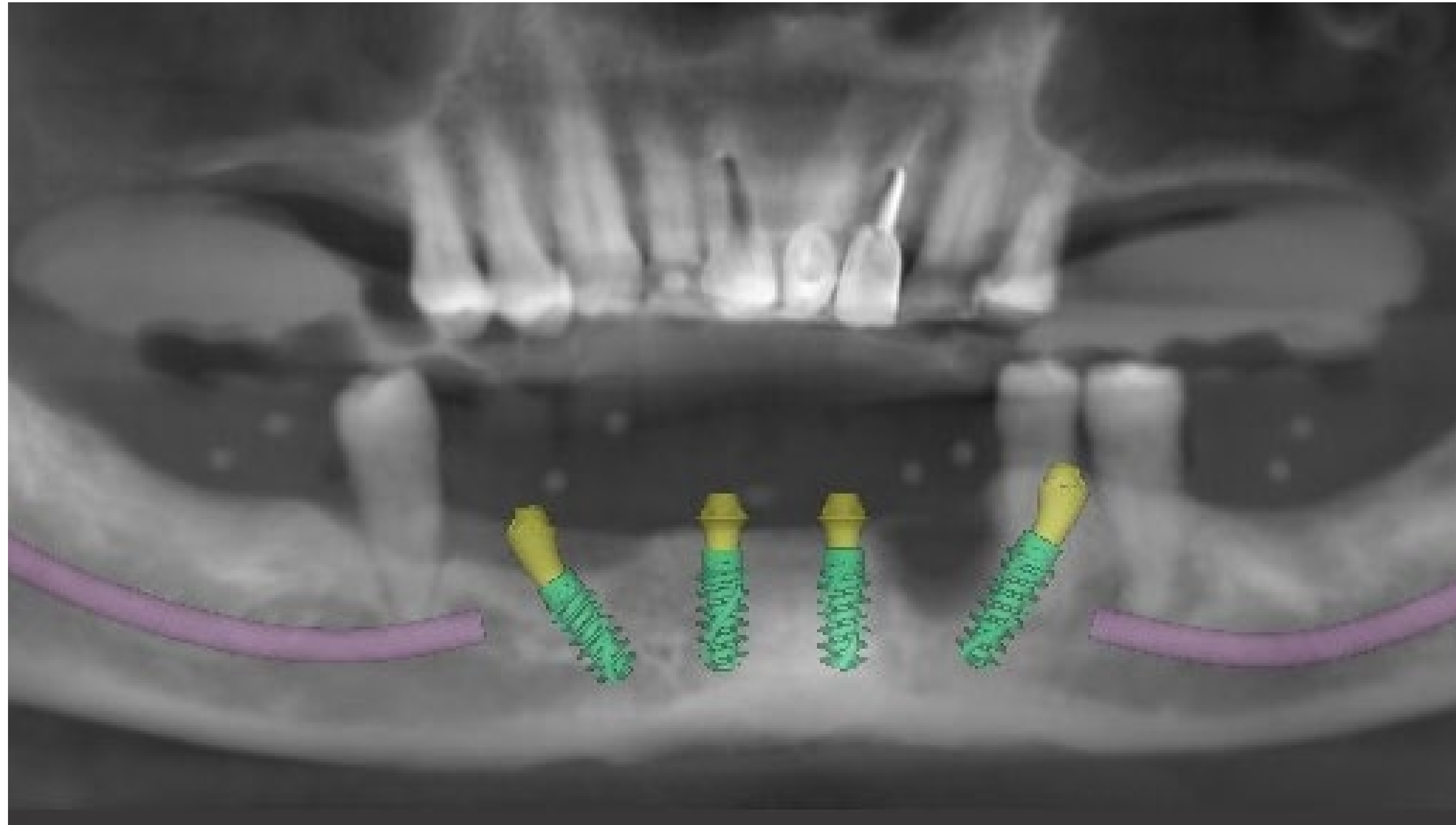


Treatment planning with coDiagnostiX®

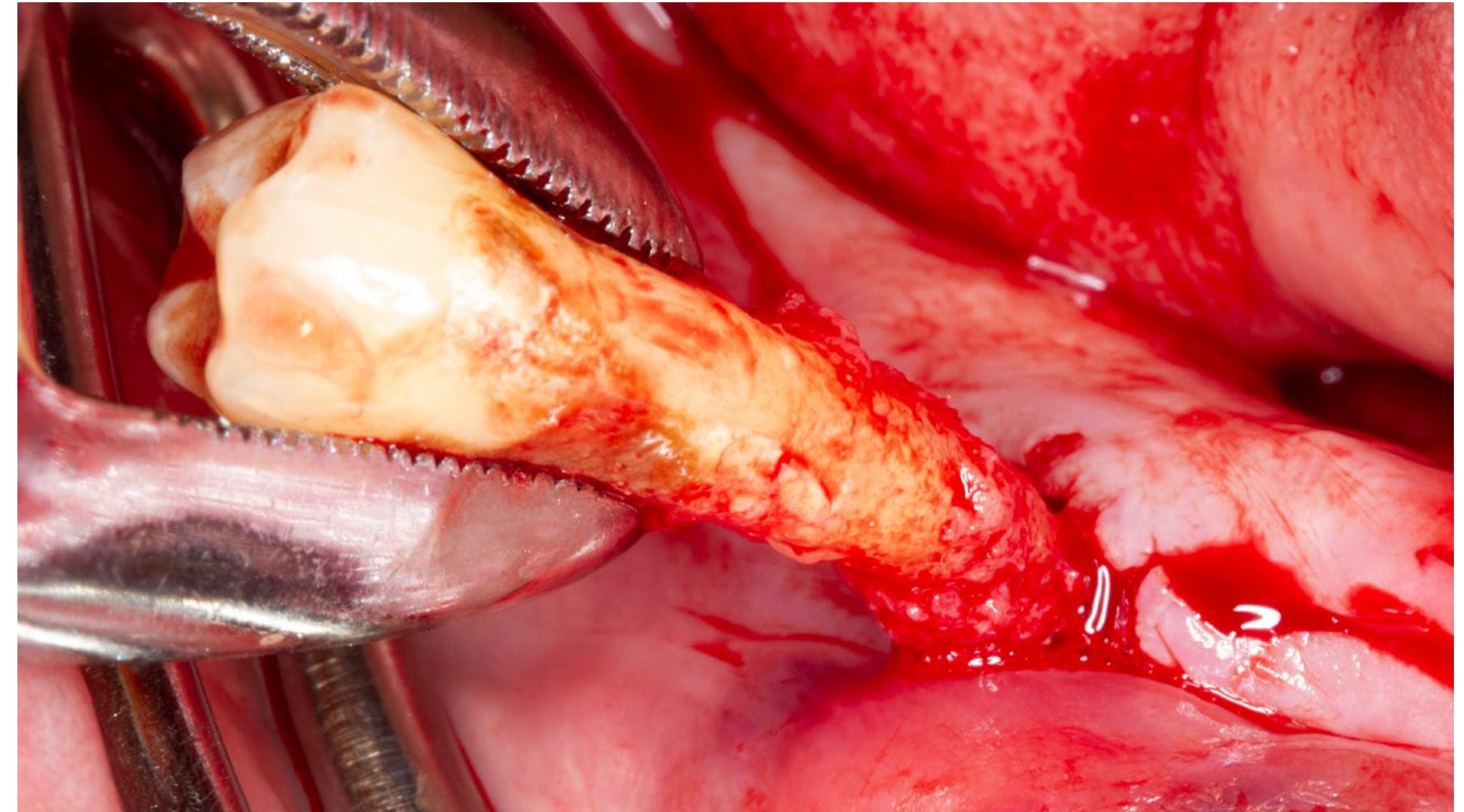


# Challenge 6: Extraction sites and periapical cyst

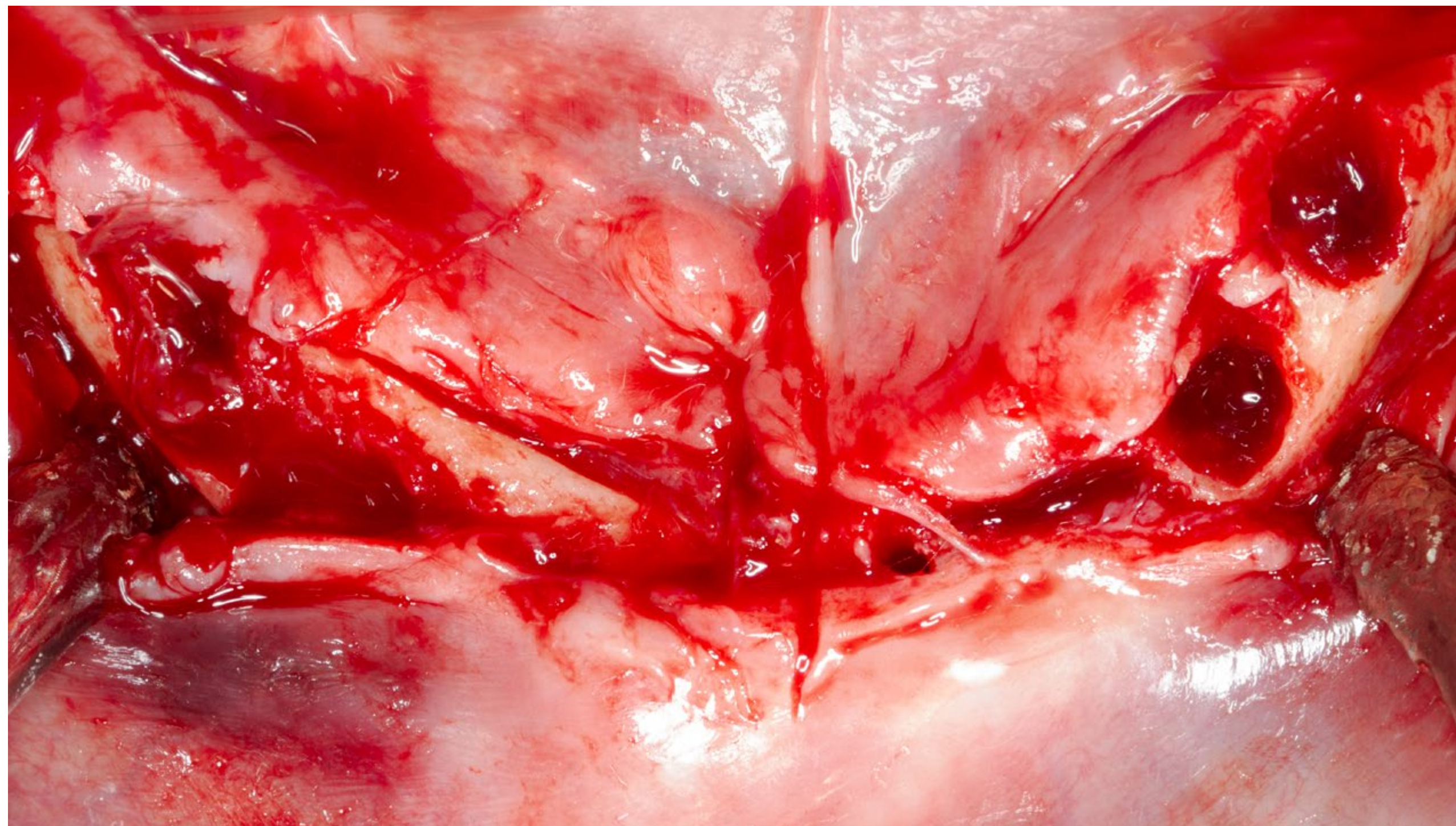
Clinical case



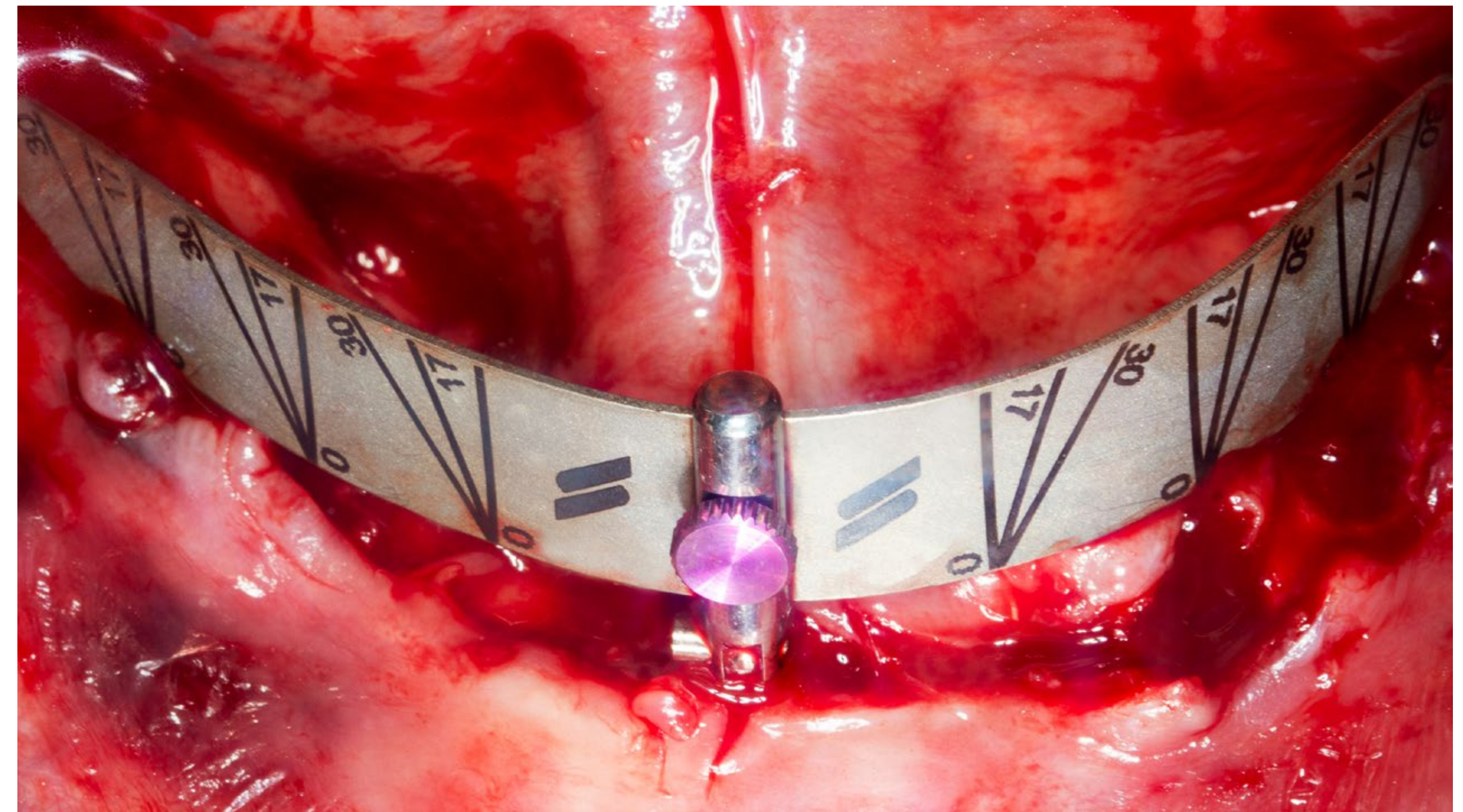
Treatment planning with coDiagnostiX®



Flap elevation and extraction of hopeless teeth



Occlusal view after flap elevation and extraction of hopeless teeth

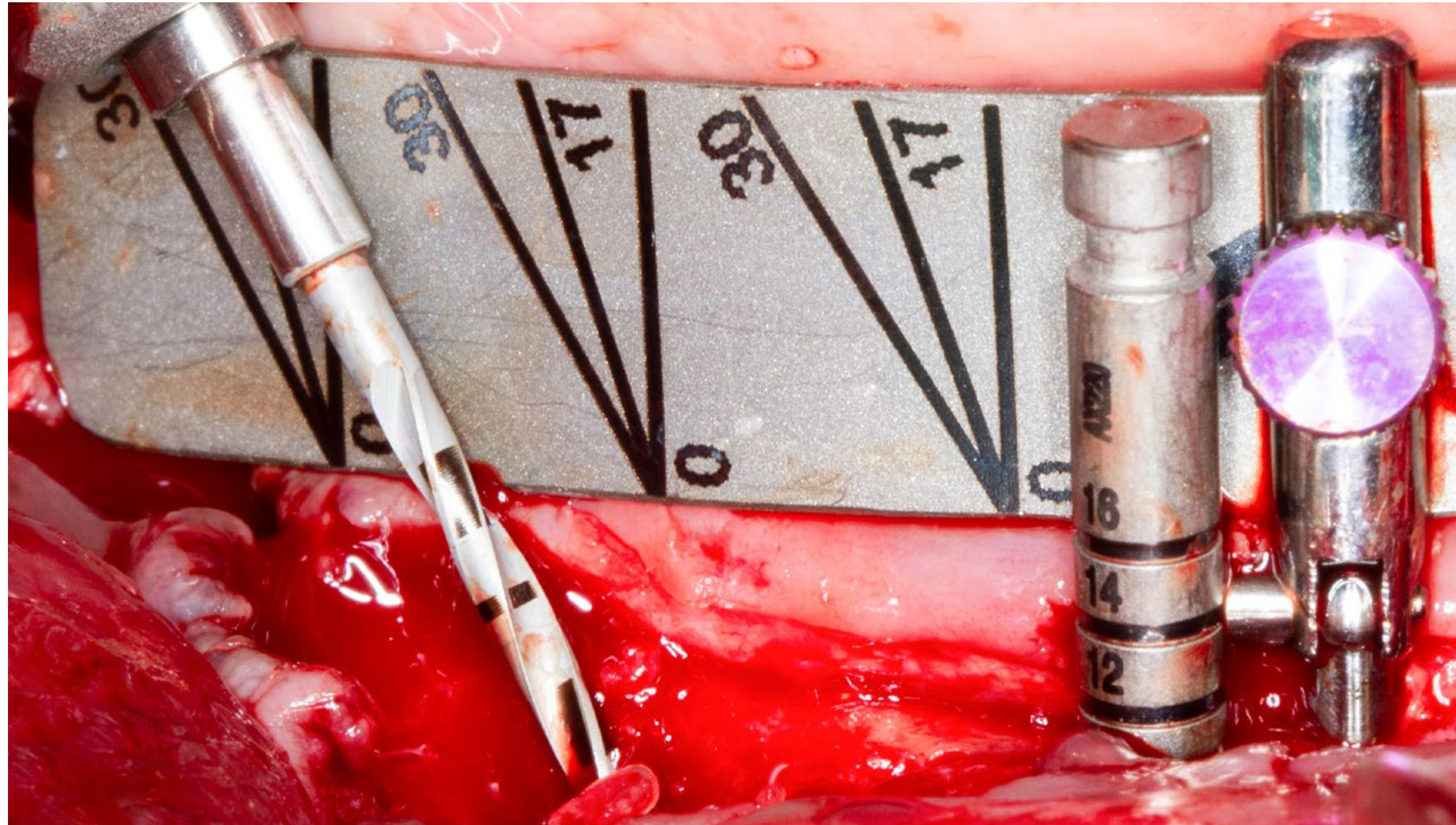


Straumann® Pro Arch Guide in place

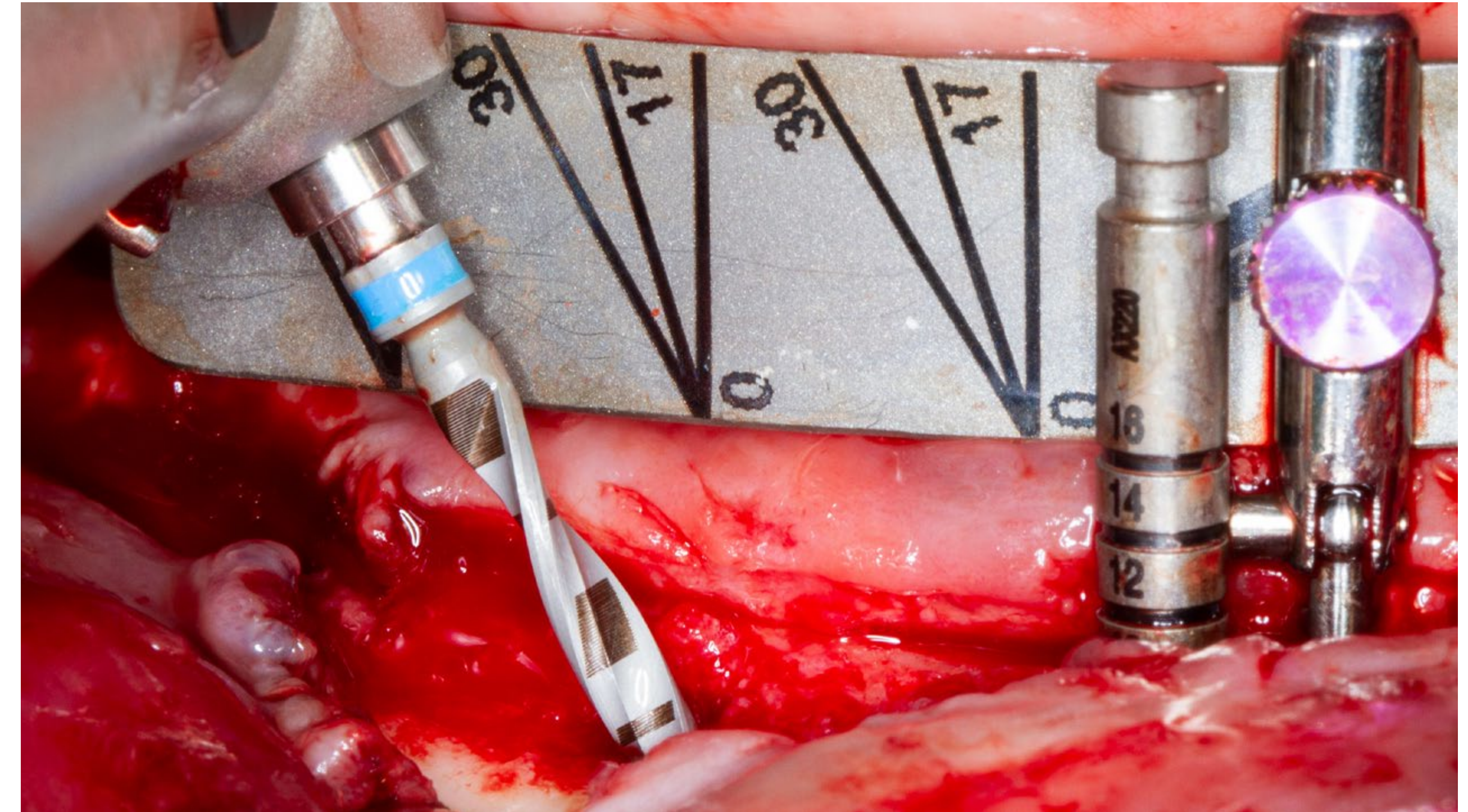


# Challenge 6: Extraction sites and periapical cyst

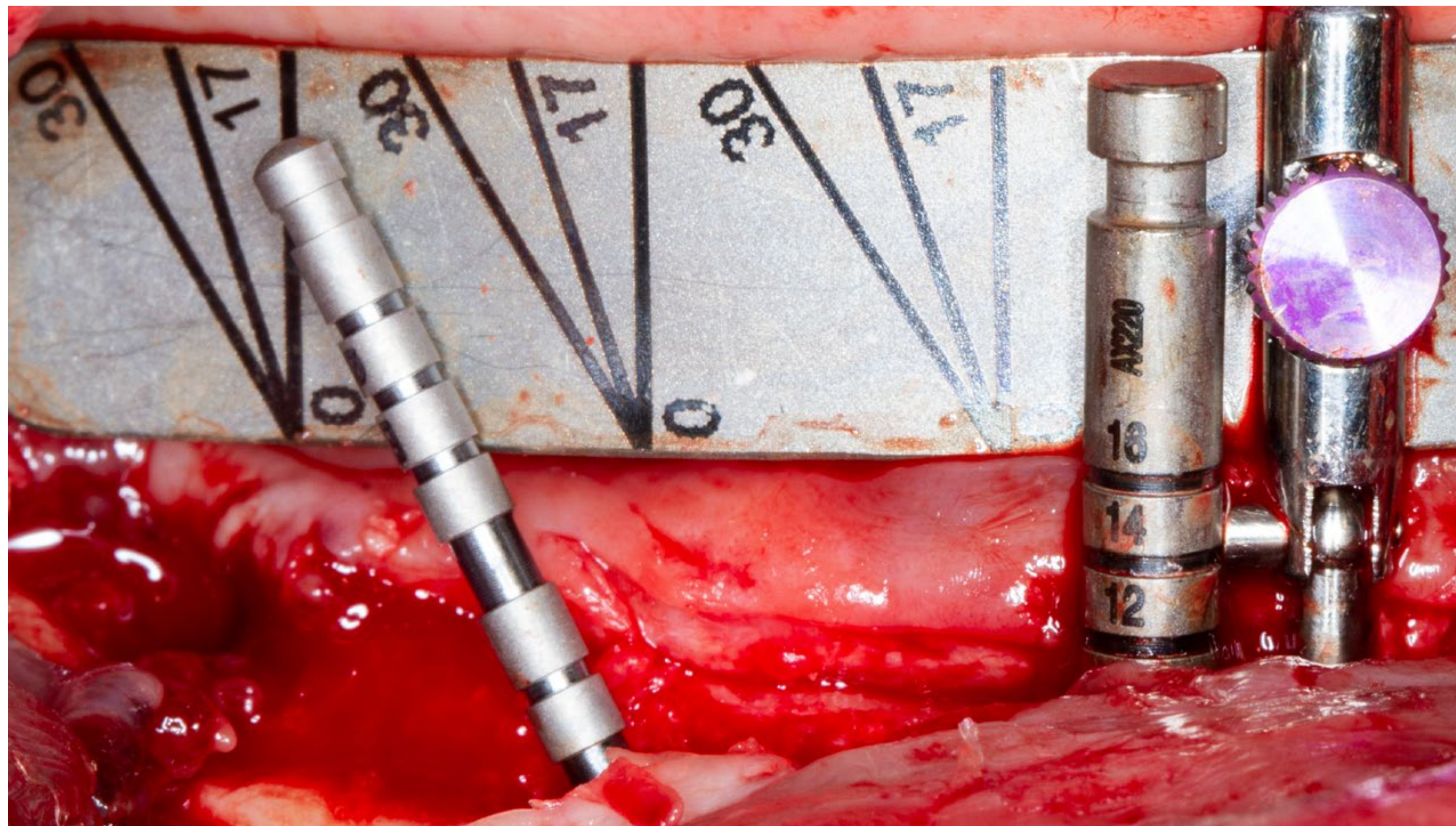Clinical case



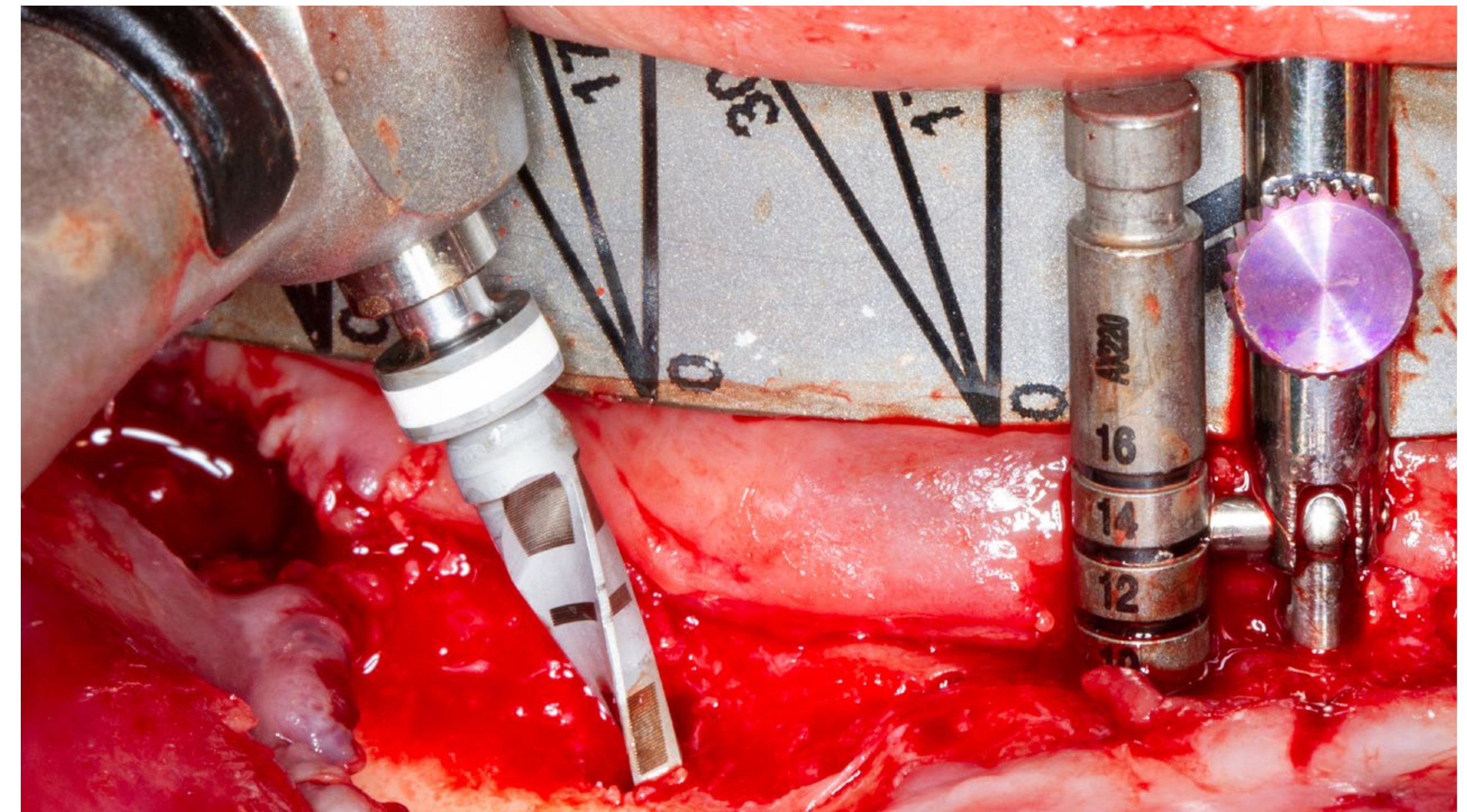
Angulation of the posterior implant to increase the A-P spread  
Preparation of posterior implant sites, Needle Drill Ø 1.6 mm



Preparation of posterior implant sites  
Pilot Drill Ø 2.2 mm



Preparation of posterior implant sites  
Alignment Pin Ø 2.2 mm

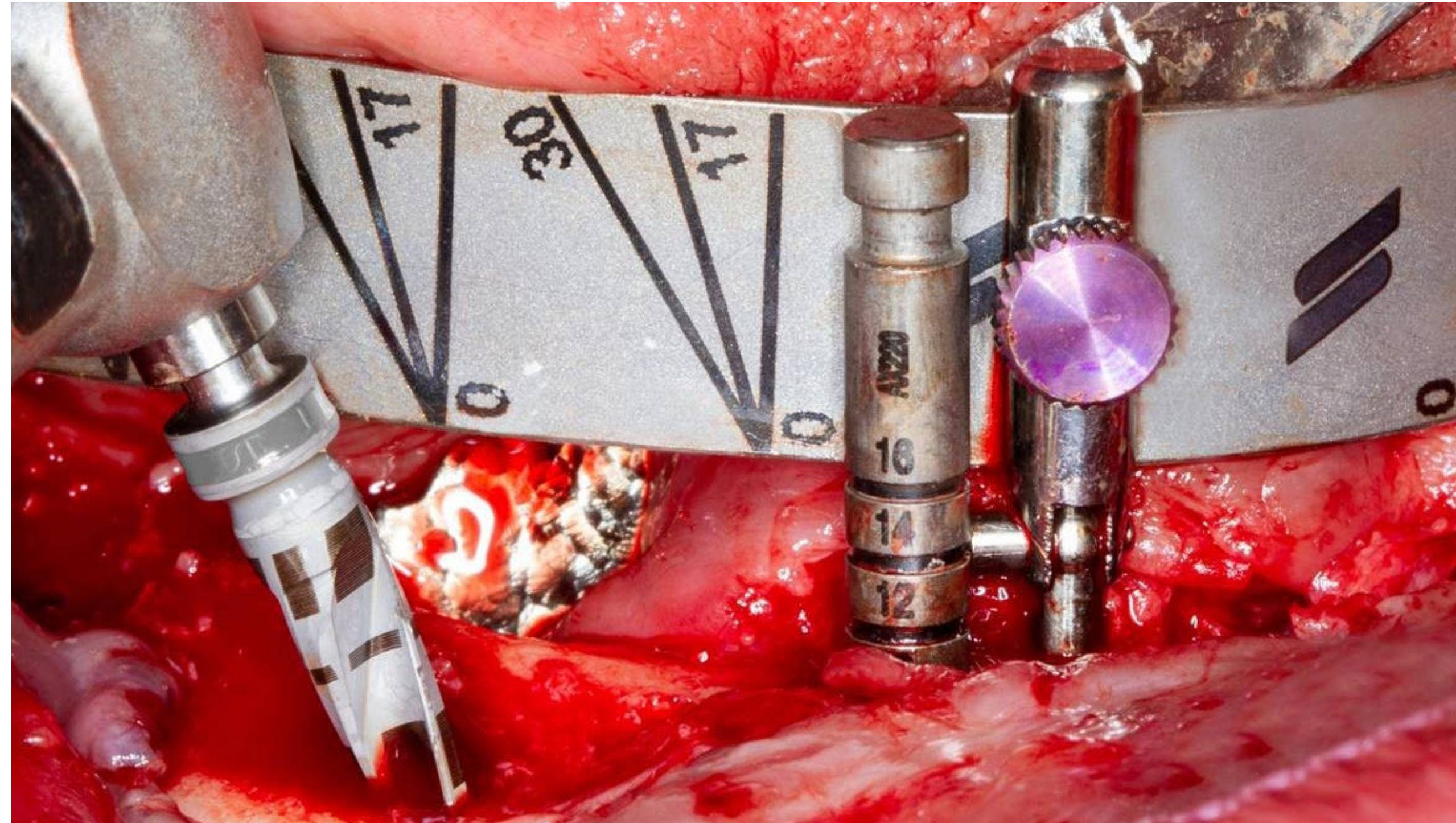


Preparation of posterior implant sites  
Alignment Pin Ø 3.2 mm

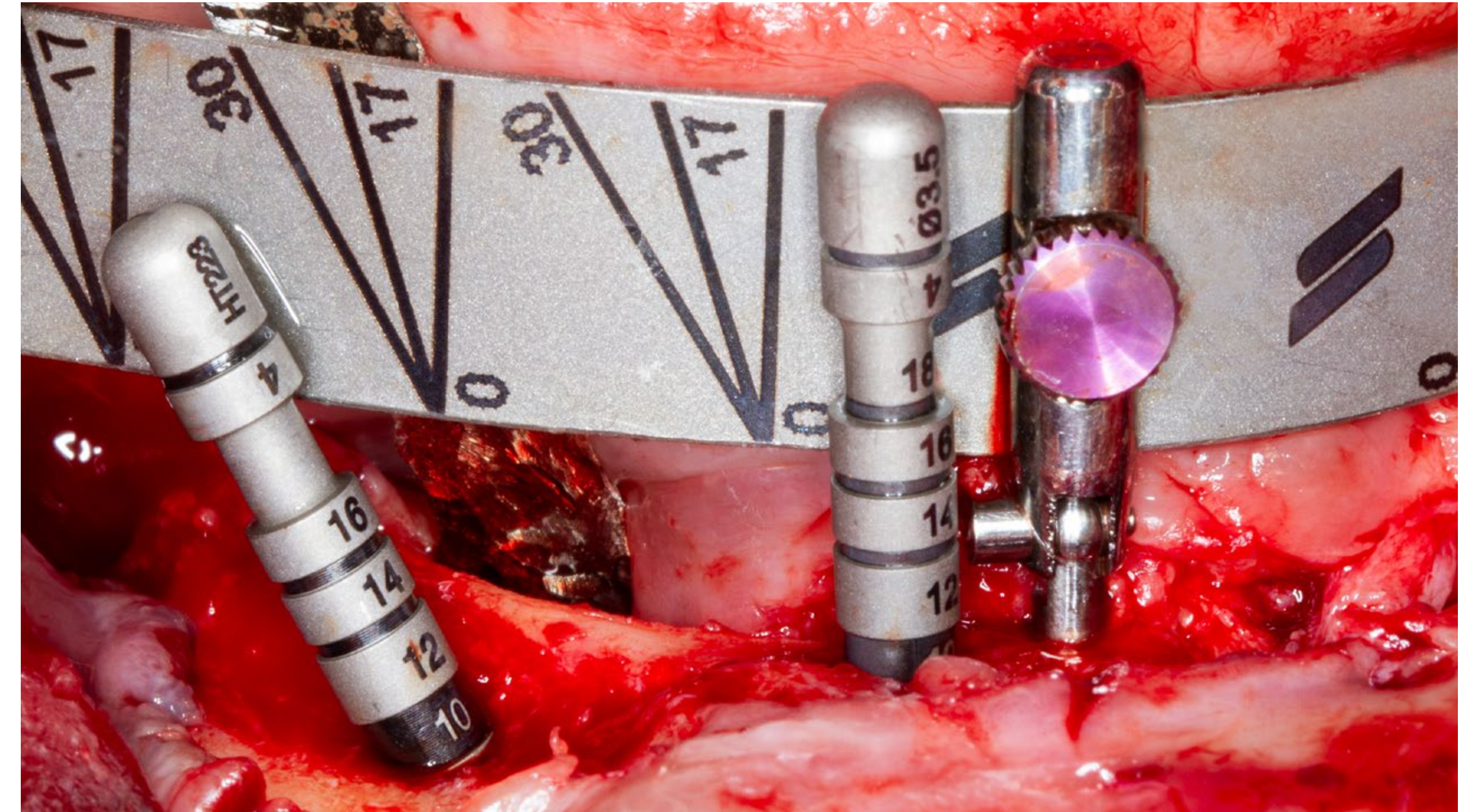


# Challenge 6: Extraction sites and periapical cyst

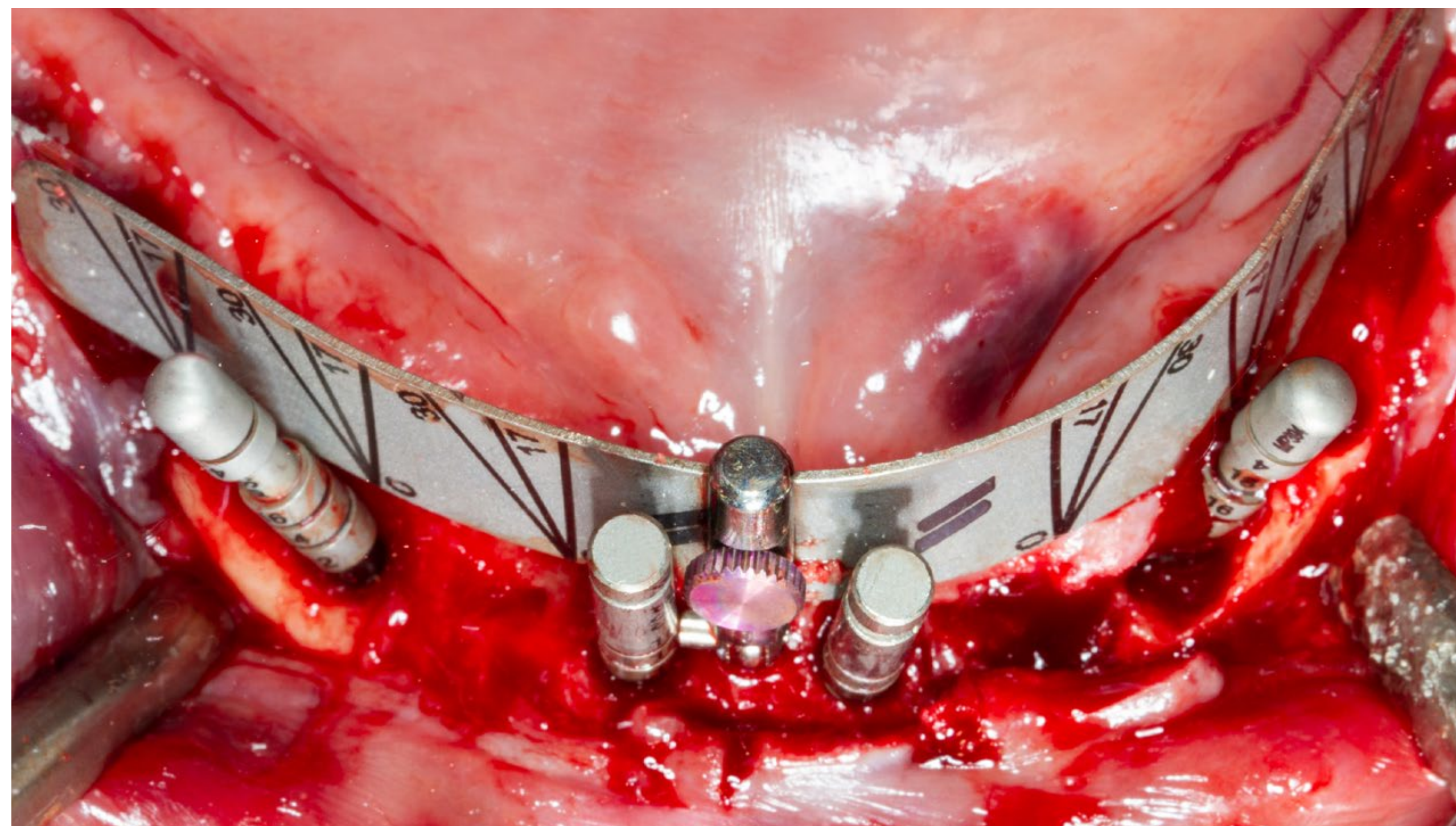
Clinical case



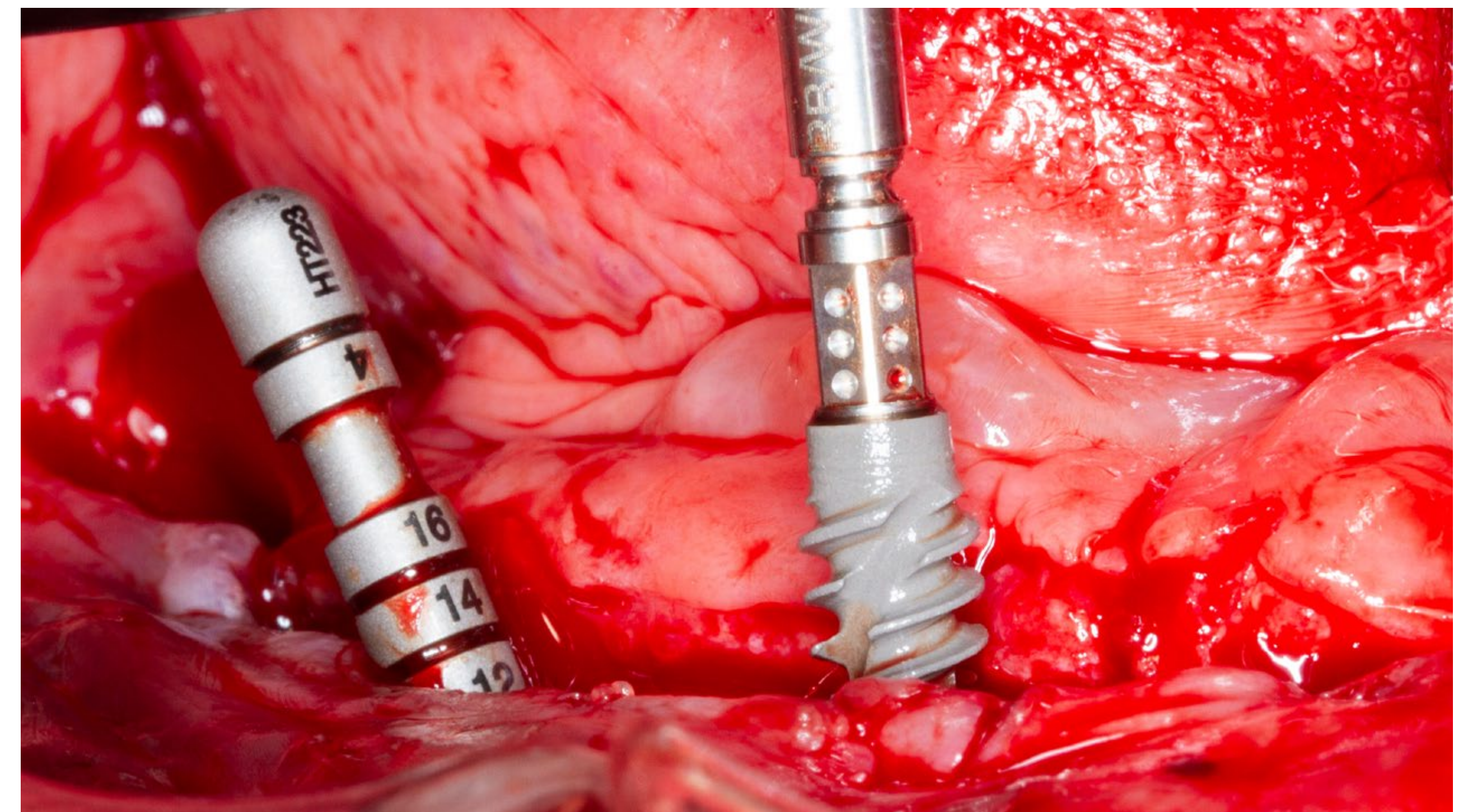
Preparation of posterior implant sites  
Alignment Pin  $\varnothing$  3.7 mm



Alignment of the implant sites



Alignment of the implant sites

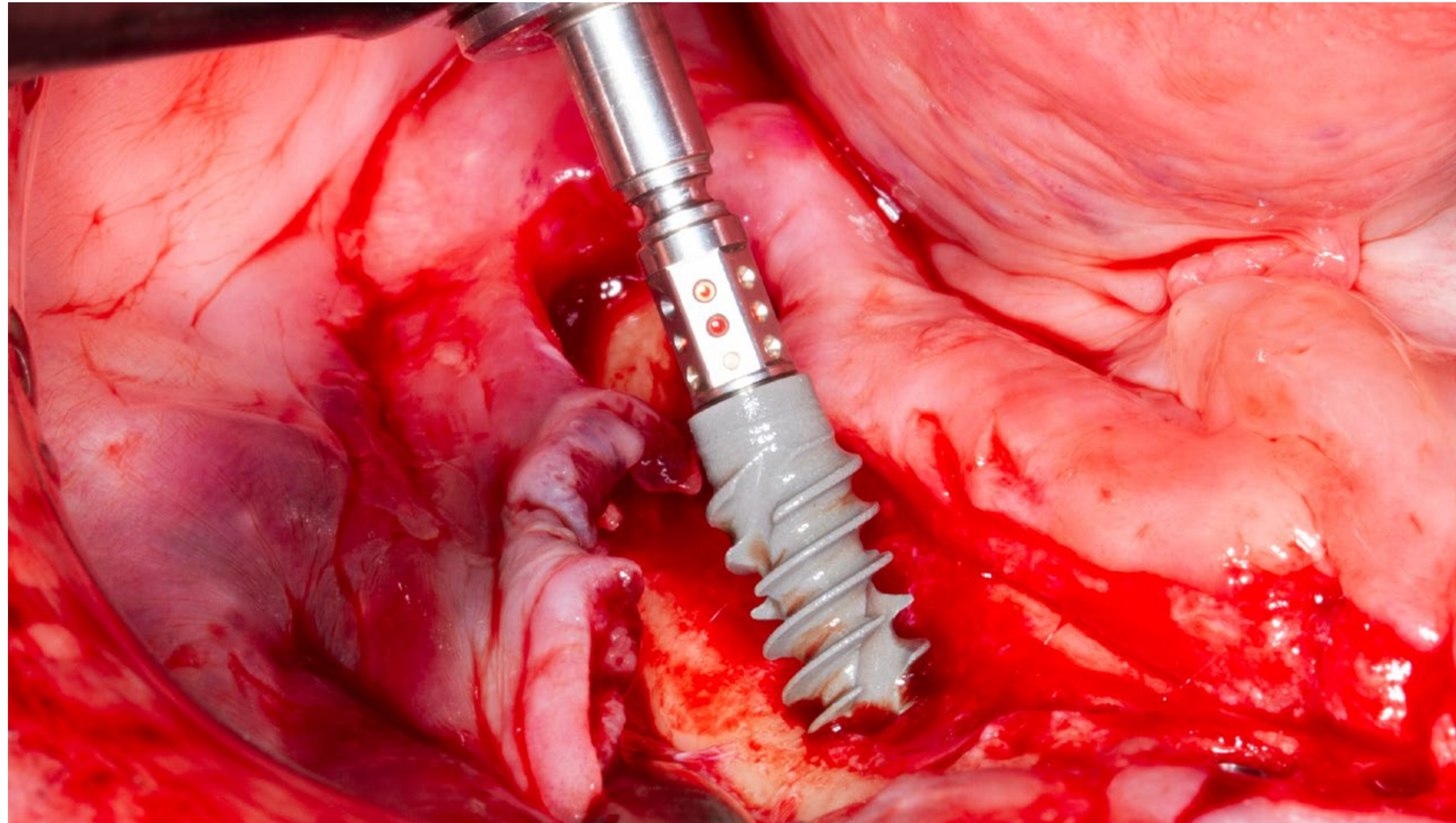


Placement of the Straumann® BLX  $\varnothing$  4.5 mm RB SLActive® 12 mm Roxolid® implant with a torque of 35 Ncm

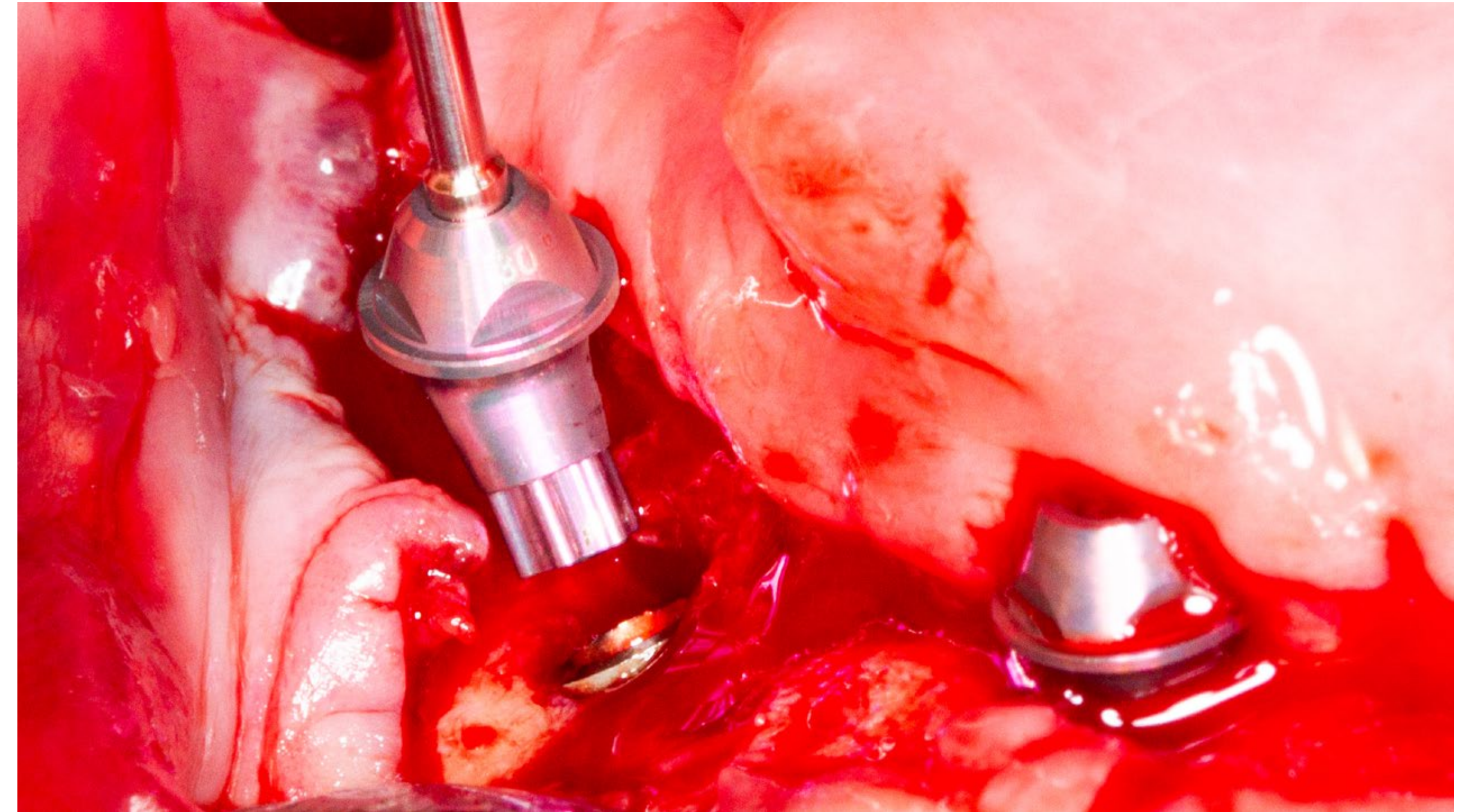


# Challenge 6: Extraction sites and periapical cyst

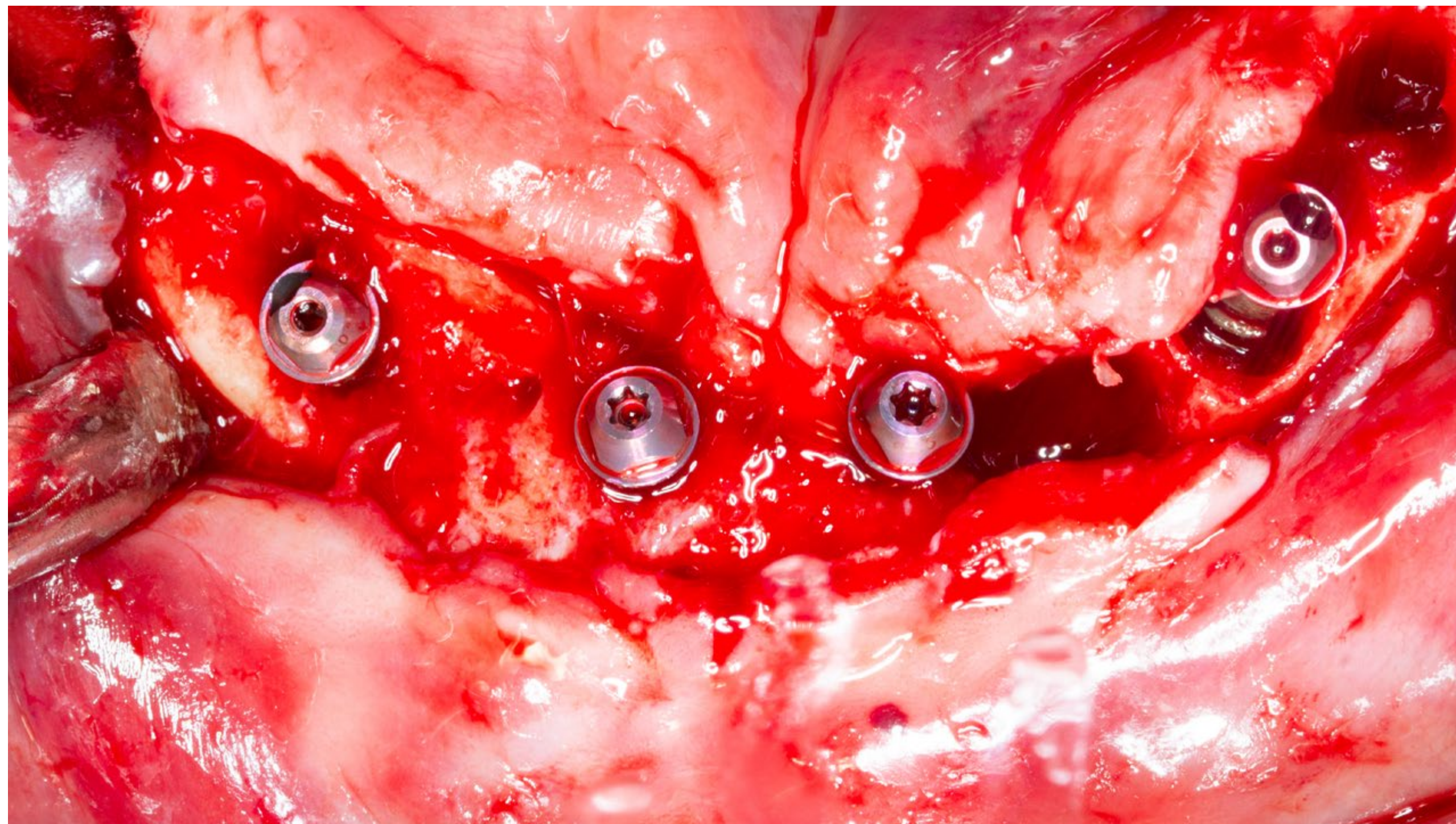
Clinical case



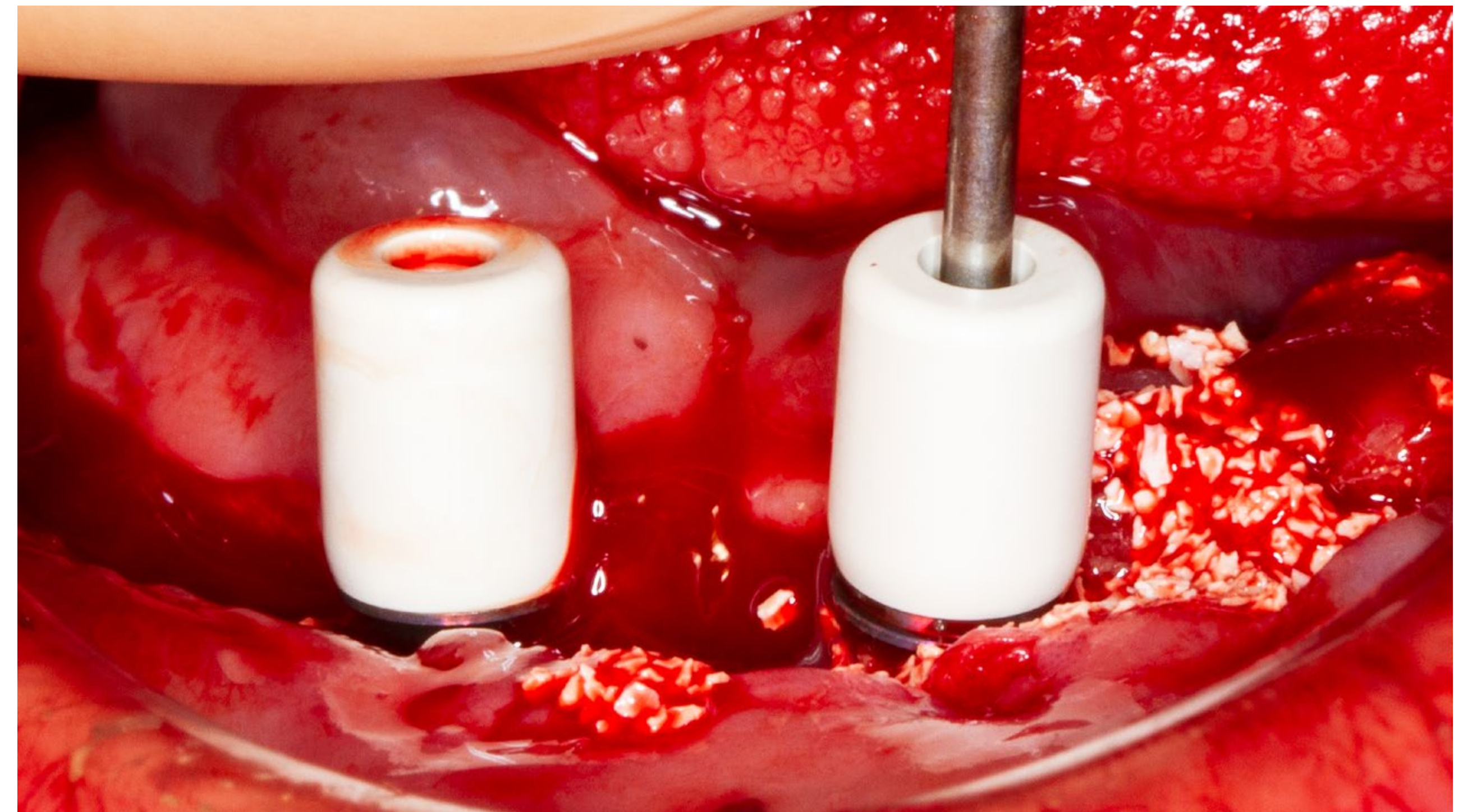
Placement of the Straumann® BLX Ø 4.5 mm RB SLActive® 12 mm Roxolid® implant with a torque of 35 Ncm



Placement of the Screw-retained Abutments



Screw-retained Abutments in place

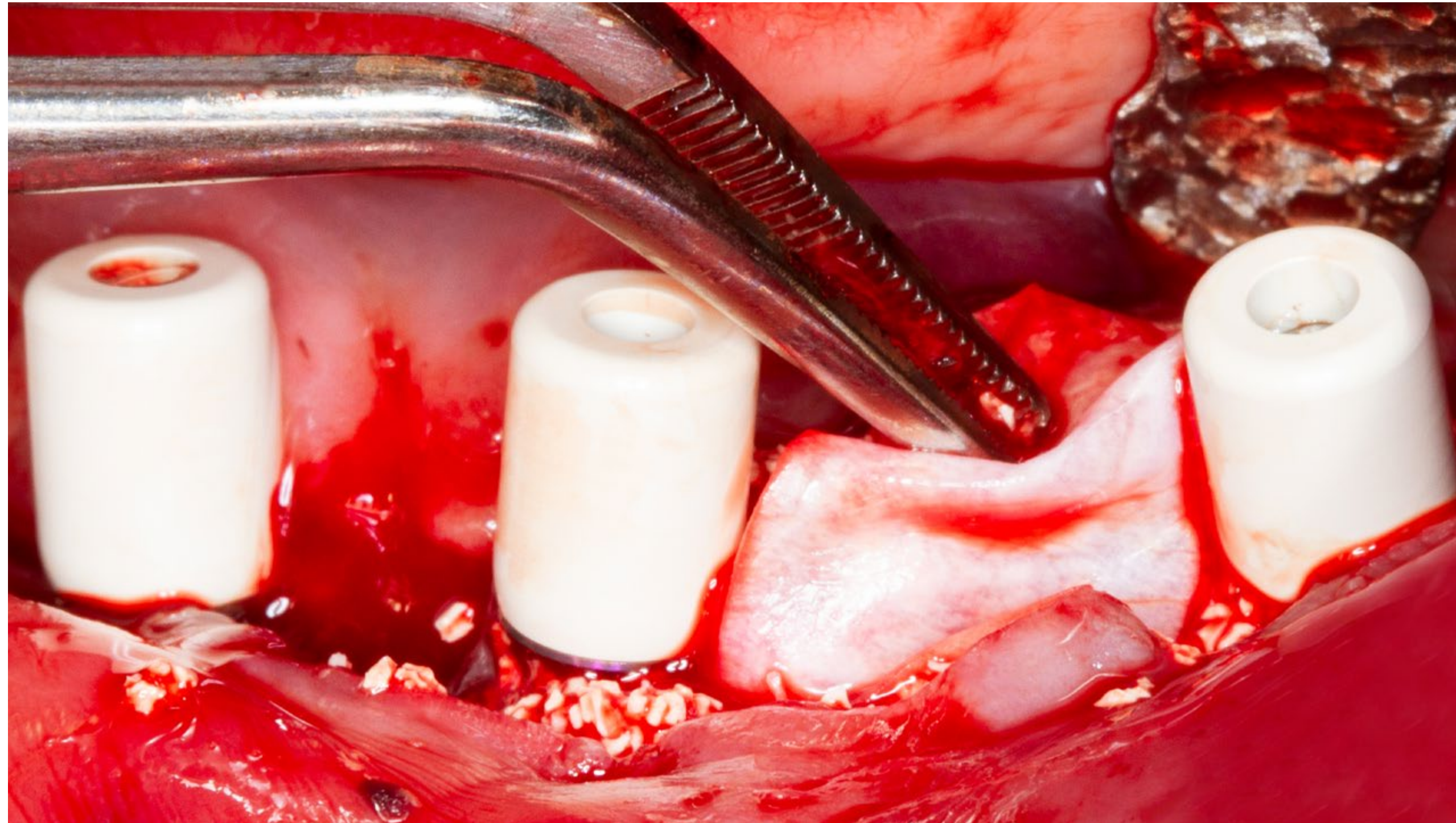


Placement of Protective Caps Ø 4.6 mm, cerabone® granules

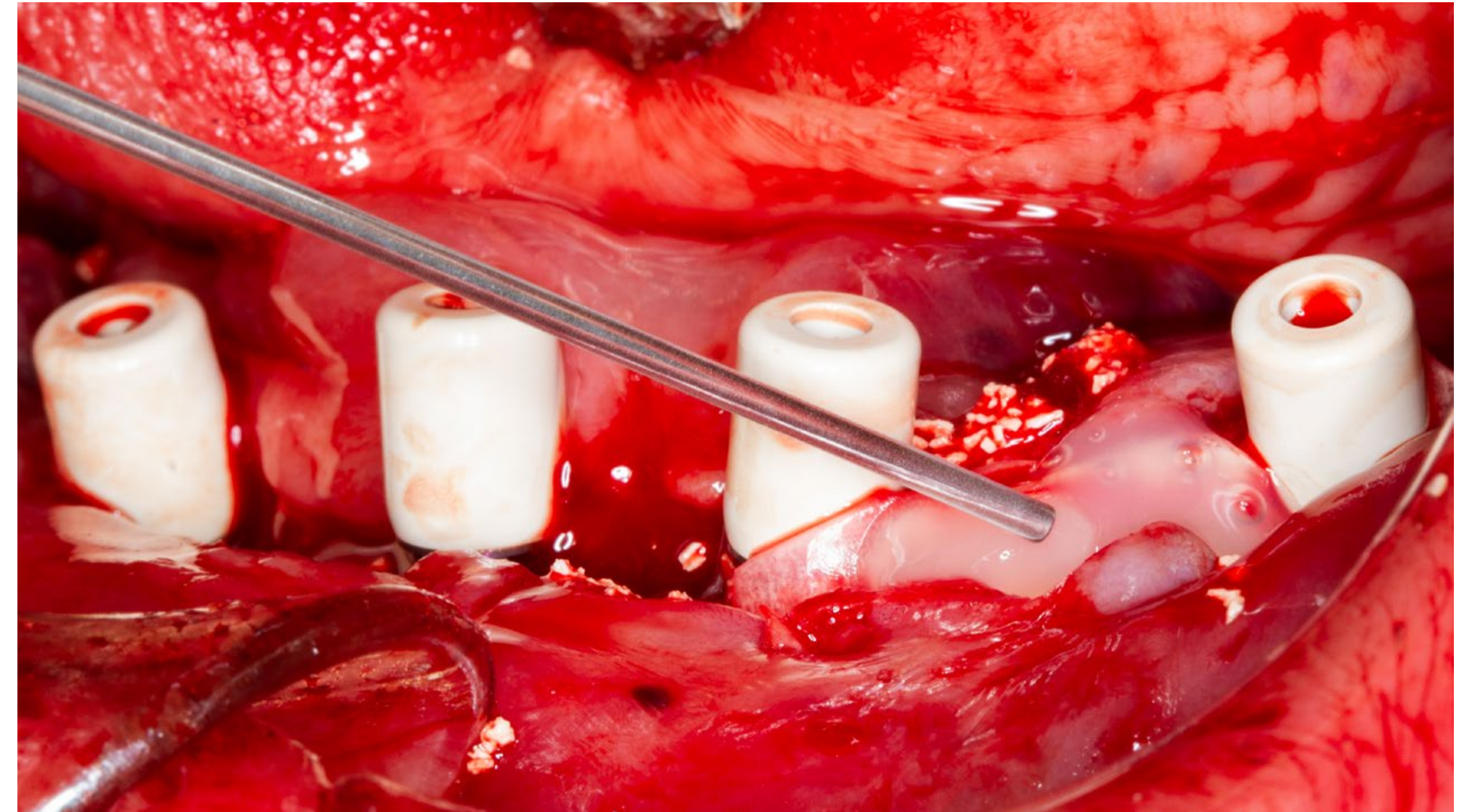


# Challenge 6: Extraction sites and periapical cyst

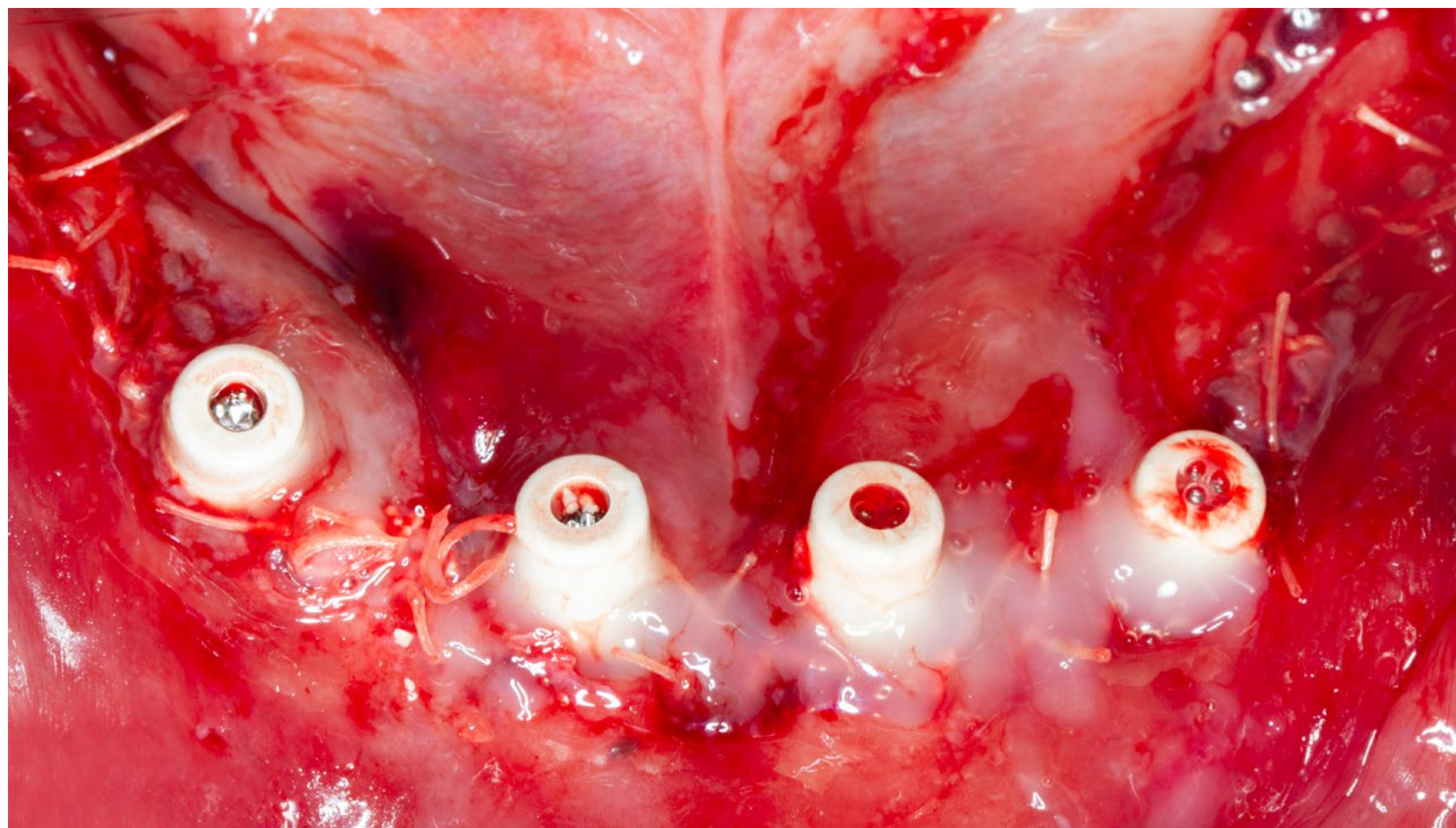
Clinical case



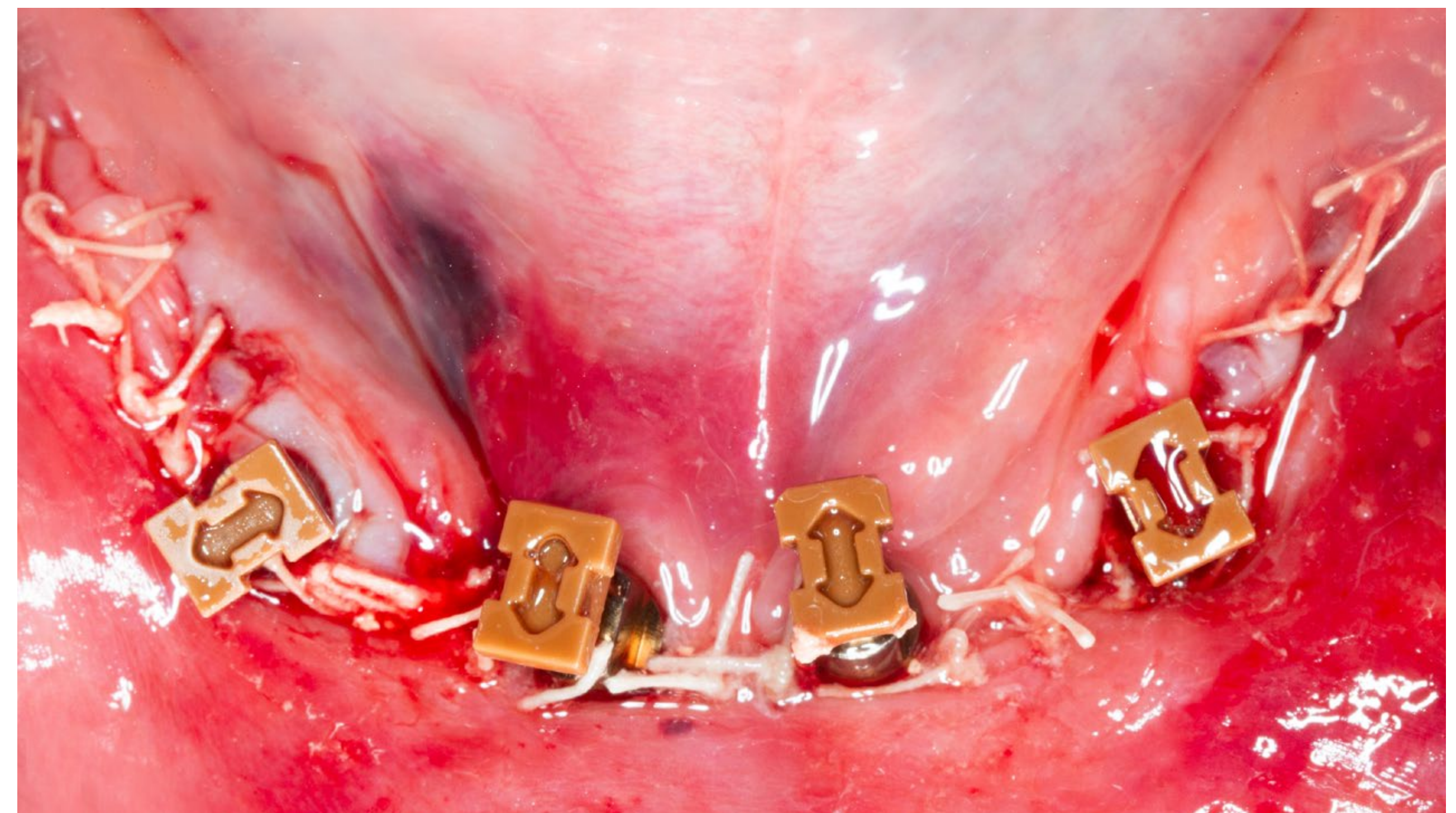
Placement of the cerabone® granules and Jason® membrane



Straumann® Emdogain® around implants



Suture and placement of Straumann® Emdogain® after flap closure

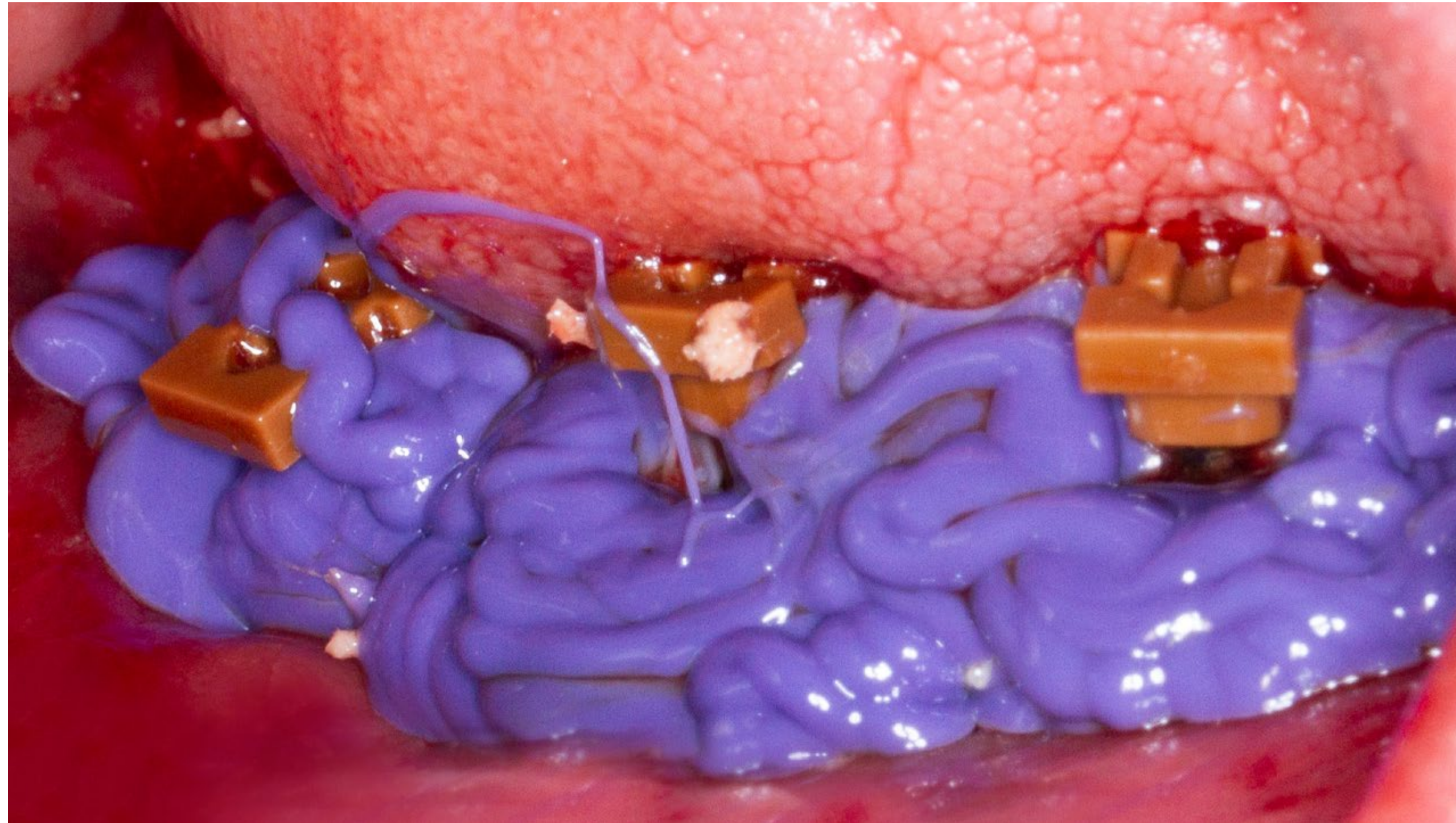


Impression taking with closed-tray technique

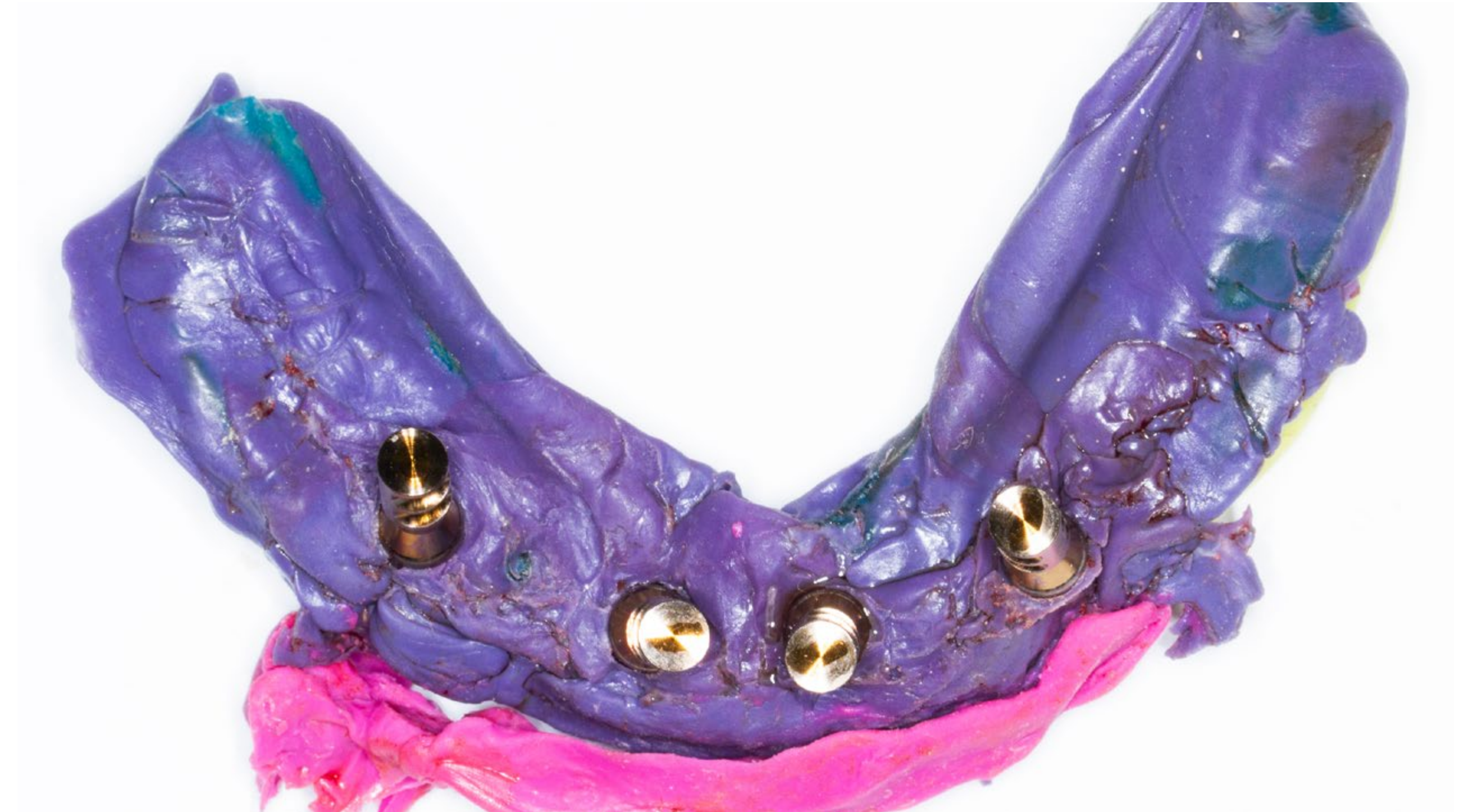

# Challenge 6: Extraction sites and periapical cyst

Clinical case



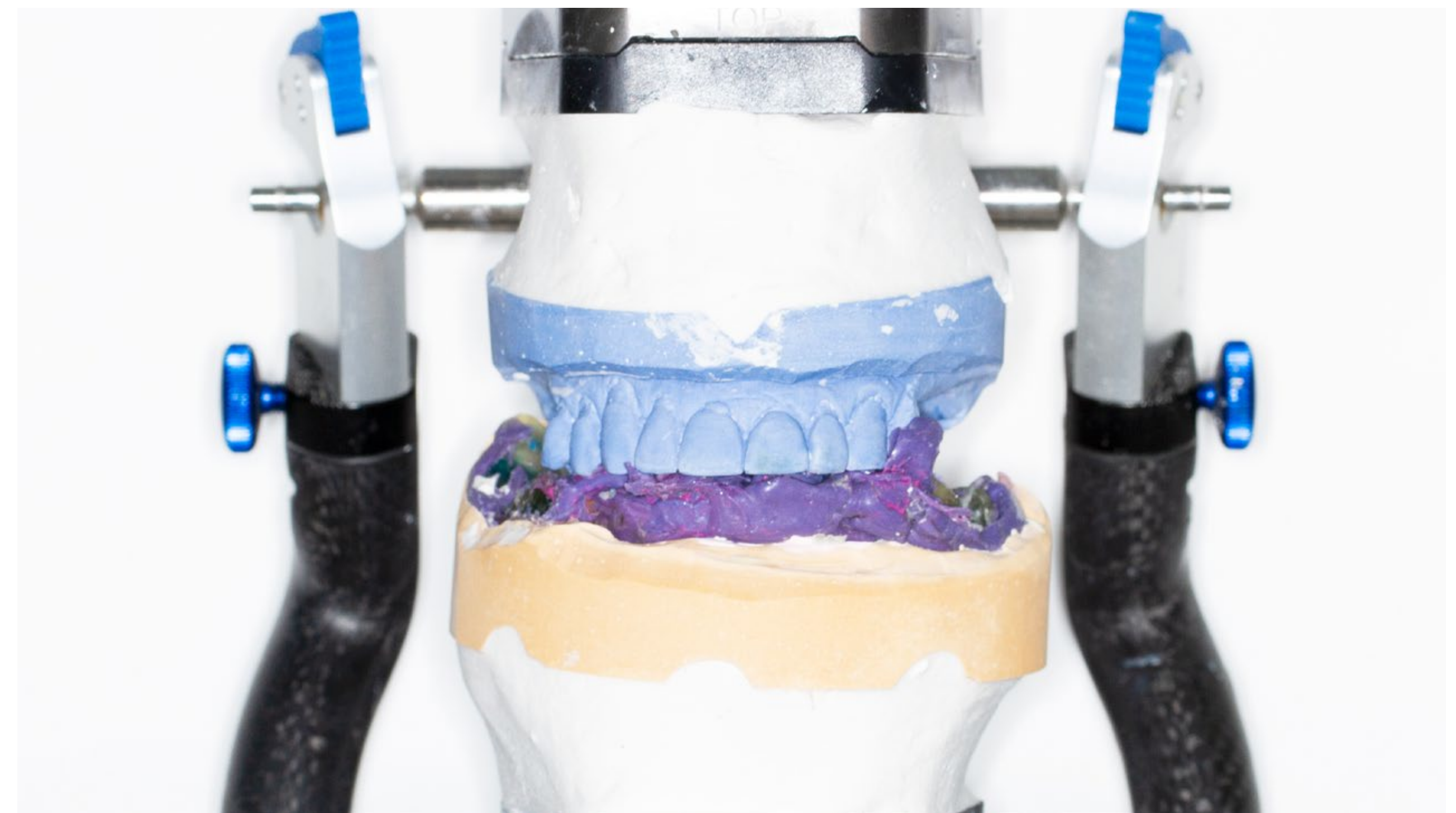Impression taking with closed-tray technique



Impression taking with closed-tray technique



Preparation of the cast

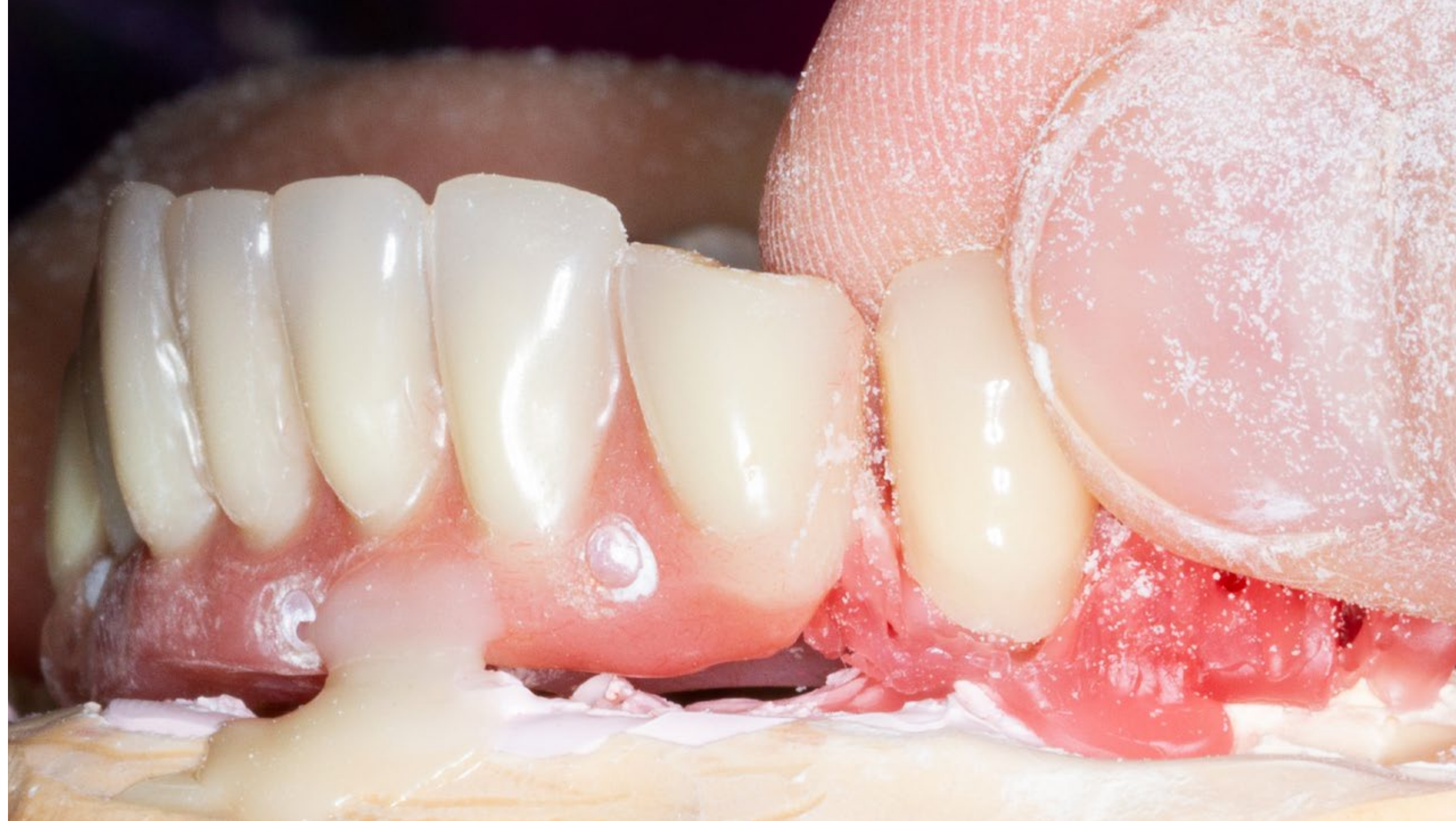

Placement of the casts in the articulator

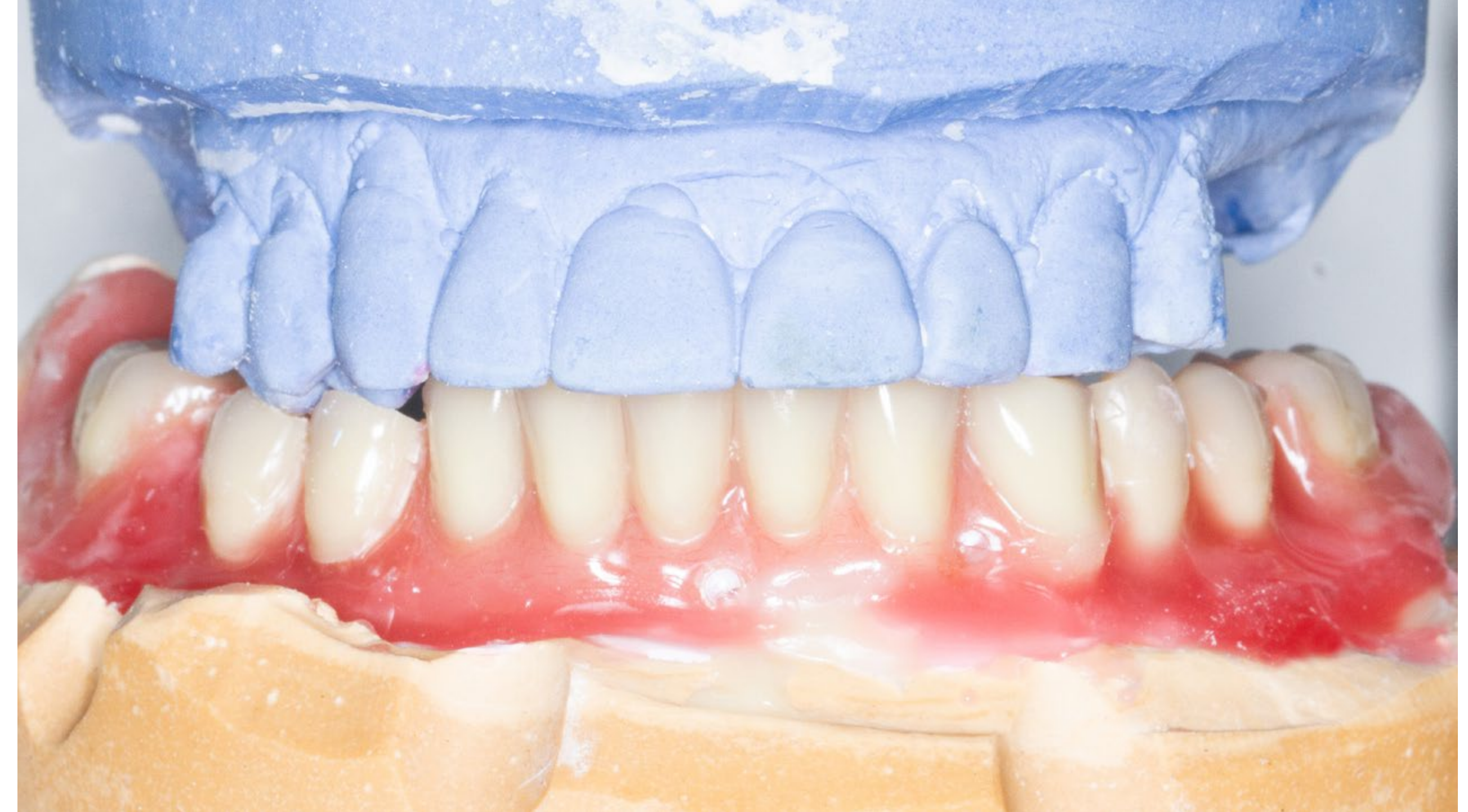

# Challenge 6: Extraction sites and periapical cyst

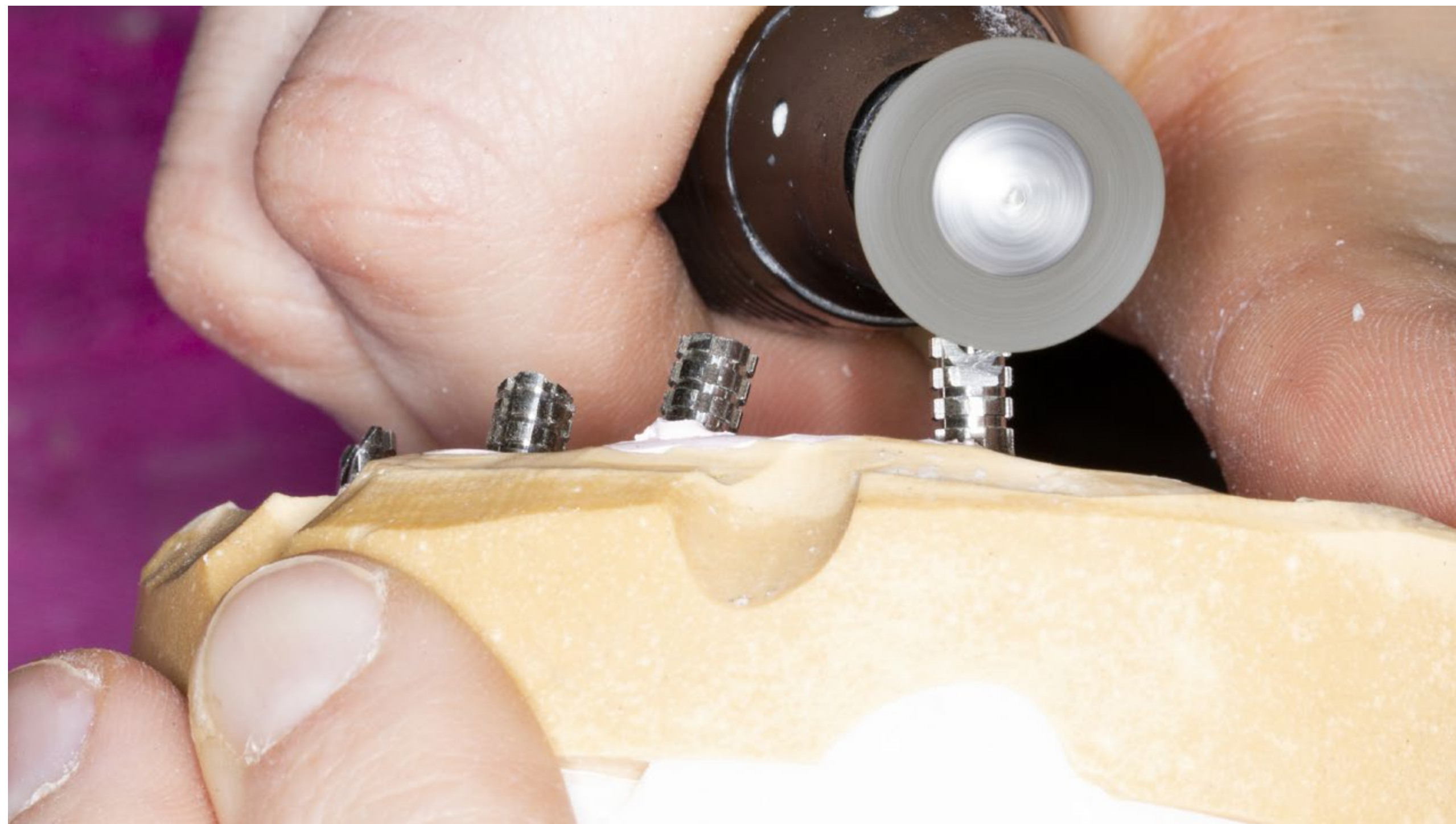Clinical case



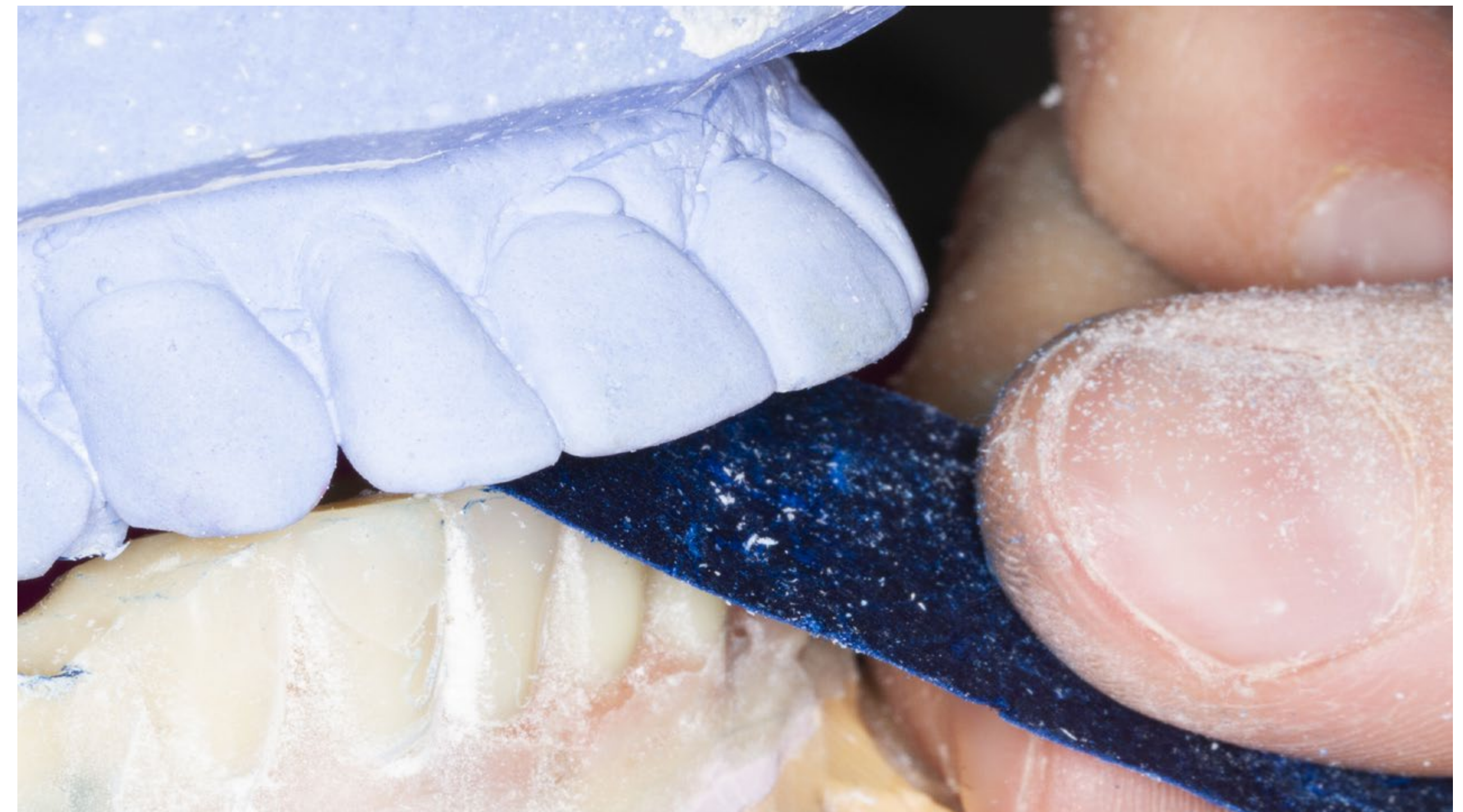Waxing up the prosthesis with stock teeth



Waxing up the prosthesis



Placement of titanium copings  
Titanium copings were placed in the model and their heights were adjusted

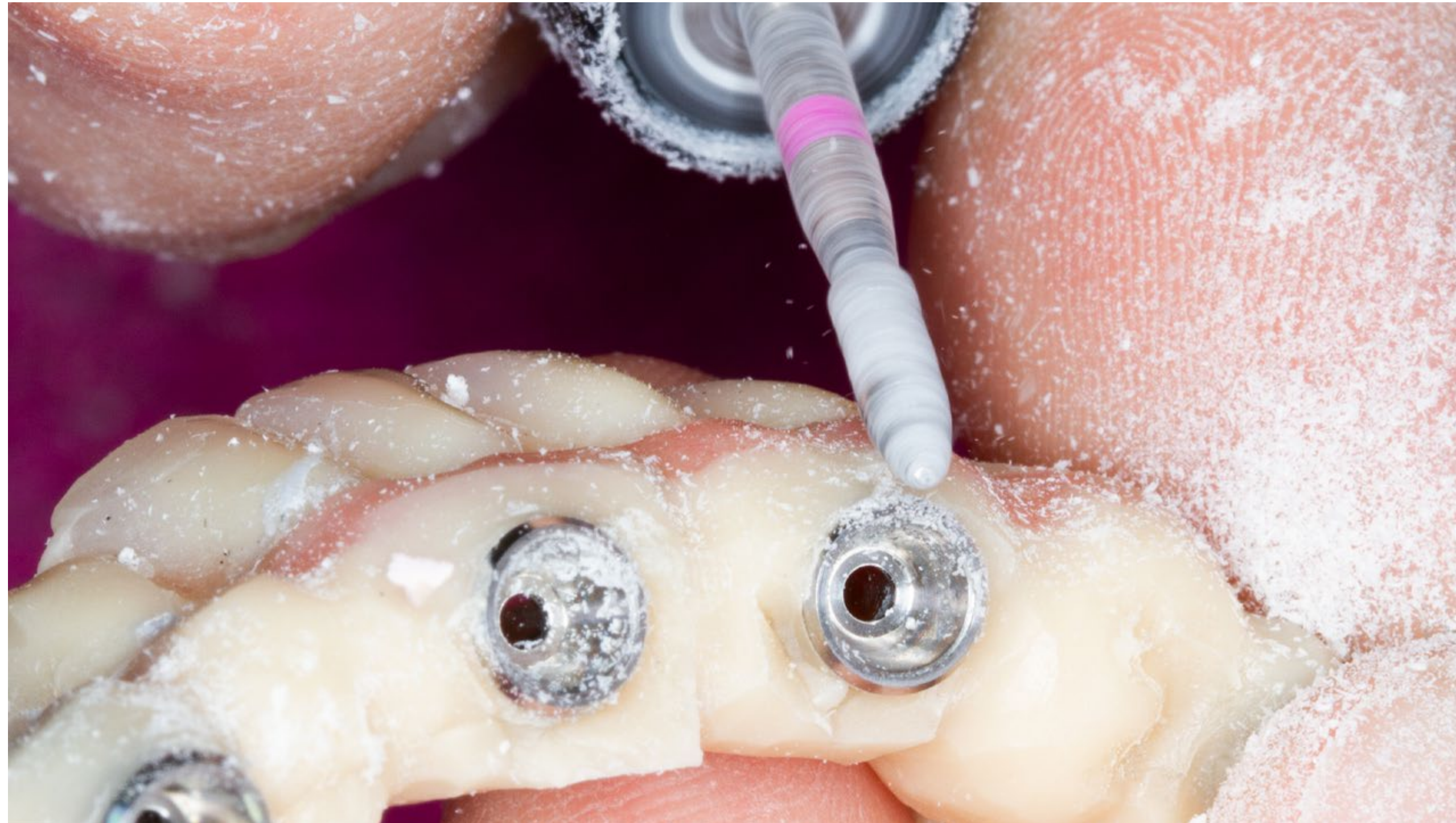

Adjustment of occlusion

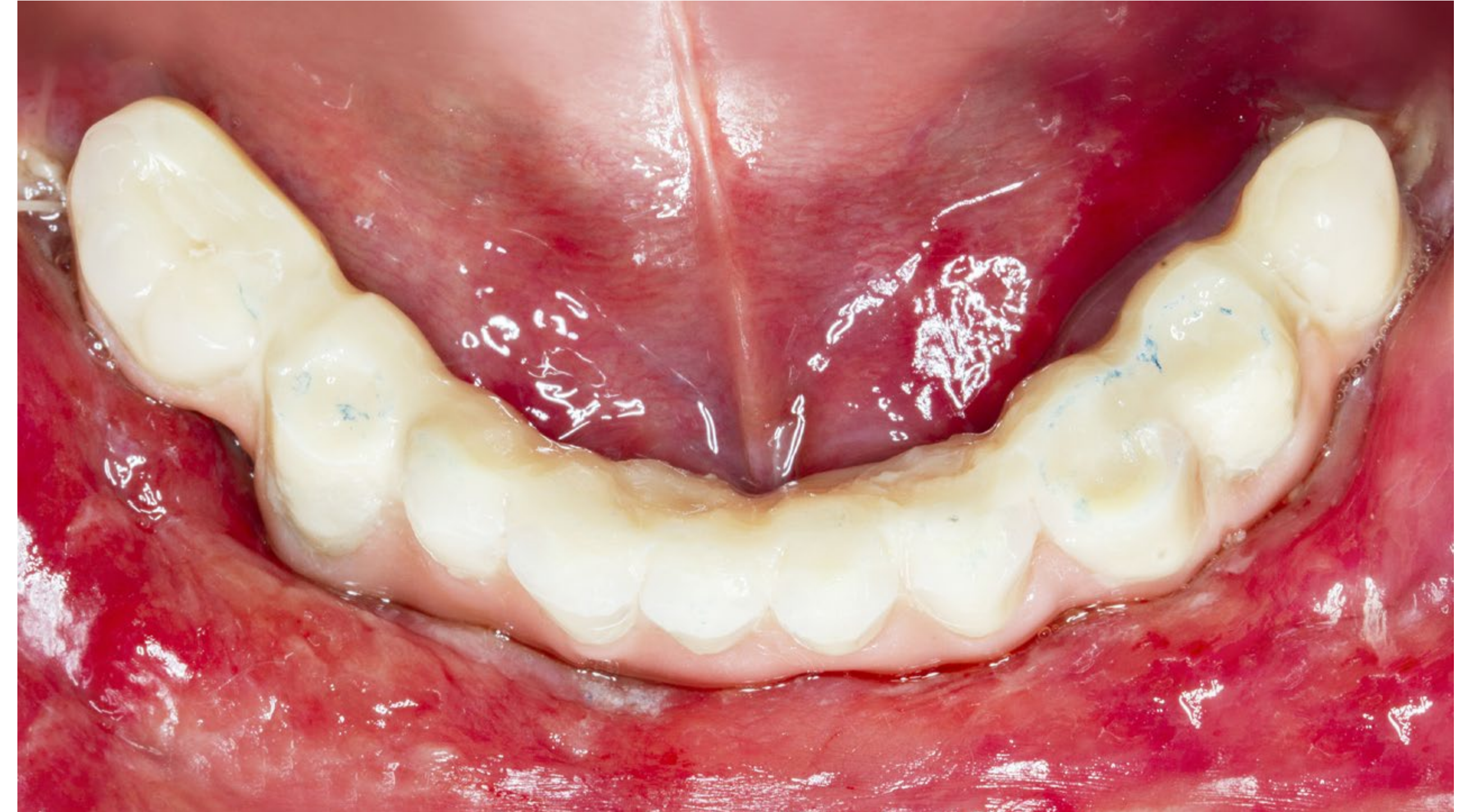

# Challenge 6: Extraction sites and periapical cyst

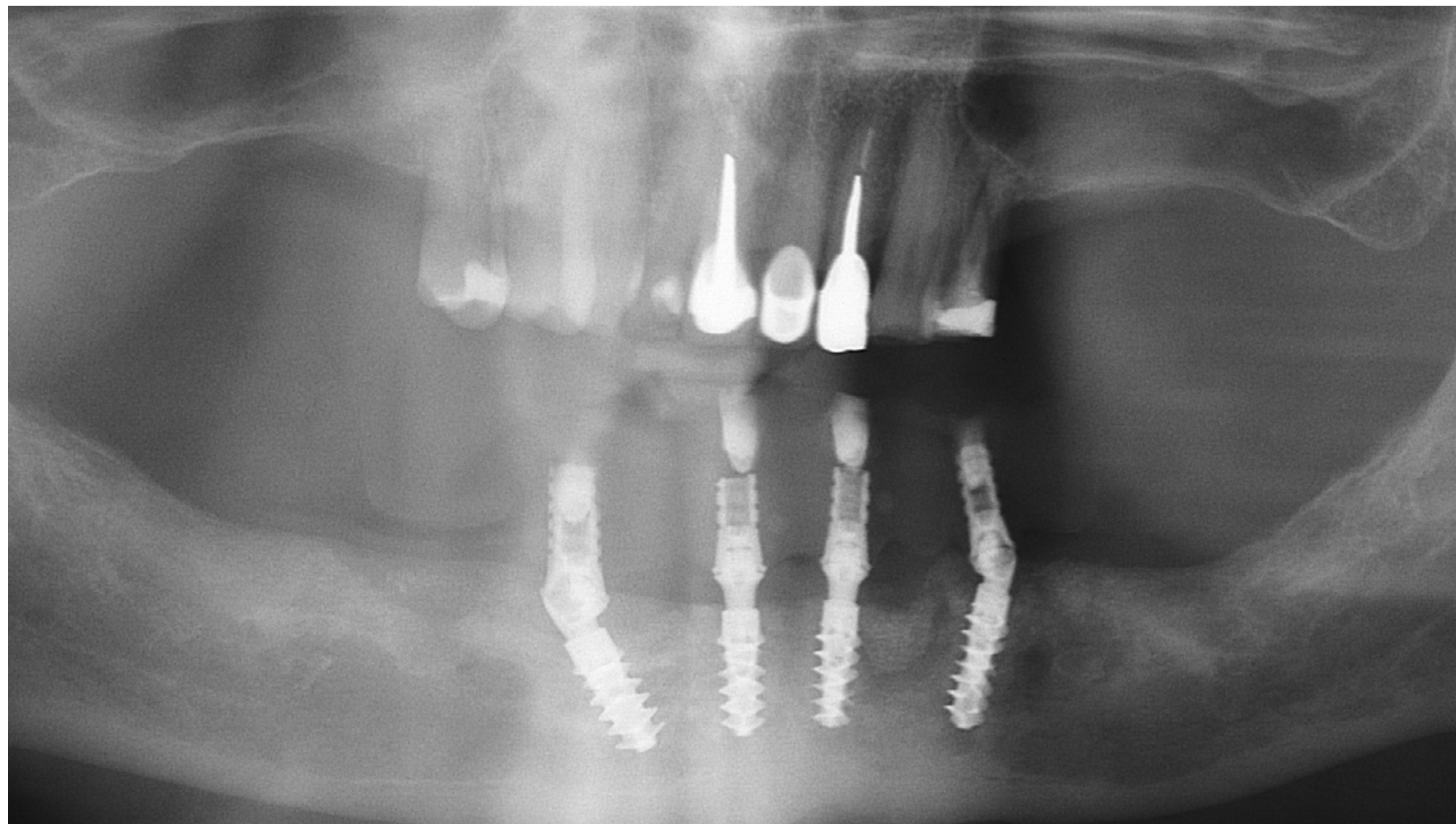
Clinical case



Polishing of provisional prosthesis



Provisional prosthesis in place  
The final prosthesis will be placed within six months

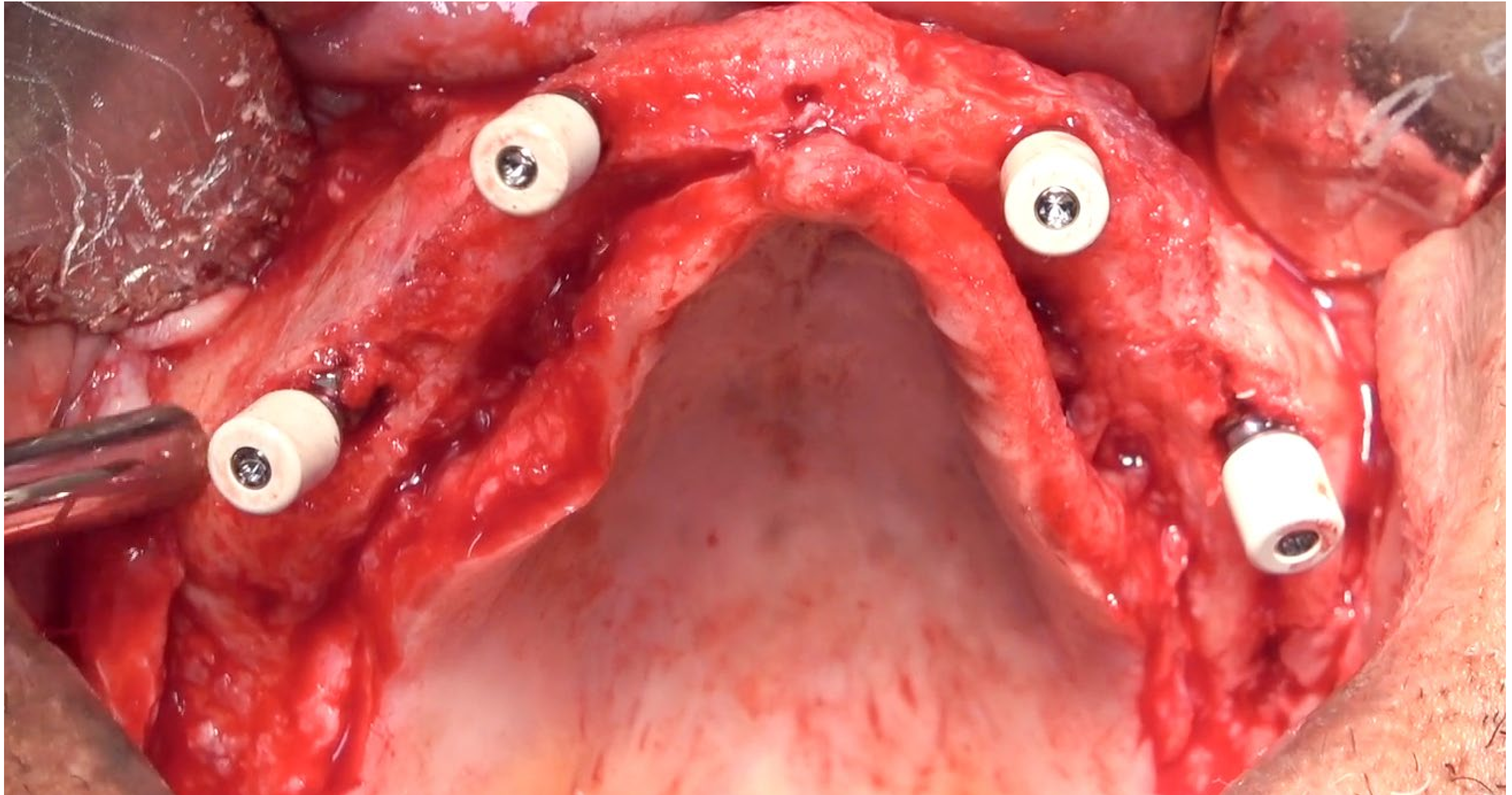


Panoramic radiograph after implant placement and placement of the provisional prosthesis



# Challenge 7: Bi-maxillary protrusion

General recommendations and clinical case from Dr. Edmond Bedrossian





# Challenge 7: Bi-maxillary protrusion

## General recommendations



### General recommendations from Dr. Edmond Bedrossian

- Use of 30° degree angulated abutments for proper orientation of the screw access holes
- Proper inclination of the anterior teeth set-up to compensate for the bi-maxillary protrusion of the alveolar bone

Dr. Edmond Bedrossian received the DDS degree from the University of the Pacific, and completed his Oral and Maxillofacial Residency at Alameda Medical Center.

Dr. Bedrossian is a Diplomate of the American Board of Oral and Maxillofacial Surgery; and Honorary Member of the American College of Prosthodontist.

He is a Professor at the University of the Pacific School of Dentistry combining private practices with academics as the director of implant surgical training.



**Dr. Edmond Bedrossian**  
DDS, FACD, FACOMS, FAO  
Private practice  
San Francisco, US

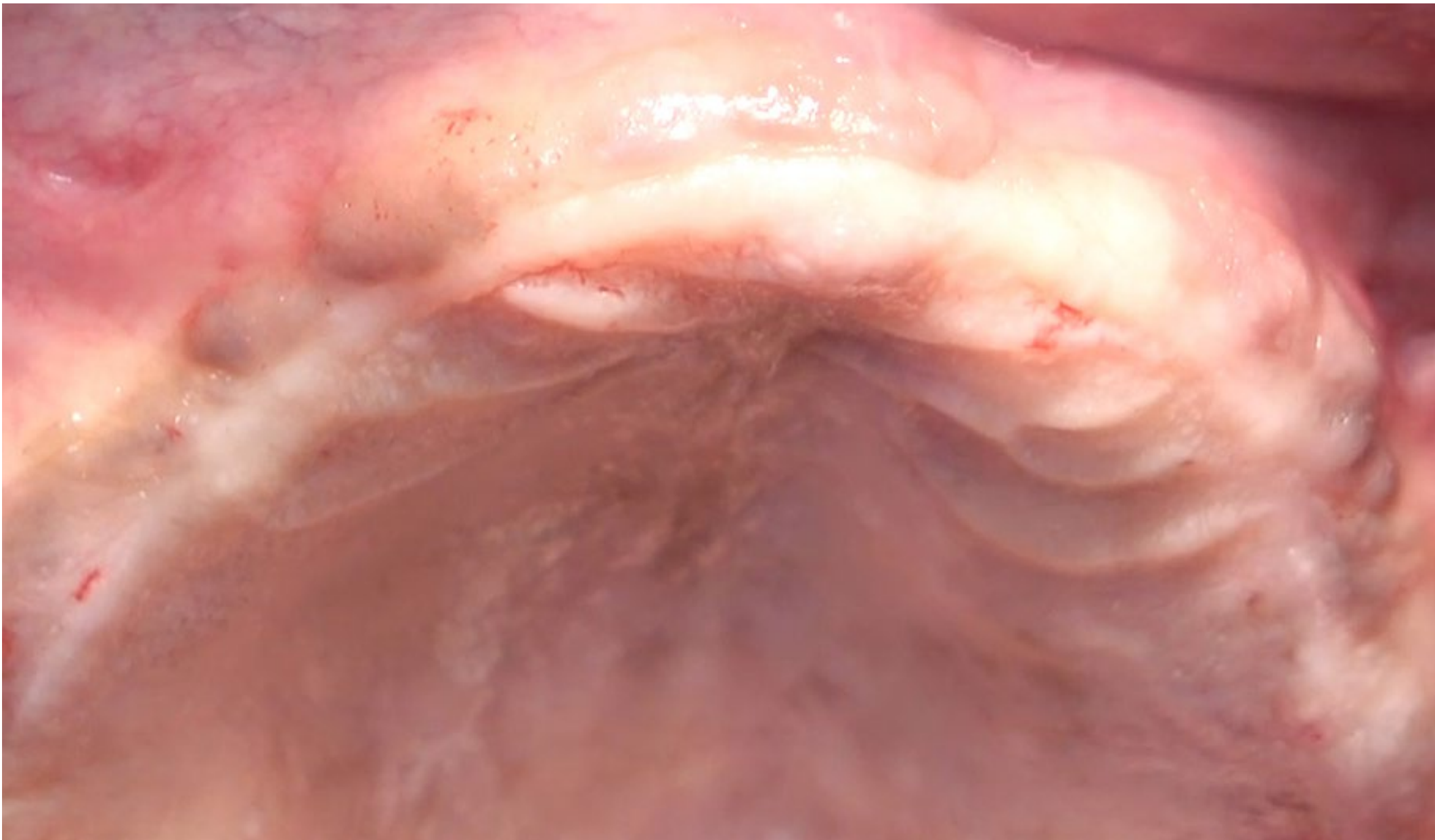

# Challenge 7: Bi-maxillary protrusion

Clinical case



## Initial situation



## Patient information

Age	76
Jaw	Maxilla mandible
Health status	Good
Height of smile line	Low, transition line is hidden
Bone type	Type 2/3 (maxilla) Type 2/3 (mandible)
Infections at implantation site	No
Bone anatomy defects	No
Risks	No

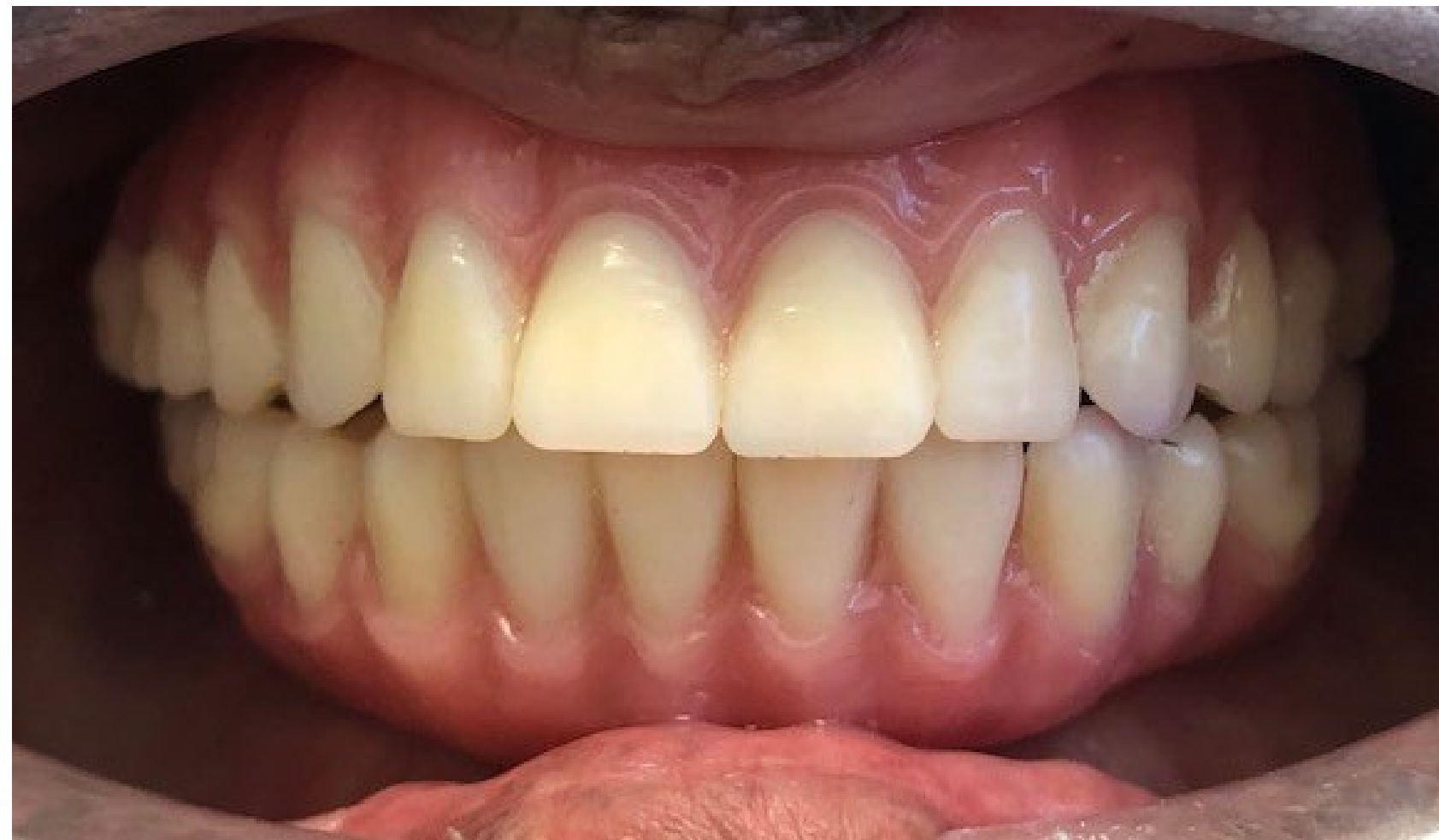

# Challenge 7: Bi-maxillary protrusion

Clinical case



## Temporary prosthesis



## Treatment

- Fixed immediate rehabilitation on four implants in the mandible and the maxilla
- Tilting of the implants due to low bone availability in the posterior region

**Temporary restoration:** direct conversion of the dentures to acrylic hybrid provisional prosthesis

**Planned final prosthesis:** titanium bar with acrylic wrap around hybrid prosthesis

## Materials used



Straumann® BLX Ø 4.5 mm  
RB SLActive® 14 mm Roxolid®  
(maxilla)  
Straumann® BLX Ø 3.75 mm  
RB SLActive® 14 mm Roxolid®  
(mandibular)  
Straumann® BLX Ø 4.5 mm  
RB SLActive® 14 mm Roxolid®  
(mandibular)



Screw-retained abutments,  
30° angled, GH 3.5 mm  
Screw-retained abutments,  
0° straight, GH 3.5 mm



# Challenge 7: Bi-maxillary protrusion

Clinical case



## My experience



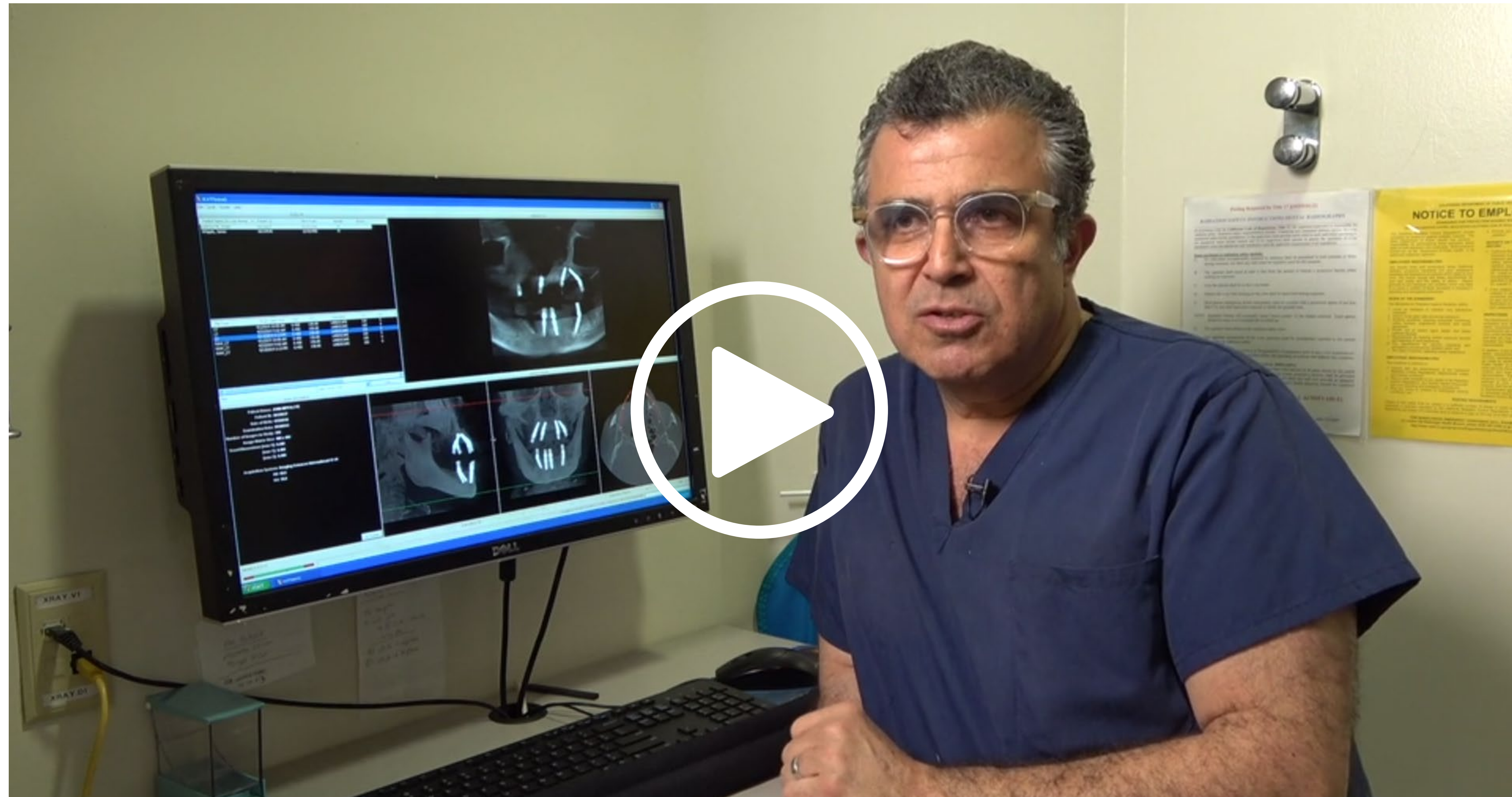
Dr. Edmond Bedrossian  
DDS, FACD, FACOMS, FAO  
Private practice  
San Francisco, US

*“I’m very happy with the results of the treatment and the initial stability of the BLX implant. The single prosthetic platform on the different thread size implants allows the surgeon to concentrate on achieving the appropriate initial implant stability using the appropriate implant diameter knowing that the prosthetic work flow will not be compromised as all implant diameters have the same prosthetic platform.”*



# Challenge 7: Bi-maxillary protrusion

Clinical case

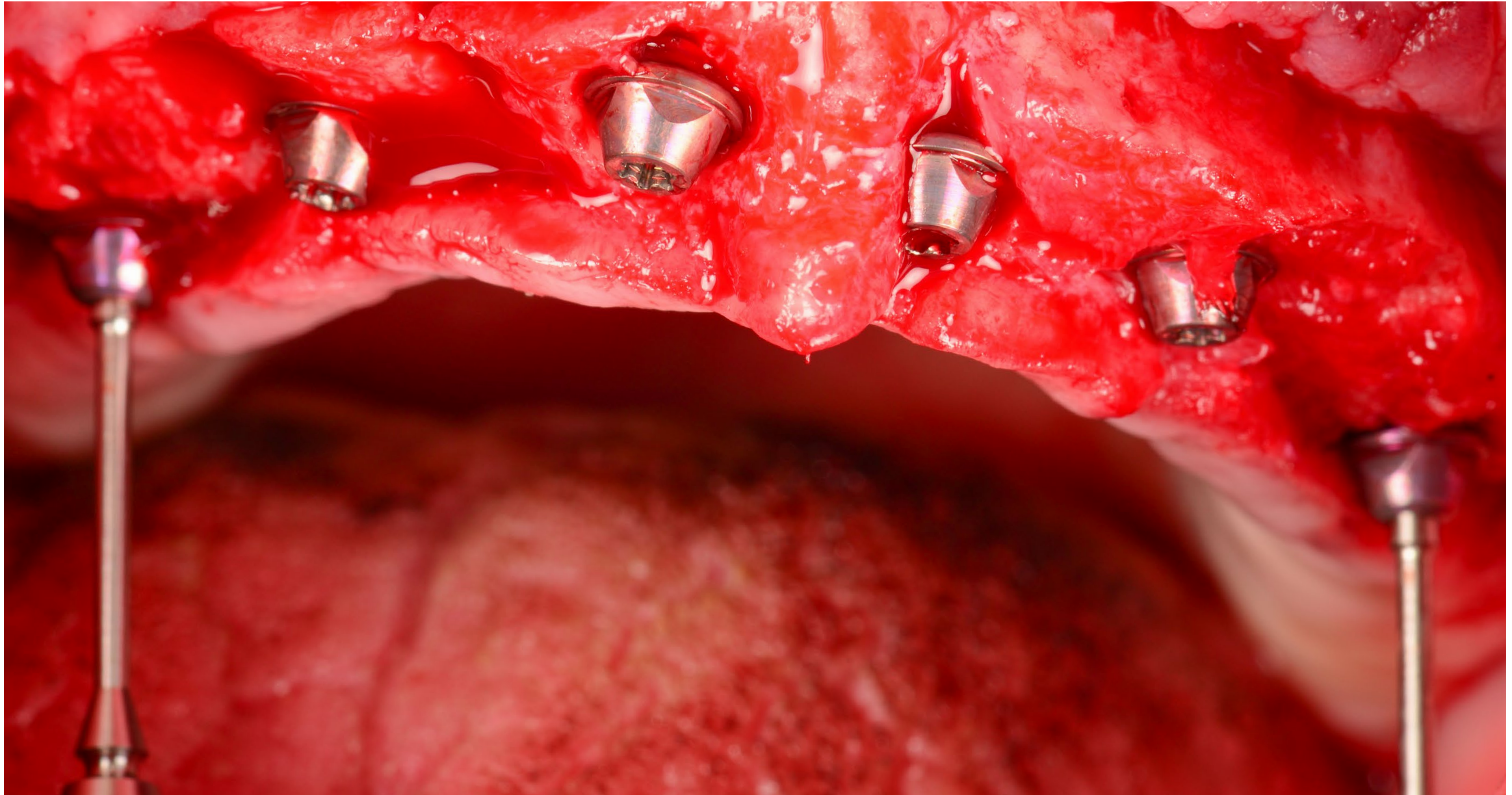


Watch the clinical case video



# Challenge 8: Strong muscular pattern

General recommendations and clinical case from Dr. Léon Pariente, Dr. Karim Dada and Dr. Marwan Daas





# Challenge 8: Strong muscular pattern

## General recommendations



### General recommendations from Dr. Léon Pariente, Dr. Karim Dada, Dr. Marwan Daas

- Optimal implant spread
- Increased number of implants for the best loading distribution

Dr. Pariente, Dr. Dada and Dr. Marwan Daas earned their DDS degrees from the University of Paris René Descartes. For several years they successfully lectured during international conferences and also conducted many advanced implant courses. They are also co-authors of several scientific publications in implantology. Together they work in a private practice dedicated to implantology and periodontology.



**Dr. Léon Pariente**  
DDS, Private practice,  
Paris, France



**Dr. Karim Dada**  
DDS, Private practice,  
Paris, France



**Dr. Marwan Daas**  
DDS, Private practice,  
Paris, France

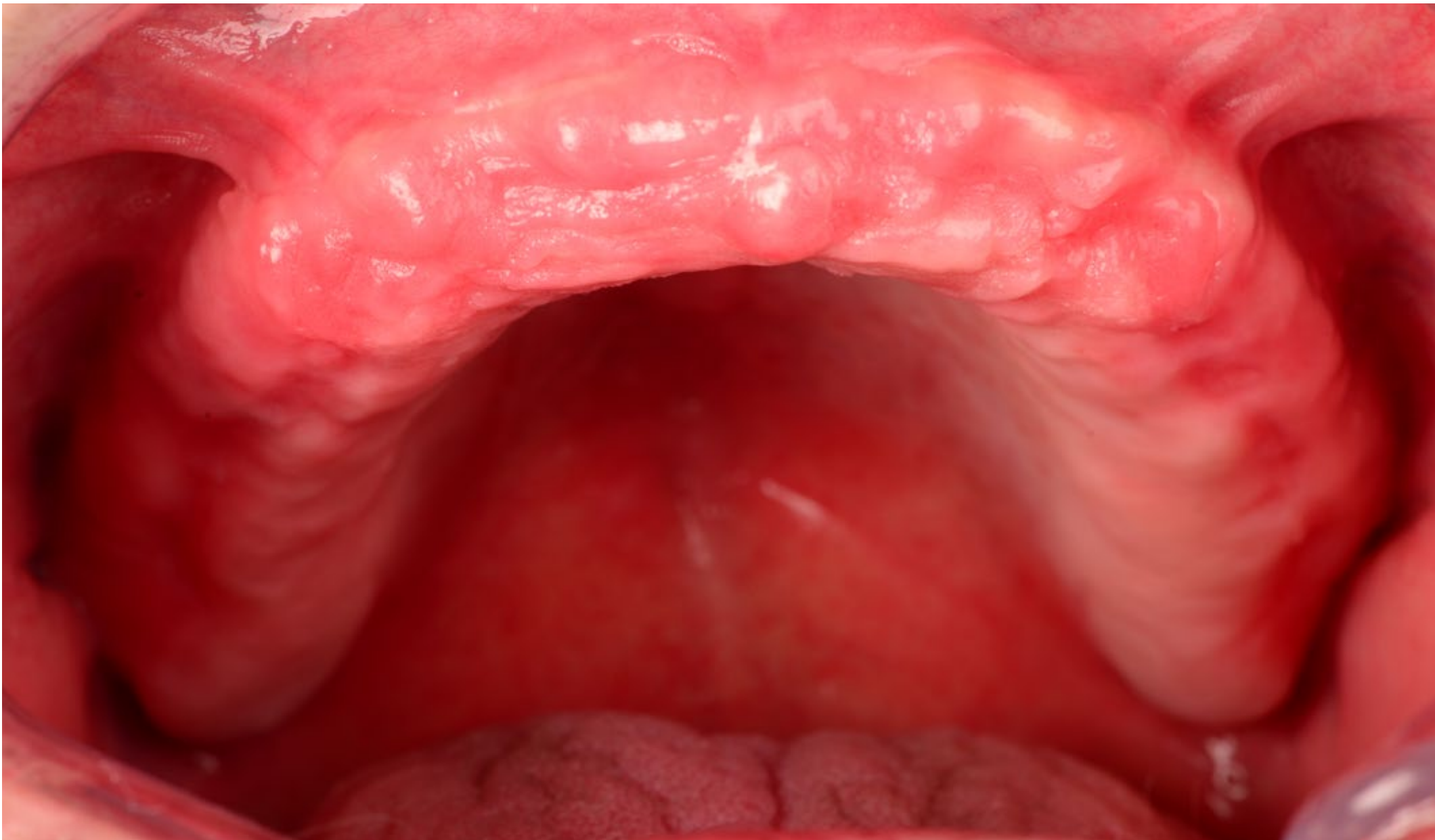

# Challenge 8: Strong muscular pattern

Clinical case



## Initial situation



## Patient information

Age	54
Jaw	Maxilla
Health status	Good
Height of smile line	Low
Bone type	Soft
Infections at implantation site	No
Bone anatomy defects	No defects
Risks	No

## Additional difficulties

Soft bone quality
Limited bone availability in the posterior area
Moderate resorption

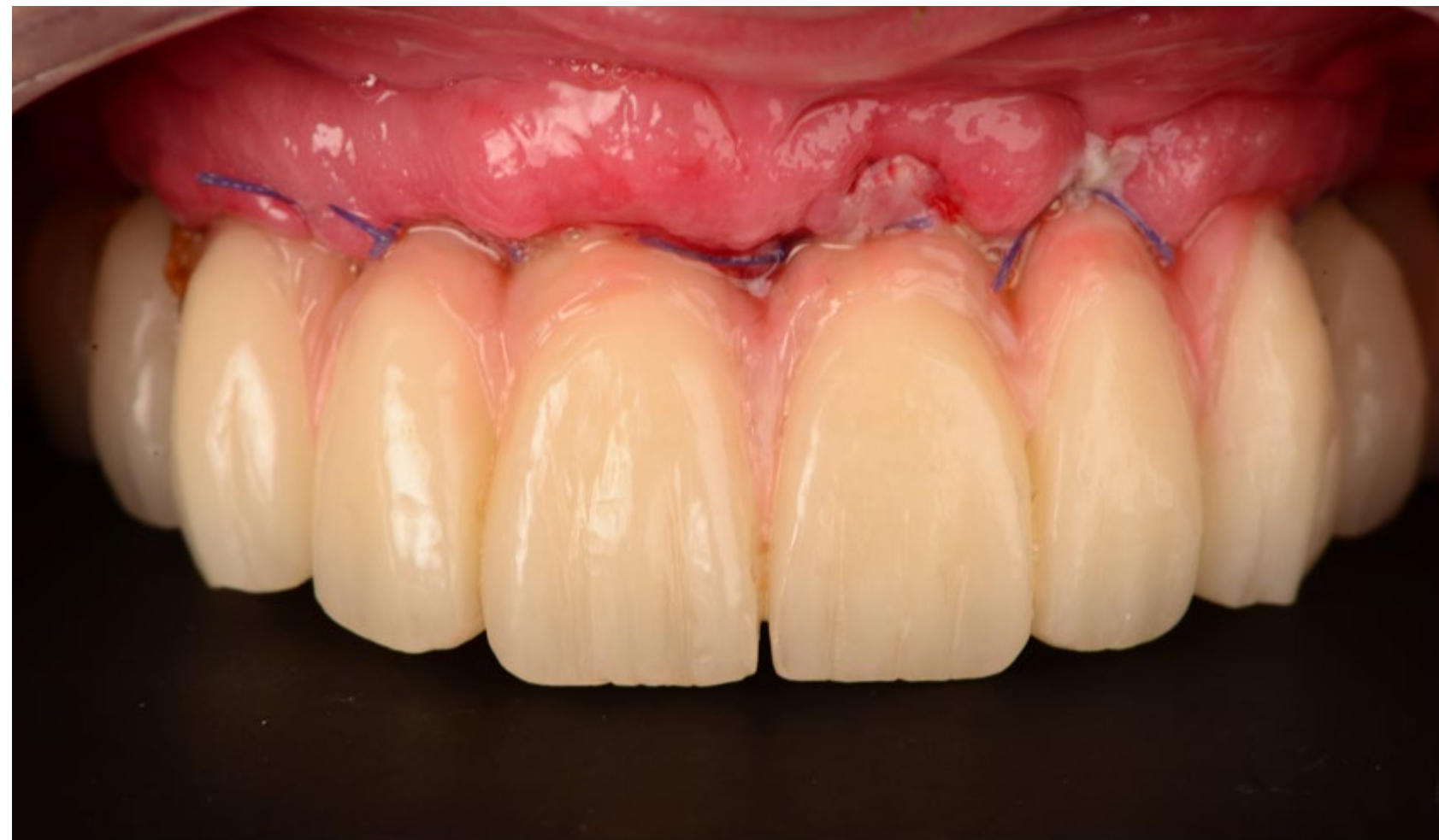

# Challenge 8: Strong muscular pattern

Clinical case



## Provisional prosthesis



## Treatment

- Fixed immediate rehabilitation on six implants
- Slight bone reduction
- Tilting of the posterior implants because of low bone availability in the posterior region

**Temporary restoration:** Milled CAD/CAM provisional

**Planned final prosthesis:** full-contour zirconium prosthesis

## Materials used



Straumann® BLX Ø 4.5 mm  
RB SLActive® 12mm, Roxolid®



Screw-retained Abutments,  
straight, GH 2.5 mm  
Screw-retained Abutments,  
30° angled, GH 3.5 mm



# Challenge 8: Strong muscular pattern

Clinical case



## Our experience



Dr. Léon PARIENTE  
DDS, Private practice,  
Paris, France

*“Despite the soft bone quality, it was possible to load the case thanks to the high primary stability of the BLX implant. I also liked the preparation of the osteotomy for the 3.75 mm implant in the soft bone. It is very fast, and only two drills were necessary.”*



Dr. Karim Dada  
DDS, Private practice,  
Paris, France

*“The use of the Screw-retained abutments allowed us to compensate for the angulated implants and offer a screw-retained solution. The smooth shape of the angulated abutment helps avoid bone interference in the crestal area. Bone profiling was not necessary and abutment placement was very quick.”*



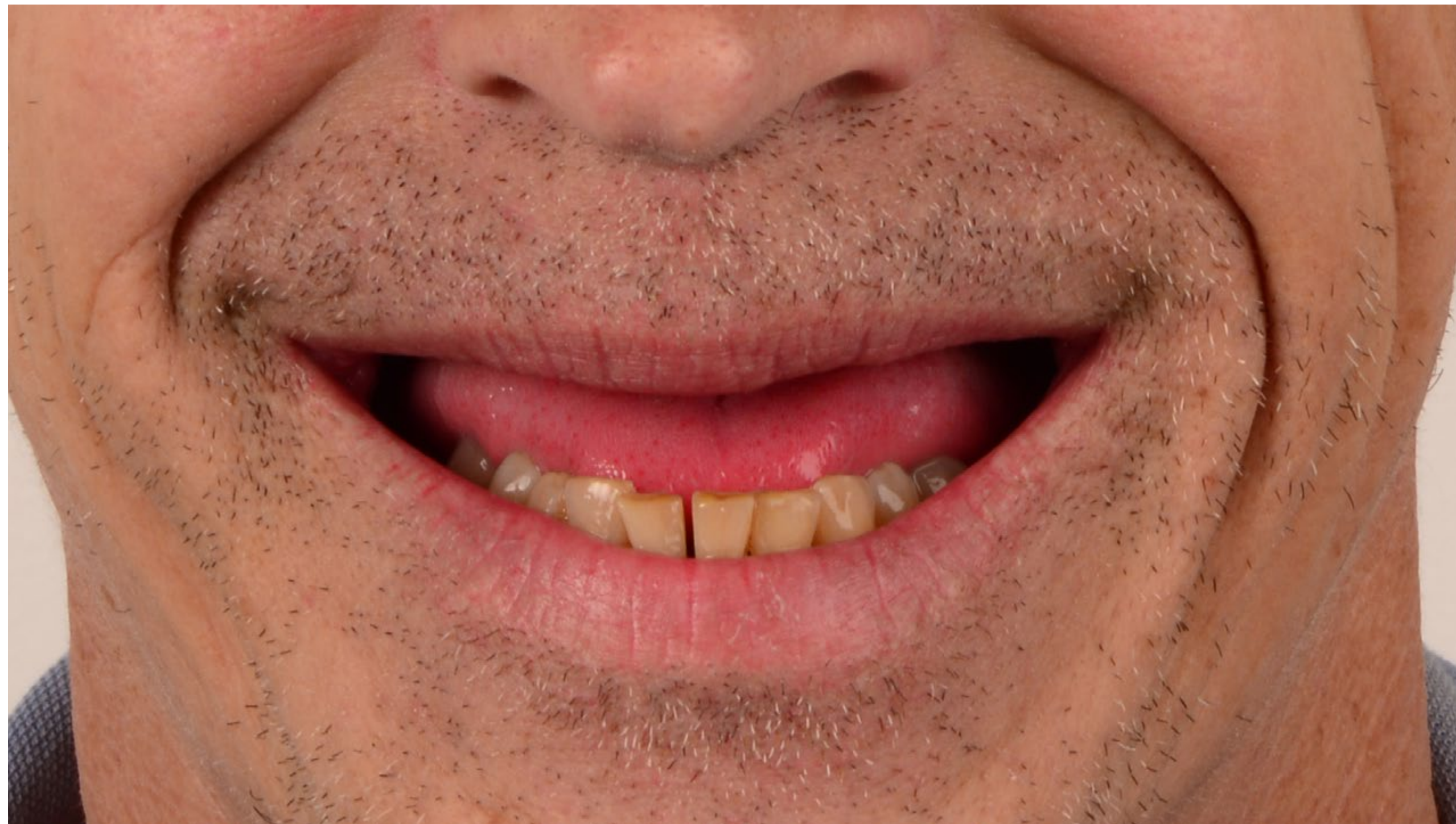Dr. Marwan Daas  
DDS, Private practice,  
Paris, France

*“When the restoration is done on more than four implants, I prefer to do the pick-up of the provisional prostheses in the laboratory rather than the patient’s mouth. As a result, we have better control of the occlusive movements in the articulator and obtain more precise results.”*

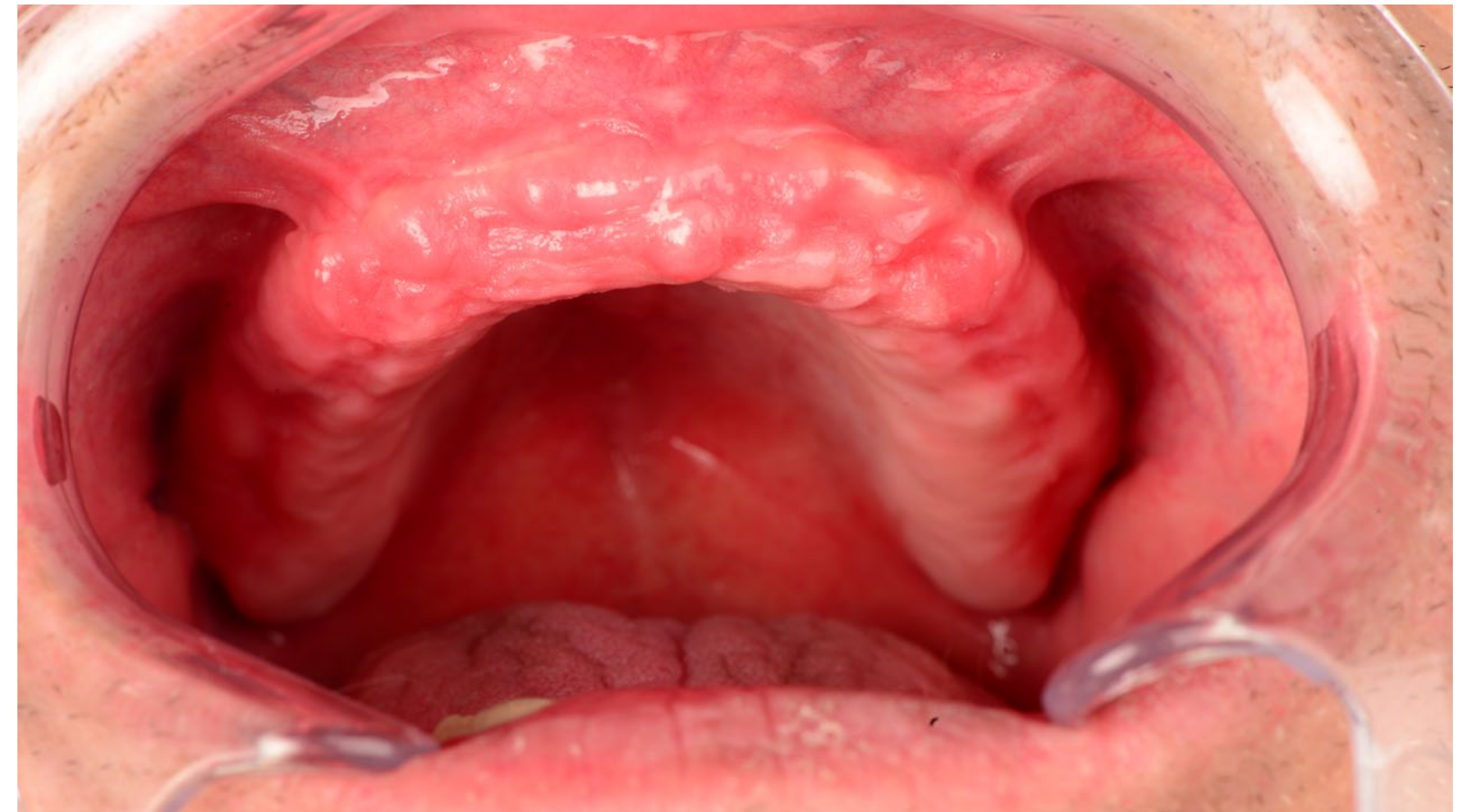

# Challenge 8: Strong muscular pattern

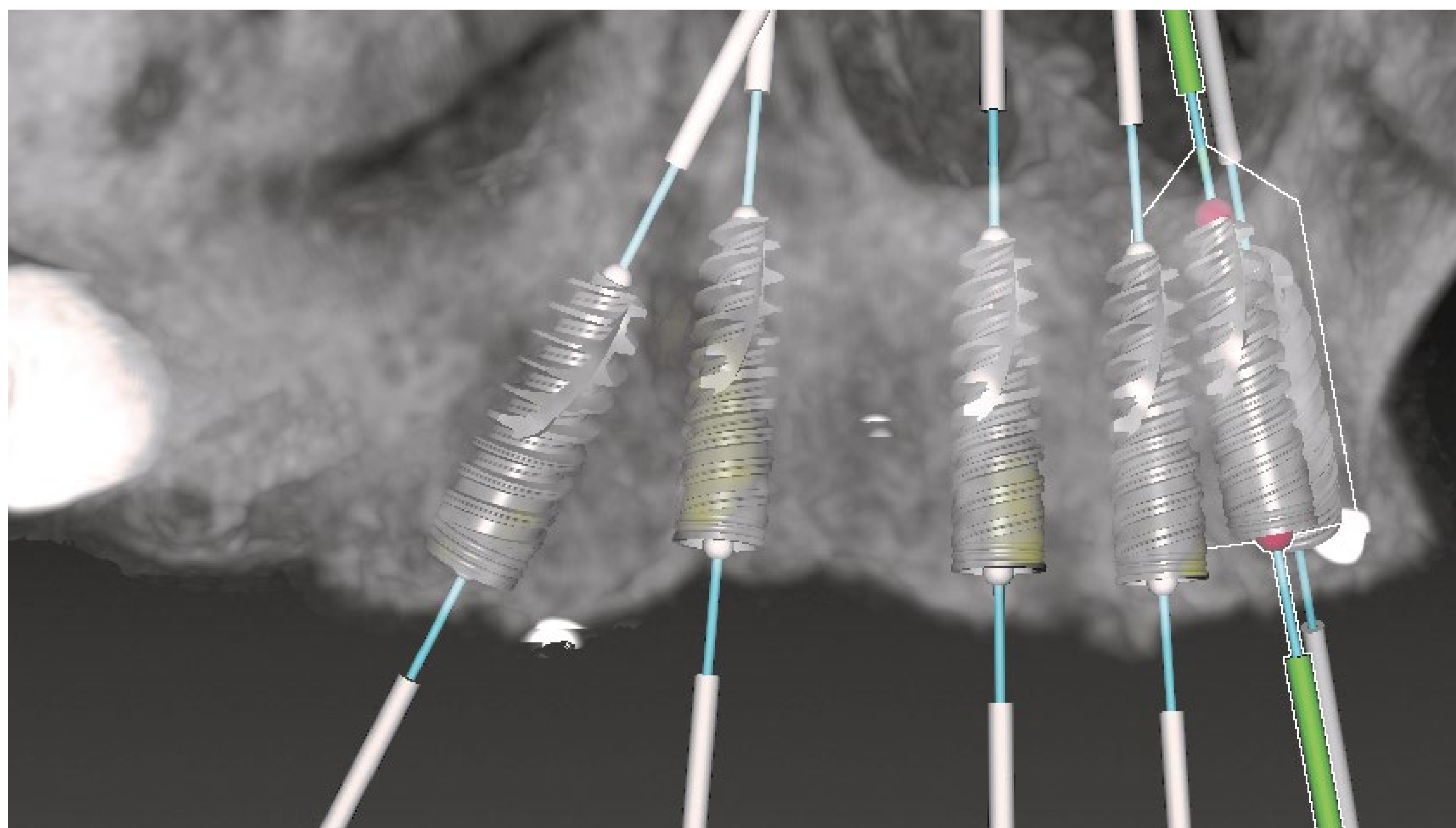
Clinical case



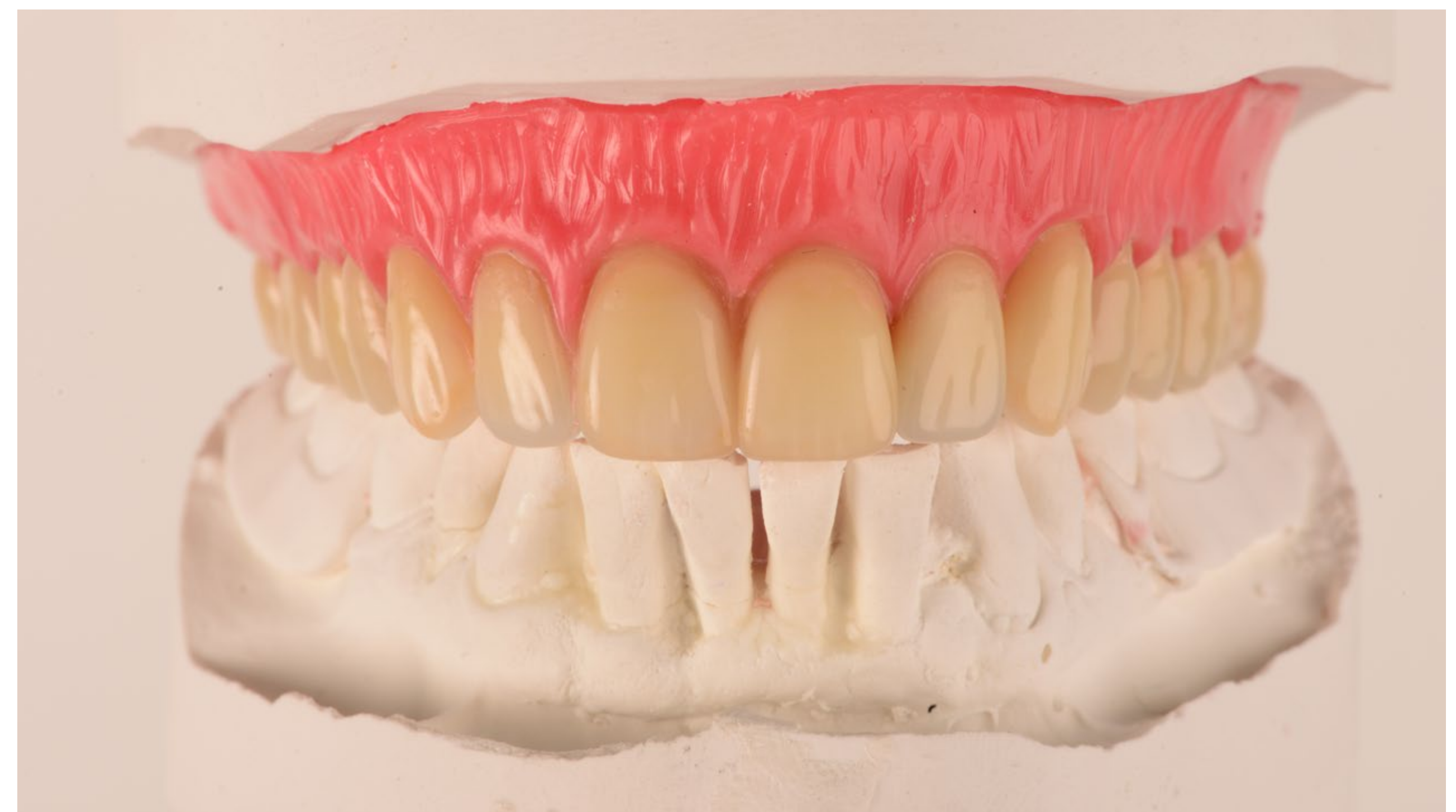Initial clinical situation



Preoperative condition



Preoperative implant planning: two implants are angulated along the anterior sinus wall to avoid a sinus lift procedure

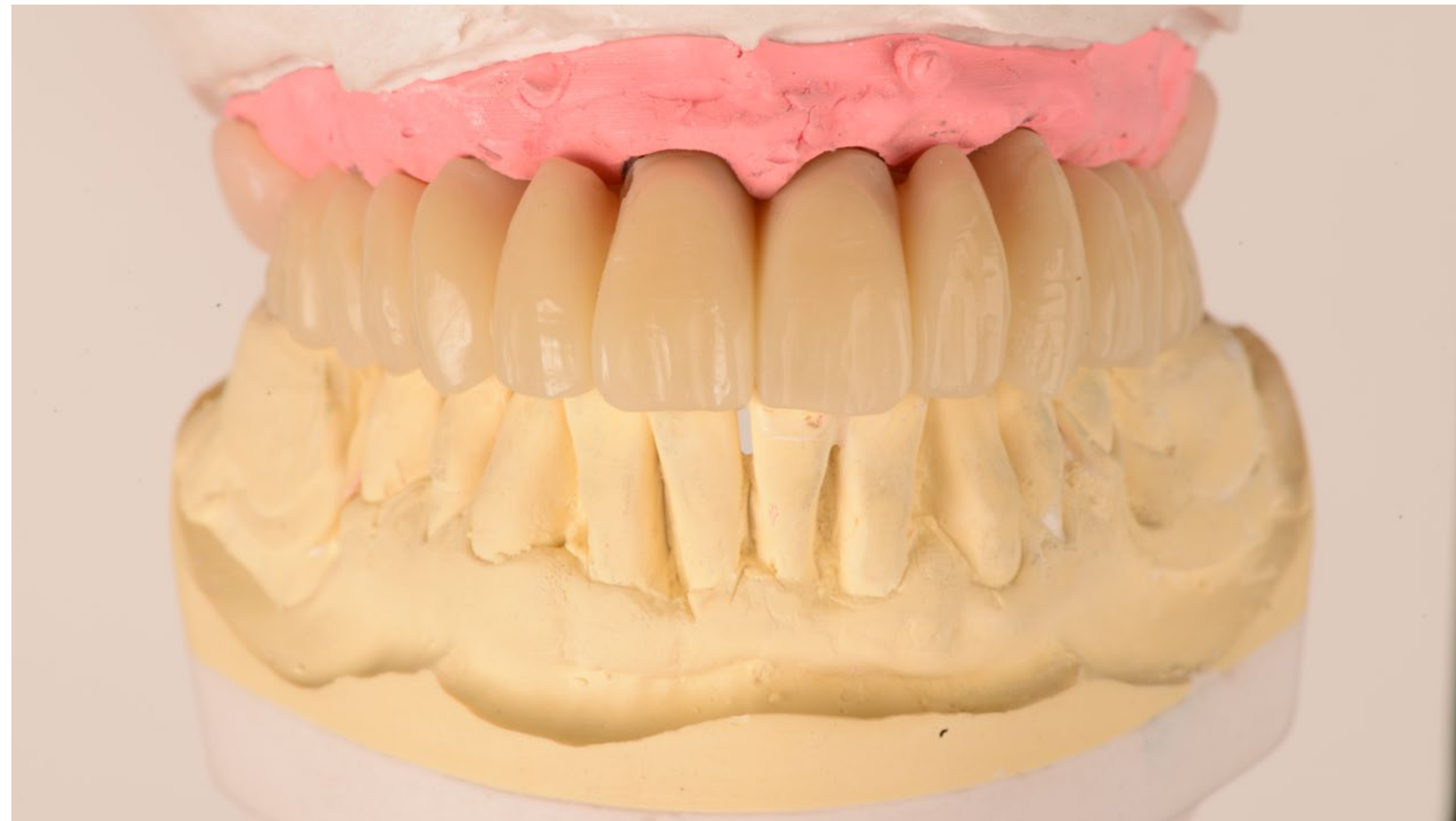

Prior to the implant treatment a new set-up is done and validated with the patient

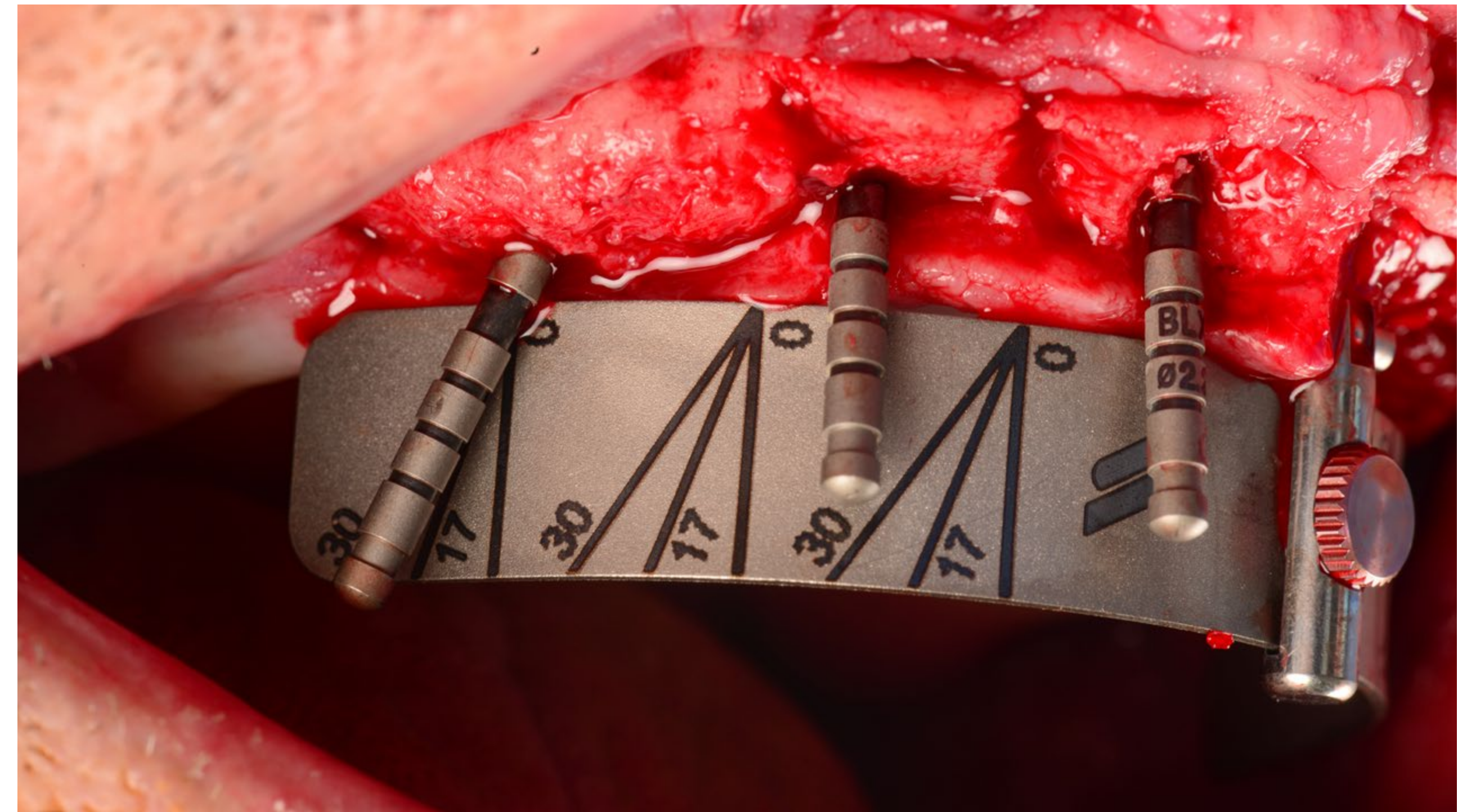


# Challenge 8: Strong muscular pattern

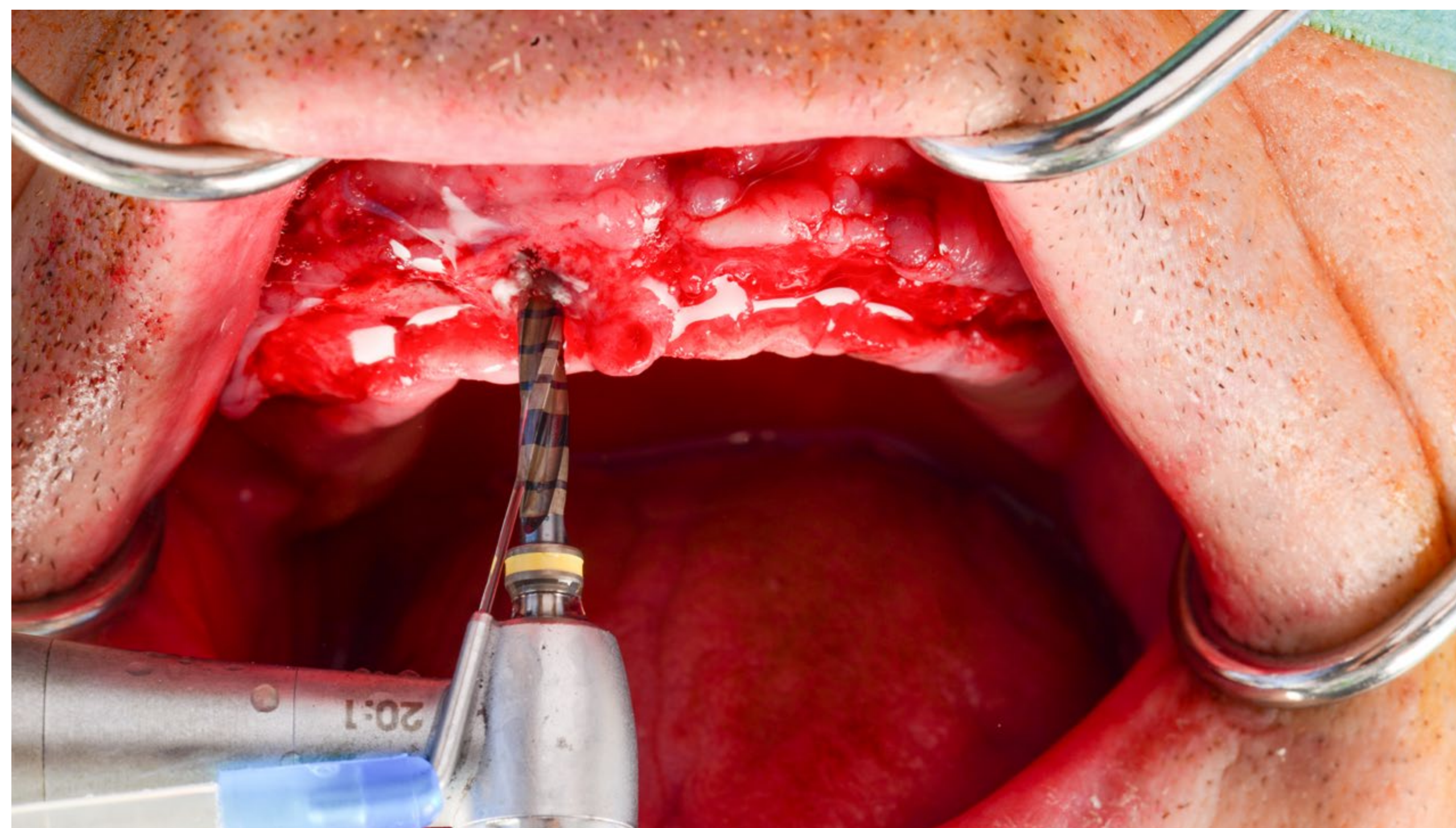
Clinical case



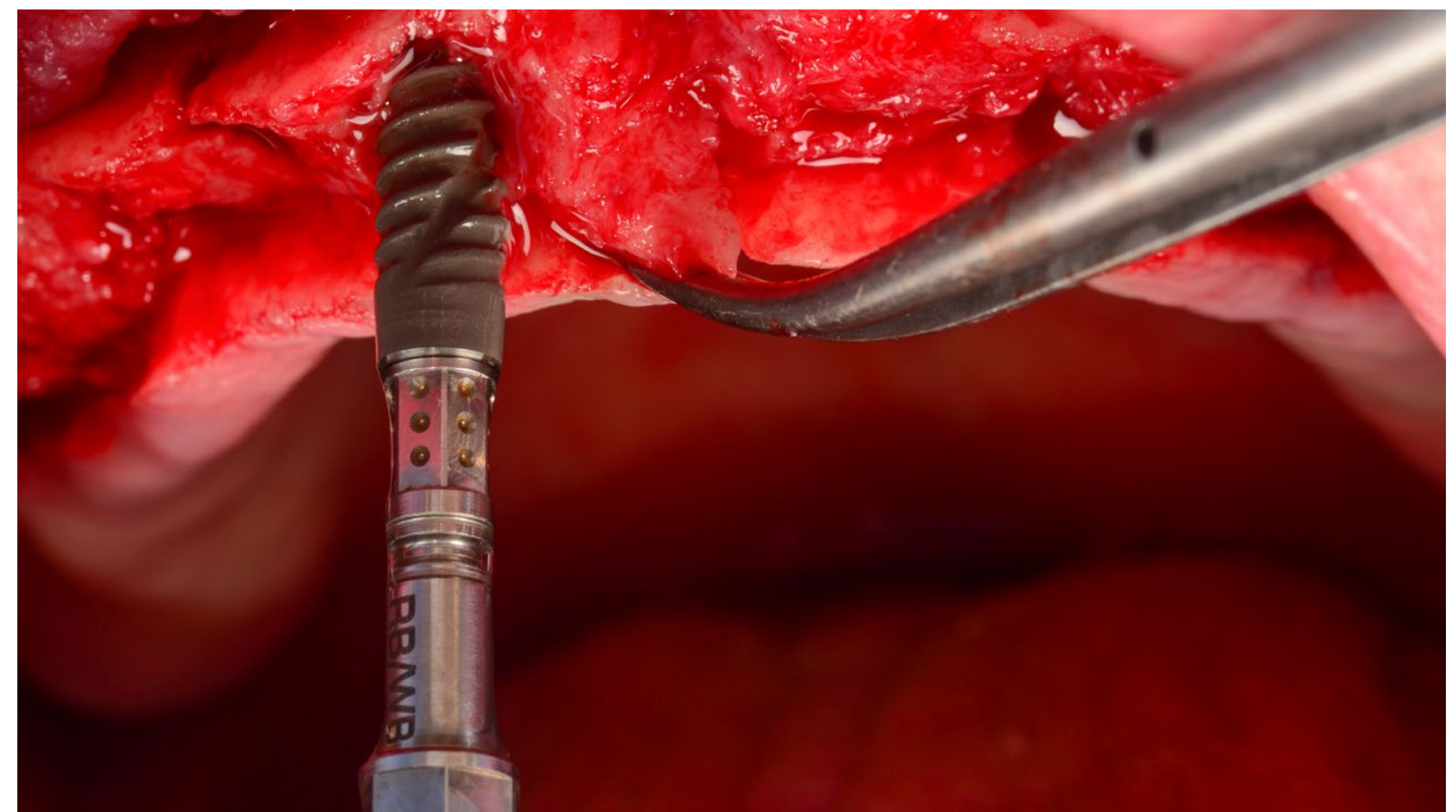
A CAD/CAM temporary restoration is designed and milled



The angulation of distal implants is checked using the alignment pins and the Pro Arch Guide



Preparation of the implant sites  
Drill Ø 2.8 mm

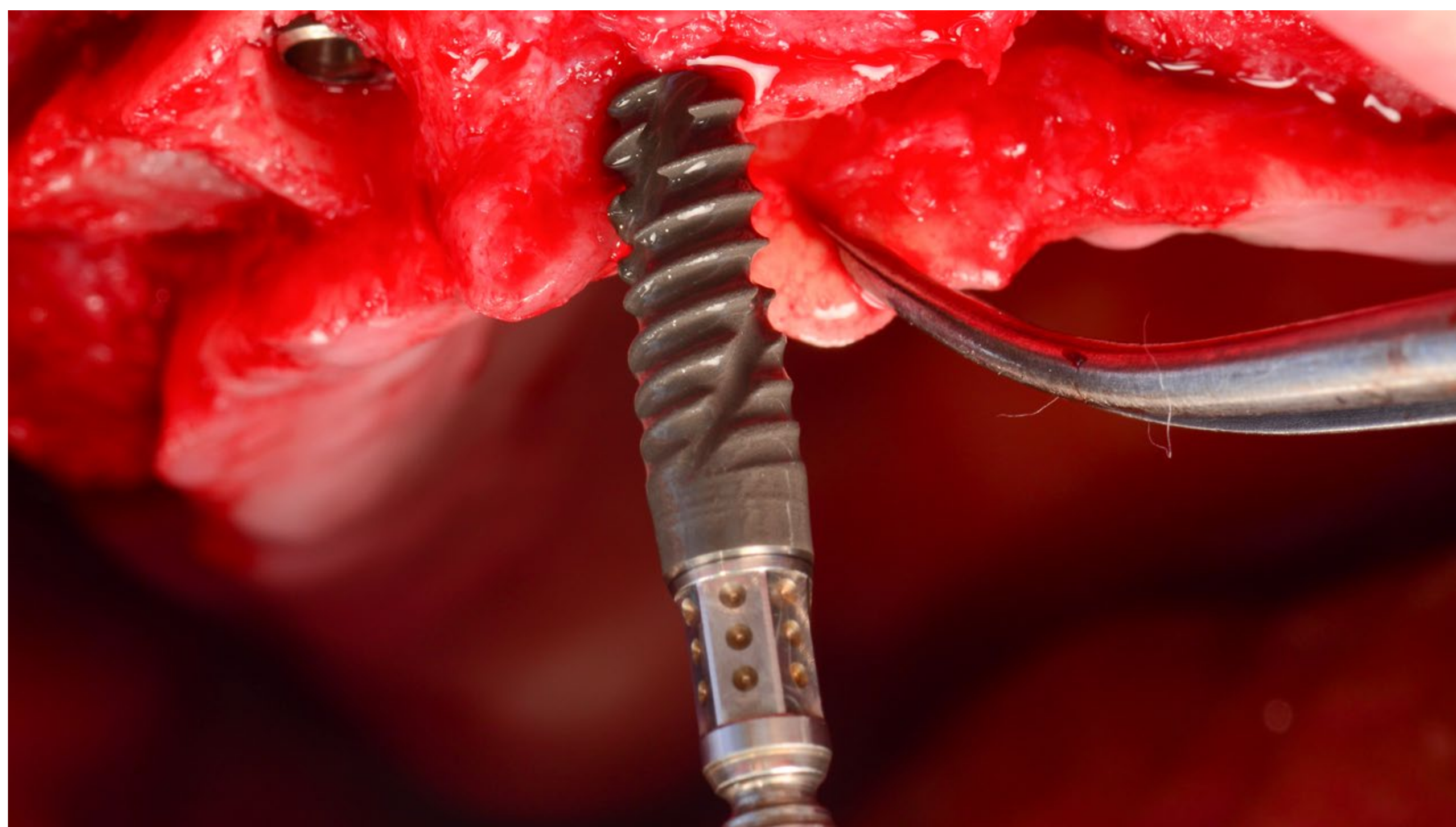


Placement of the Straumann® BLX Ø 4.5 mm RB SLActive® 12mm, Roxolid® with a torque of 35Ncm

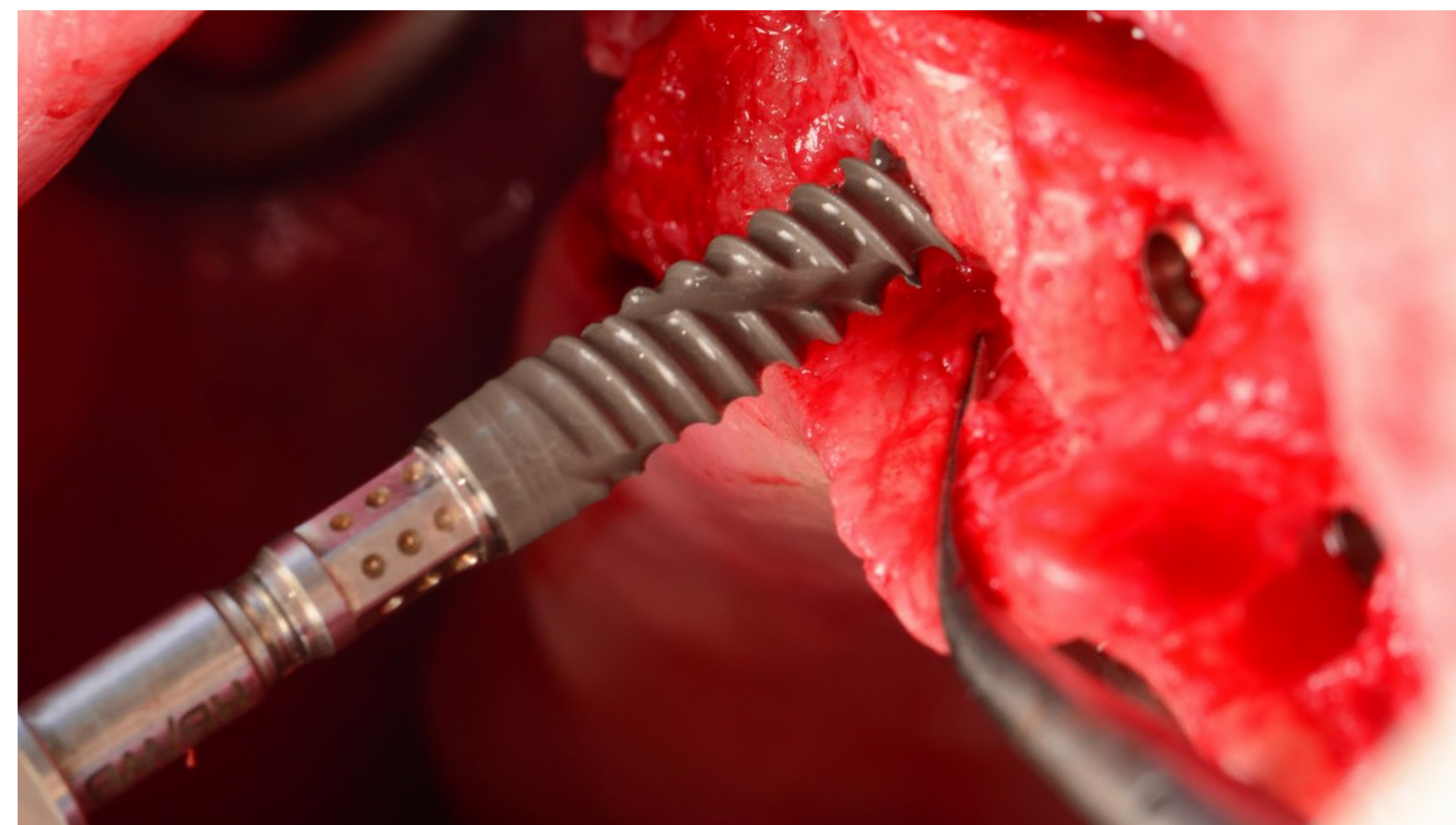


# Challenge 8: Strong muscular pattern

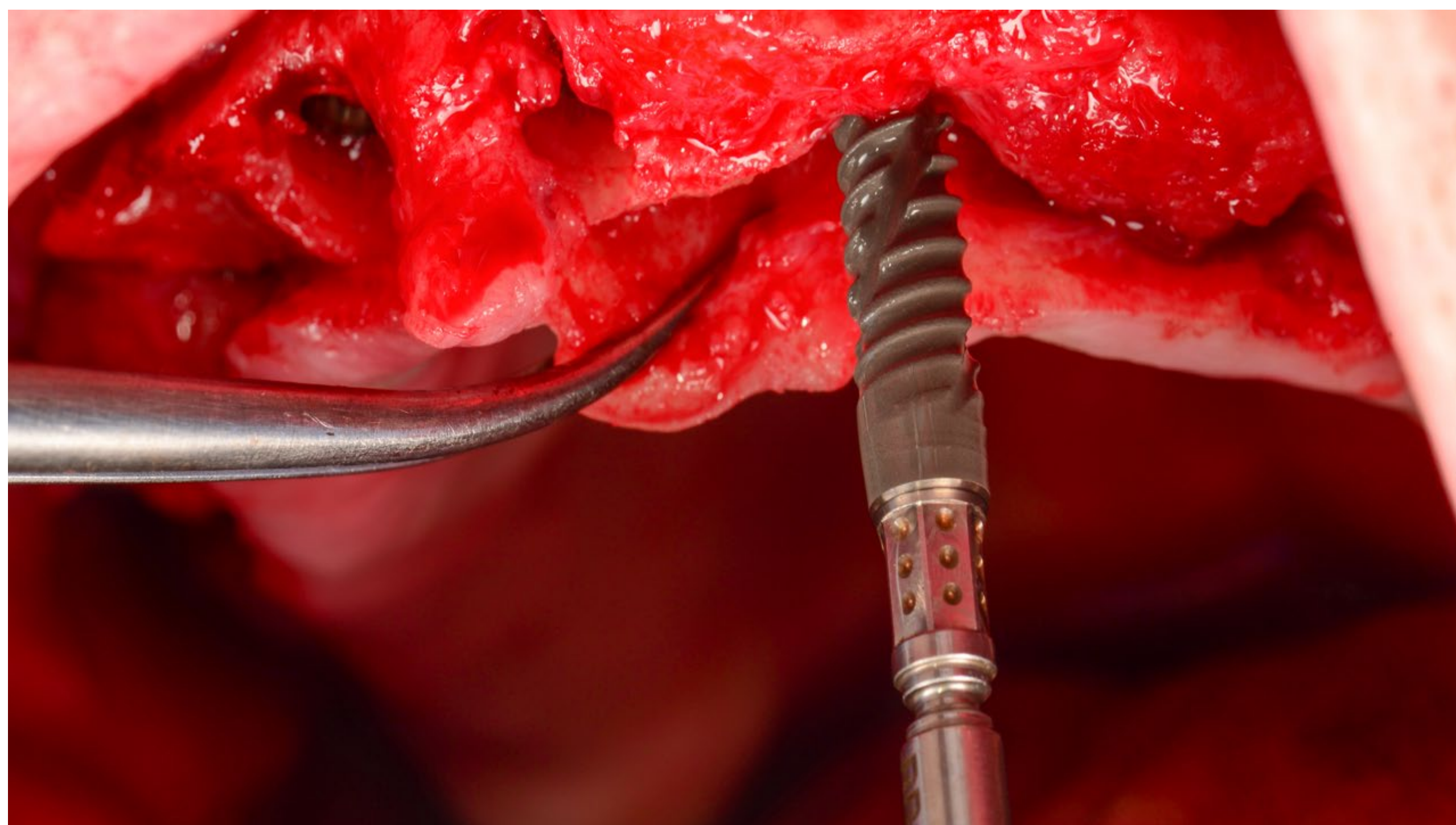
Clinical case



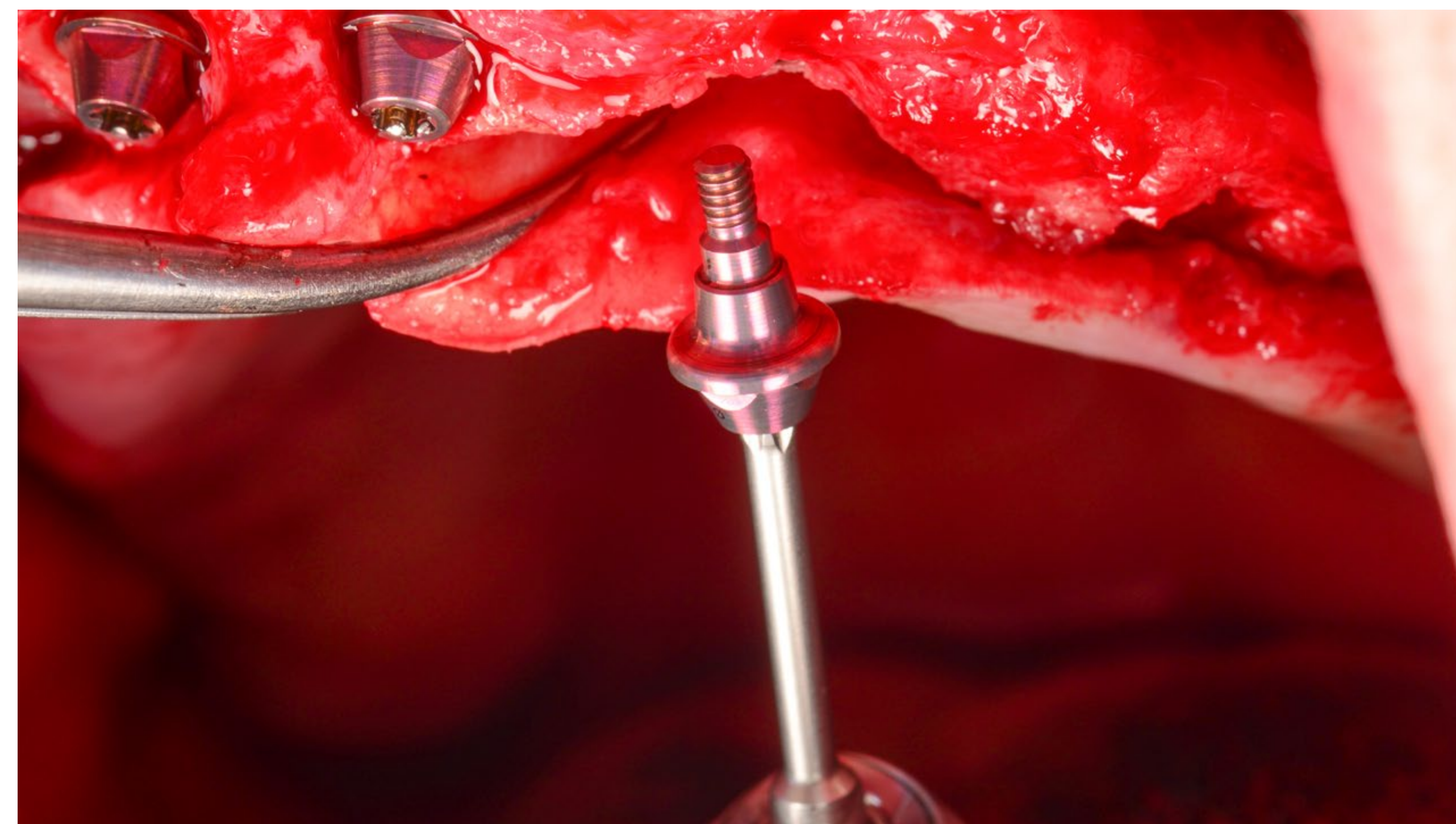
Placement of the Straumann® BLX Ø 4.5 mm RB SLActive® 12 mm, Roxolid® with a torque of 35 Ncm



Placement of the Straumann® BLX Ø 4.5 mm RB SLActive® 12 mm, Roxolid® with a torque of 35 Ncm



Placement of the Straumann® BLX Ø 4.5 mm RB SLActive® 12 mm, Roxolid® with a torque of 35 Ncm

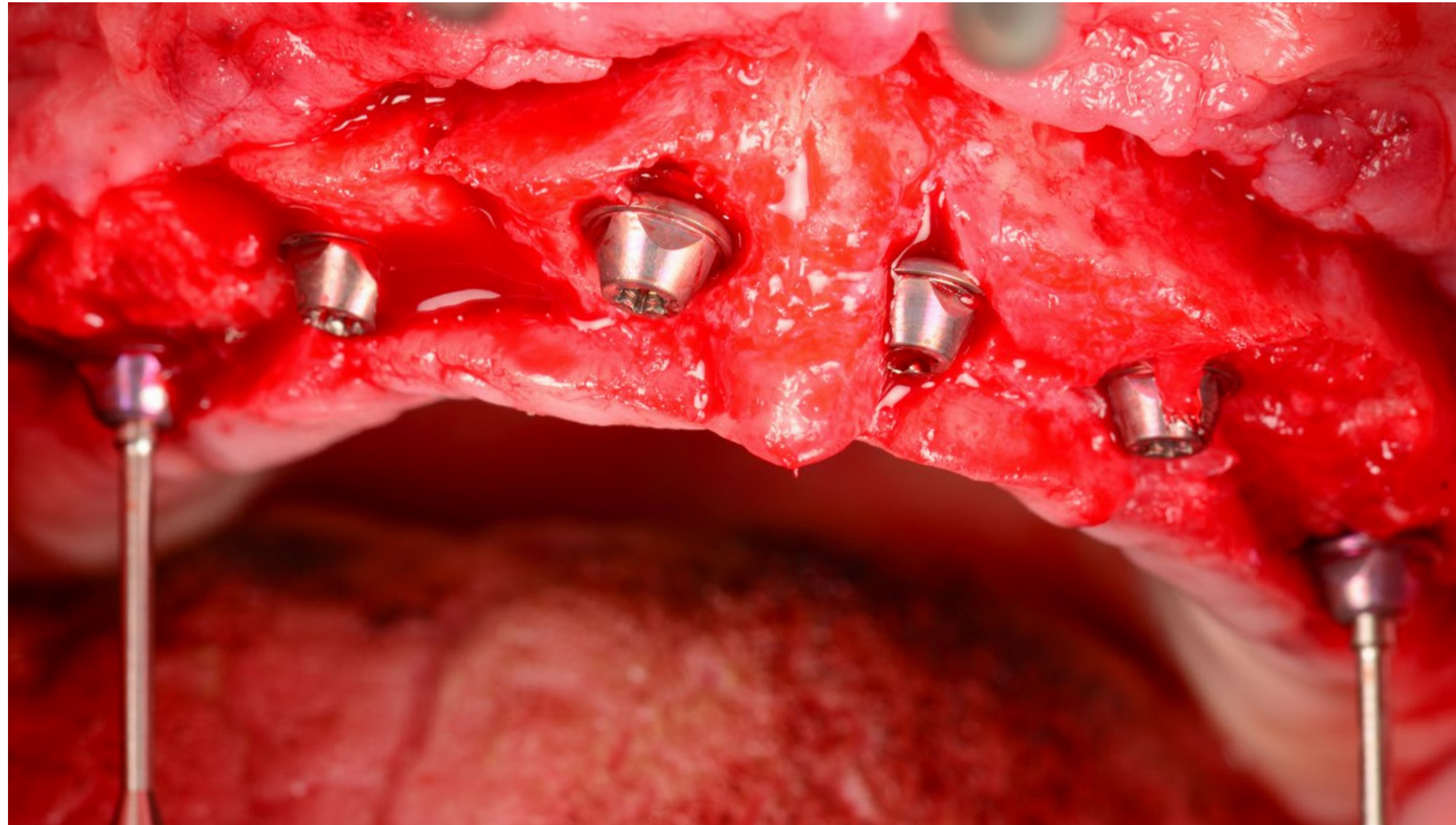


Placement of the Screw-retained Abutments

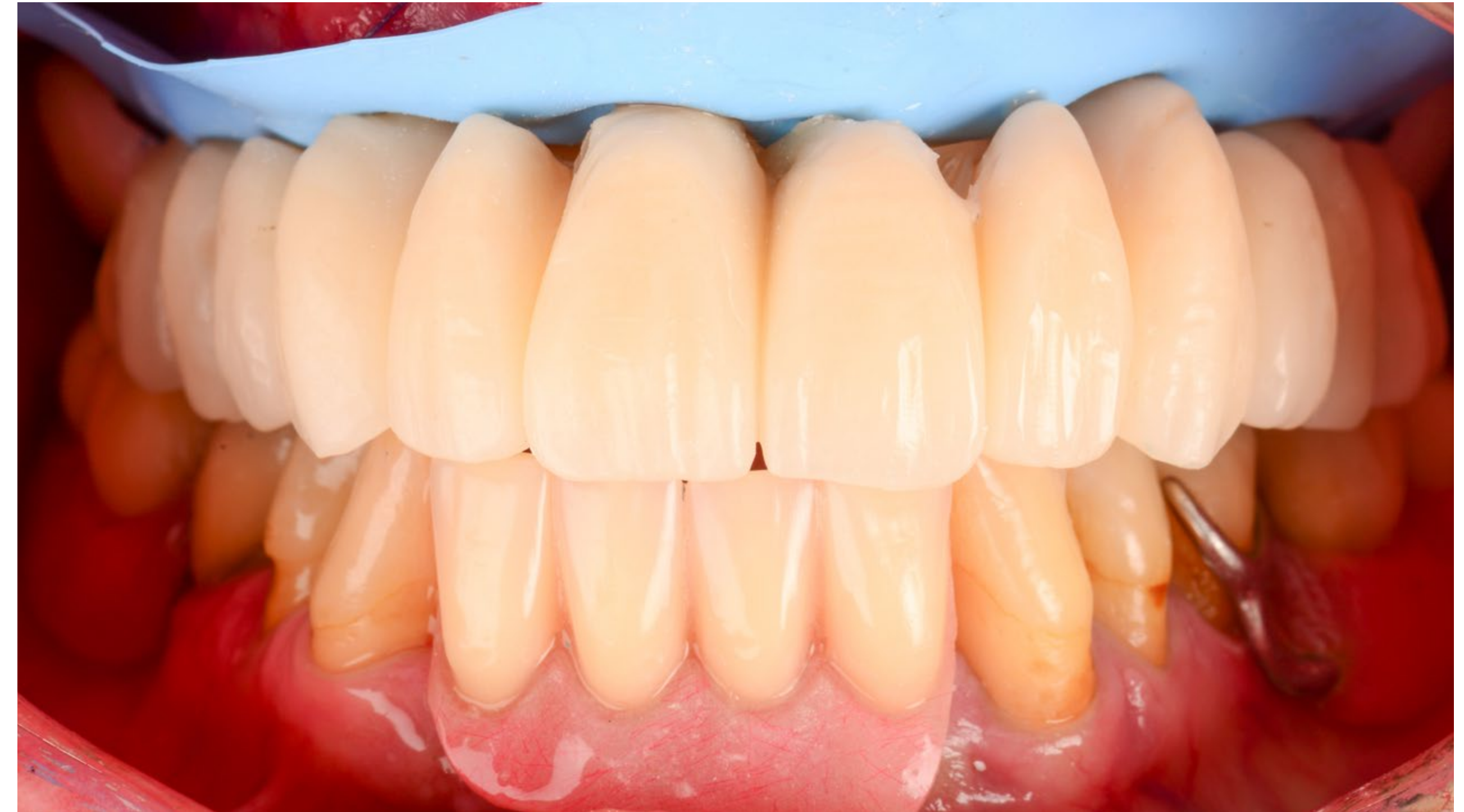

# Challenge 8: Strong muscular pattern

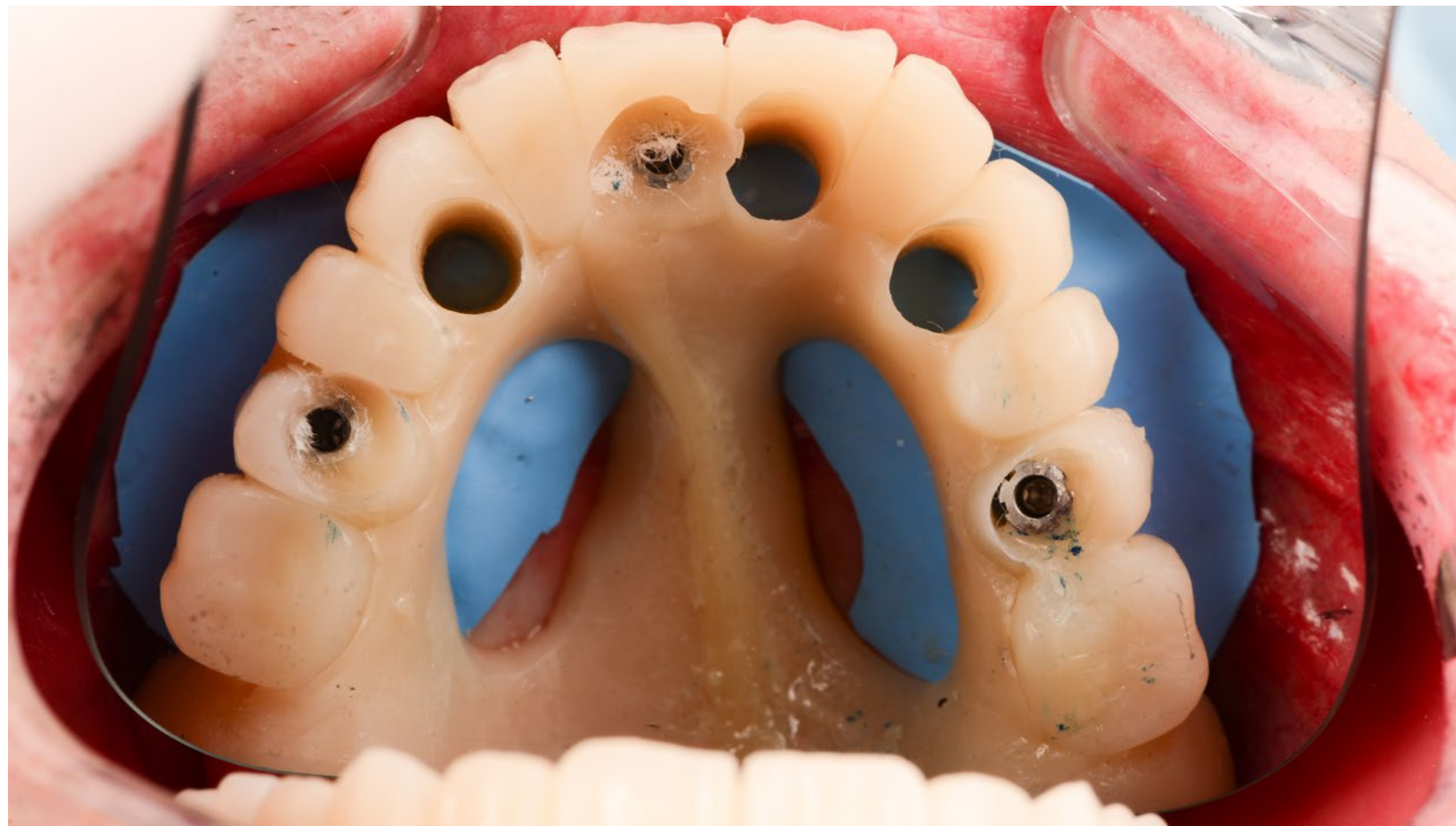
Clinical case



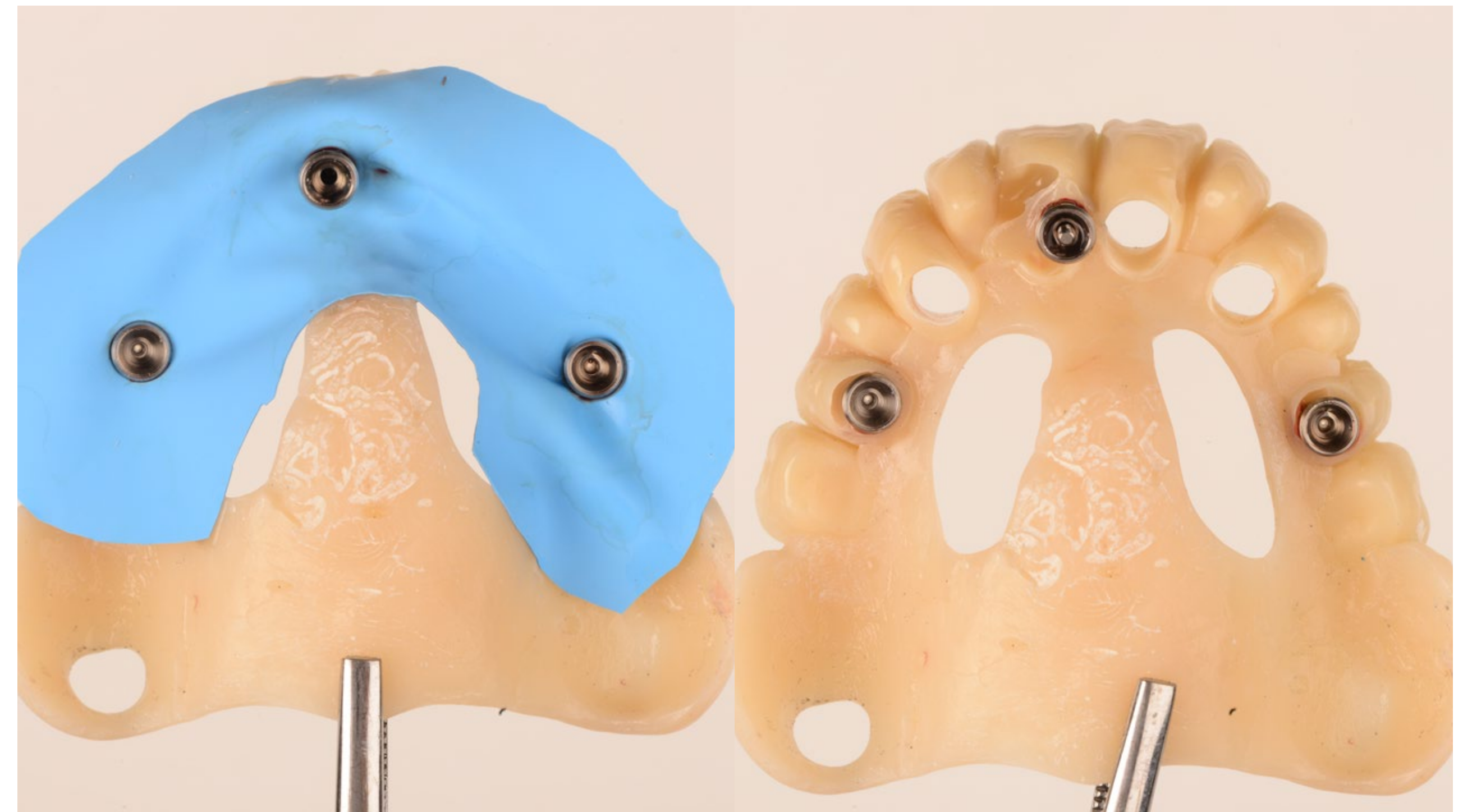Screw-retained Abutments in place



The CAD/CAM temporary restoration is positioned and connected to three implants to avoid any displacement during occlusion adjustment and registration



Connection of the CAD/CAM temporary restoration and occlusal adjustments

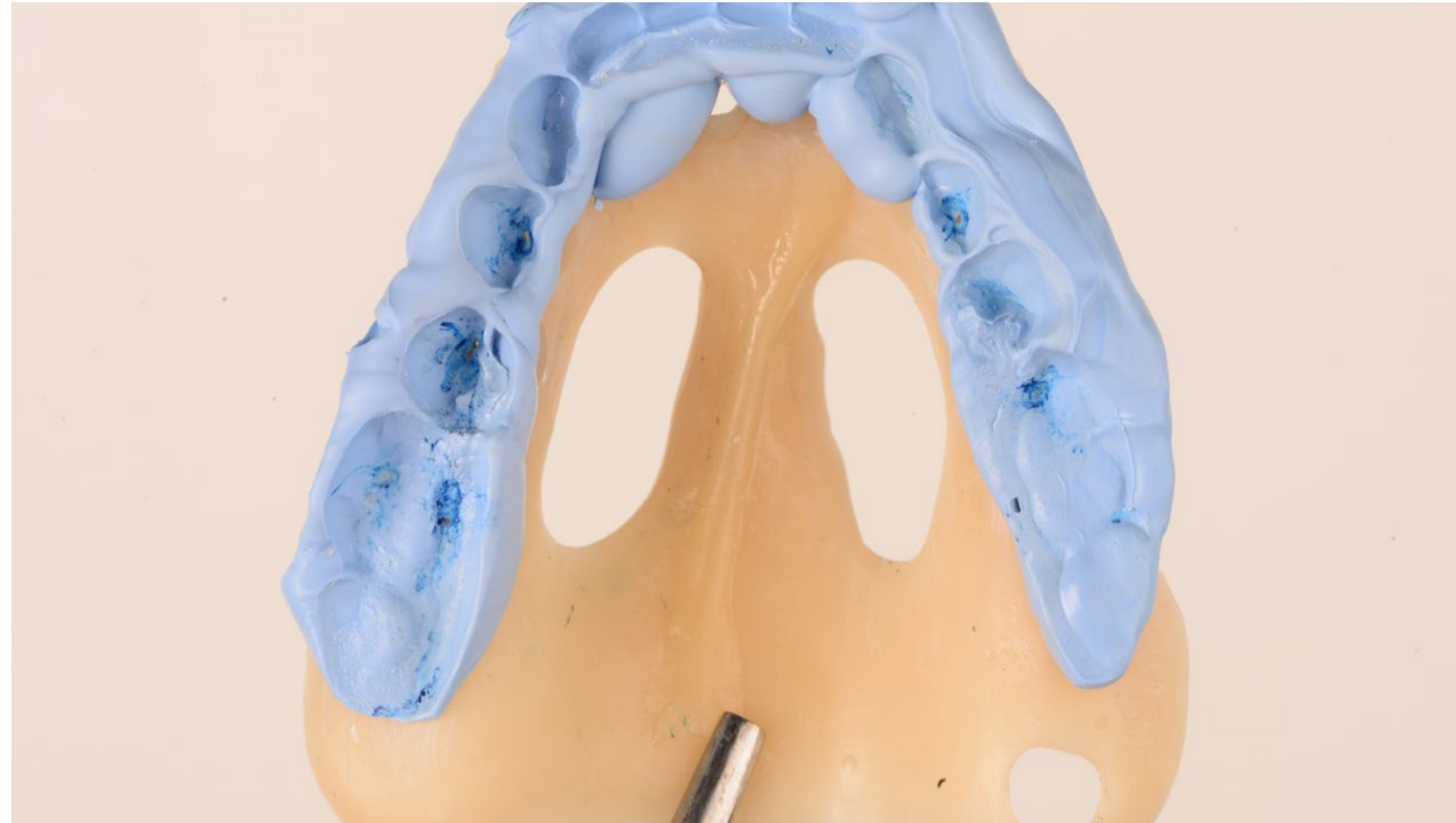


After the registration of the occlusion, the CAD-CAM temporary restoration is sent to the lab

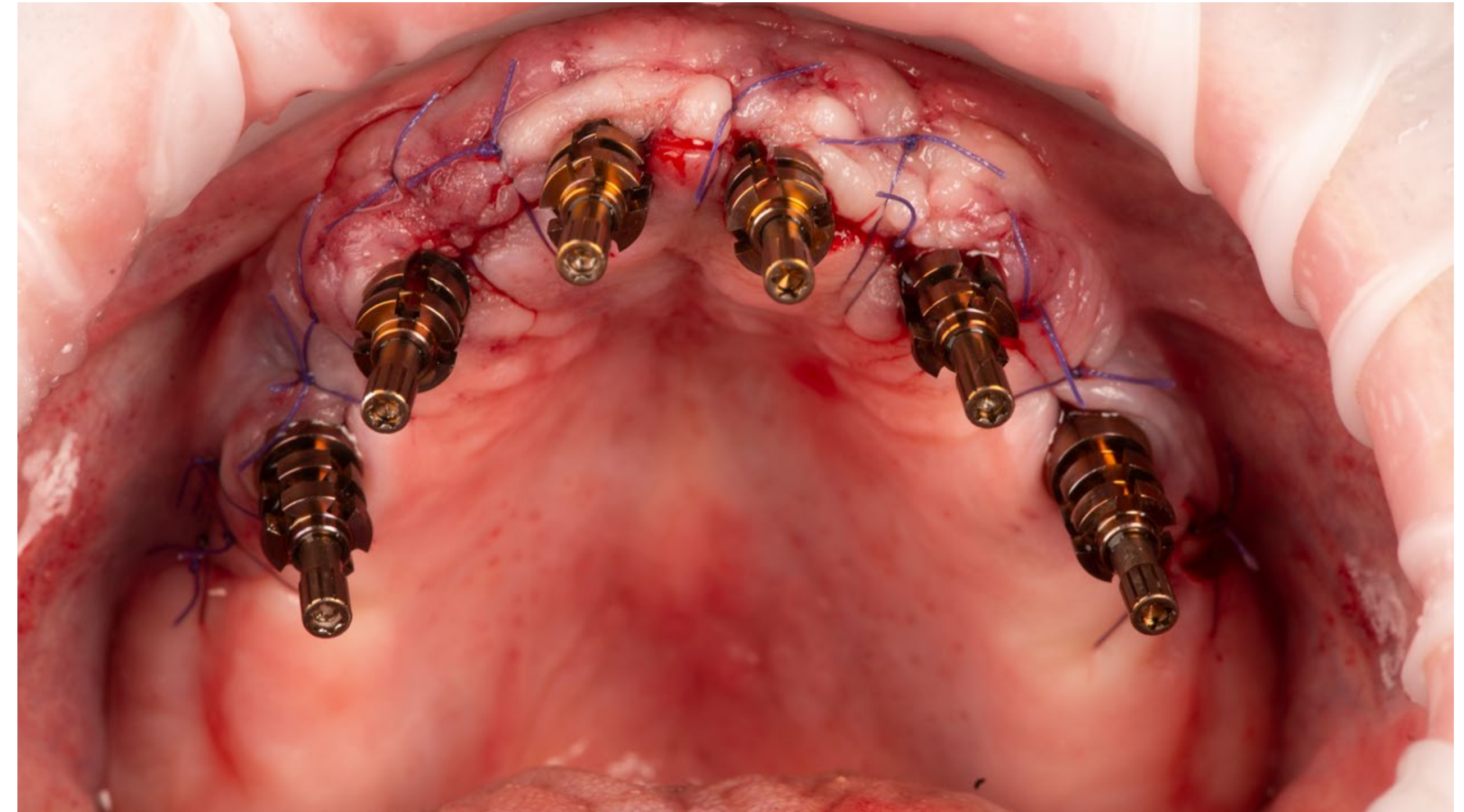


# Challenge 8: Strong muscular pattern

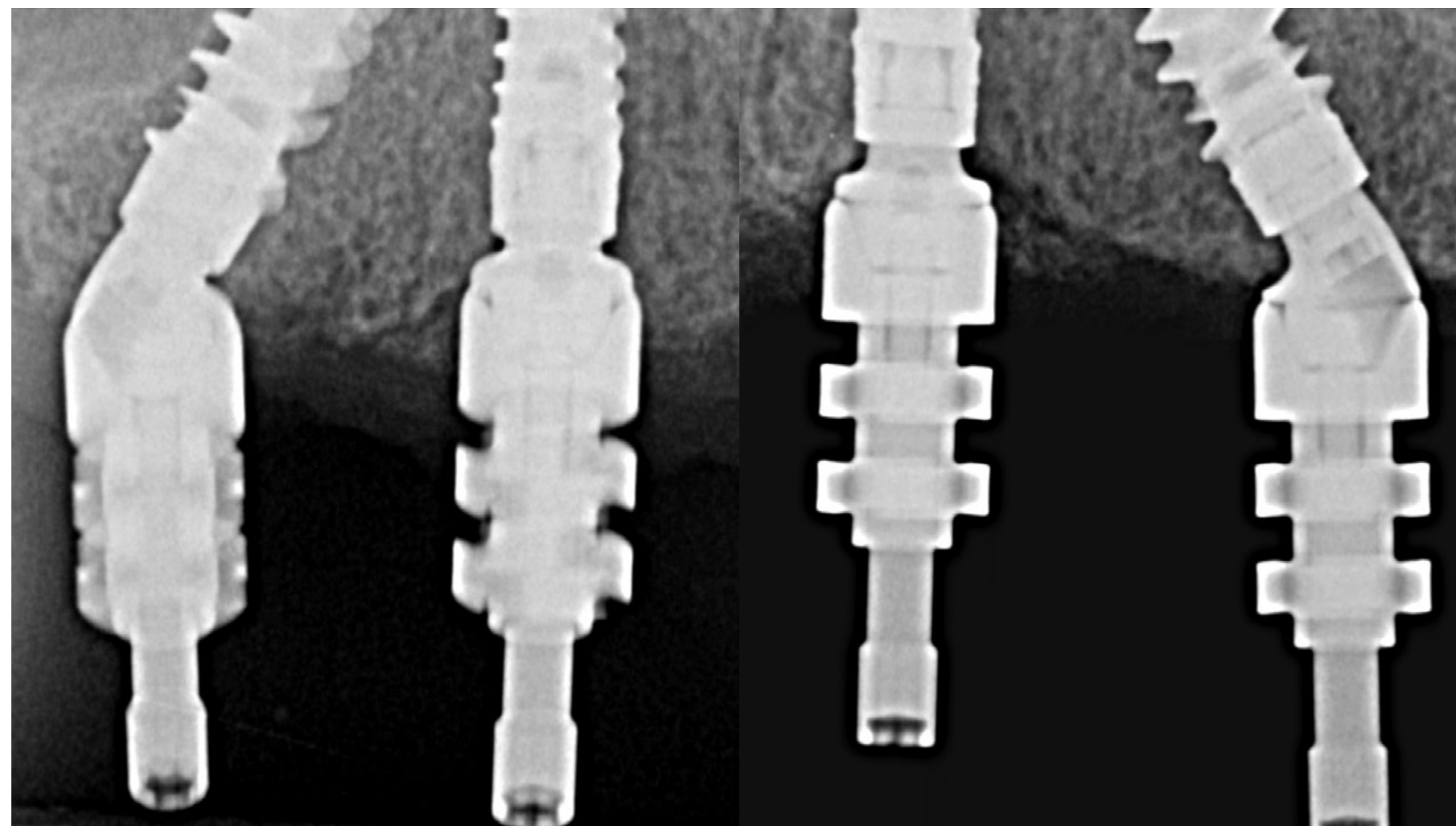
Clinical case



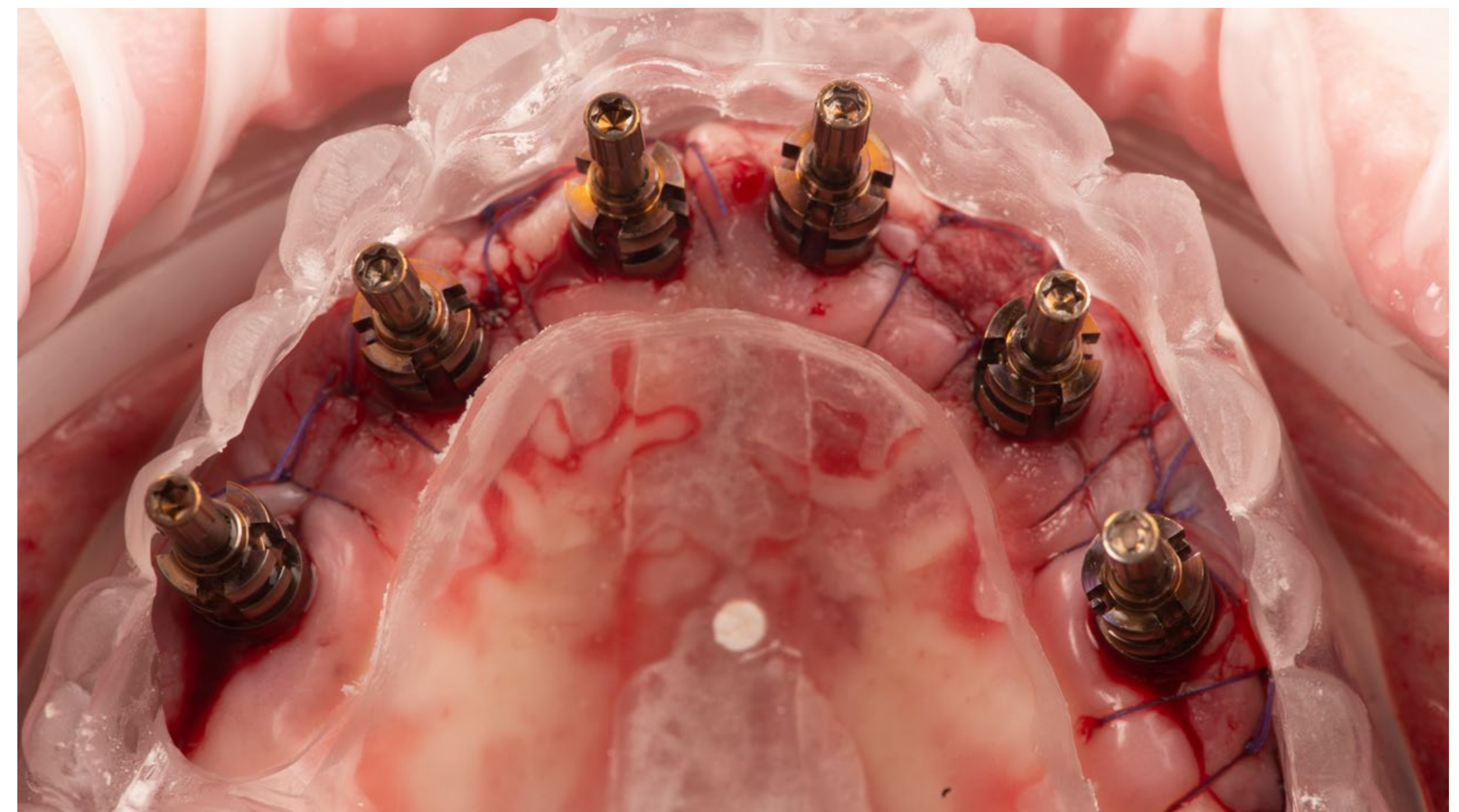
The occlusion is registered with silicone



Positioning of impression copings on Screw-retained Abutments



Postoperative x-rays  
On these two x-rays, the benefit of using slim and undercontoured Screw-retained Abutments to avoid any bony interferences is obvious

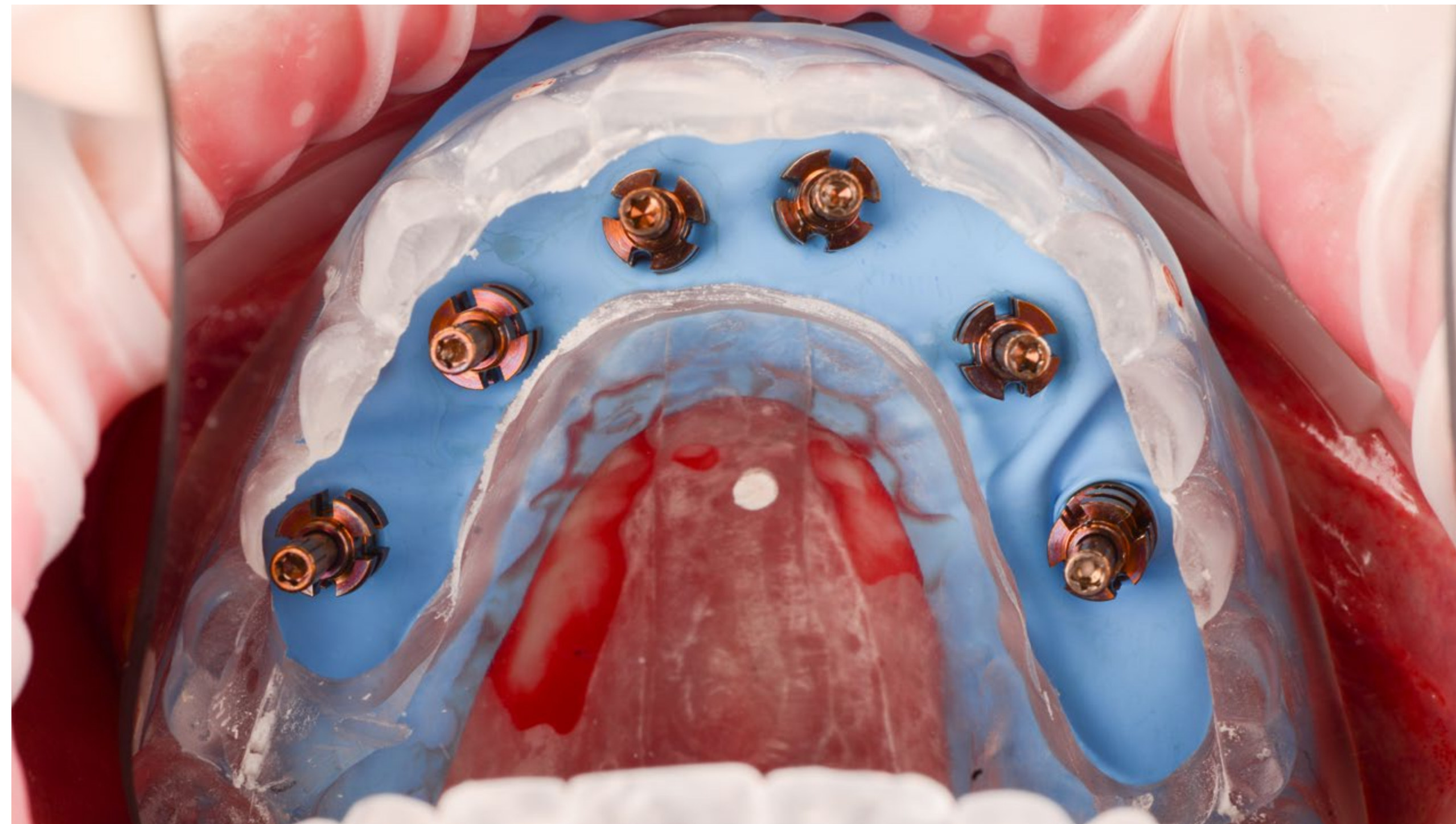


A customized tray (duplicate of the complete denture) is hollowed out at the implant sites to register the position of the implants

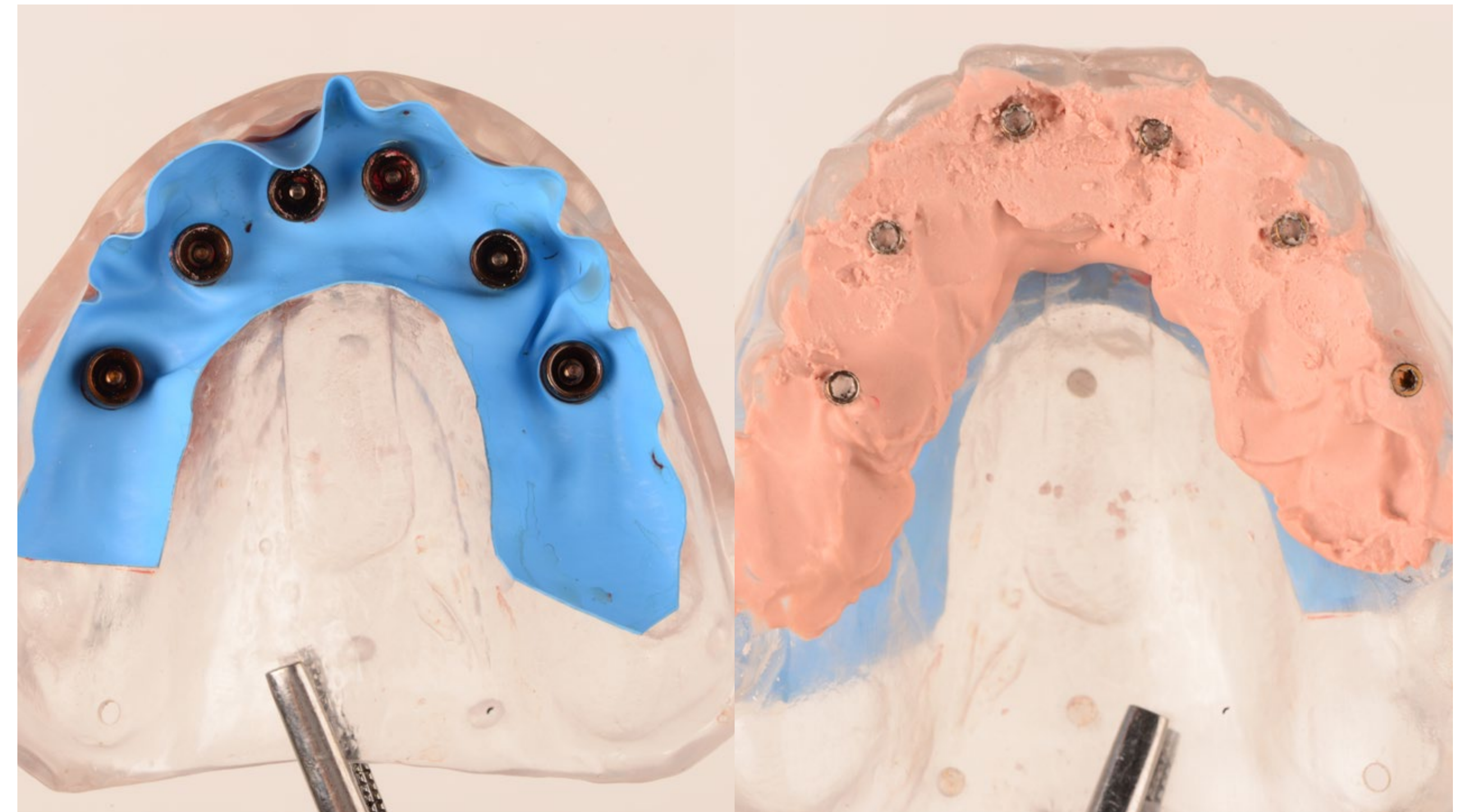

# Challenge 8: Strong muscular pattern

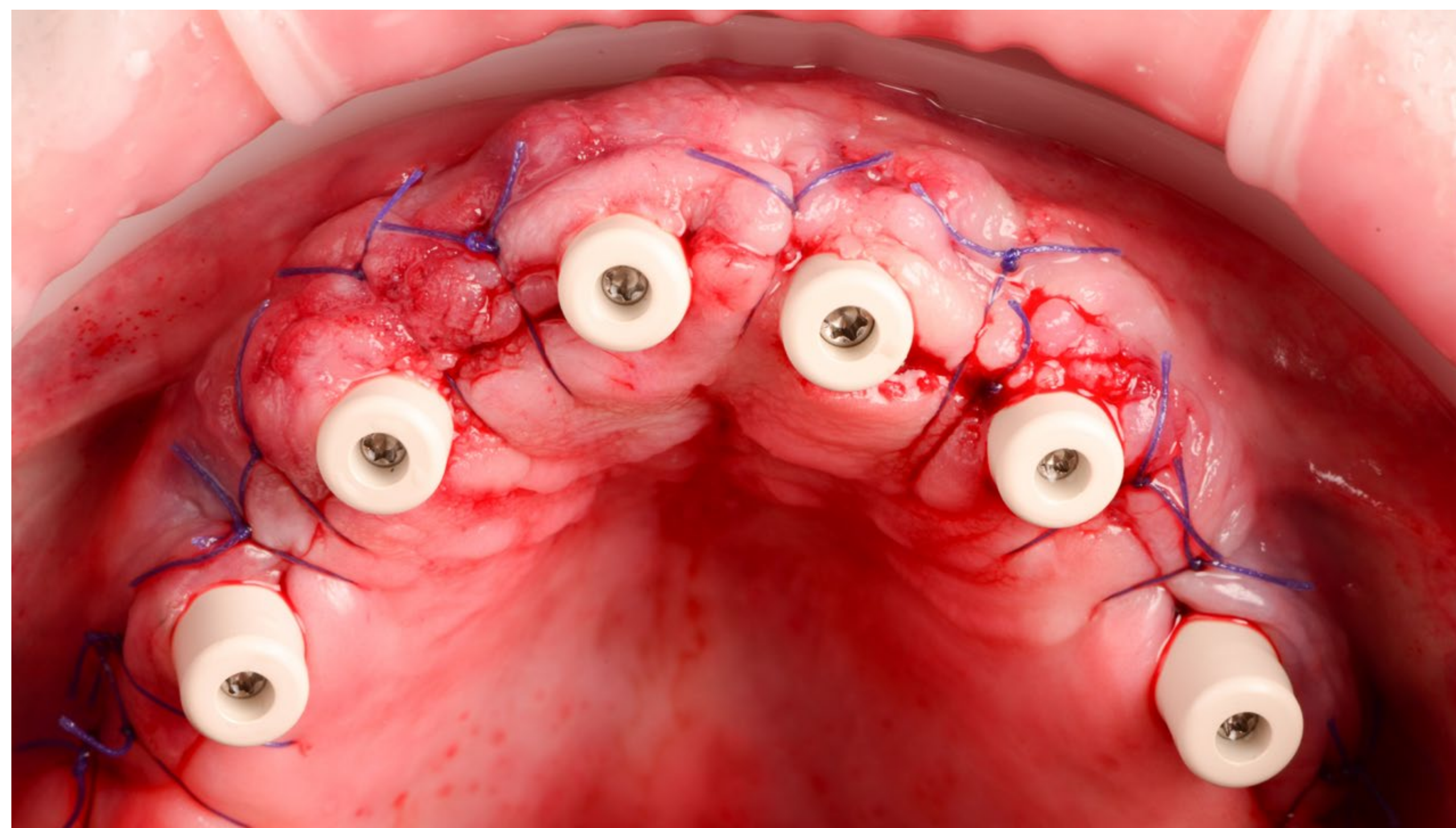
Clinical case



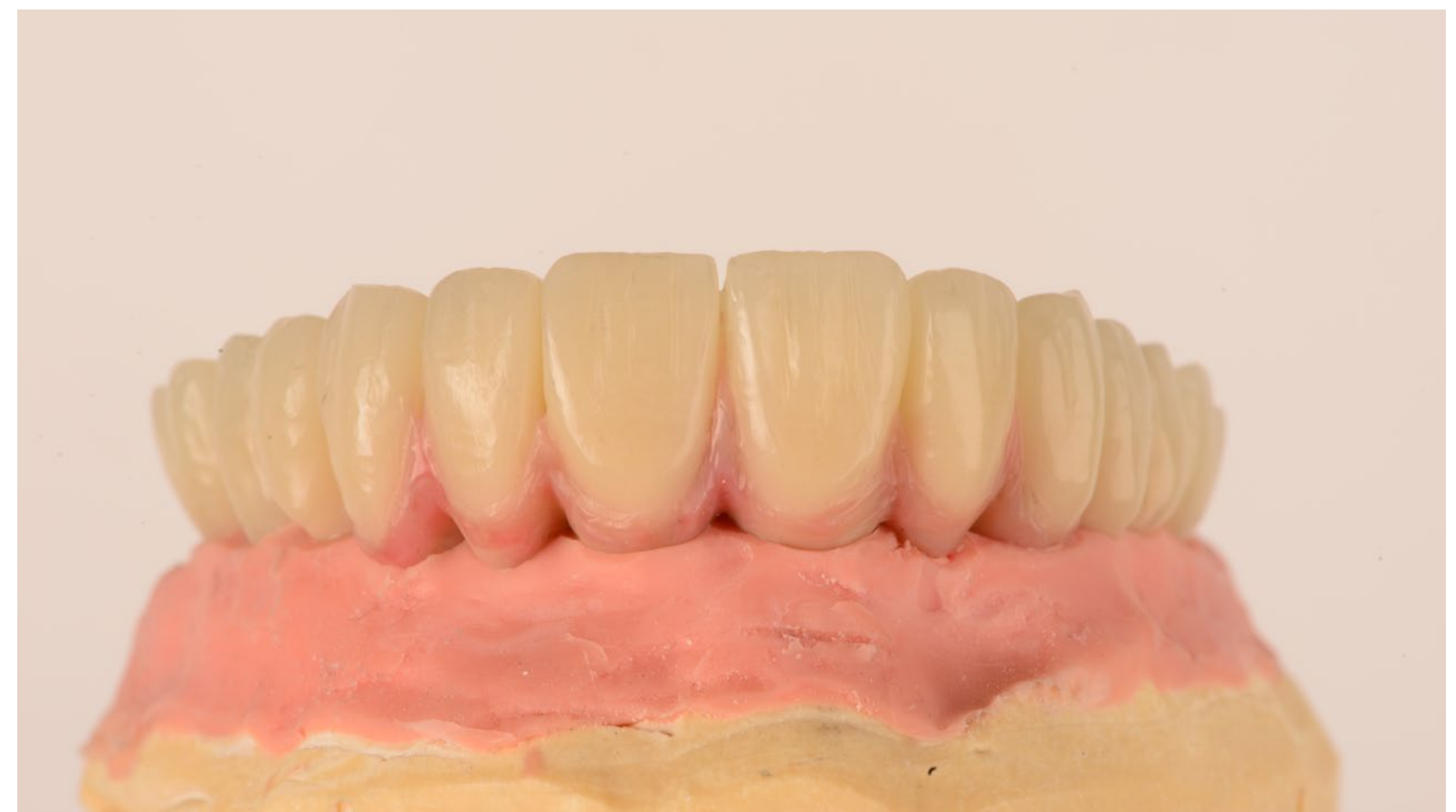A piece of rubber dam is used to isolate the surgical wound



Views of the inner and outer sides of the tray after impression taking with plaster



Postoperative condition

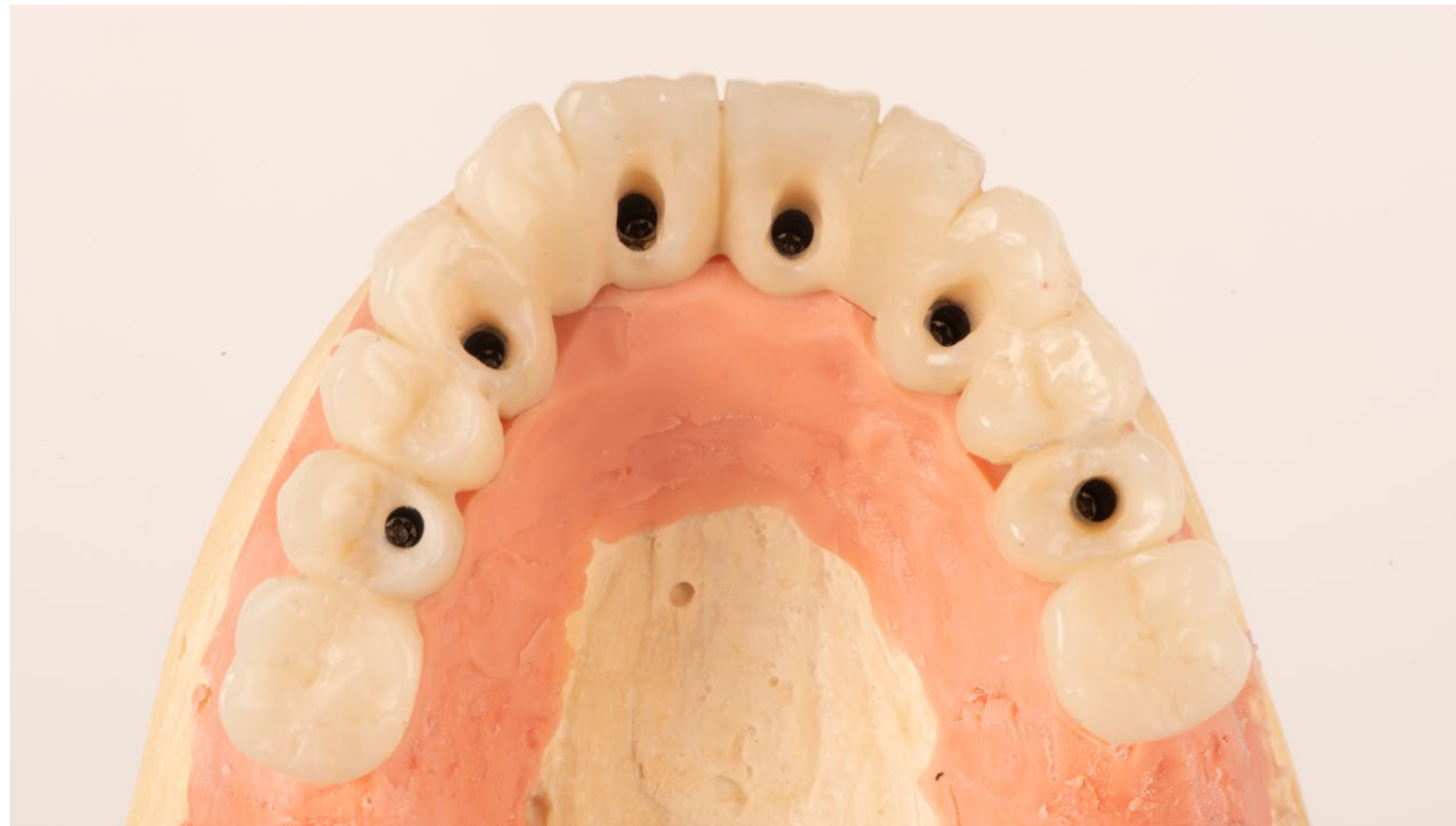

The CAD/CAM temporary restoration is connected to all the implants by the technician

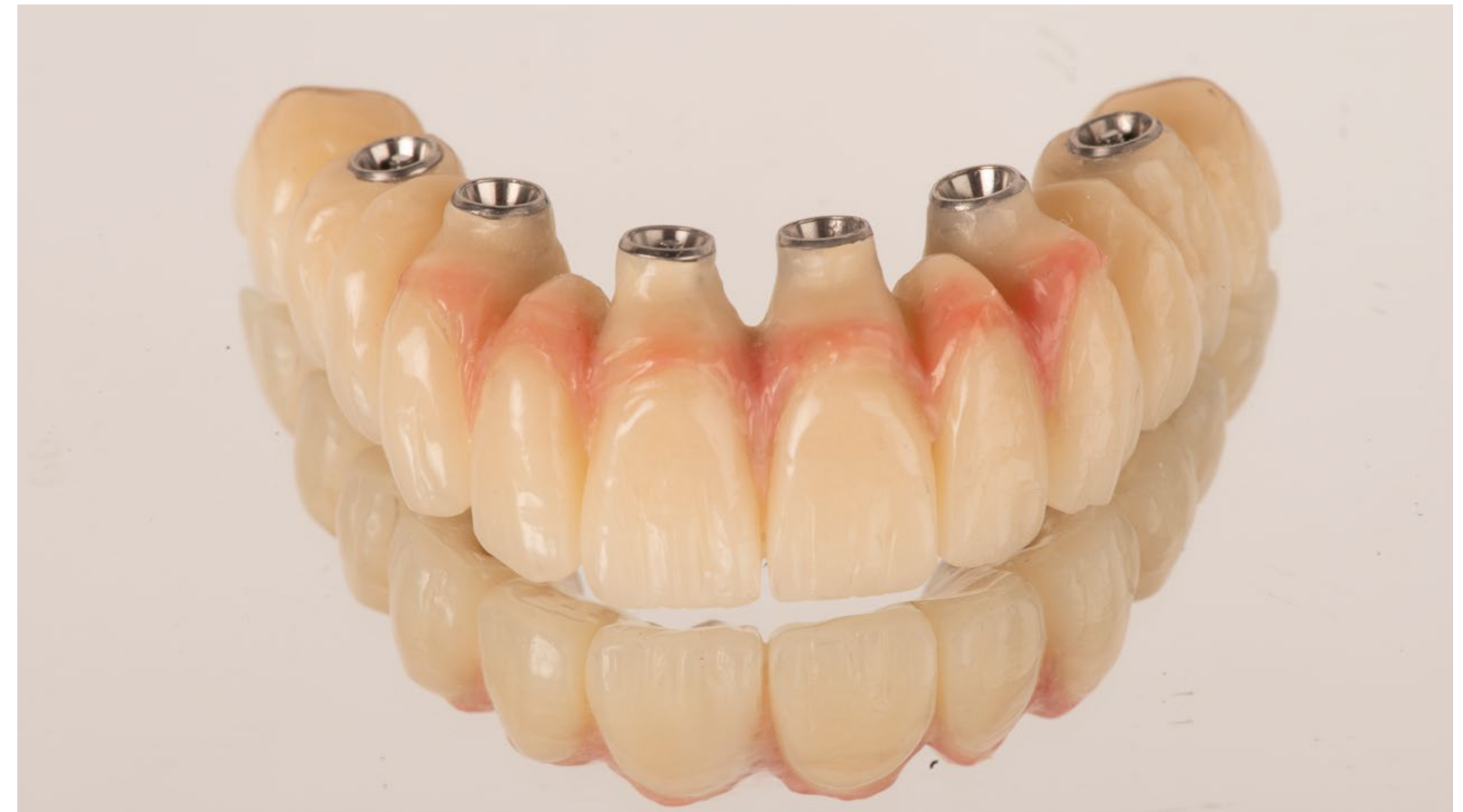

# Challenge 8: Strong muscular pattern

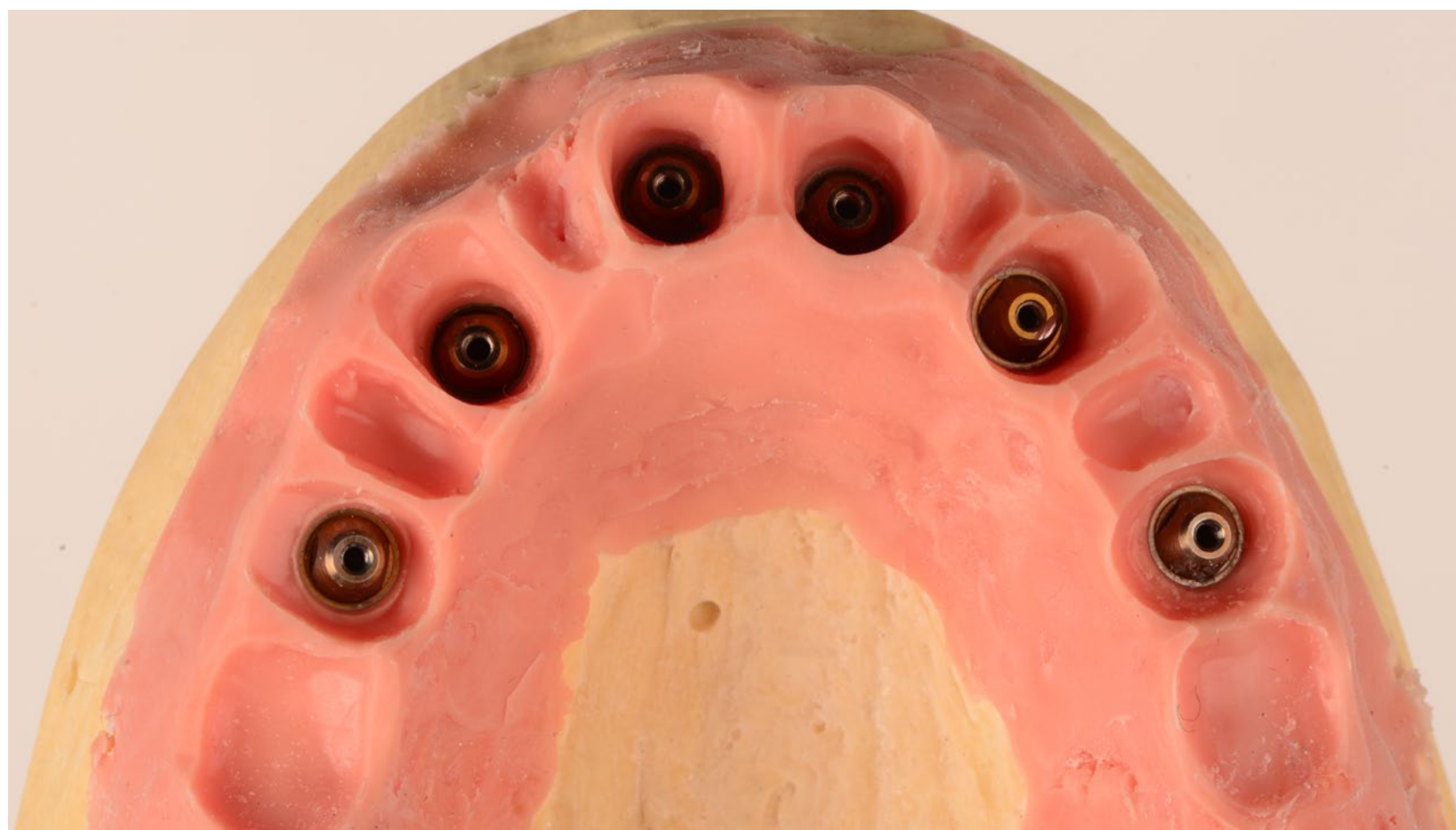Clinical case



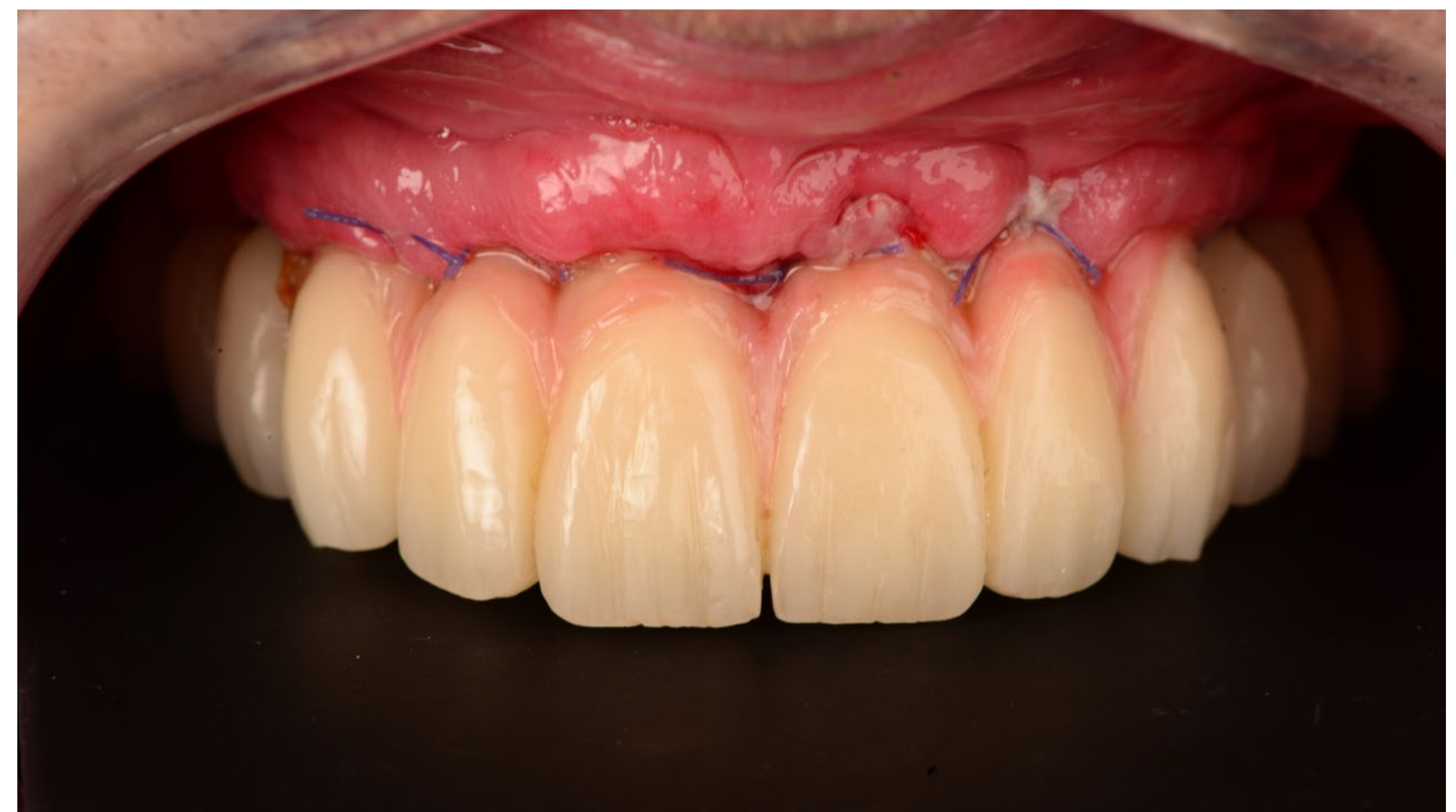Close-up of the CAD/CAM temporary restoration (Dental Technician: Julien Montenero)



Close-up of the CAD/CAM temporary restoration (Dental Technician: Julien Montenero)



Emergence profiles have been set up on the master model



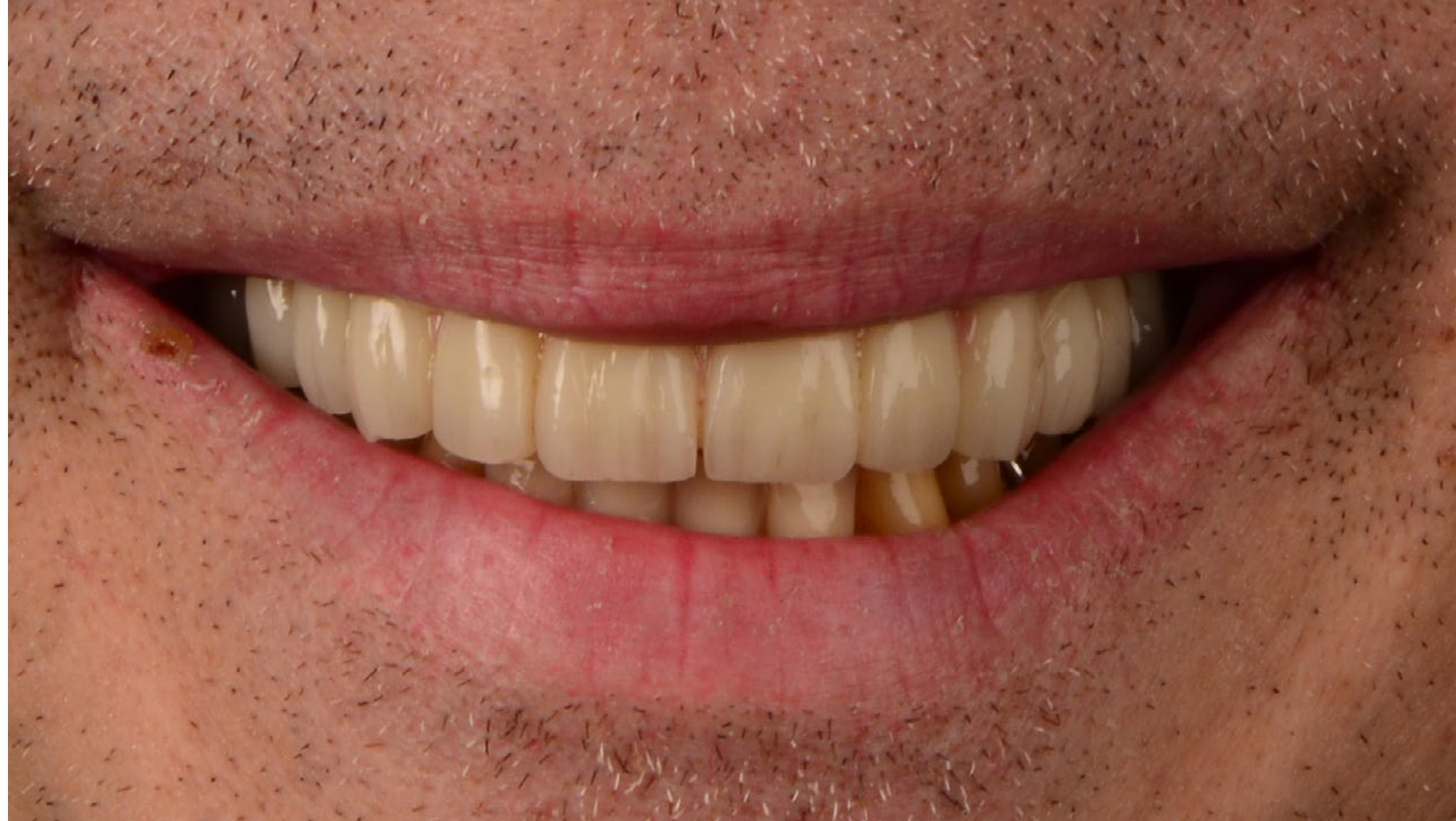Postoperative condition with the CAD/CAM temporary restoration fully seated



---

# Challenge 8: Strong muscular pattern

Clinical case



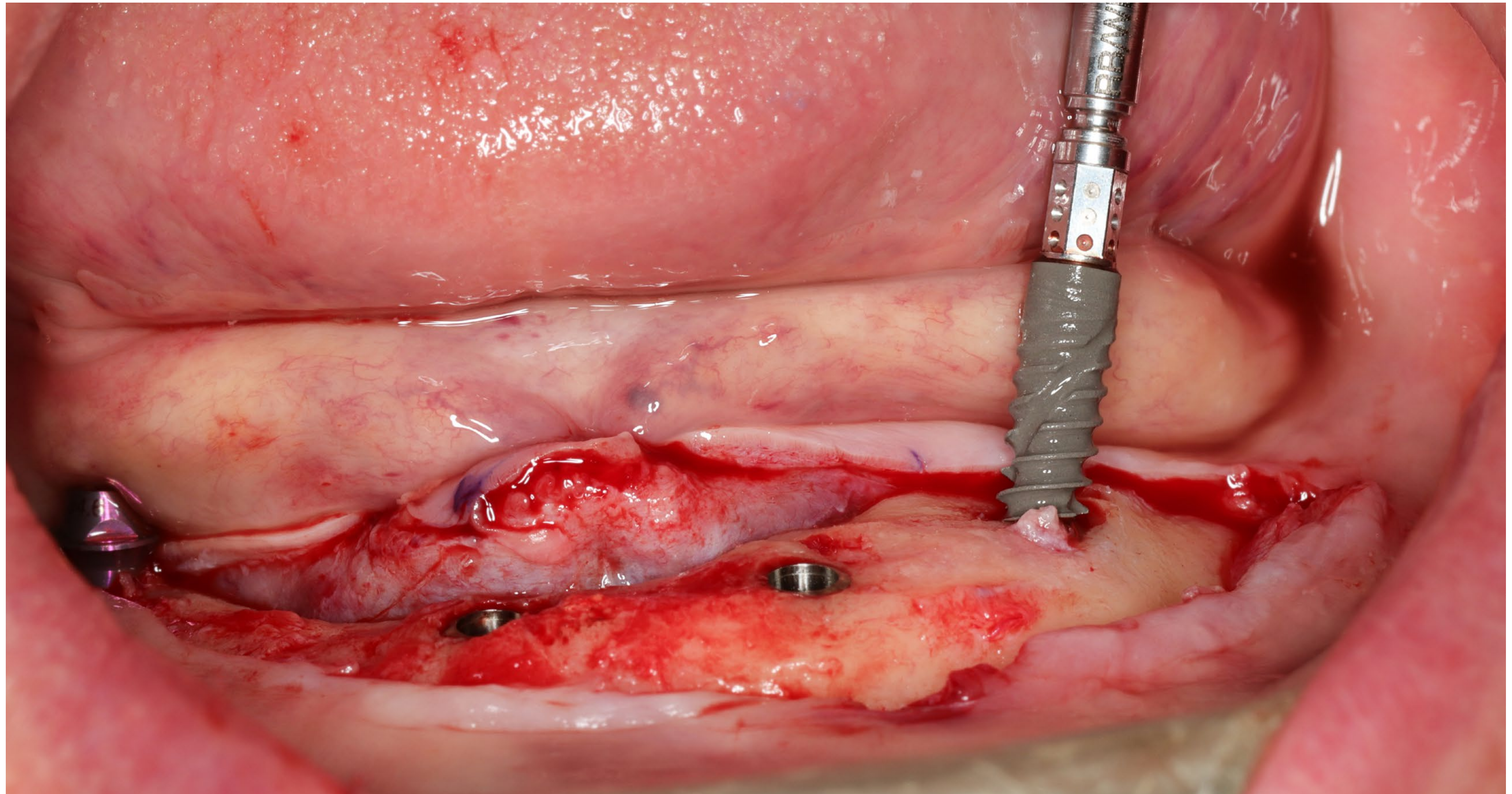
Postoperative clinical situation  
Final prosthesis will be placed six months after the surgery



# Challenge 9: Hard bone quality and insufficient bone availability



General recommendations and clinical case from Dr. Louwrens Swart and Dr. Paul Van Zyl





# Challenge 9: Hard bone quality and insufficient bone availability

## General recommendations



### General recommendations from Dr. Louwrens Swart and Dr. Paul Van Zyl

#### Hard bone:

- Regular osteotomy. Do not underprepare and keep the maximum torque below 50 Ncm. If a torque value above 50 Ncm is achieved before the final position is reached, two options are available:
  1. Reverse and forward the implant, using self-tapping properties to decrease the torque.
  2. Remove the implant, re-prepare the osteotomy to a wider diameter and re-seat the implant
- Implants with shallow threads
- Narrow implants

#### Posterior low bone availability:


- Fewer than five implants per jaw
- Tilting of the posterior implant

Dr. Swart received his degree from Stellenbosch University, Cape Town, South Africa, and his master's degree in MFOS in 1994. He has been in private practice in Cape Town since 1995, focusing on the immediate placement and loading of implants. He serves on the ambassadors' board of the EAO. He is an honorary consultant in dental implants in the department of MFOS, University of Western Cape (UWC). He serves on the faculty of gIDE and is a member of various dental and MFOS societies. Dr. Swart received Merit Awards for his contributions to implantology in 2008 and 2012.



**Dr. Louwrens Swart**  
BChD, MChD (MFOS),  
Private practice, Cape Town,  
South Africa

Dr. Paul van Zyl qualified as a prosthodontist from the University of Stellenbosch in 1992. He has been involved in postgraduate implant teaching since 1998 and is currently Chair of the ITI Section Southern Africa. He has participated in ITI Consensus Conferences, is an author of ITI Speaker Library modules and contributed to the creation of content for the ITI Online Academy. He serves on the executive committee of the South African Association of Osseointegration.



**Dr. Paul Van Zyl**  
BChD, MChD (Prost)  
Private practice Cape Town,  
South Africa

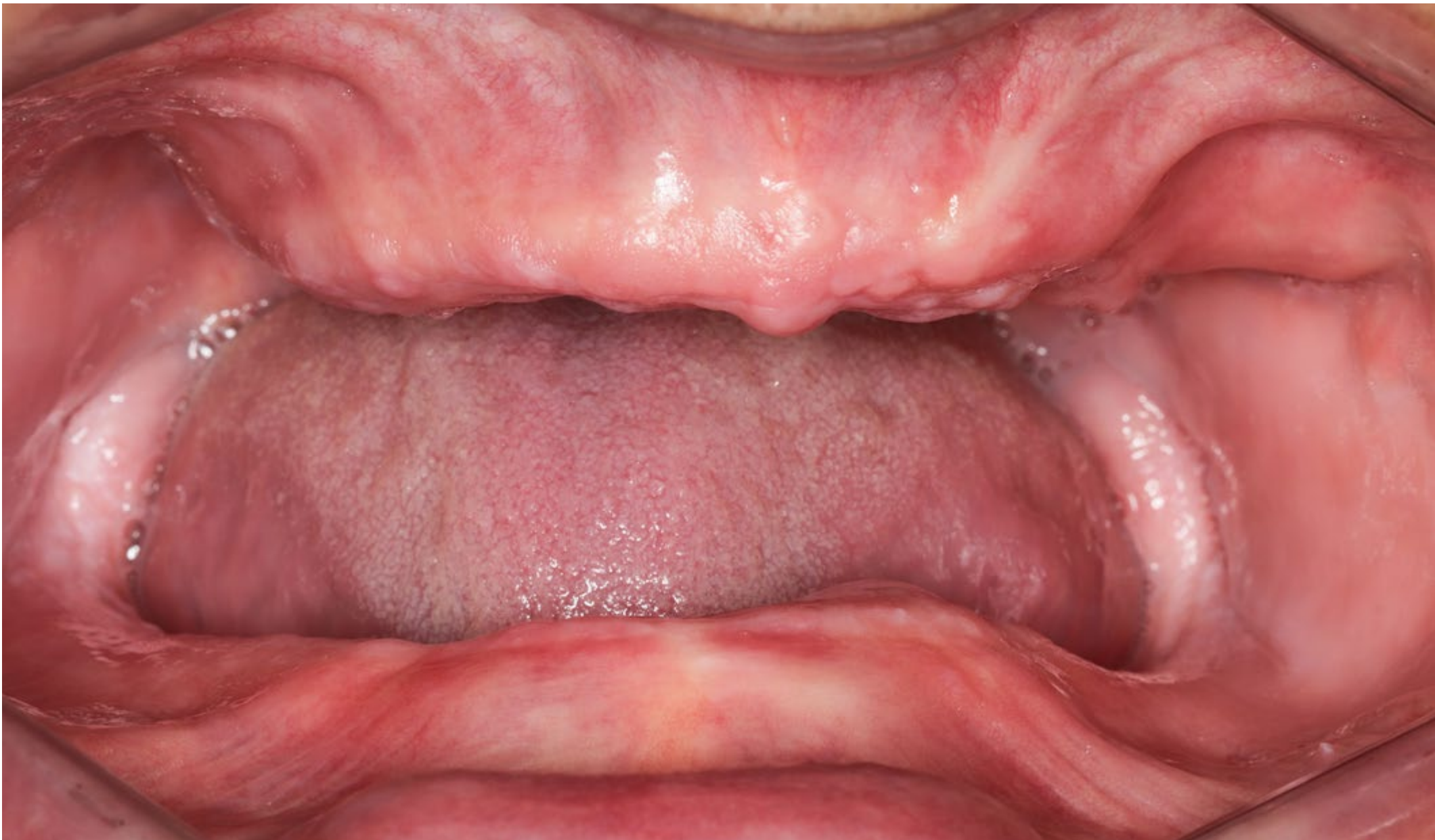

# Challenge 9: Hard bone quality and insufficient bone availability



Clinical case

## Initial situation



## Patient information

Age	55
Jaw	Mandible
Health status	Good
Height of smile line	Low
Bone type	Hard
Infections at implantation site	No
Bone anatomy defects	Normal
Risks	Nerve injury

## Additional difficulties

Severe resorption in the posterior area
Anterior inferior alveolar nerve loop in the area of 34/35
Bruxing habit

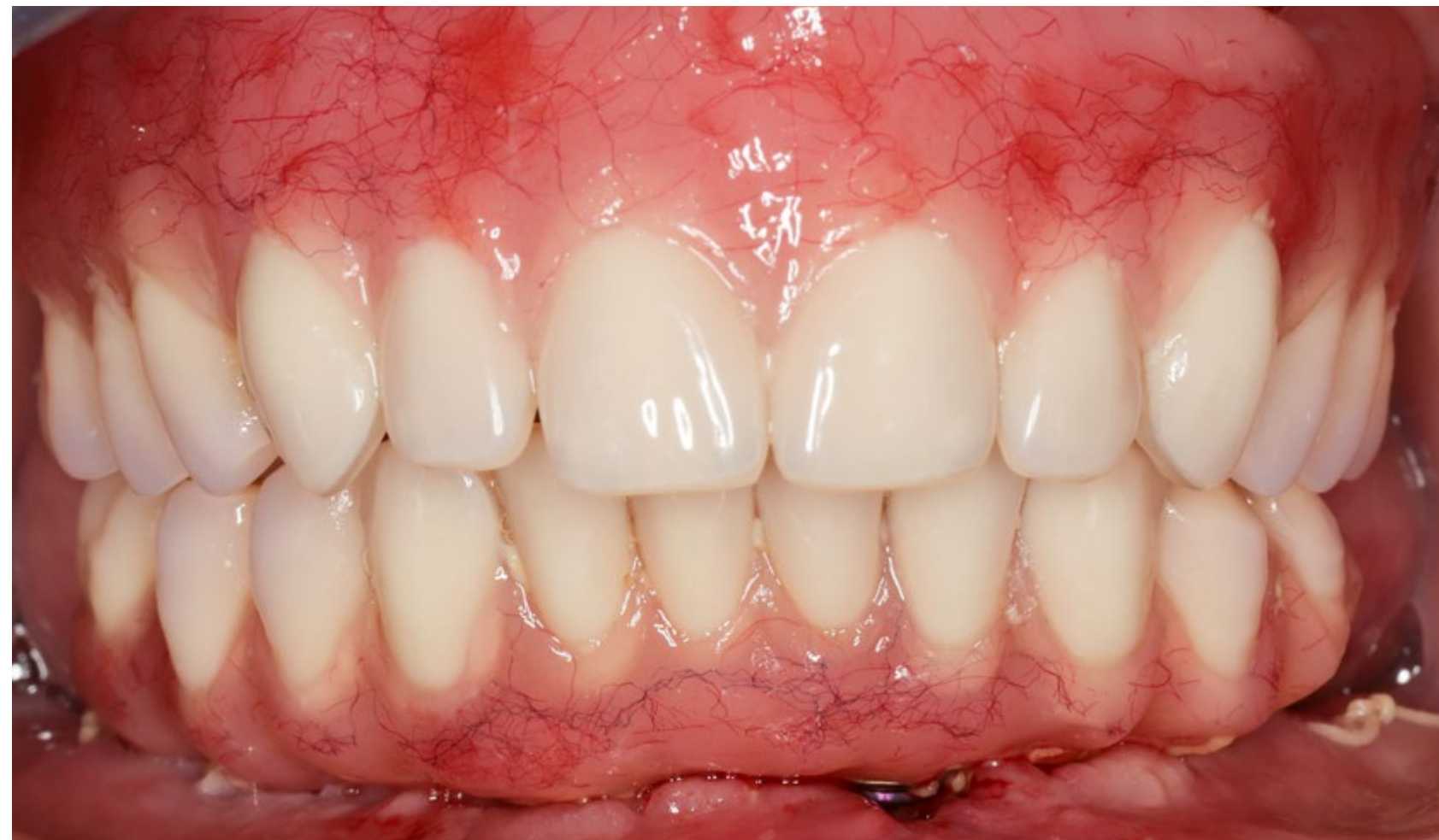

# Challenge 9: Hard bone quality and insufficient bone availability

Clinical case



## Provisional prosthesis



## Treatment

- Fixed immediate rehabilitation on four implants
- The height of bone in the third quadrant did not allow an implant larger than 4 mm in the 36 position. The presence of an anterior inferior alveolar nerve loop in the area of 34/35 did not allow for a straight implant at this site. Placing a tilted implant in the area of 35 was therefore indicated.
- Cantilevers were minimized or eliminated with implant spread

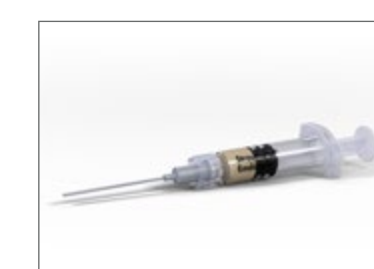**Temporary restoration:** acrylic provisional prosthesis

**Planned final prosthesis:** Straumann® Cares® titanium CAD/CAM bar, Ivoclar acrylic teeth processed with Lucitone® acrylic

## Materials used



Straumann® BLX Ø 3.75 mm  
RB SLActive® 10 mm, Roxolid®



Straumann® Emdogain®



Screw-retained abutments,  
straight, GH 2.5 mm  
Screw-retained abutments,  
30° angled GH 4.5 mm



# Challenge 9: Hard bone quality and insufficient bone availability

Clinical case



## Our experience



Dr. Louwrens Swart  
BChD, MChD (MFOS),

*“According to the latest consensus guidelines, straight and tilted implants have similar success rates. Thus, the question should not be between straight or tilted, but rather what optimal position can be achieved to shorten or eliminate a cantilever in the best interests of patient care. The BLX implant, 10 mm in length, is sufficiently strong (Roxolid®) with the added strength of the TorcFit™ to confidently use this option for long-term stability.”*



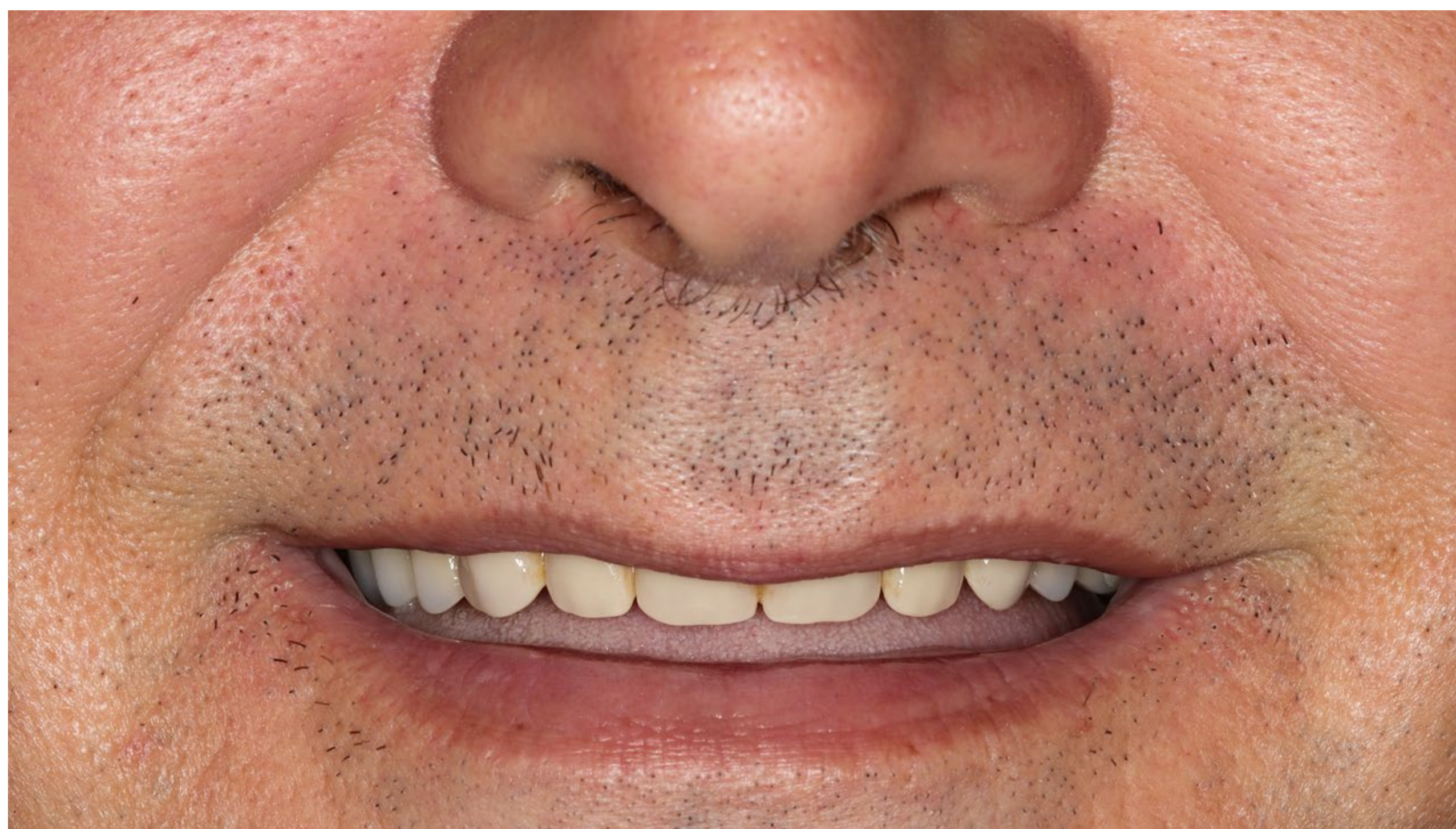Dr. Paul Van Zyl  
BChD, MChD (Prost)

*“Connection of the screw-retained abutments during surgery is very helpful to create a levelled and close to parallel prosthodontic platform. This also ensures that angled abutments path of insertion is not restricted by bone, especially to the mesial of distally angulated implants. Preoperative planning and creating the surgical guide is imperative to have the emergence of these abutments within the occlusal arch. This guide then also facilitates with the impressions and bite registration immediately after surgery.»*

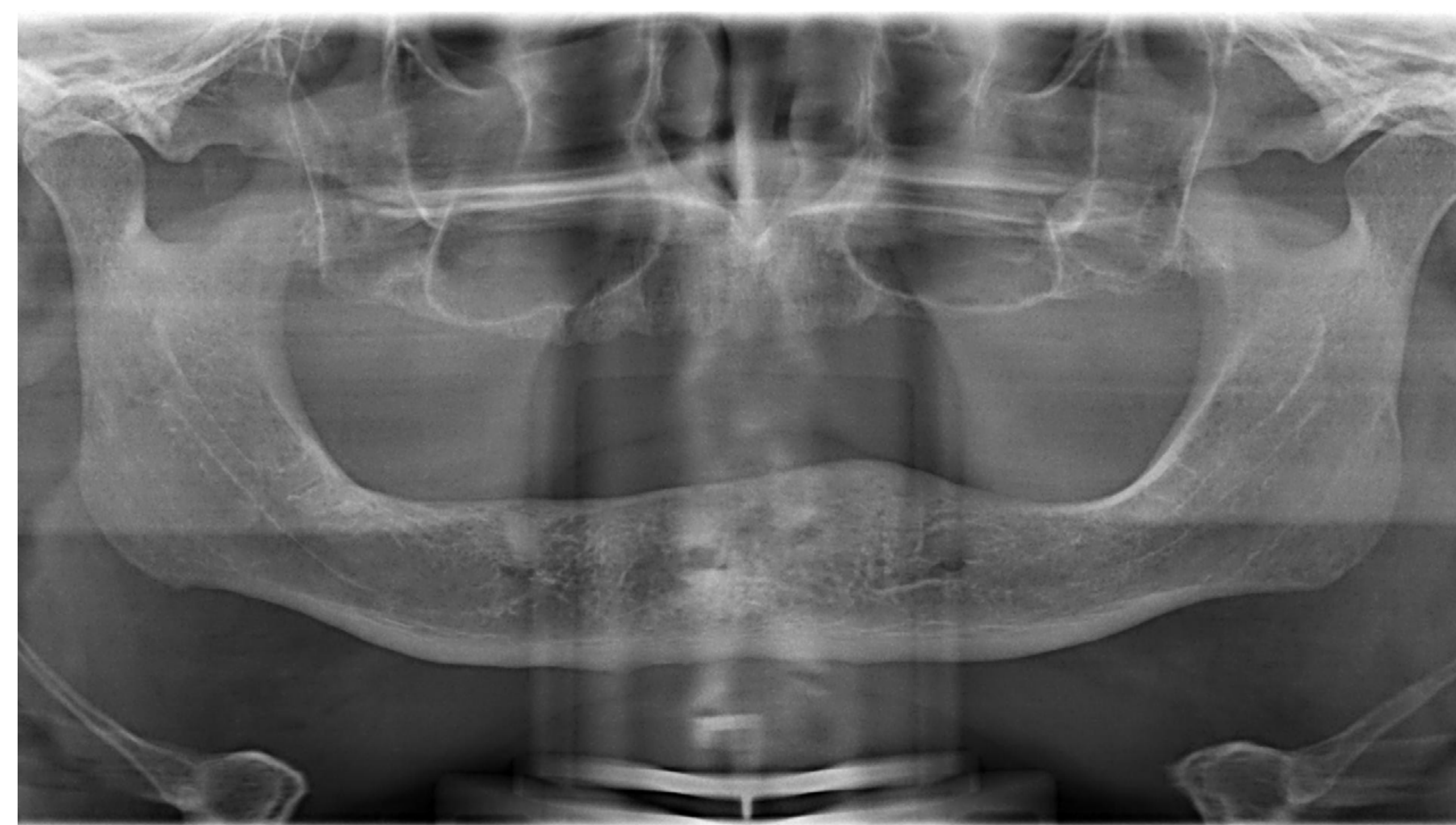


# Challenge 9: Hard bone quality and insufficient bone availability

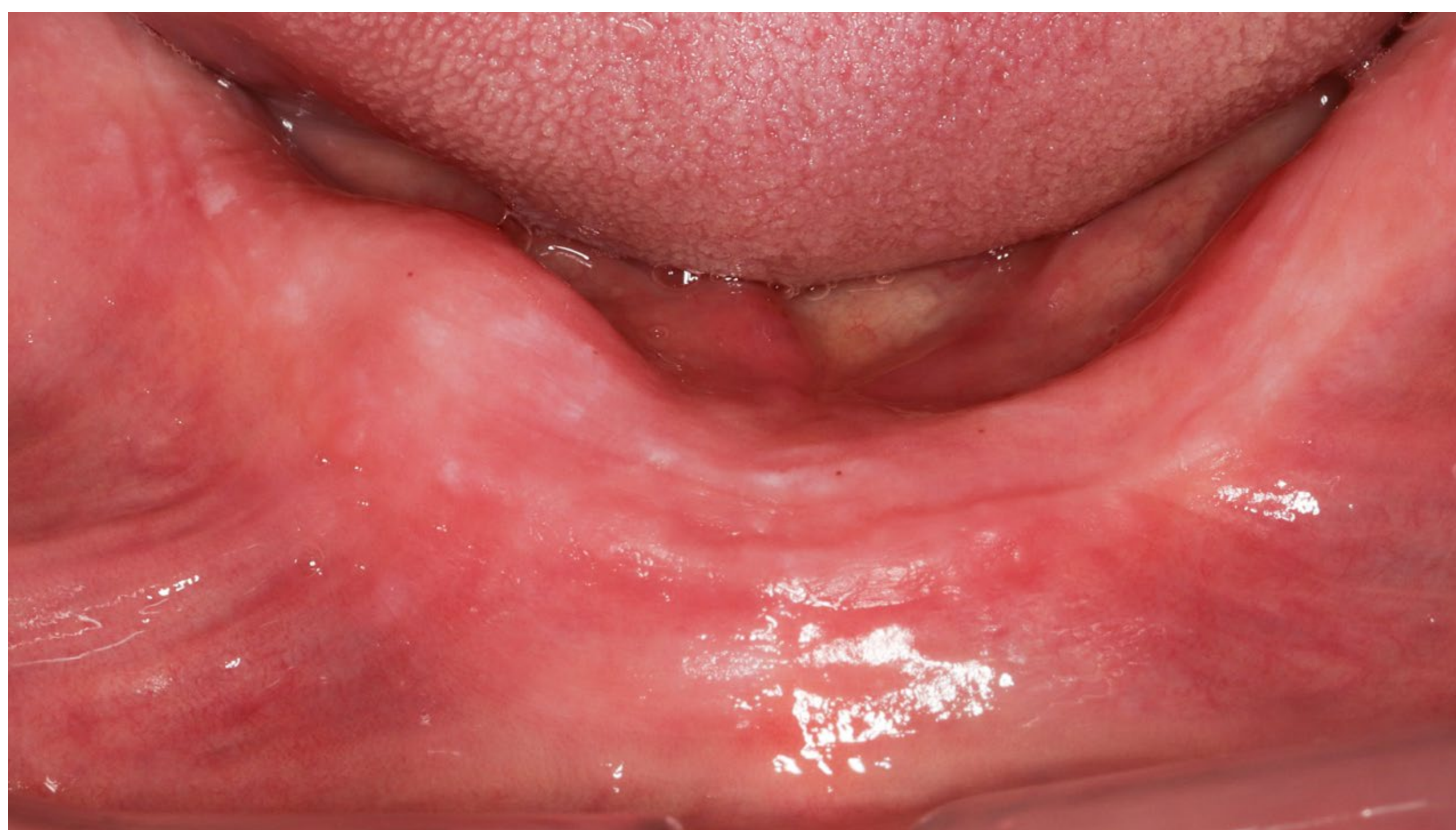Clinical case



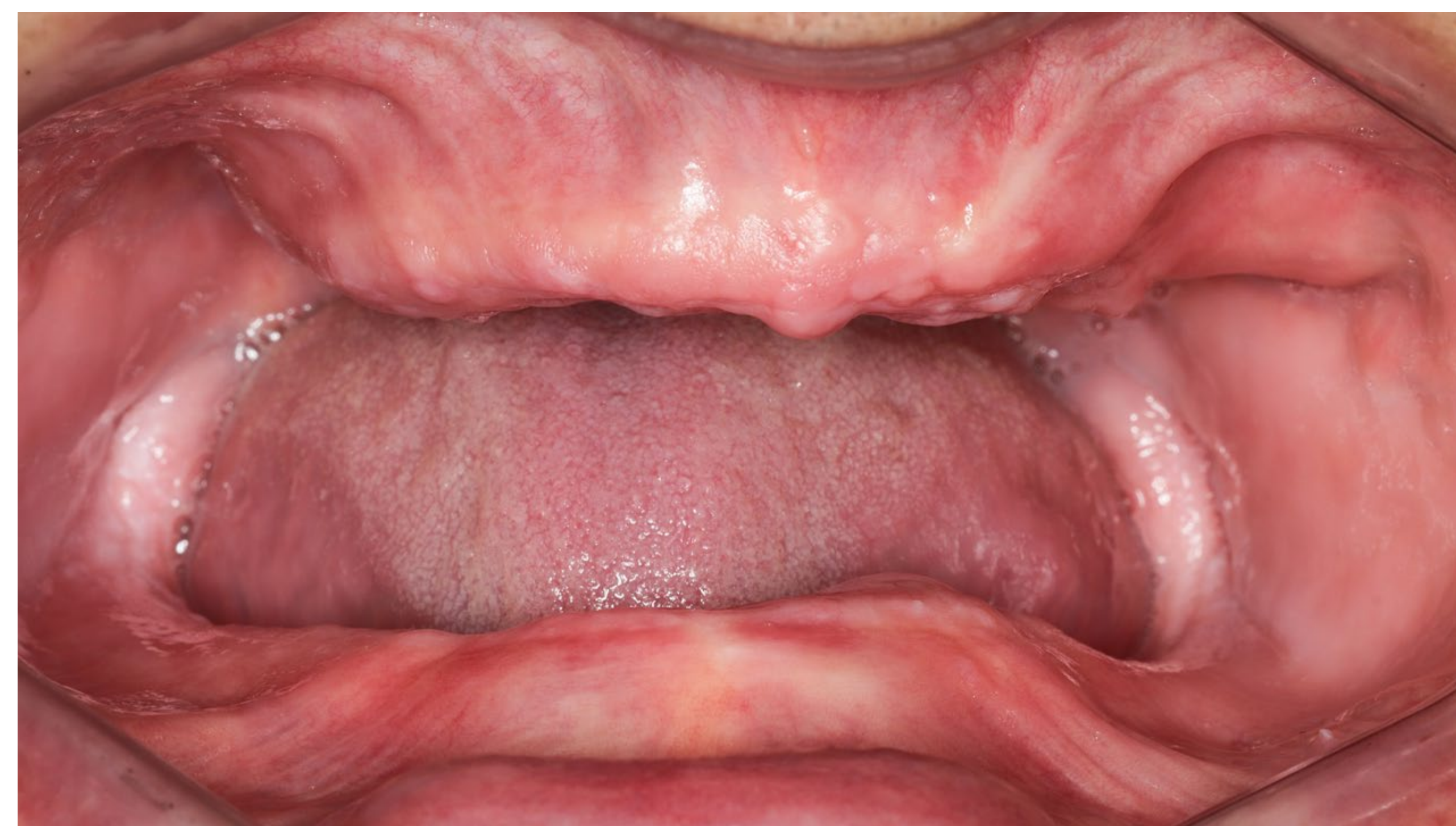Initial clinical situation



Preoperative panoramic radiograph



Initial clinical situation

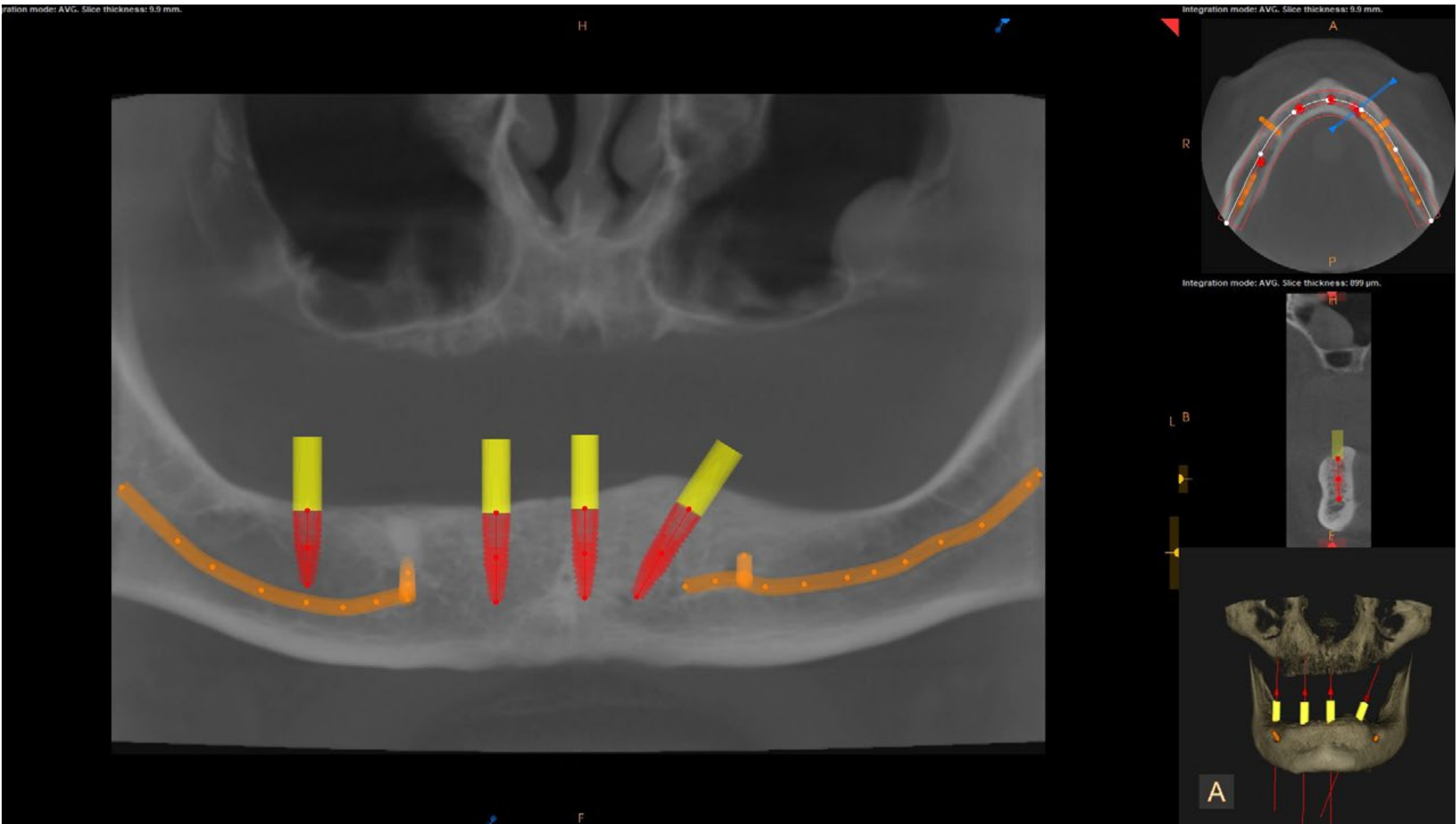


Frontal view

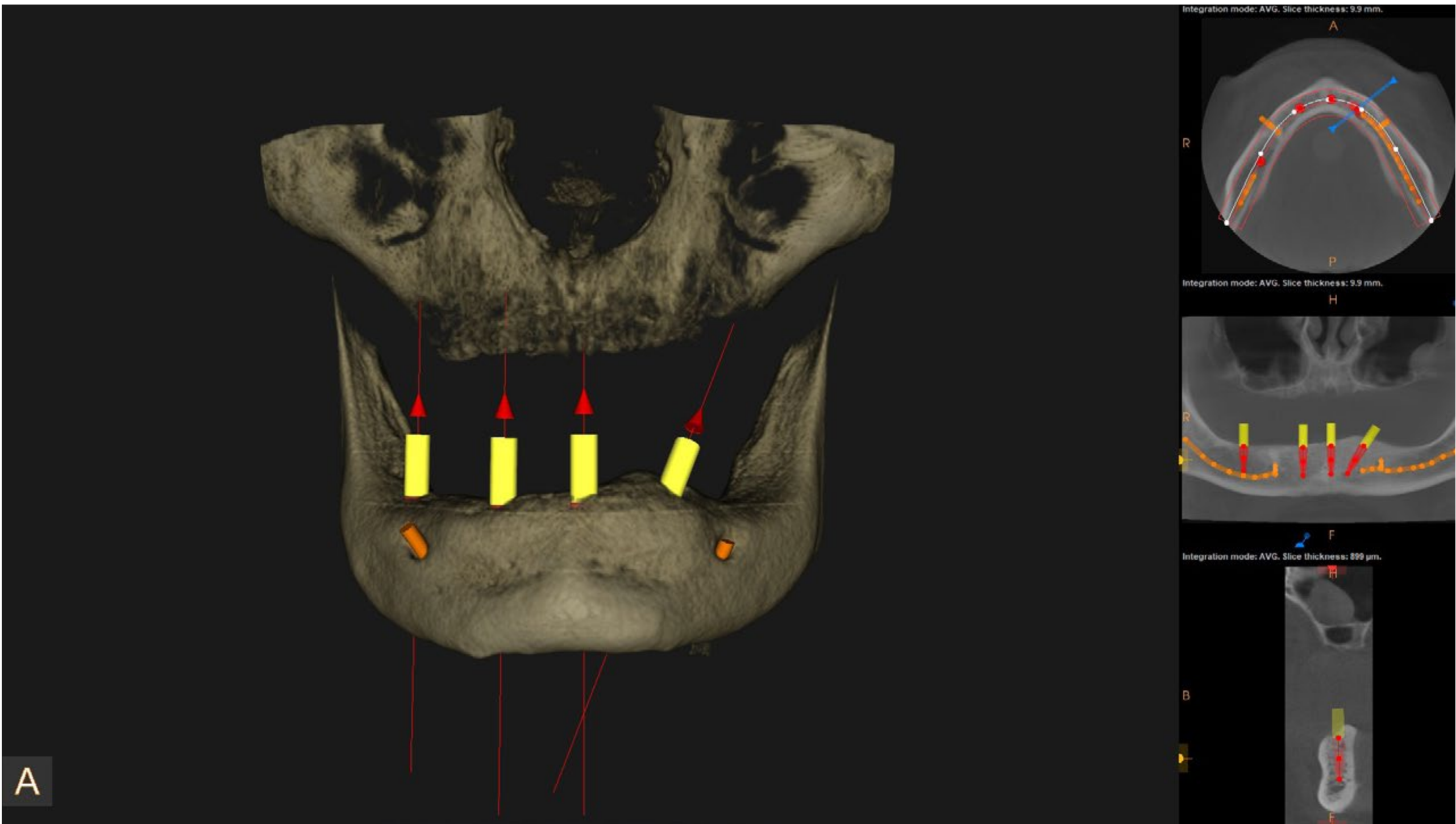


# Challenge 9: Hard bone quality and insufficient bone availability

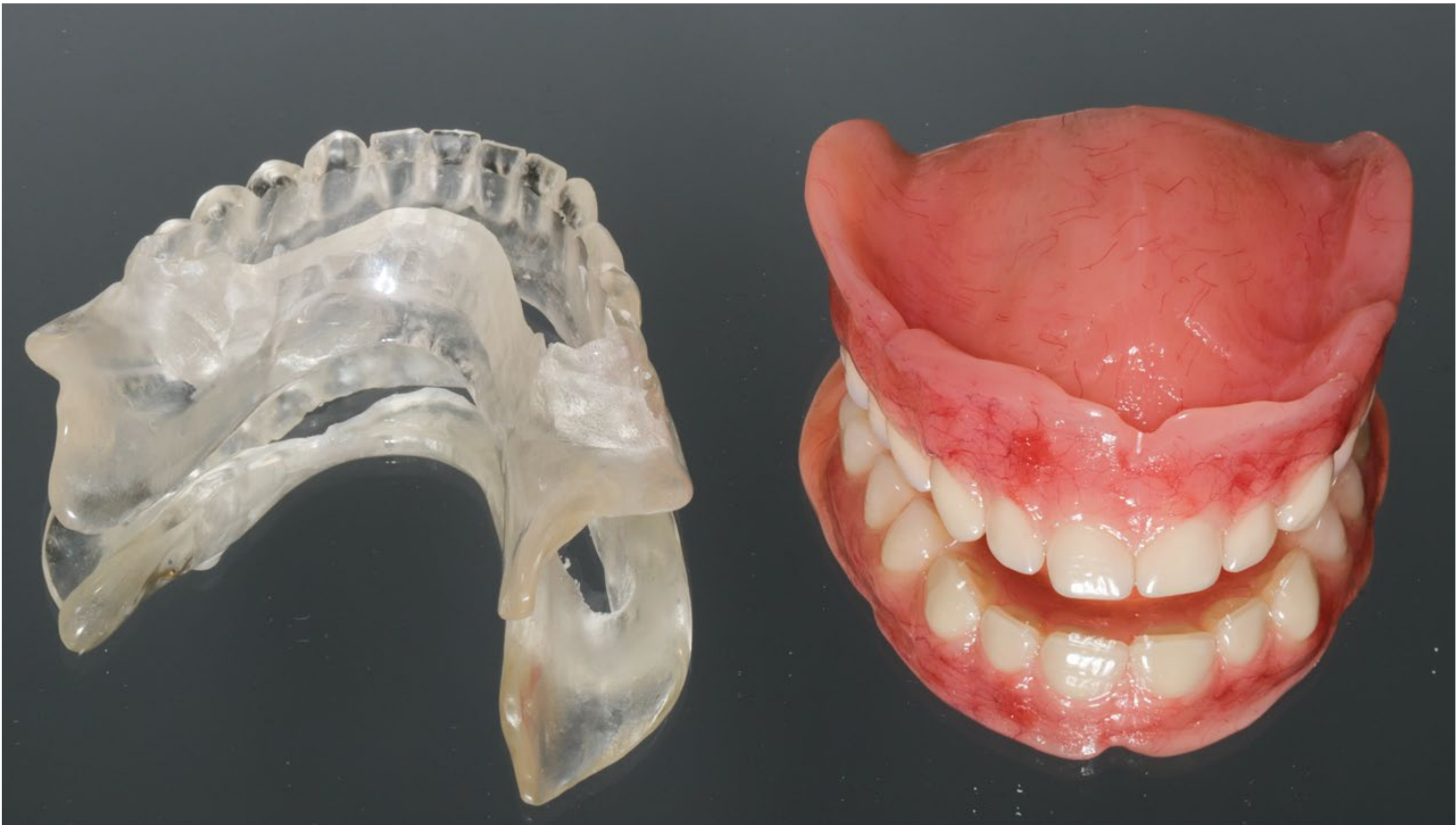Clinical case



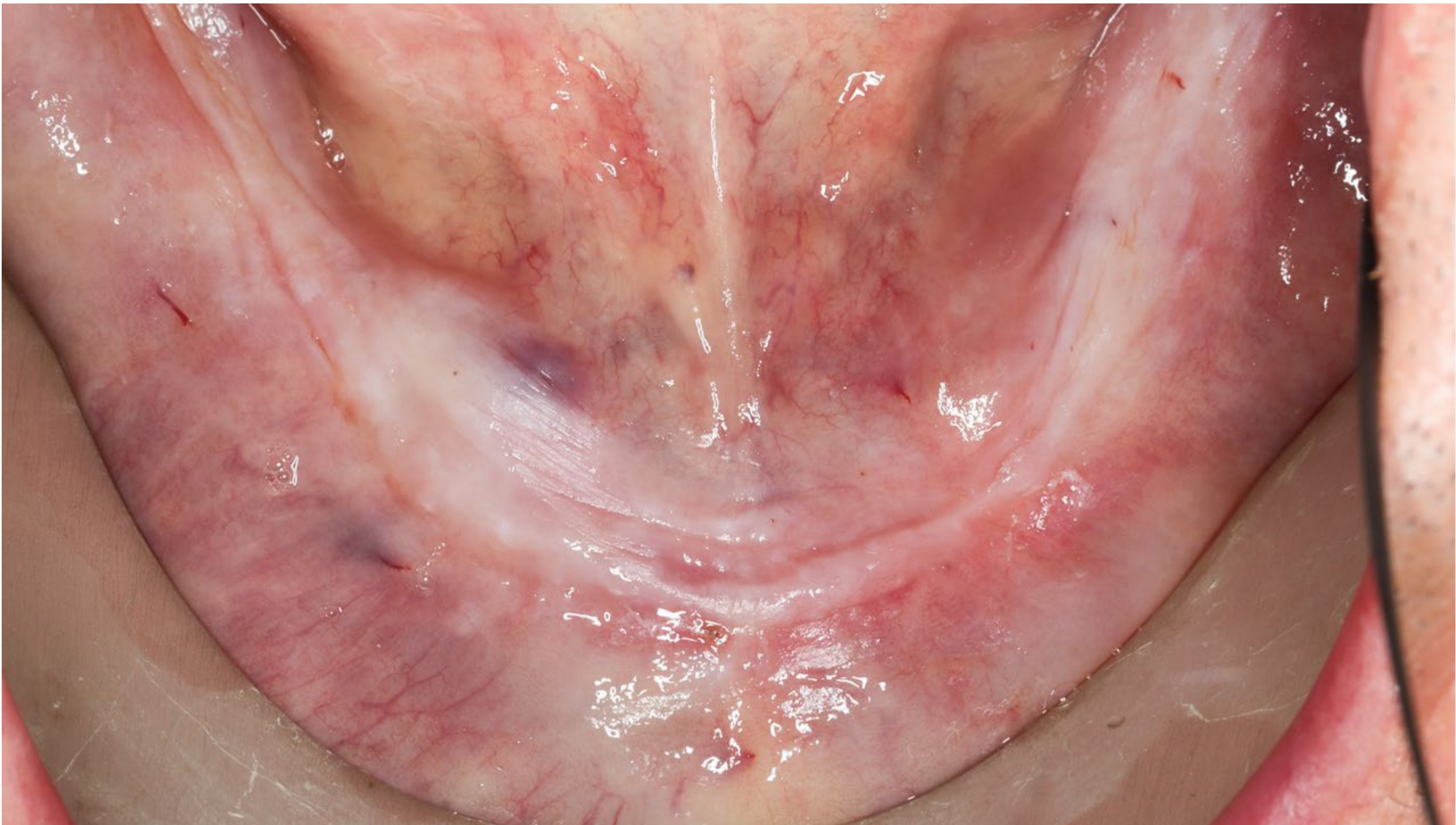Treatment planning



Treatment planning



Transparent guide for the lower jaw and regular denture for the upper jaw

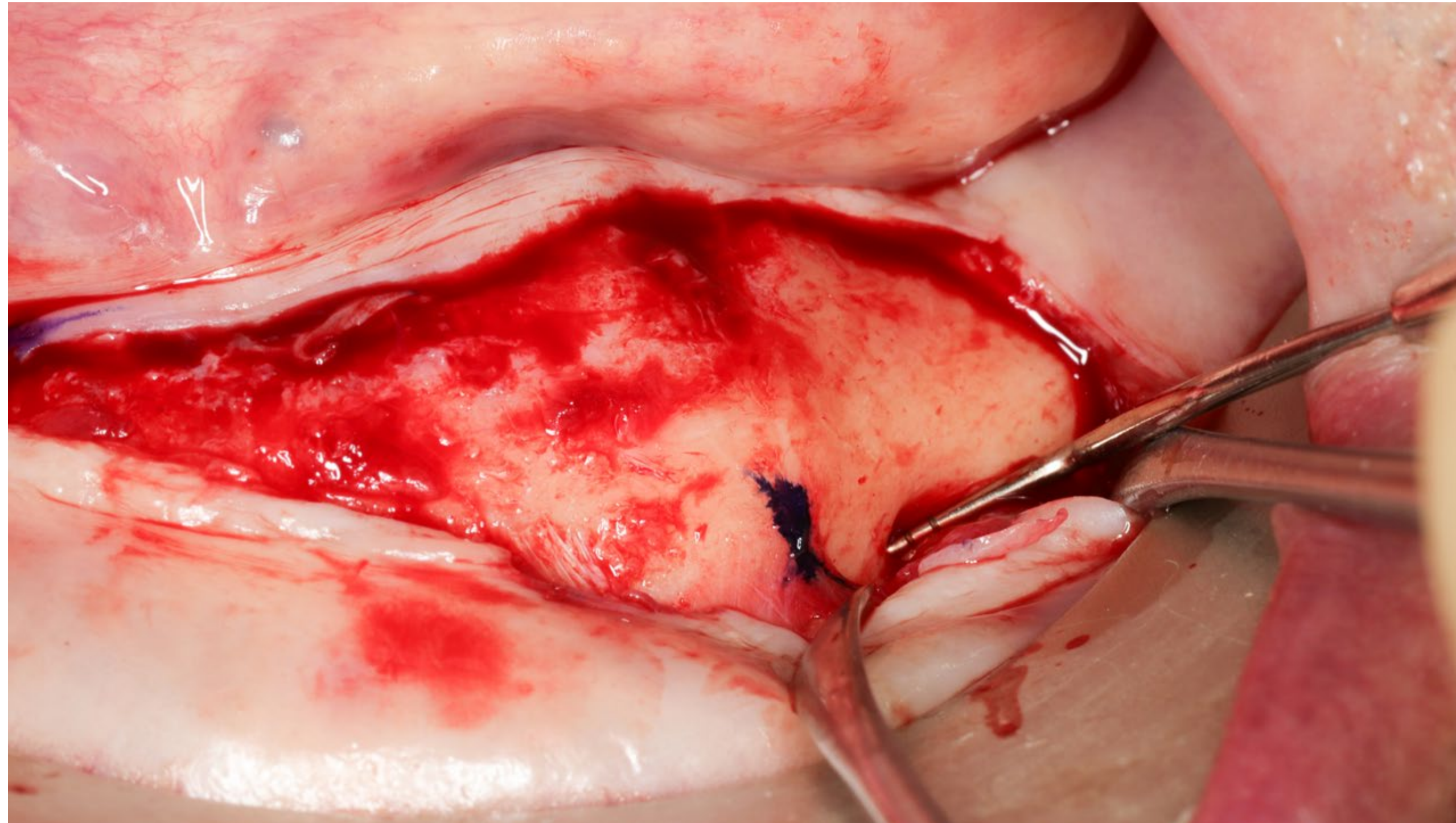


Initial clinical situation  
Occlusal view

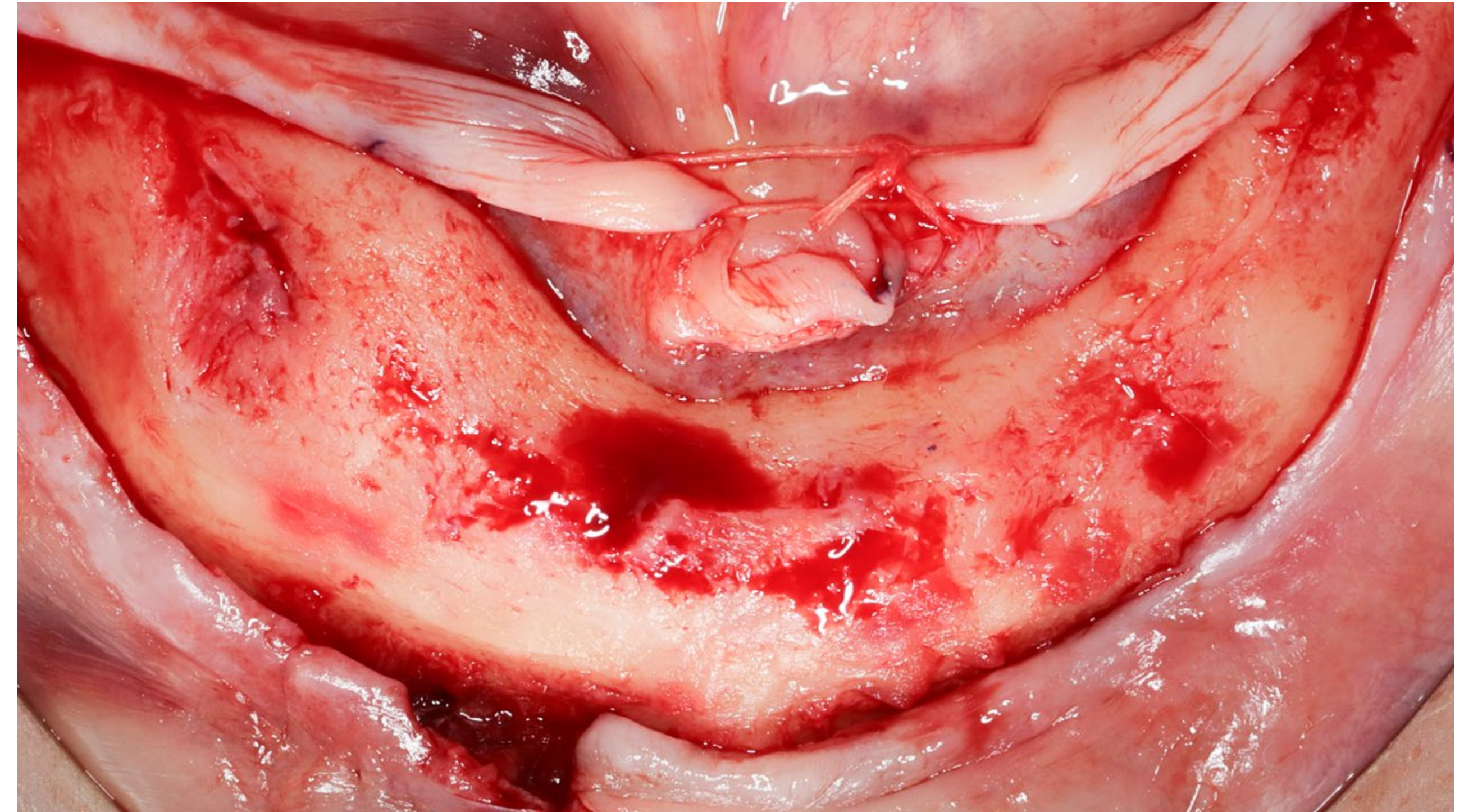


# Challenge 9: Hard bone quality and insufficient bone availability

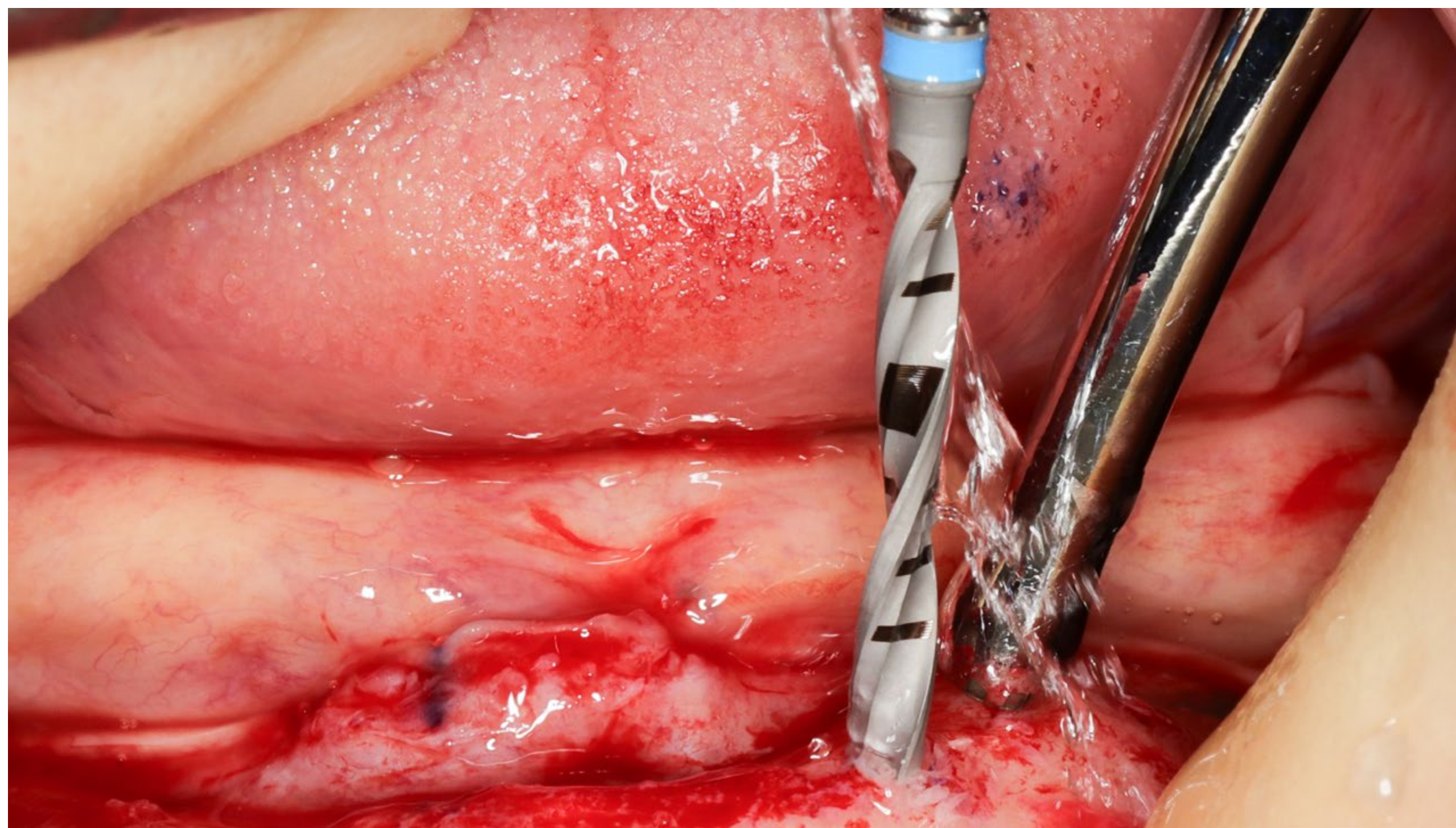
Clinical case



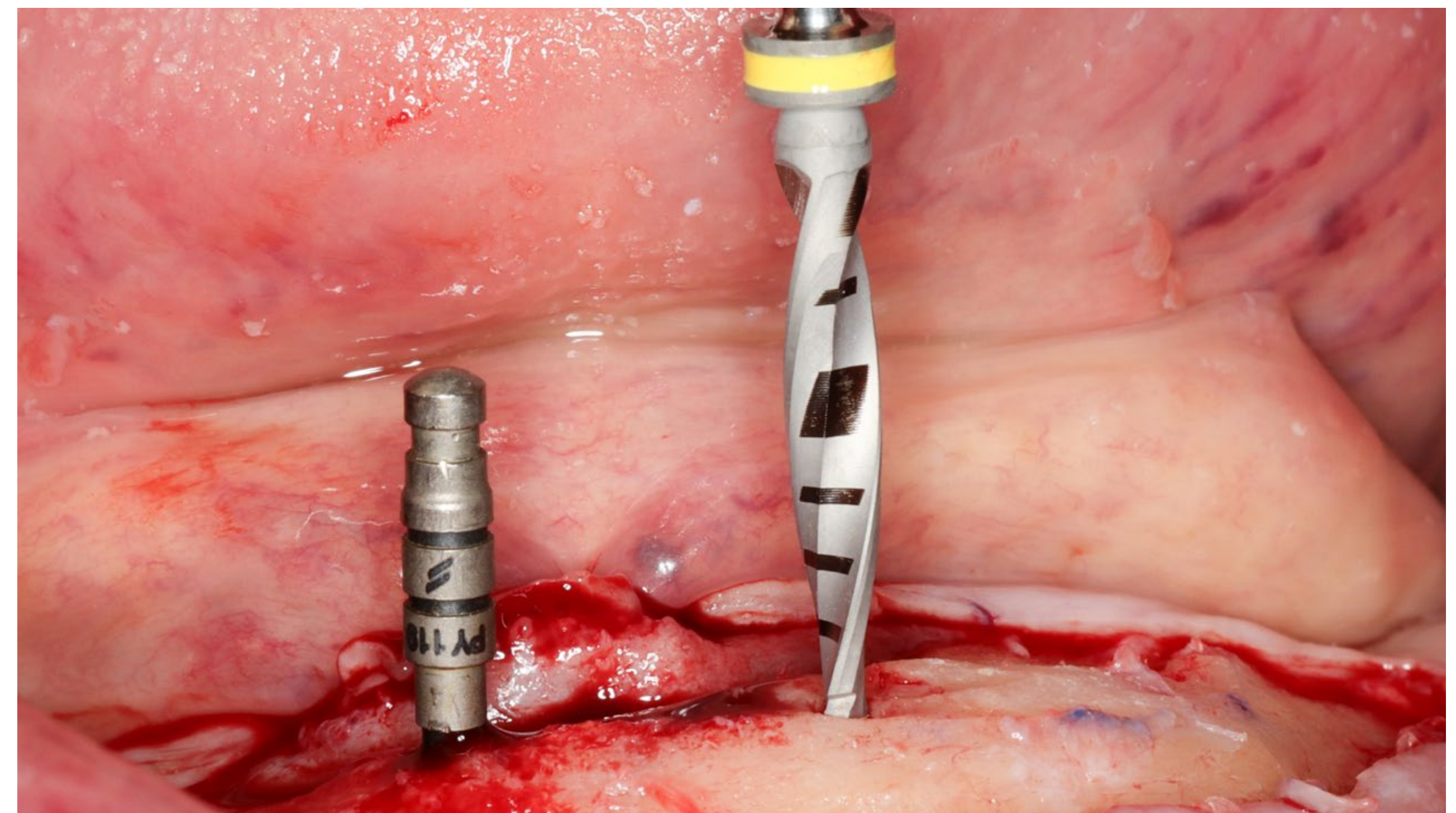
Marking of the anterior inferior alveolar nerve loop



Occlusal view after the bone reduction



Preparation of anterior implant sites  
Pilot Drill Ø 2.2 mm

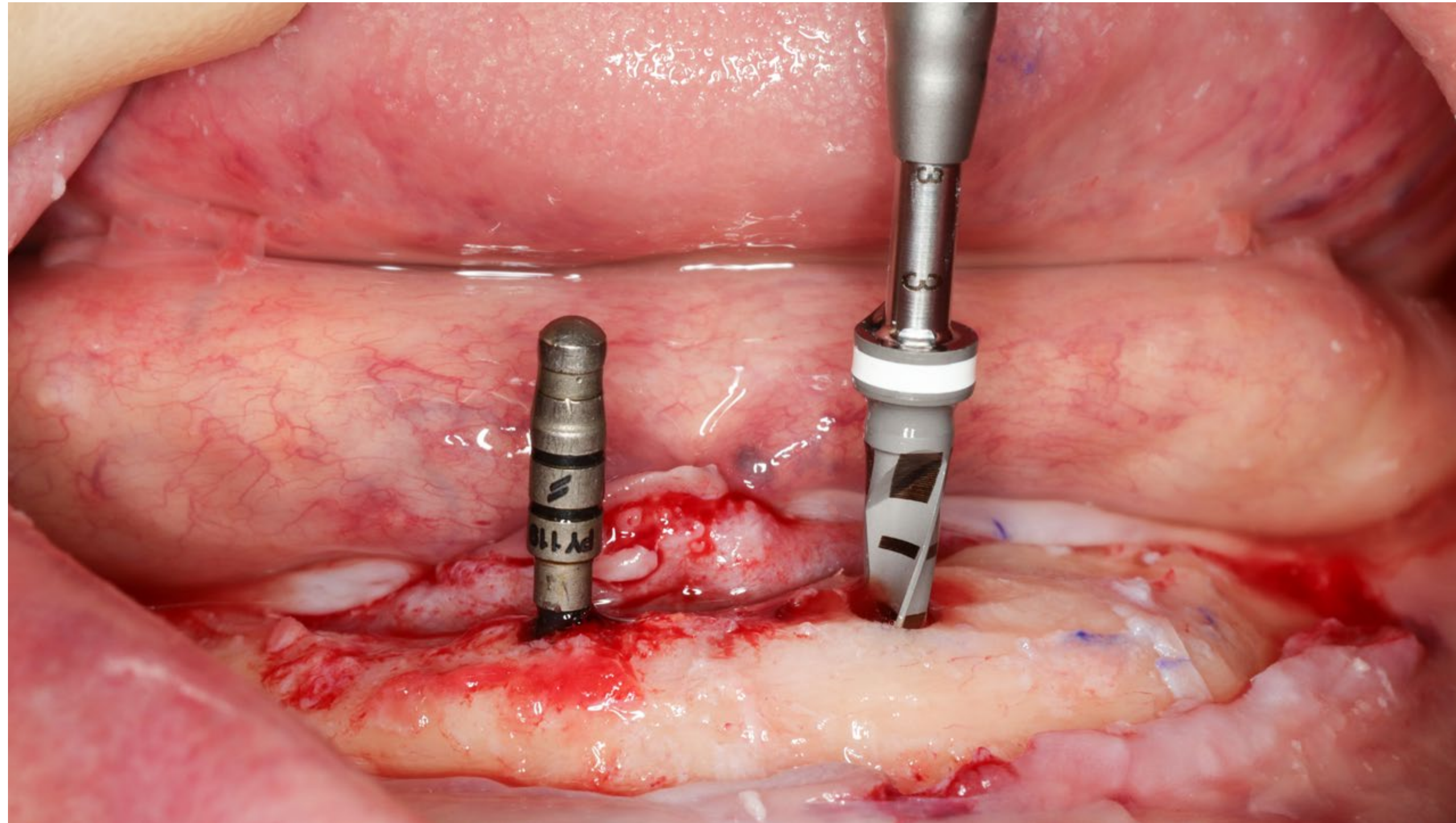


Preparation of anterior implant sites  
Drill Ø 2.8 mm

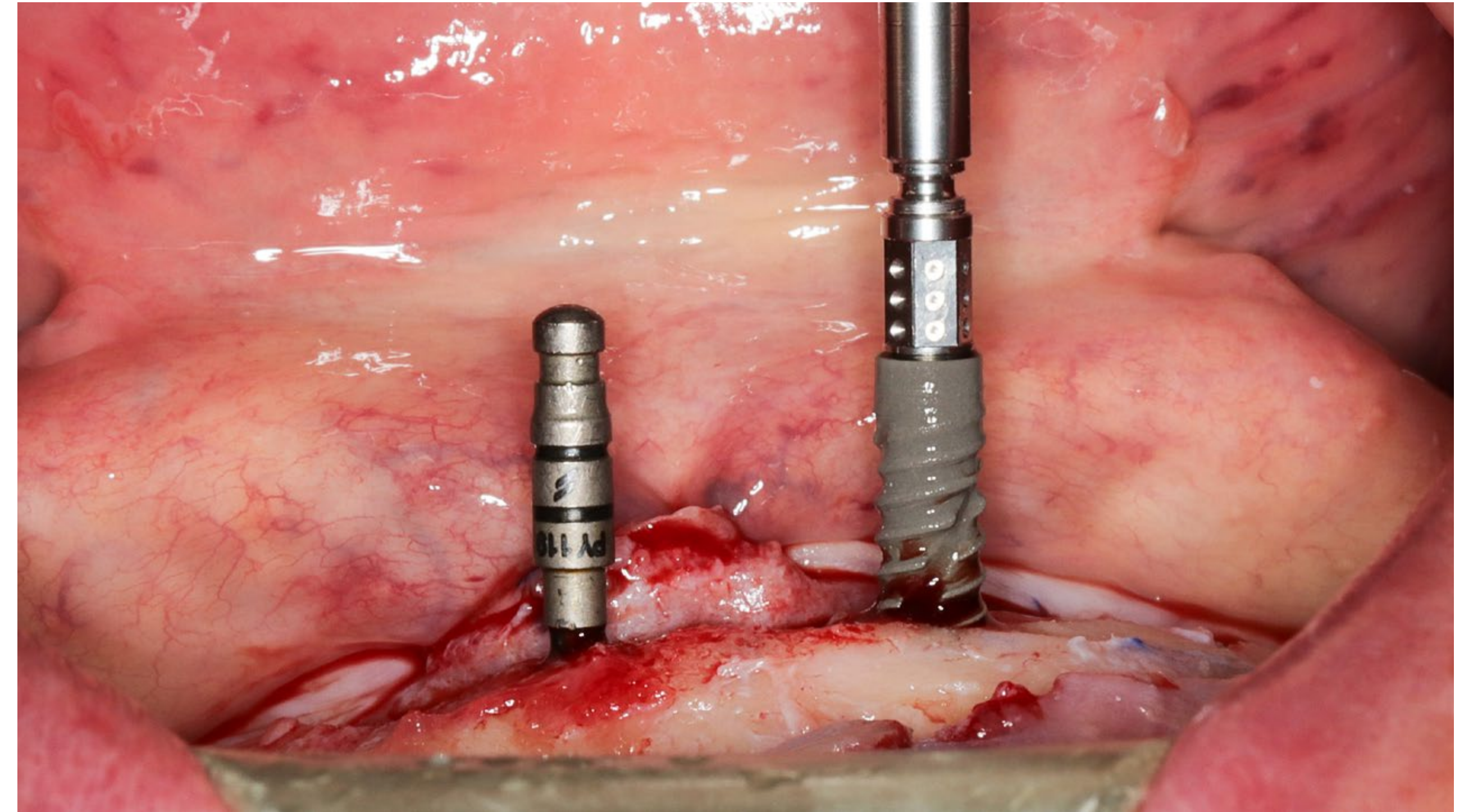


# Challenge 9: Hard bone quality and insufficient bone availability

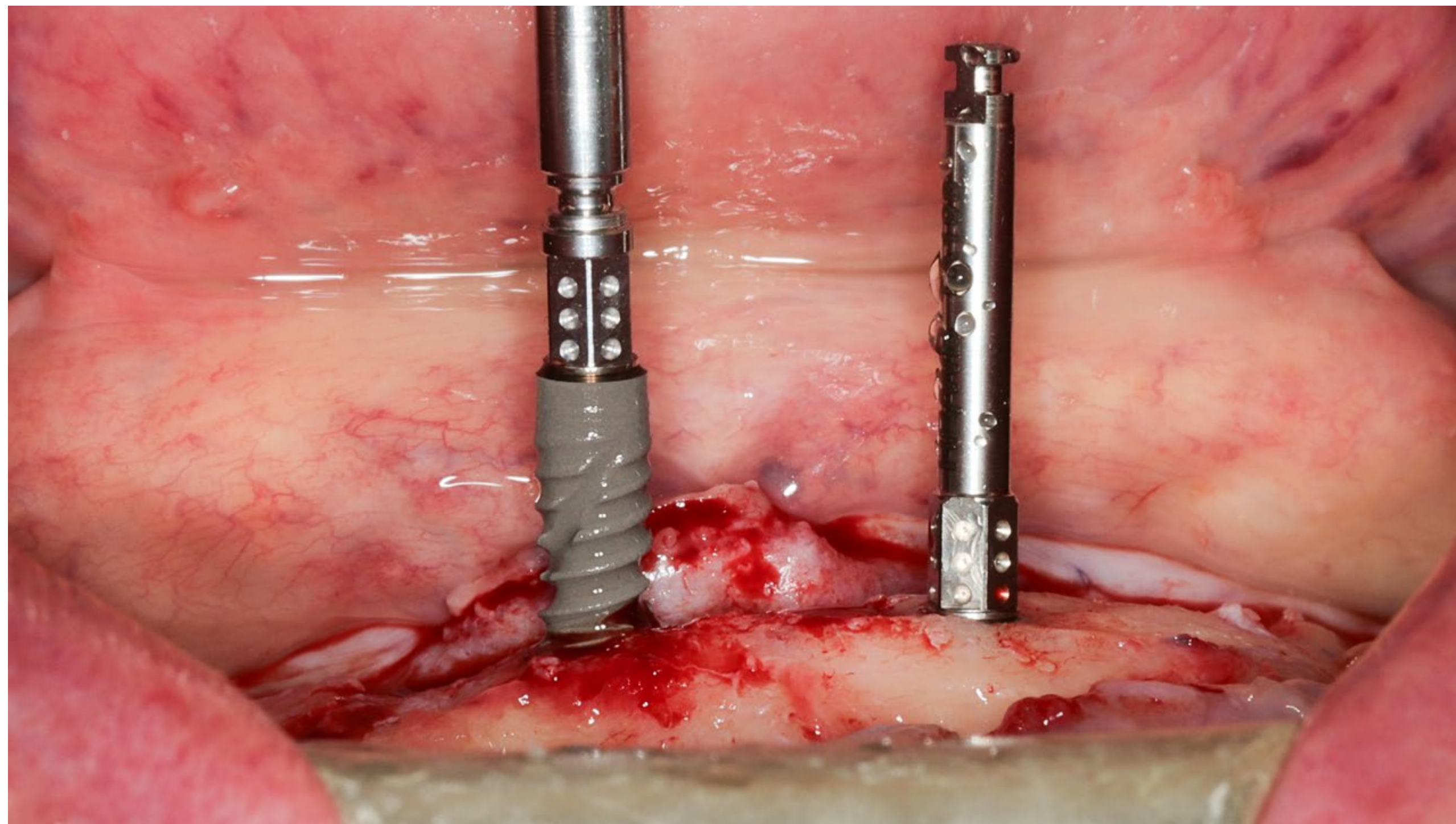
Clinical case



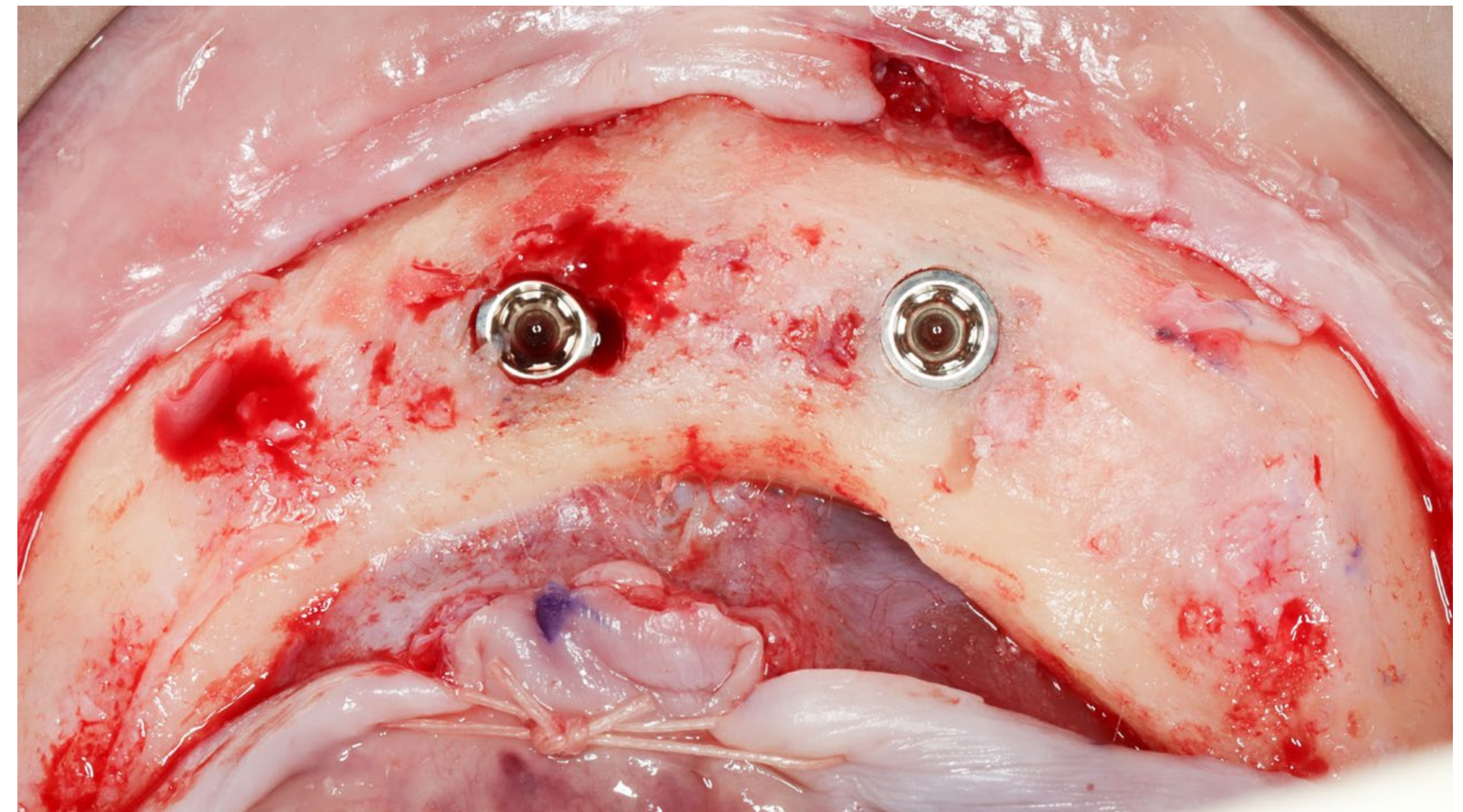
Preparation of anterior implant sites  
Drill Ø 3.7 mm



Placement of the Straumann® BLX Ø 3.75 mm RB SLActive® 10 mm Roxolid® implant  
with a torque of 35 Ncm



Placement of the Straumann® BLX Ø 3.75 mm RB SLActive® 10 mm Roxolid® implant  
with a torque of 35 Ncm

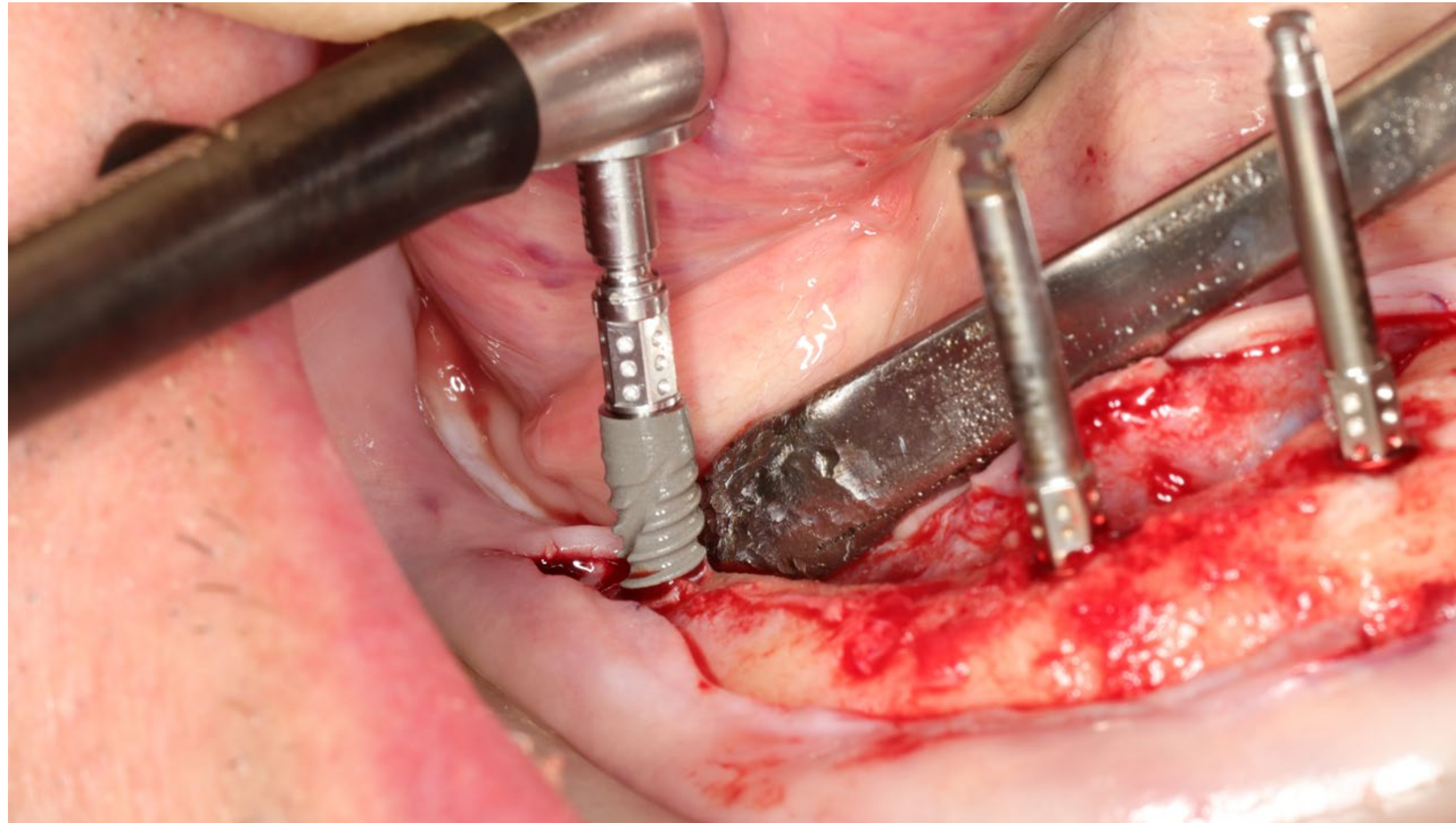


Anterior implants in place

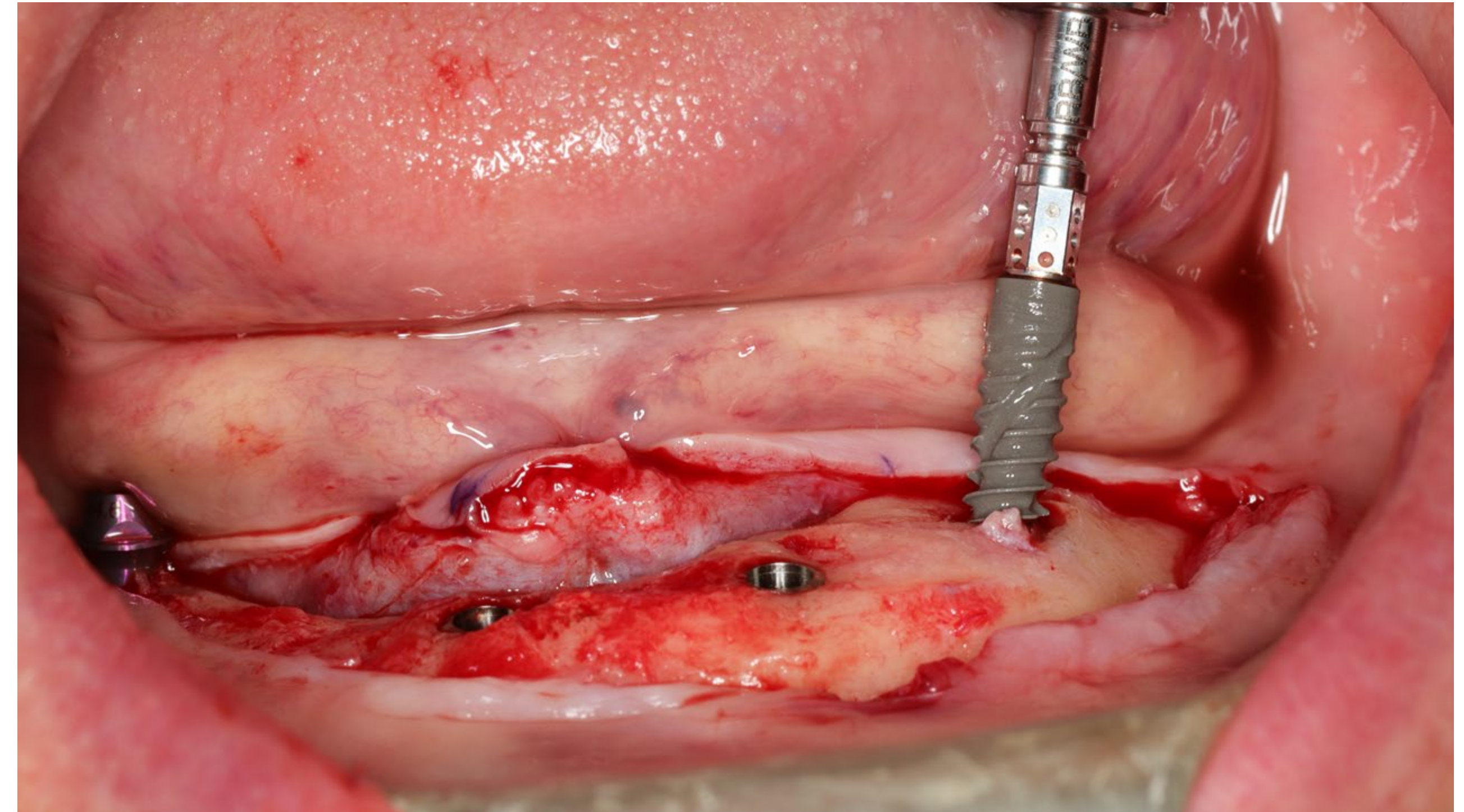


# Challenge 9: Hard bone quality and insufficient bone availability

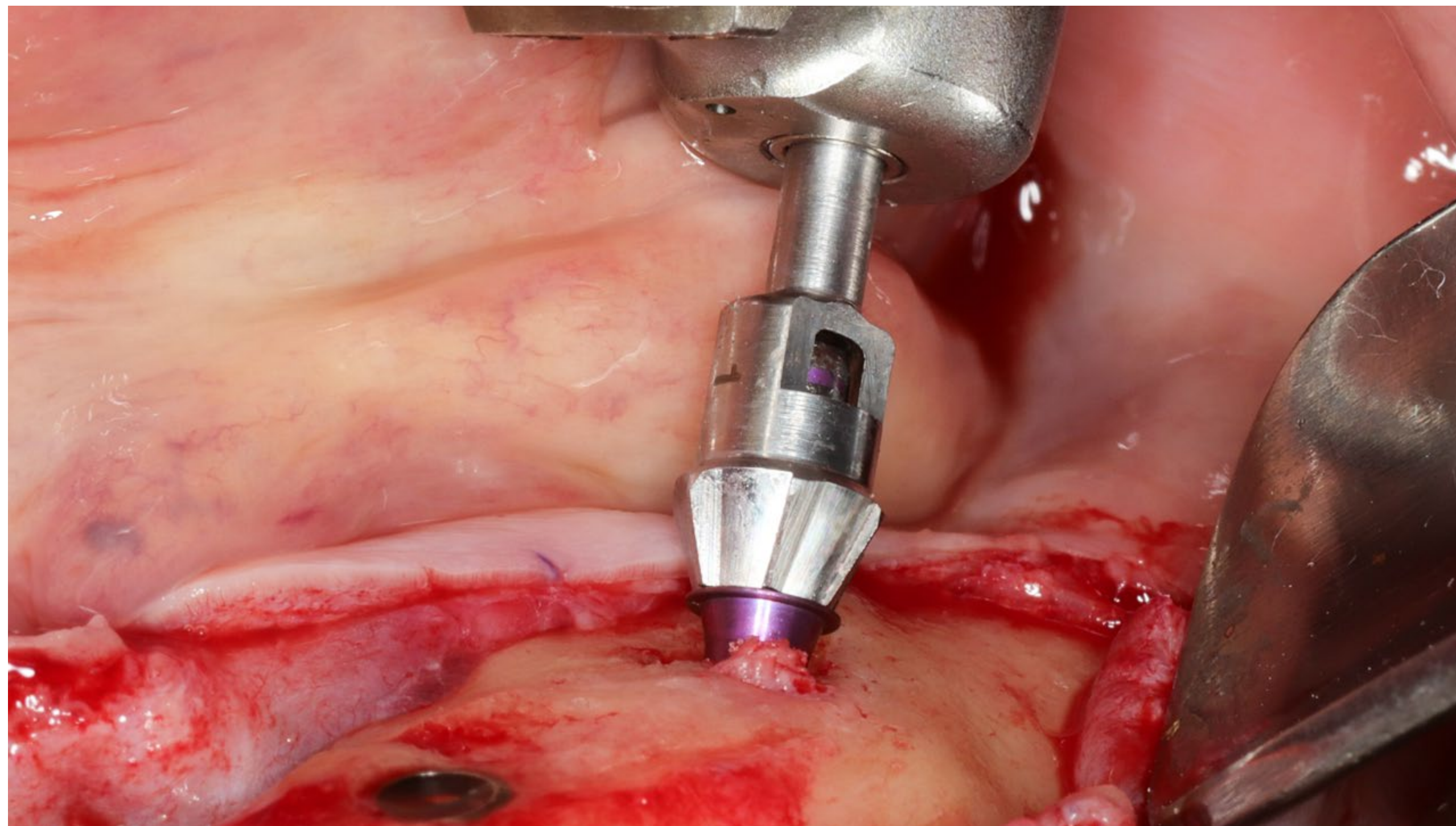
Clinical case



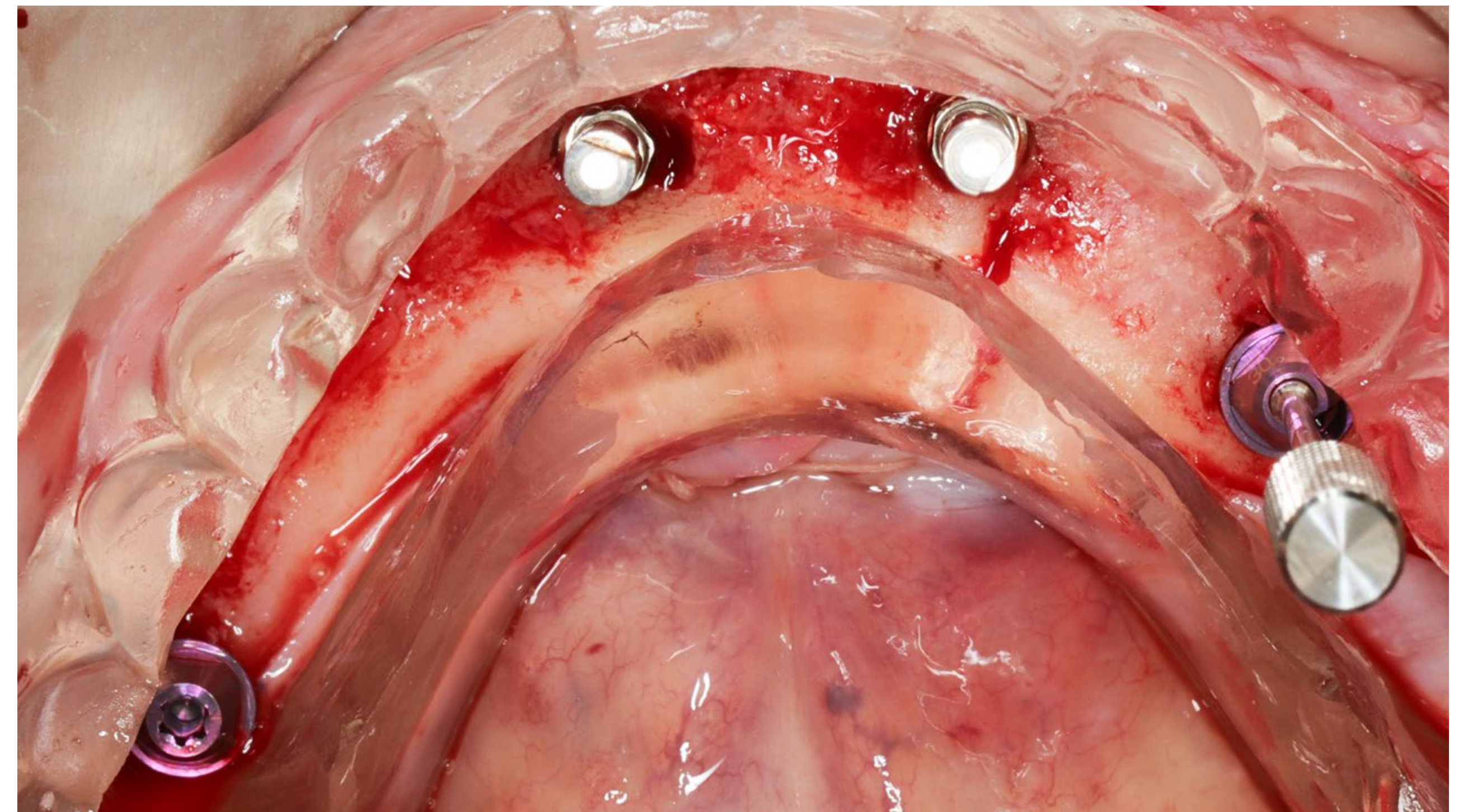
Placement of the Straumann® BLX Ø 3.75 mm RB SLActive® 10 mm Roxolid® implant with a torque of 35 Ncmt



Placement of the Straumann® BLX Ø 3.75 mm RB SLActive® 10 mm Roxolid® implant with a torque of 35 Ncm



Removal of the bone coronally with Straumann® Bone Level Bone Profiler

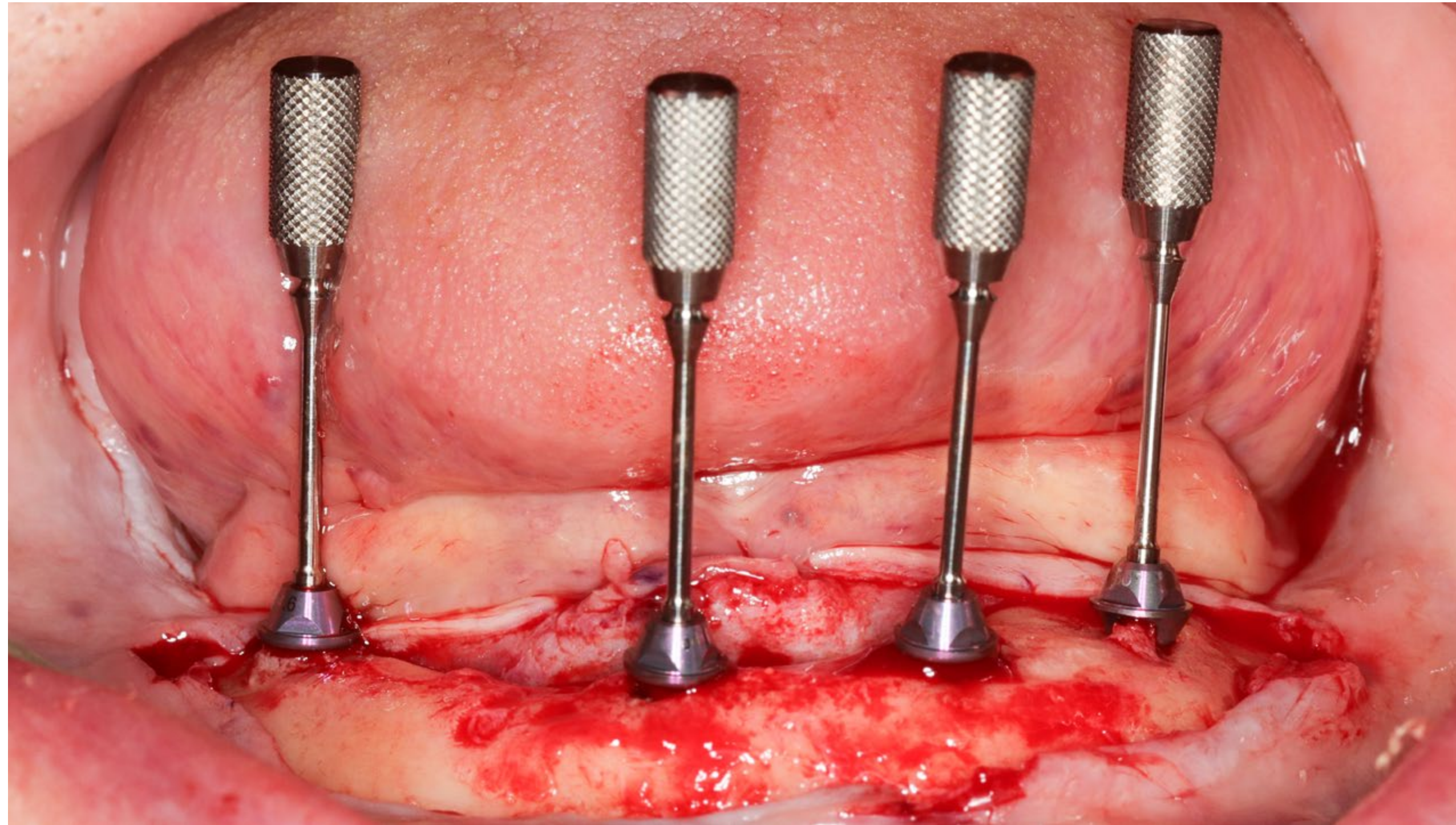


Placement of the Screw-retained Abutments and alignment

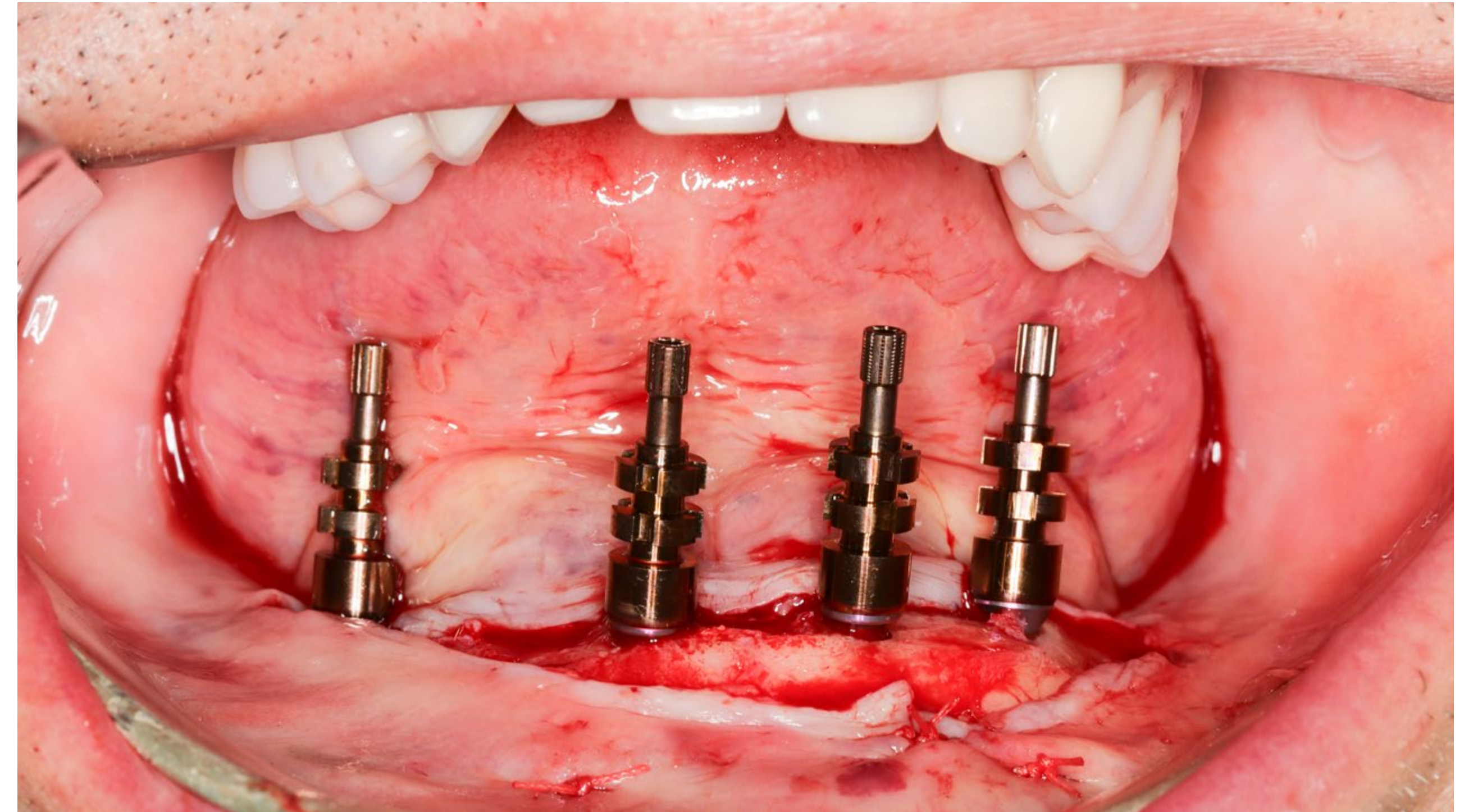


# Challenge 9: Hard bone quality and insufficient bone availability

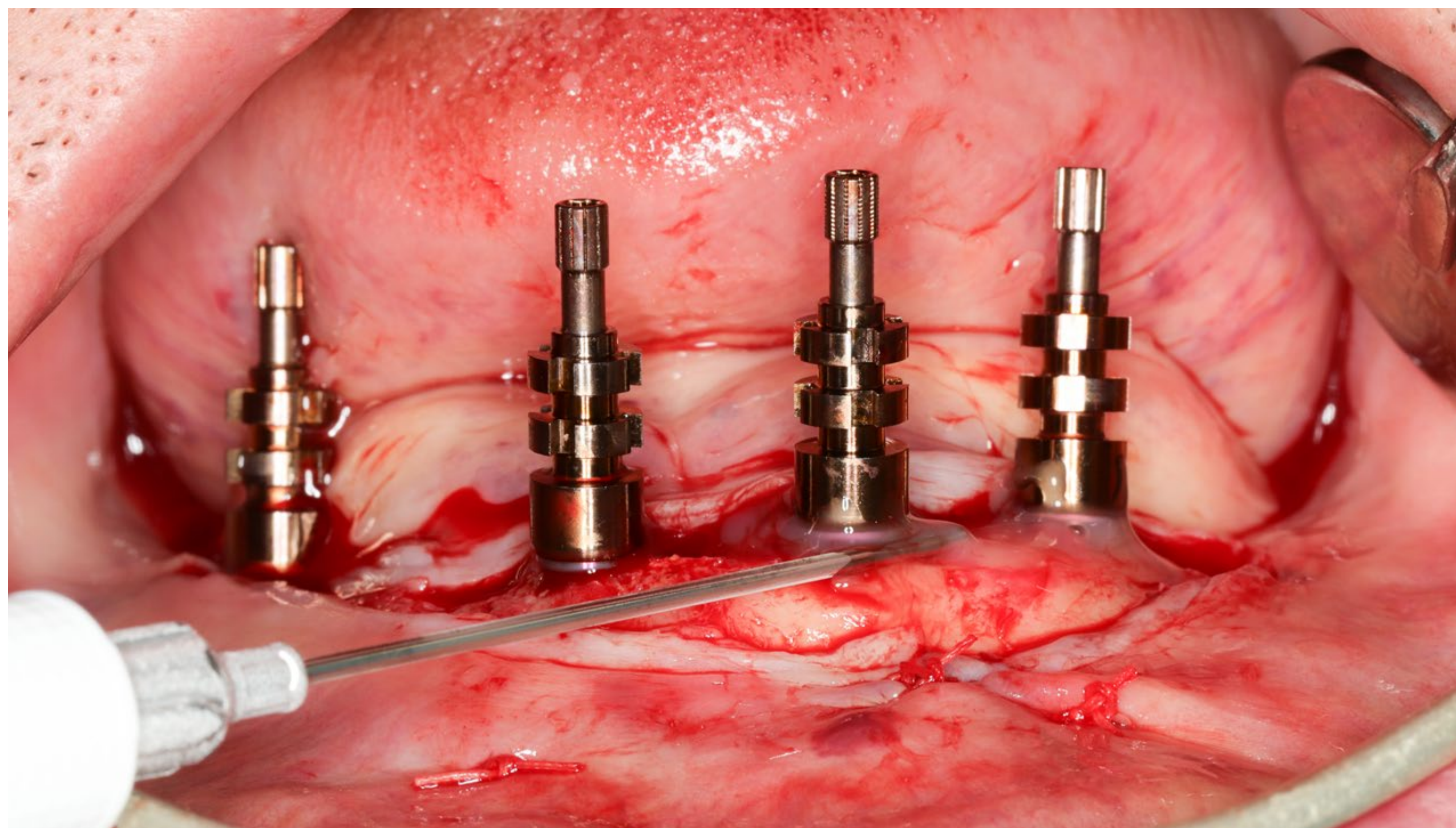
Clinical case



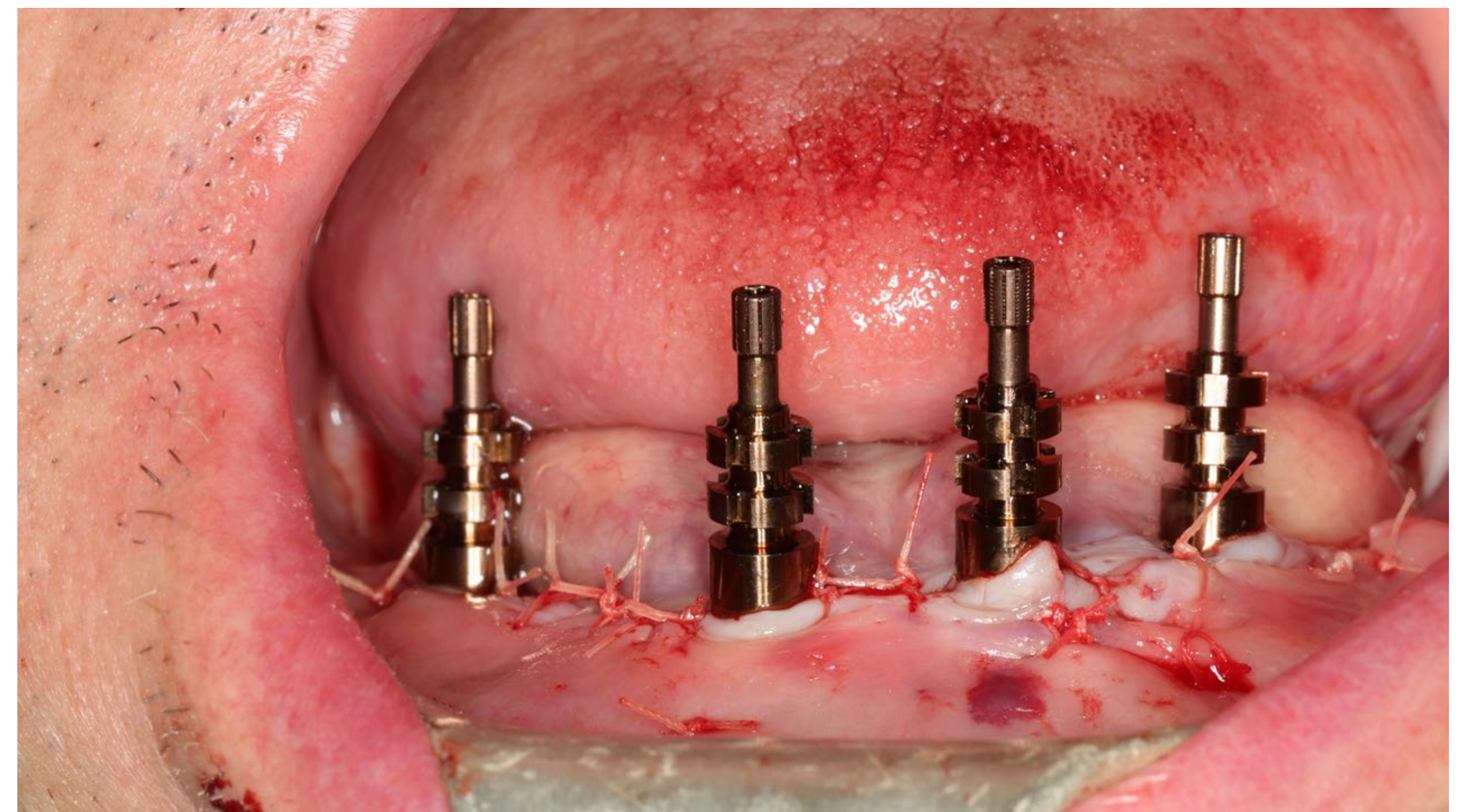
Screw-Retained Abutments in place



Impression Posts for Screw-retained Abutments in place



Straumann® Emdogain® placement around implants

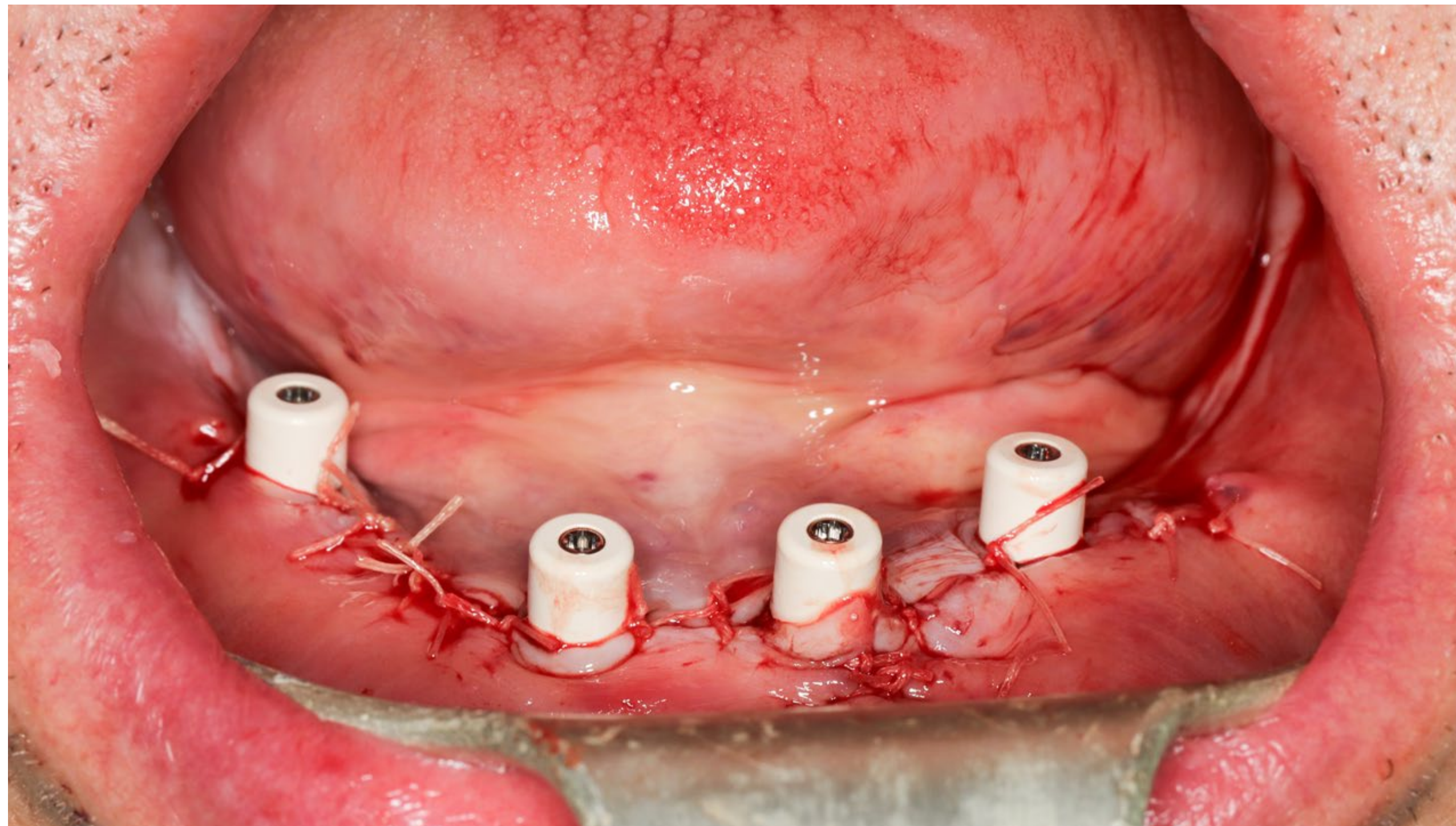


Closure of the flap

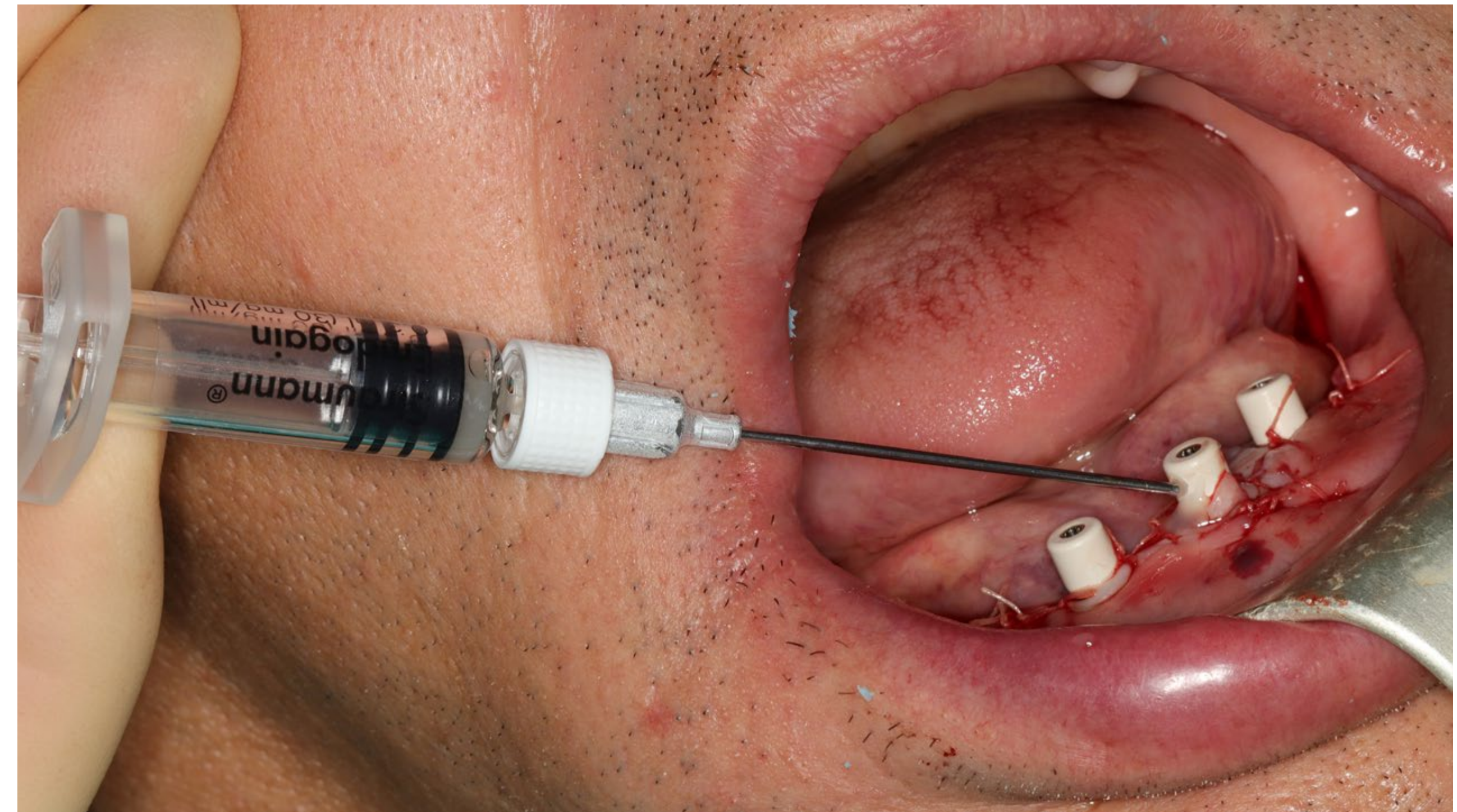

# Challenge 9: Hard bone quality and insufficient bone availability

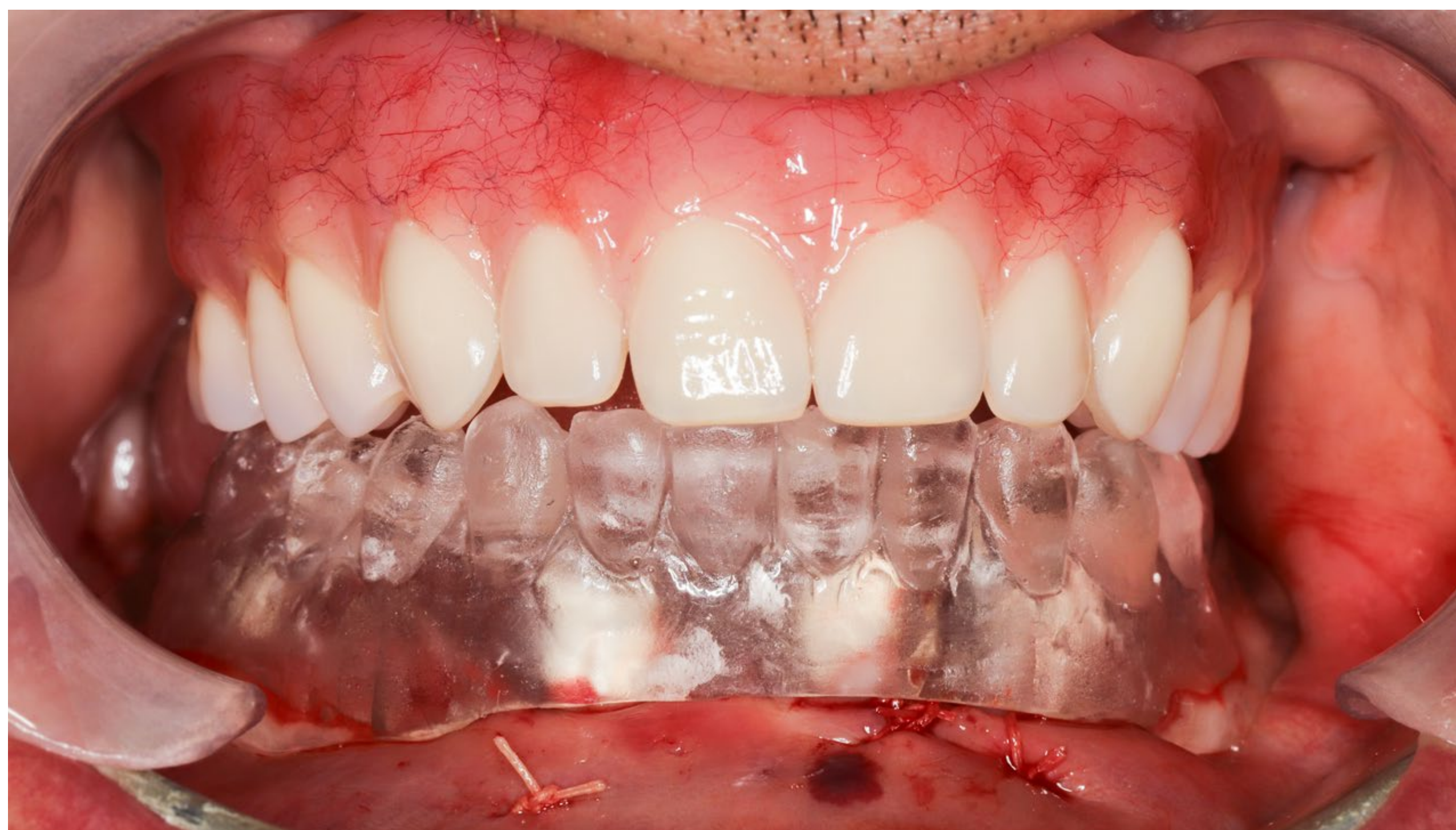Clinical case



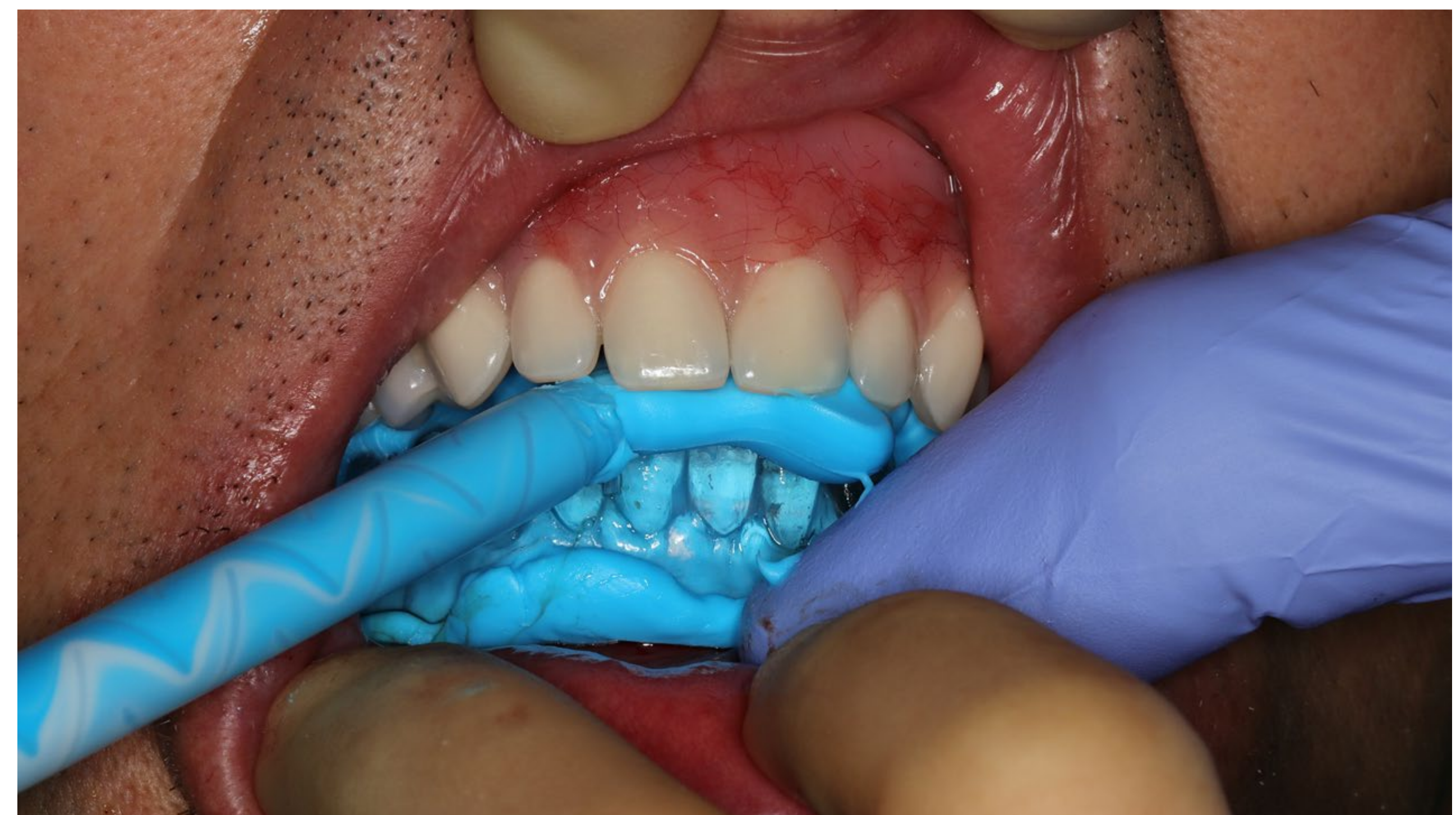Protective Caps Ø 4.6 mm in place



Straumann® Emdogain® placement after flap closure



Transparent guide to verify implant position and occlusion

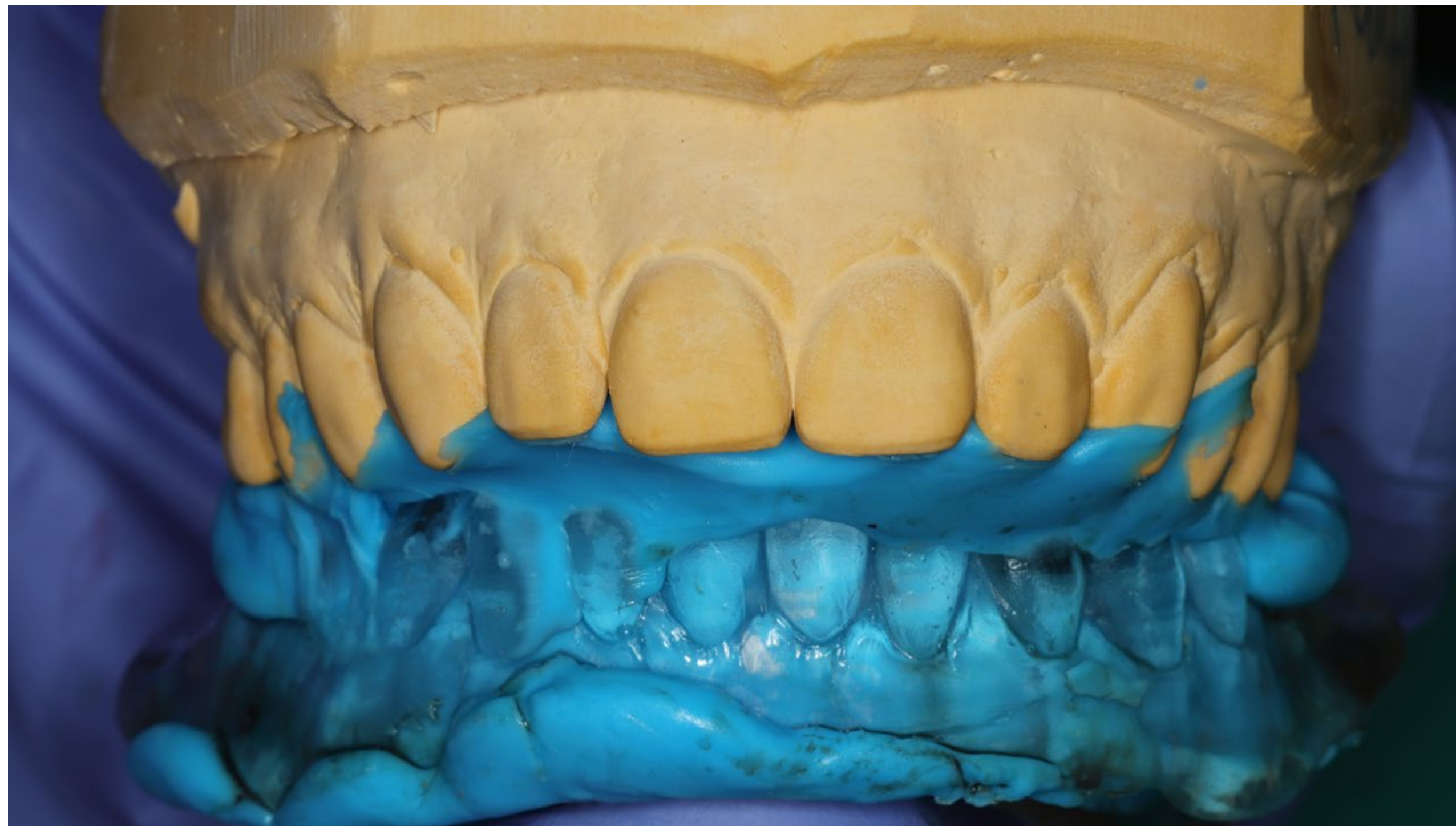

Impression taking and bite registration

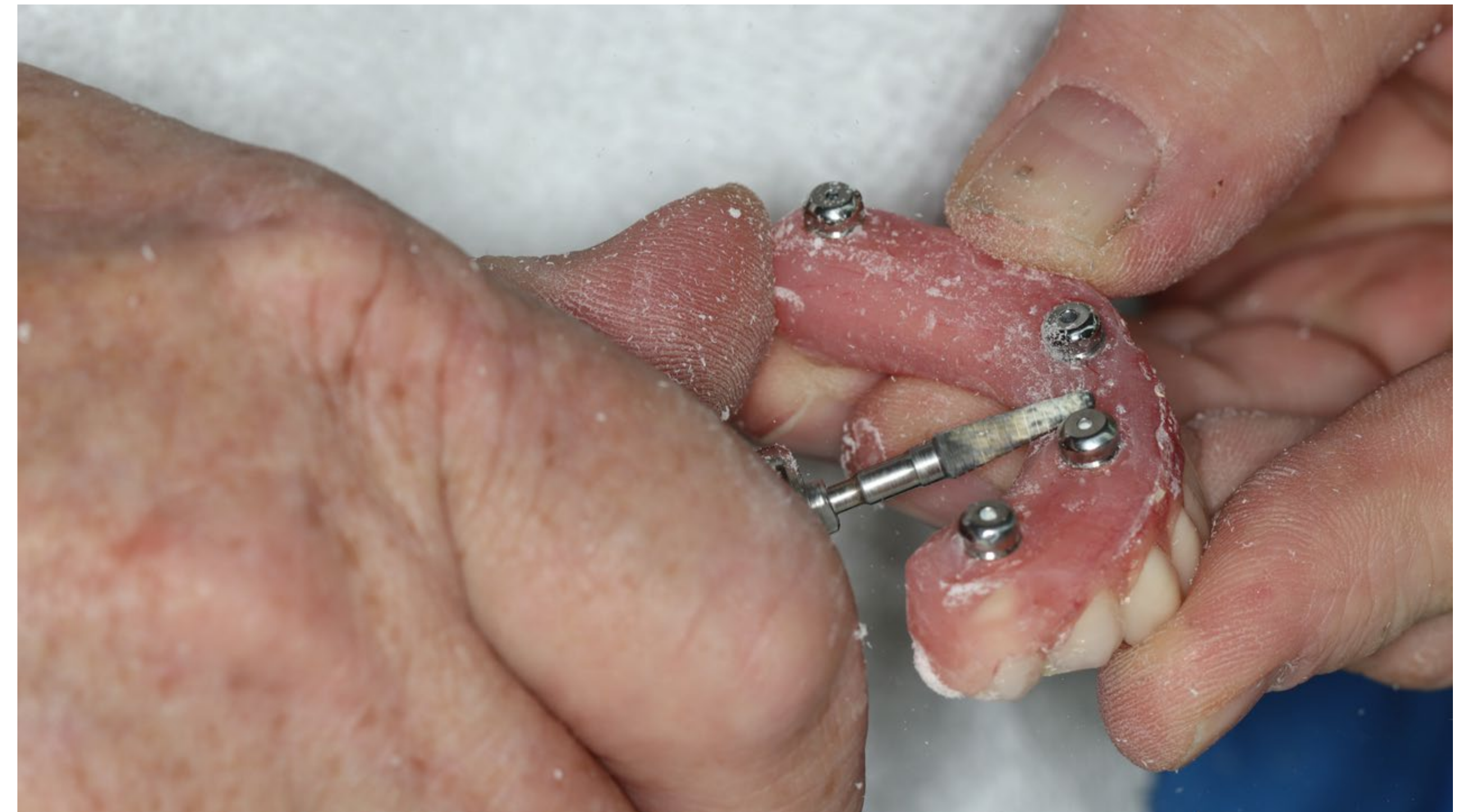

# Challenge 9: Hard bone quality and insufficient bone availability

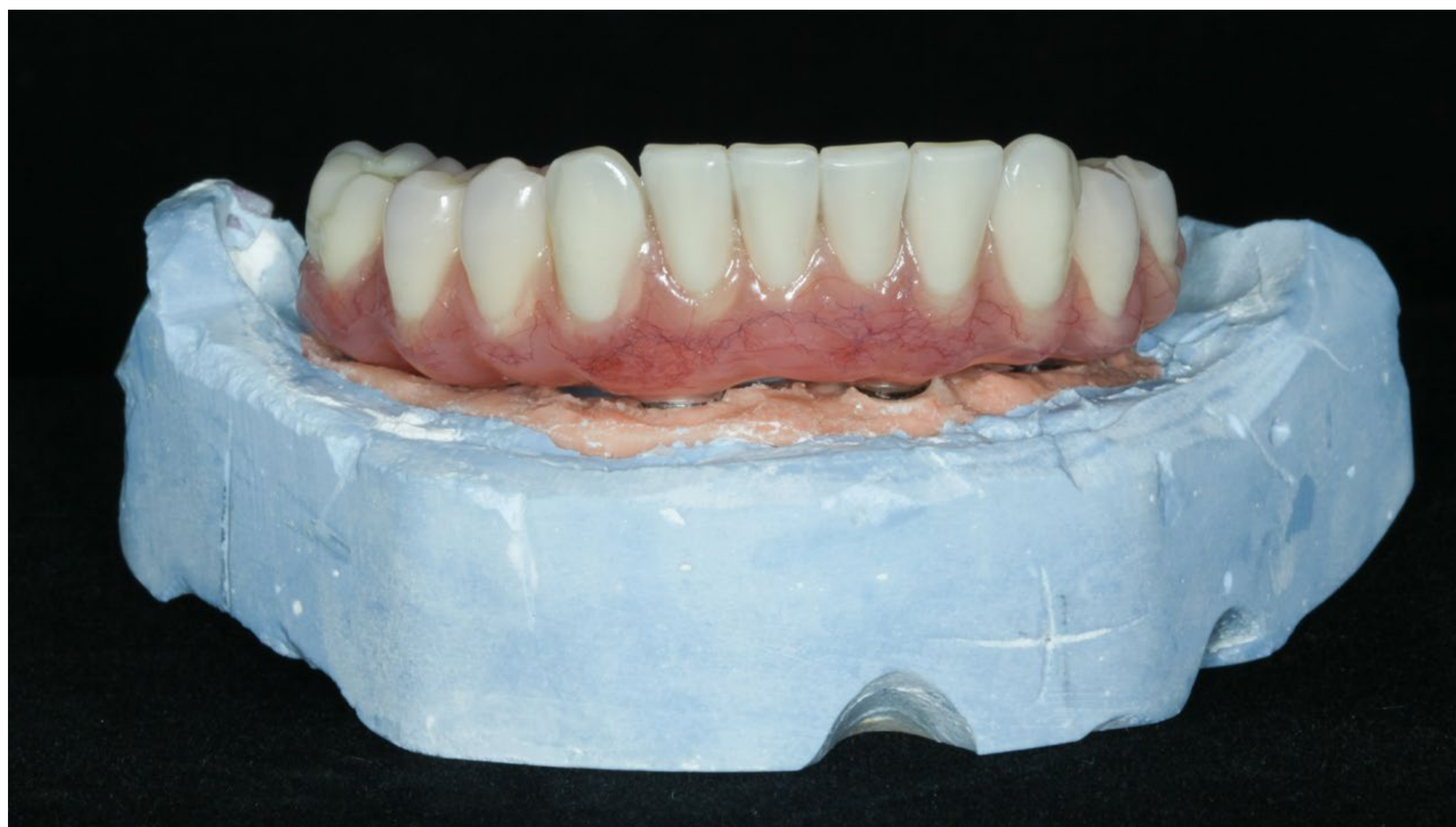Clinical case



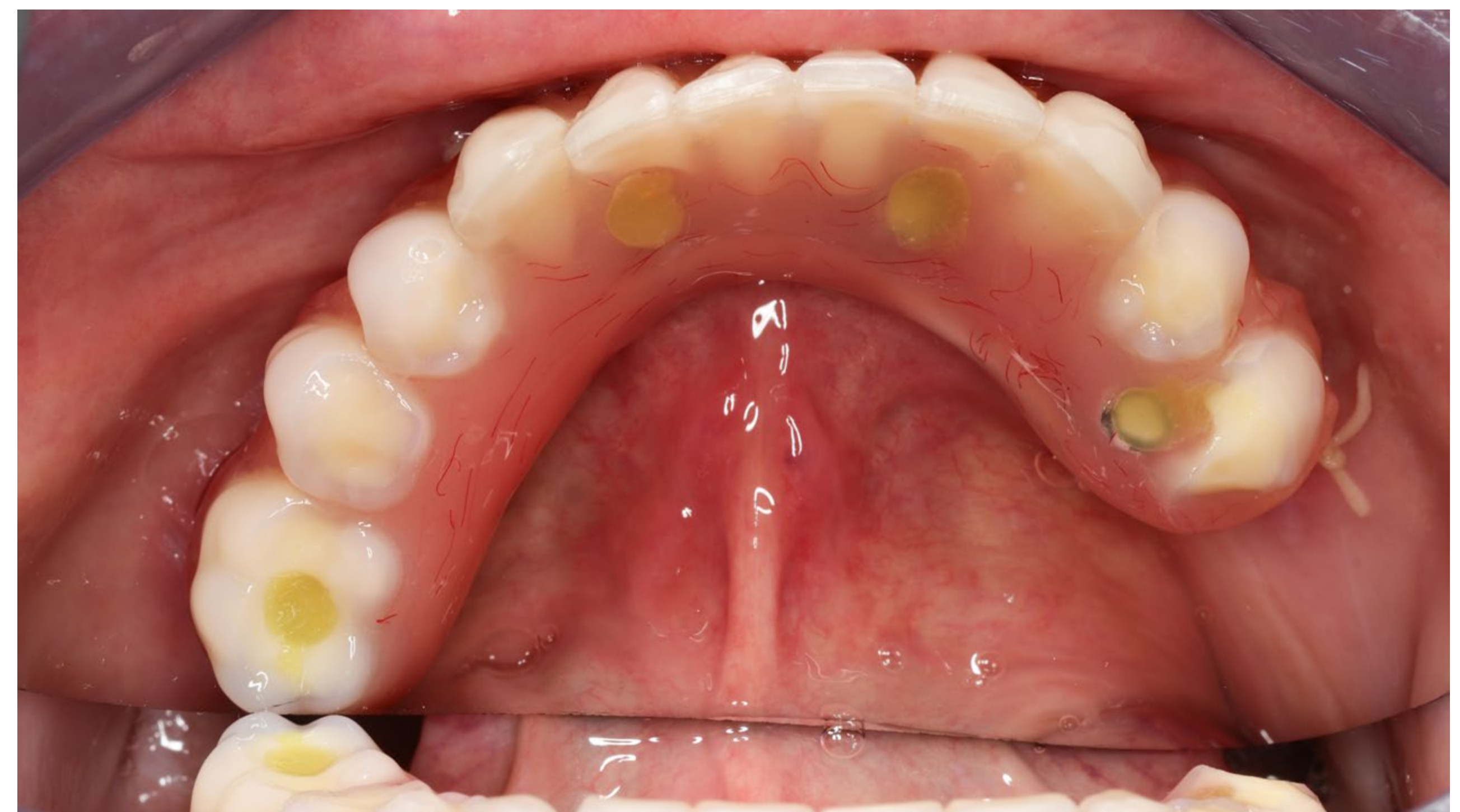Placement of the casts on the articulator



Preparation of the provisional prosthesis



Finished provisional prosthesis

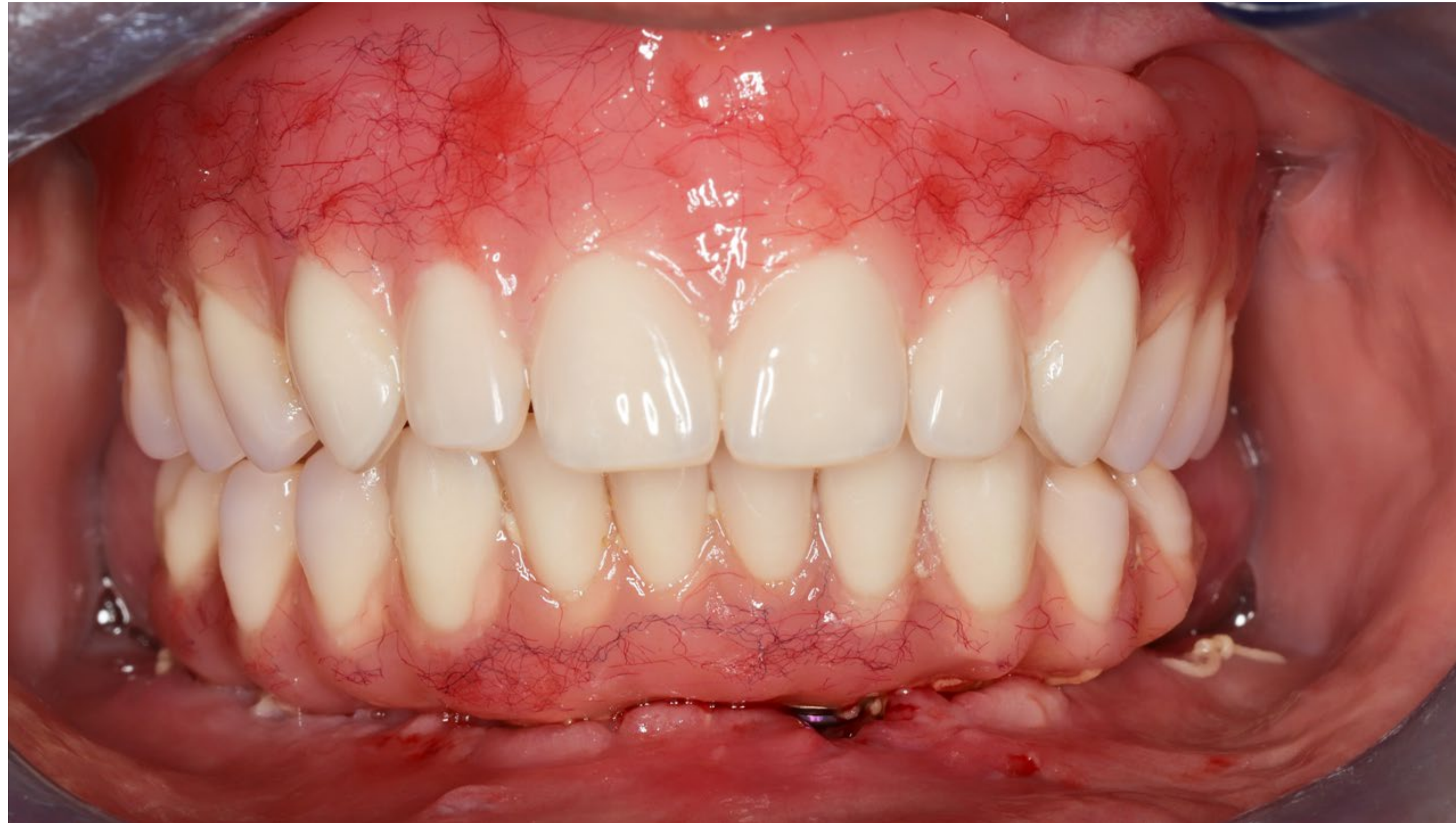

Placement of the provisional prosthesis  
Occlusal view

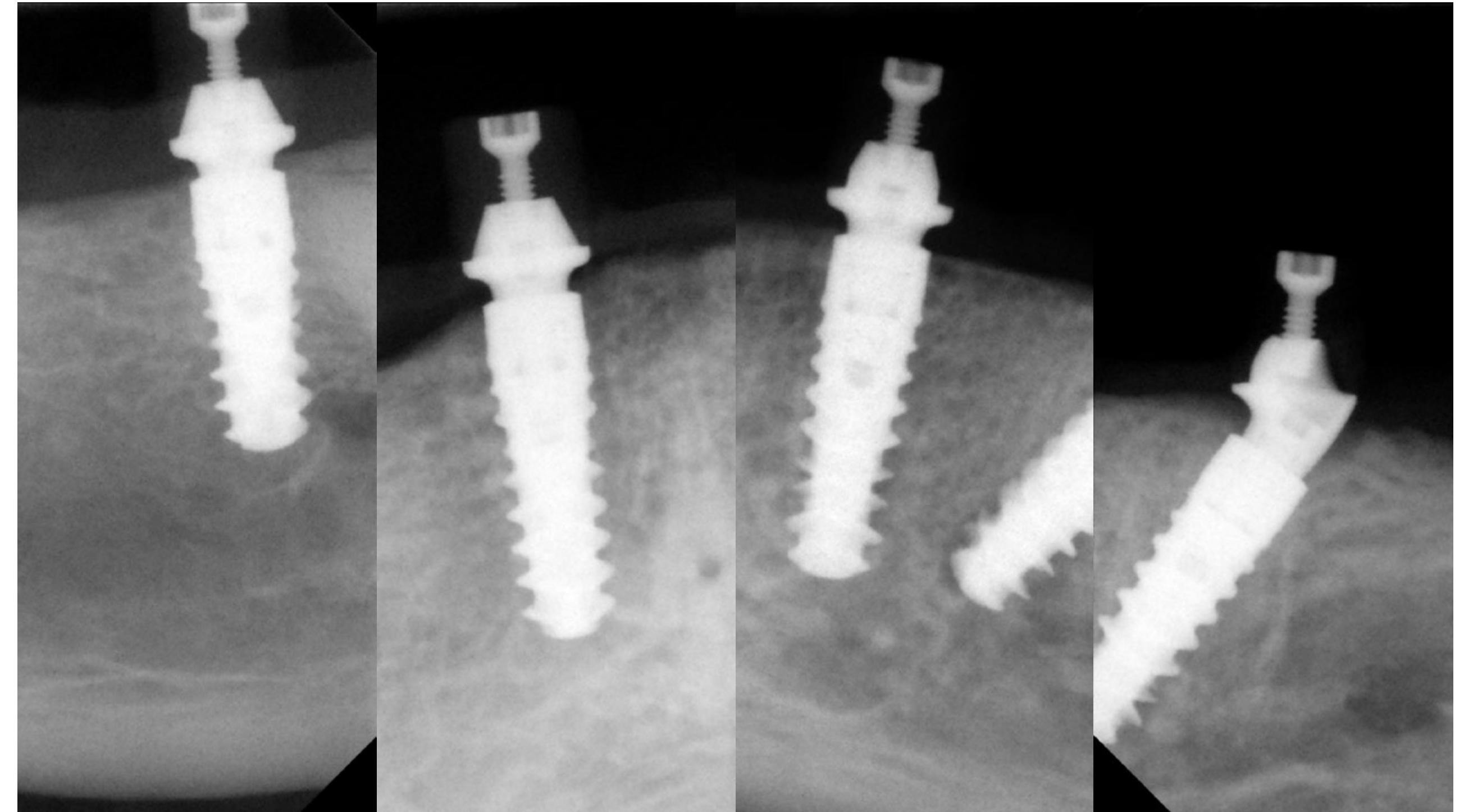


# Challenge 9: Hard bone quality and insufficient bone availability

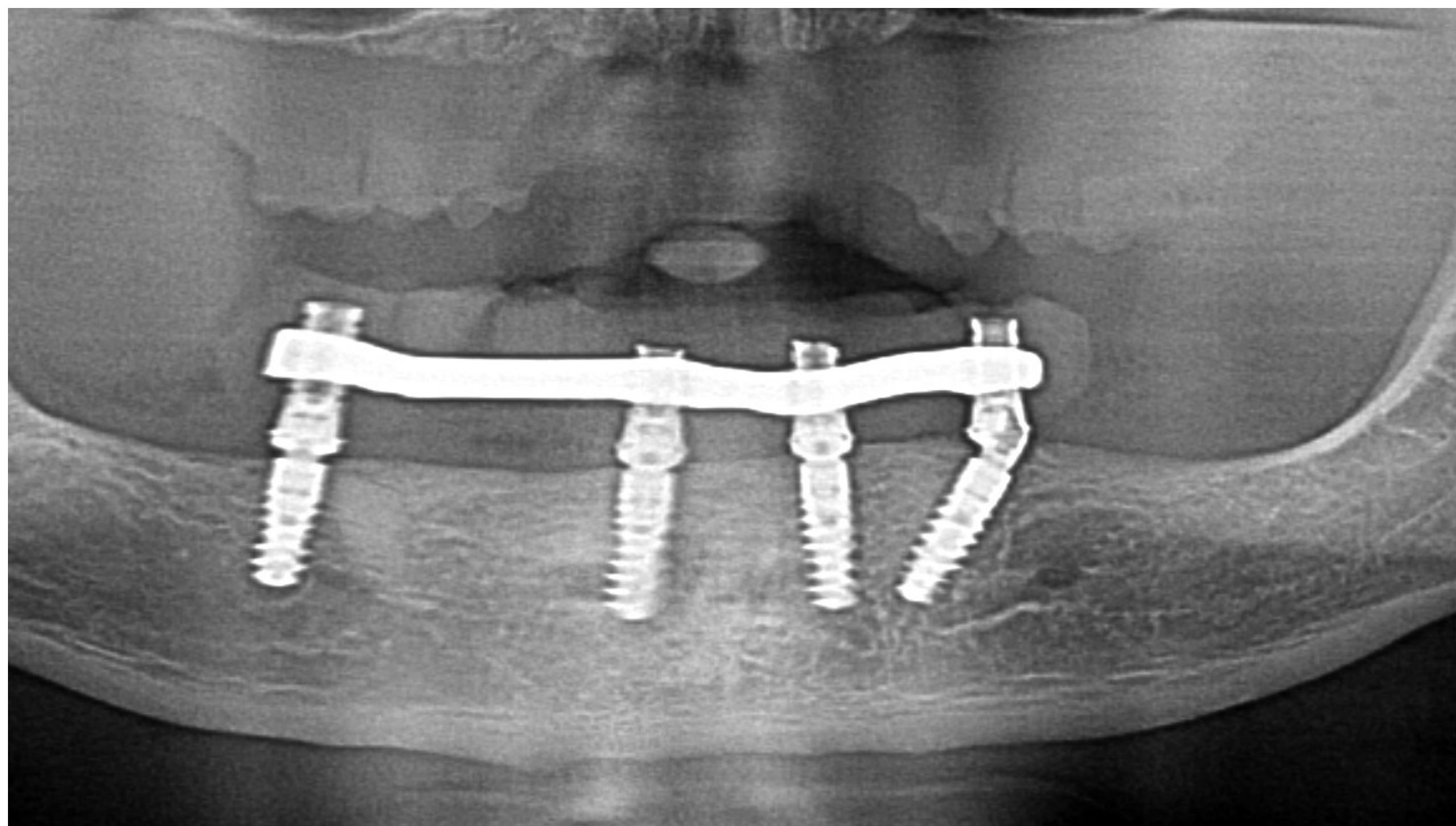
Clinical case



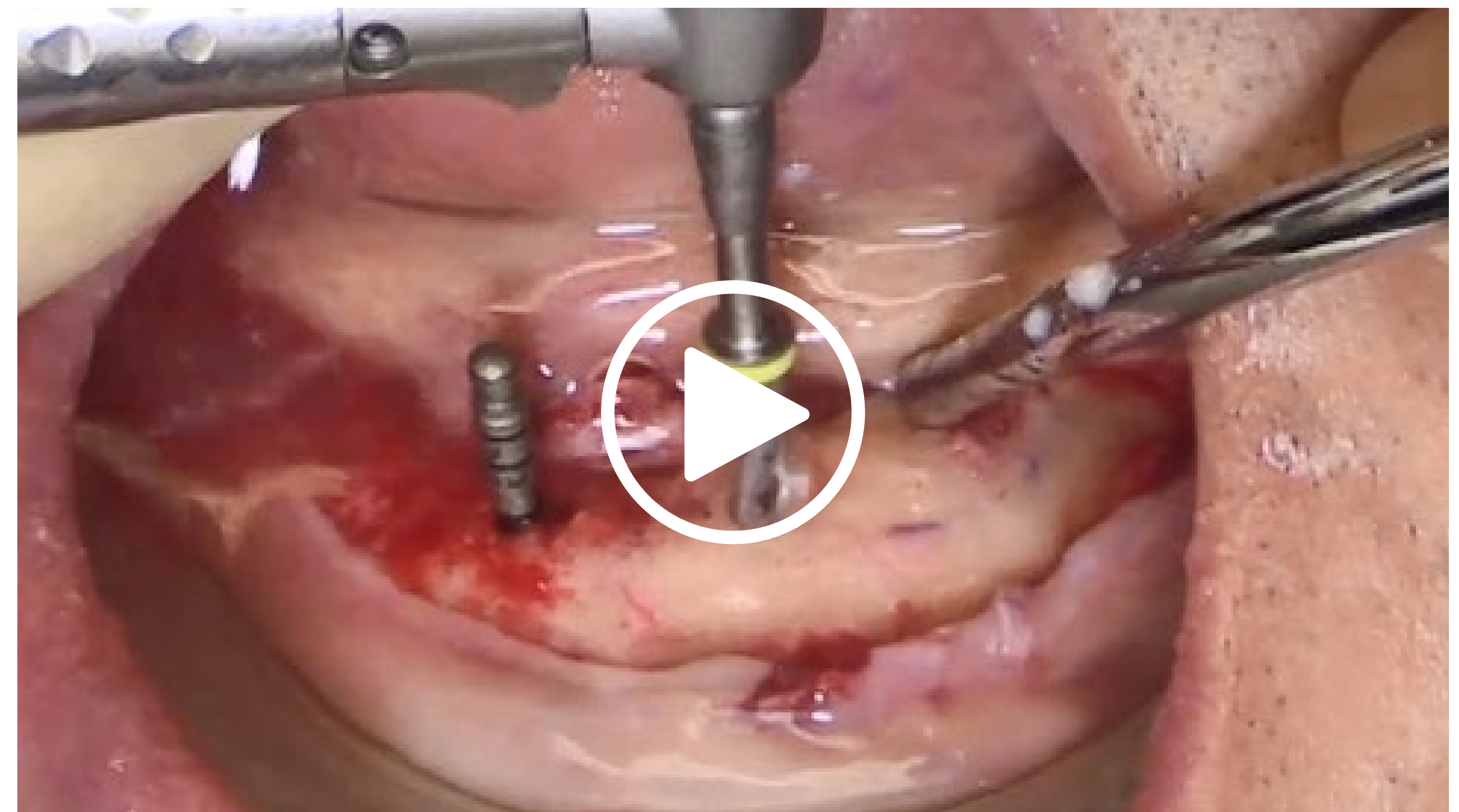
Placement of the provisional prosthesis



Postoperative panoramic radiograph



Panoramic radiograph after implant placement and placement of the provisional prosthesis

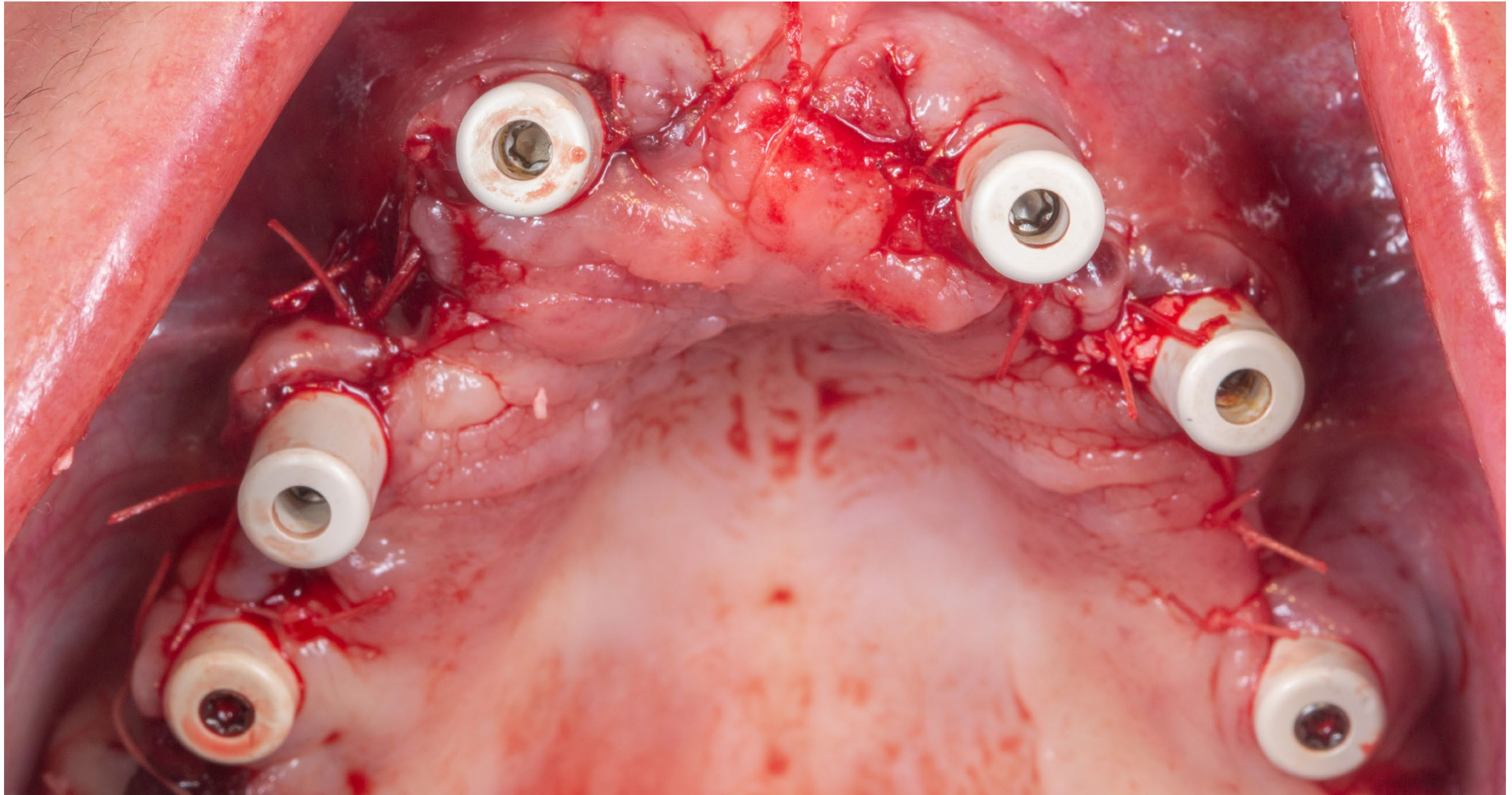


Watch the clinical case video



# Challenge 10: Narrow ridge

General recommendations and clinical case from Prof. Helena Francisco





# Challenge 10: Narrow ridge

## General recommendations



## General recommendations from Prof. Helena Francisco

- Ø 3.75 mm or narrow diameter implants
- Augmentation
- Six implants for optimized distribution in the narrow ridge

Professor Helena Francisco acquired a PhD from the University of Lisbon, School of Dental Medicine. She received the Post-graduate Certificate in Periodontology and Implant Dentistry from the New York University College of Dentistry (USA) and is a member of the Research Group for Oral Biology and Biochemistry Research Unit in Oral and Biomedical Sciences. Besides practicing dentistry, Professor Francisco also works as an Assistant Professor and co-coordinator of the Oral Surgery and Implant Dentistry Post-graduate Program in the School of Dental Medicine at the University of Lisbon. She has authored several posters, as well as national and international publications.



**Prof. Helena Francisco**  
DDS, Implantology Institute  
Lisbon, Portugal

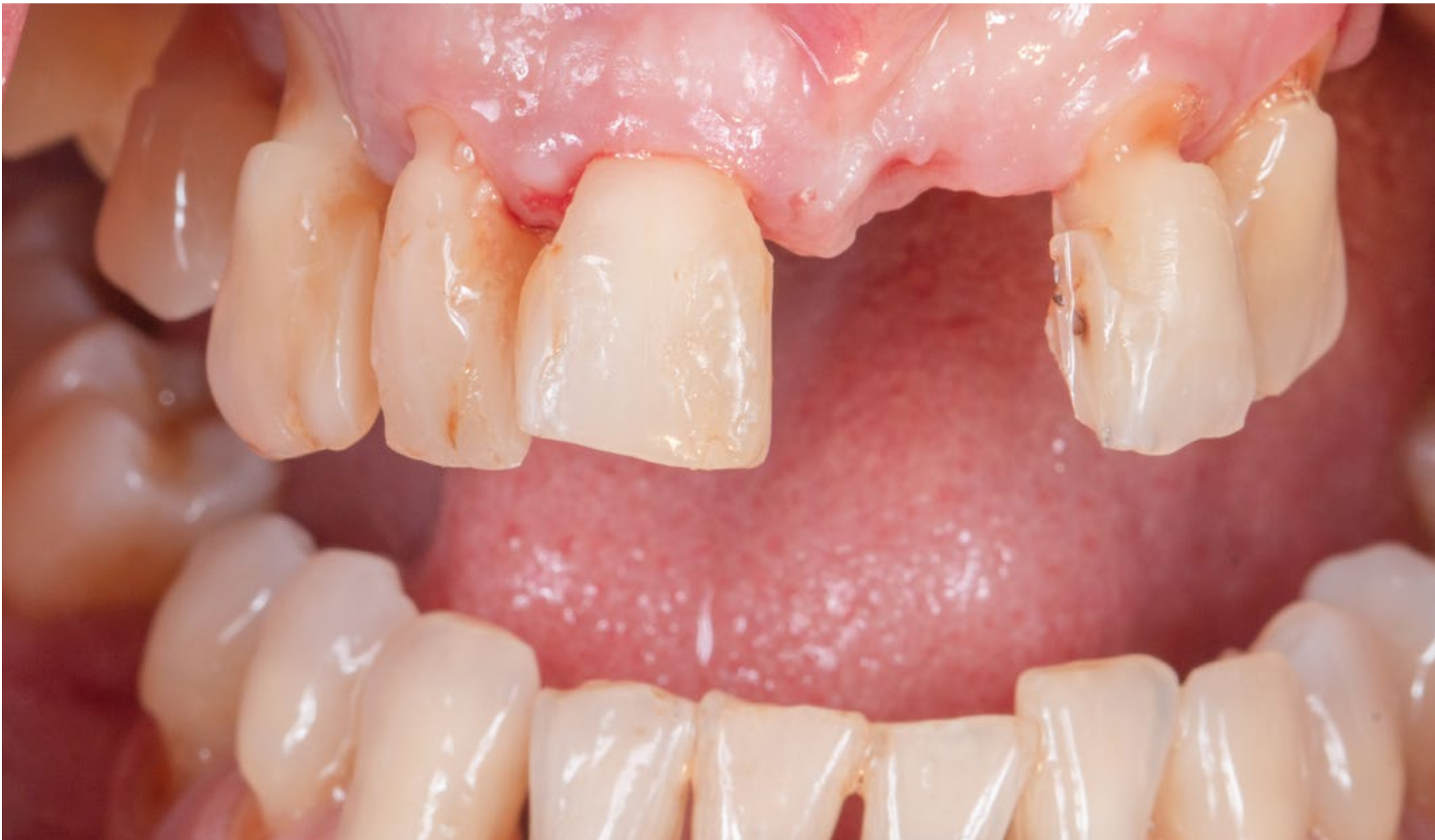

# Challenge 10: Narrow ridge

Clinical case



## Initial situation



## Patient information

Age	42
Jaw	Maxilla
Health status	Good
Height of smile line	Low
Bone type	Type D4
Infections at implantation site	No
Bone anatomy defects	No defects
Risks	No

## Additional difficulties

Soft bone quality
Limited bone availability in the posterior area

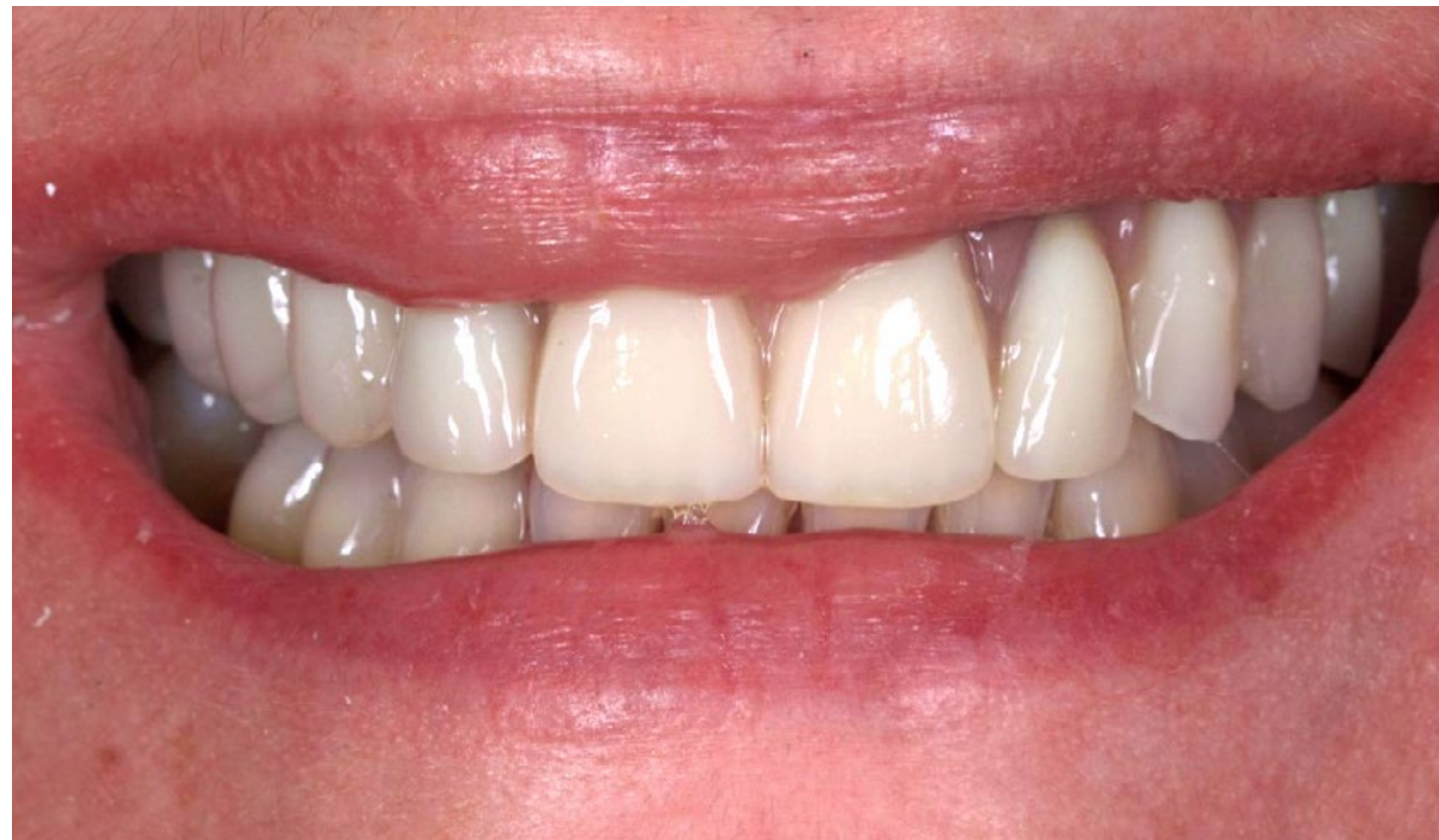

# Challenge 10: Narrow ridge

Clinical case



## Provisional prosthesis



## Treatment

- Fixed immediate rehabilitation on six straight implants
- Slight bone reduction

**Temporary restoration:** acrylic temporary prosthesis

**Planned final prosthesis:** monolithic zirconia

## Materials used



Straumann® BLX Ø 3.75 mm  
RB SLActive® 10 mm, Roxolid®



Screw-retained abutments,  
straight, GH 2.5 mm



Straumann® XenoGraft  
0.5 mm



---

# Challenge 10: Narrow ridge

Clinical case

---



## Our experience



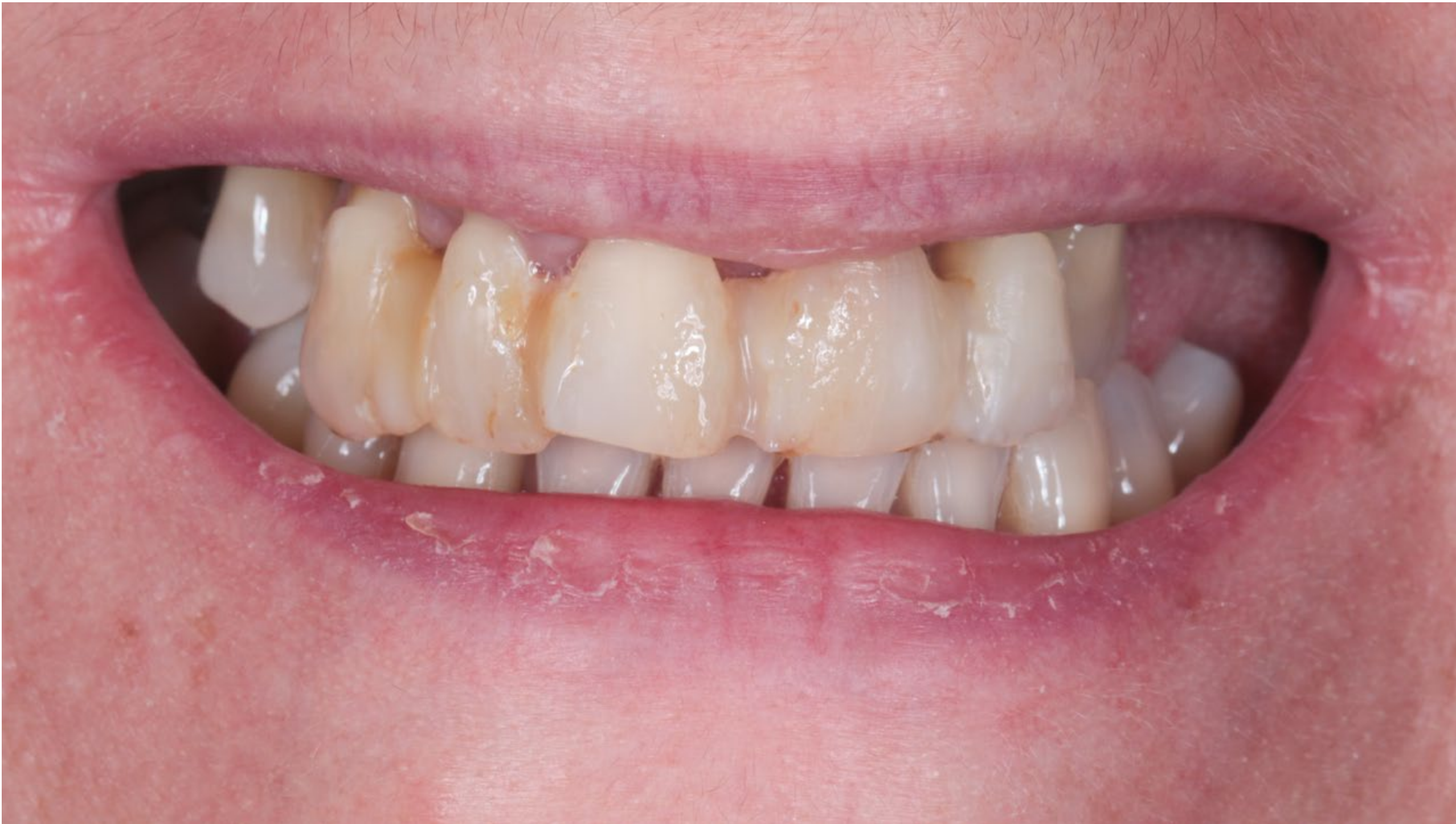Prof. Helena Francisco  
DDS, Implantology Institute

*“BLX has great features for the immediate loading of full-arch cases: aggressive thread design allows good stability even in the soft bone; one connection for all the implant diameters simplifies the prosthetic portfolio; six positions for the screw-retained abutment. The lack of edges in the angled screw-retained abutments helps the soft tissues adapt better.”*

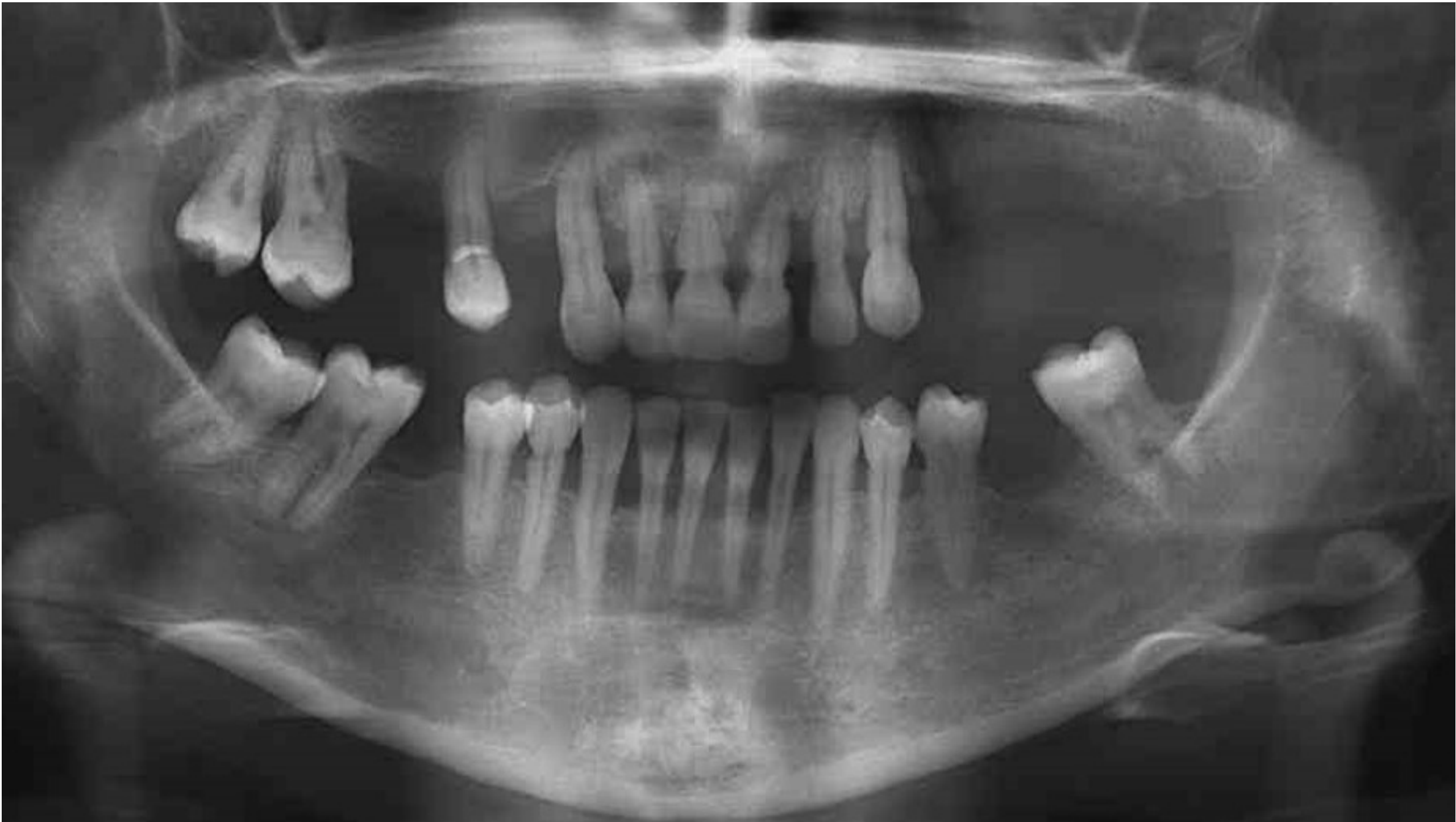


# Challenge 10: Narrow ridge

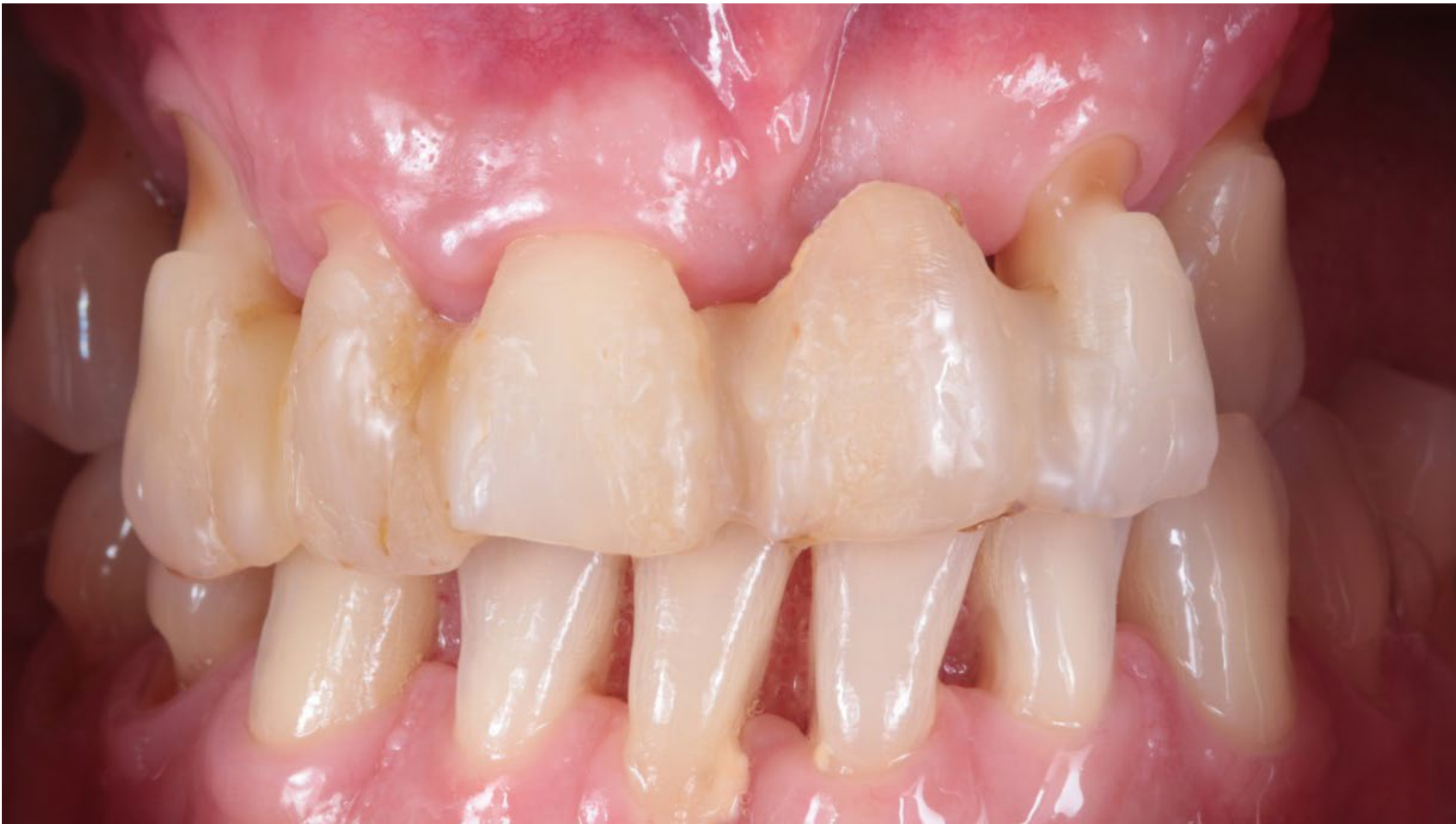Clinical case



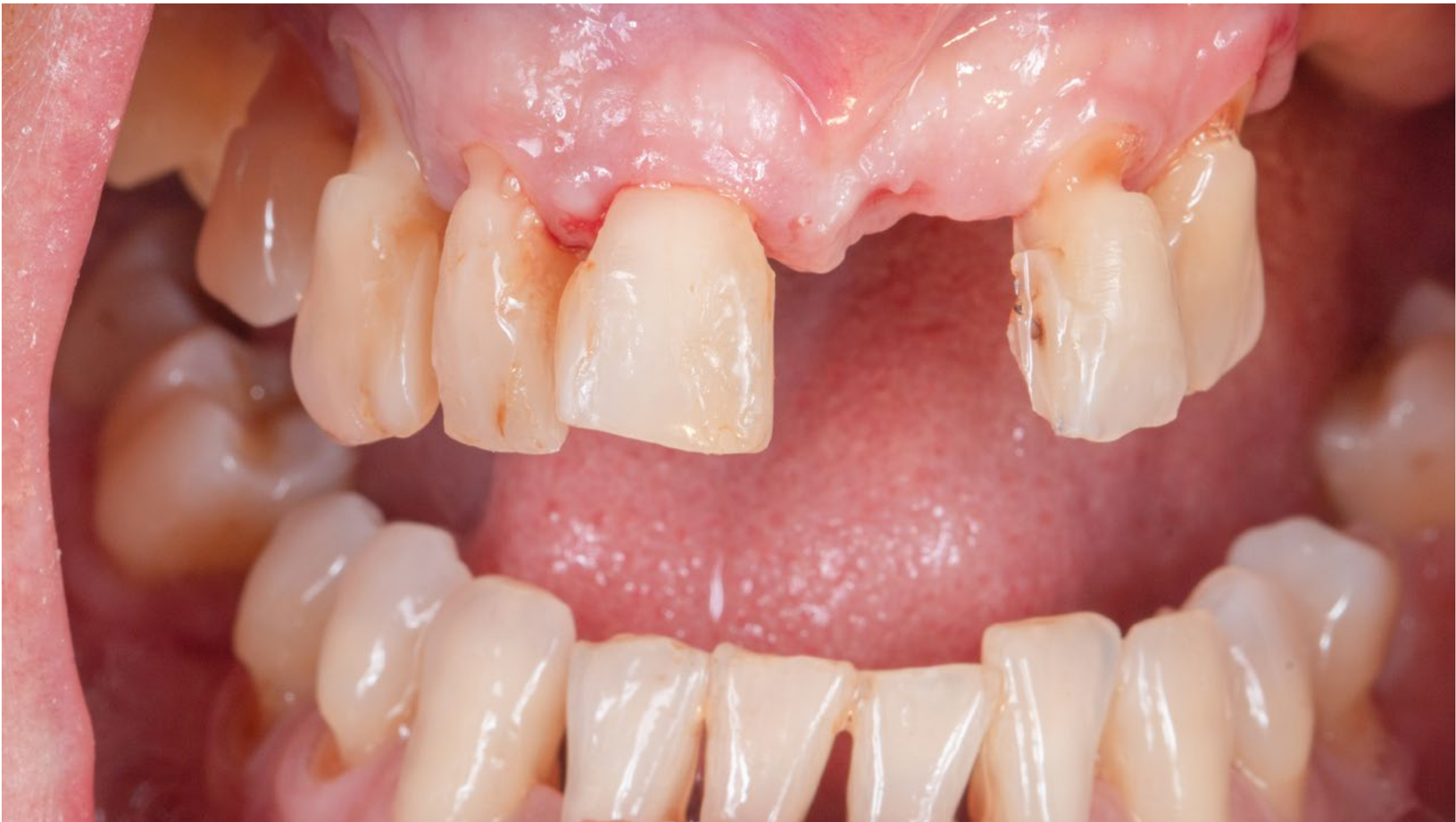Initial clinical situation



Preoperative panoramic radiograph



Initial clinical situation




Initial clinical situation

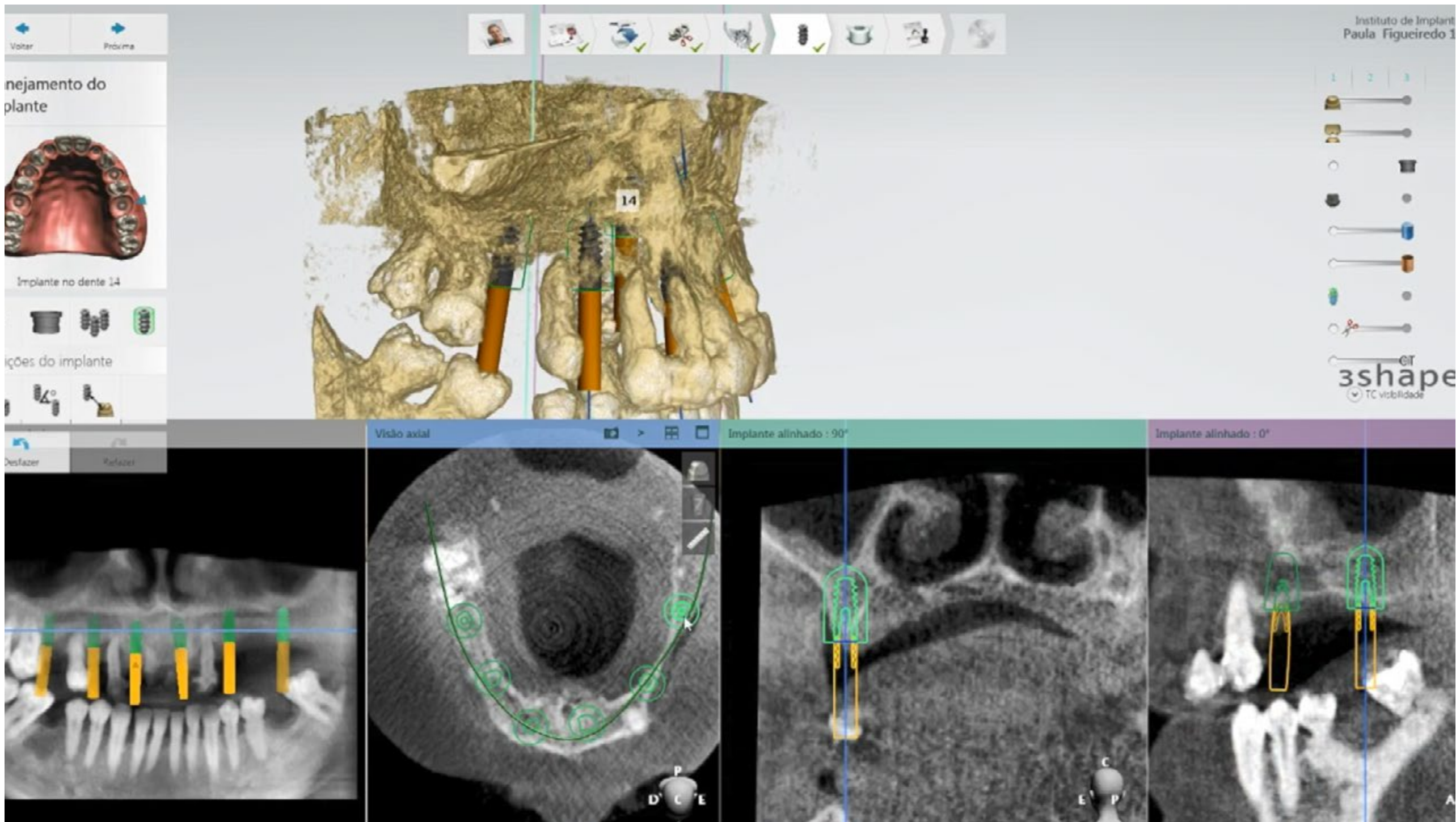


# Challenge 10: Narrow ridge

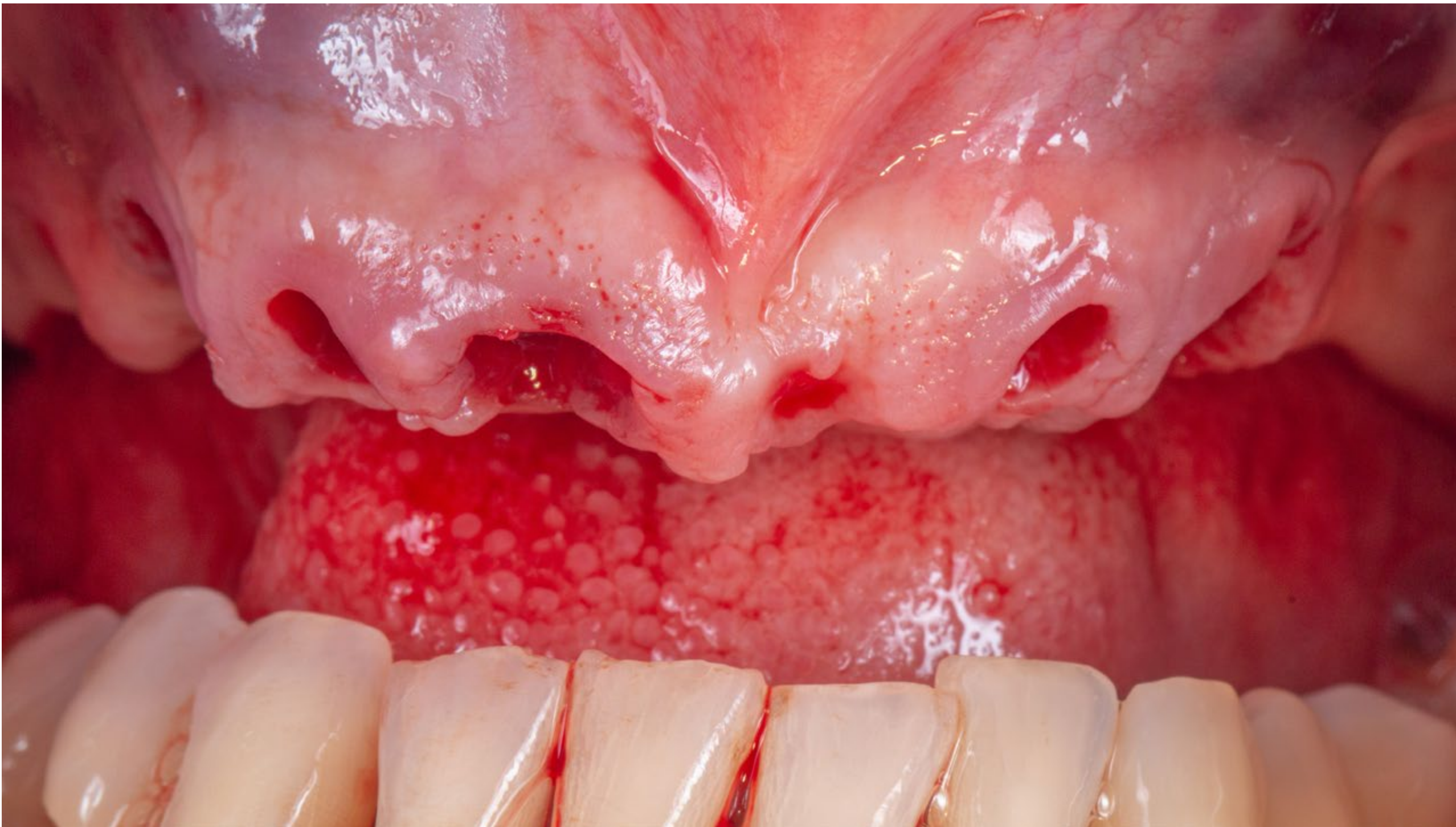Clinical case



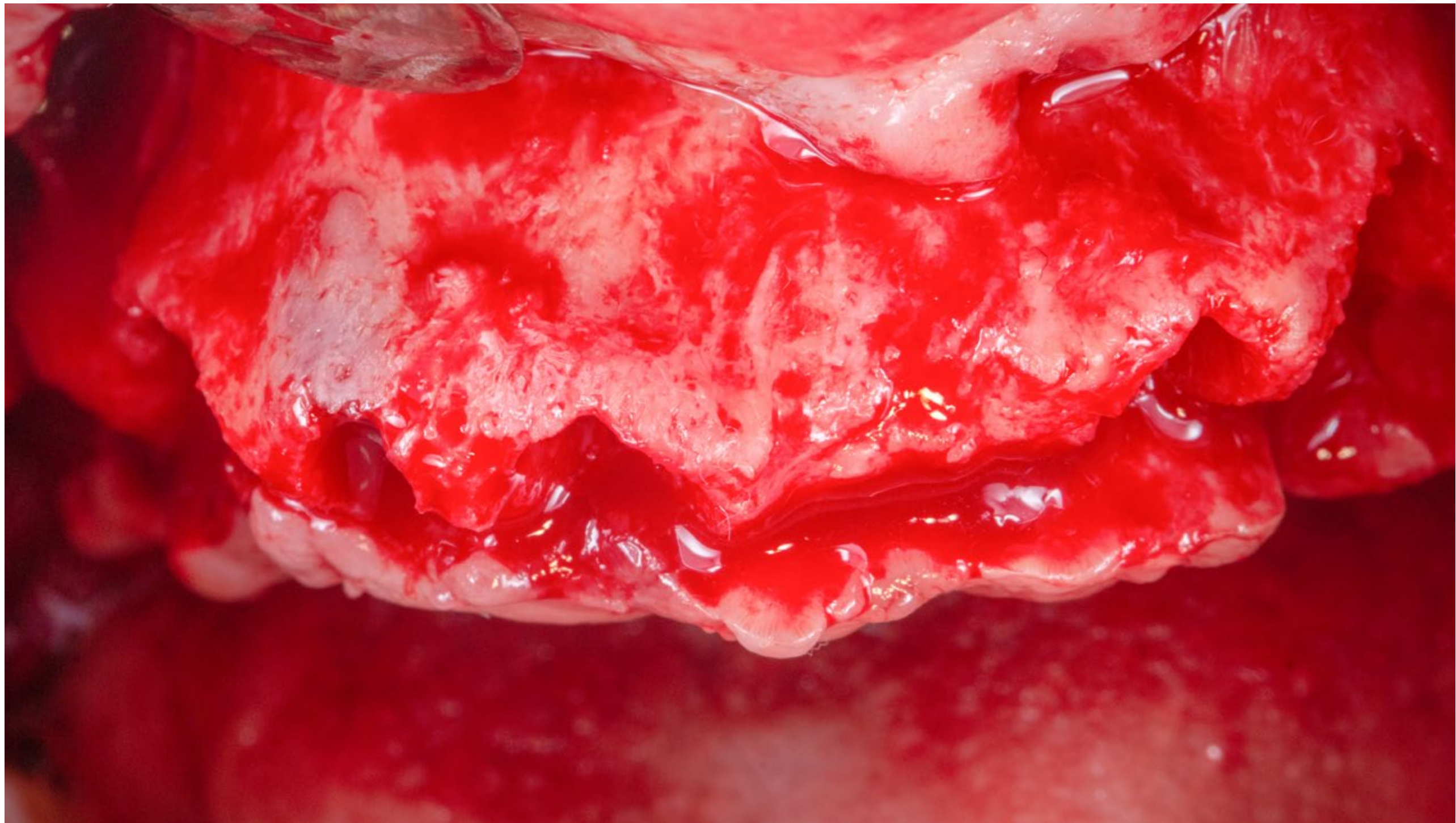3D treatment planning



Treatment planning with Implant Studio



Hopeless teeth were extracted

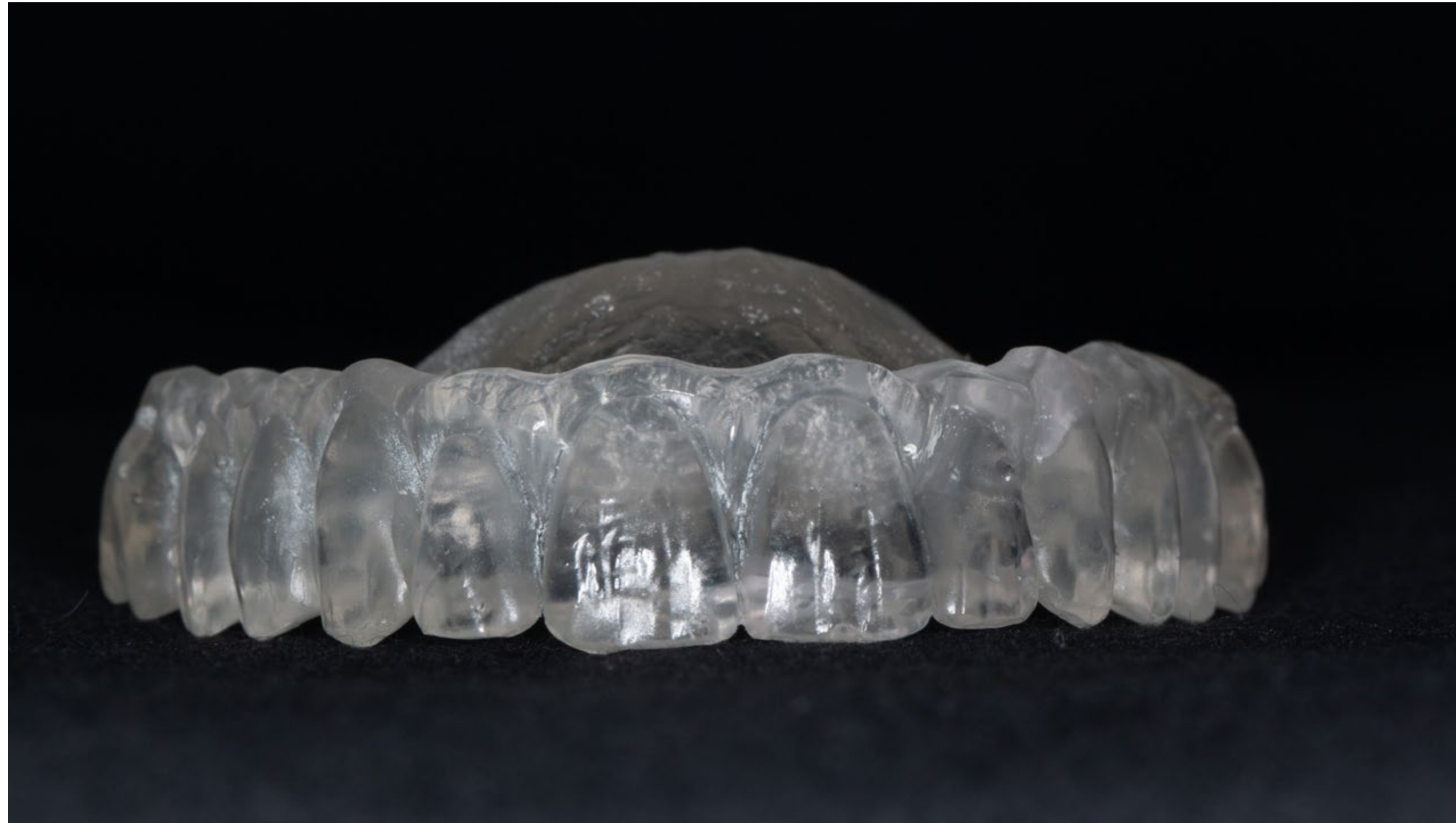

Full flap elevation

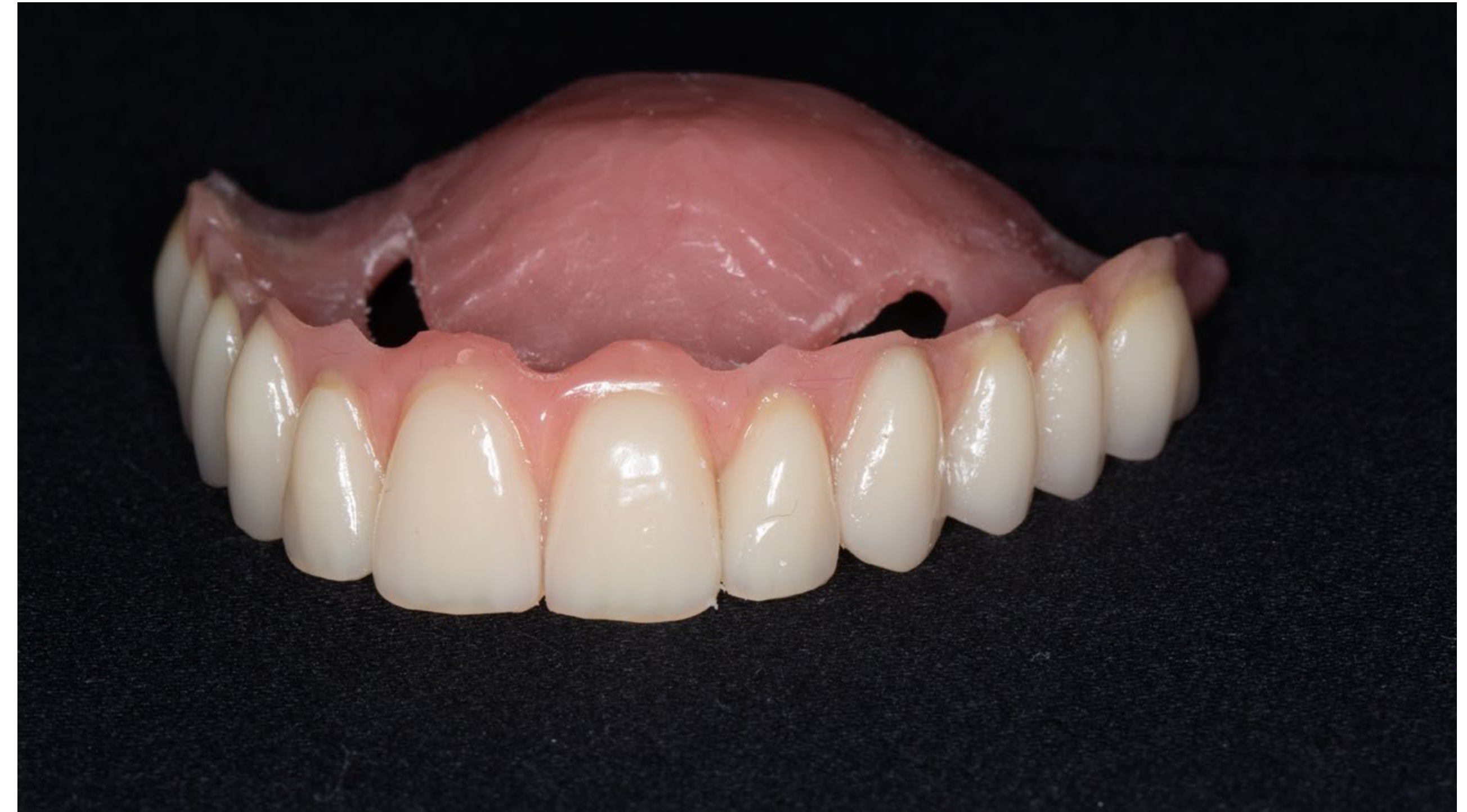

# Challenge 10: Narrow ridge

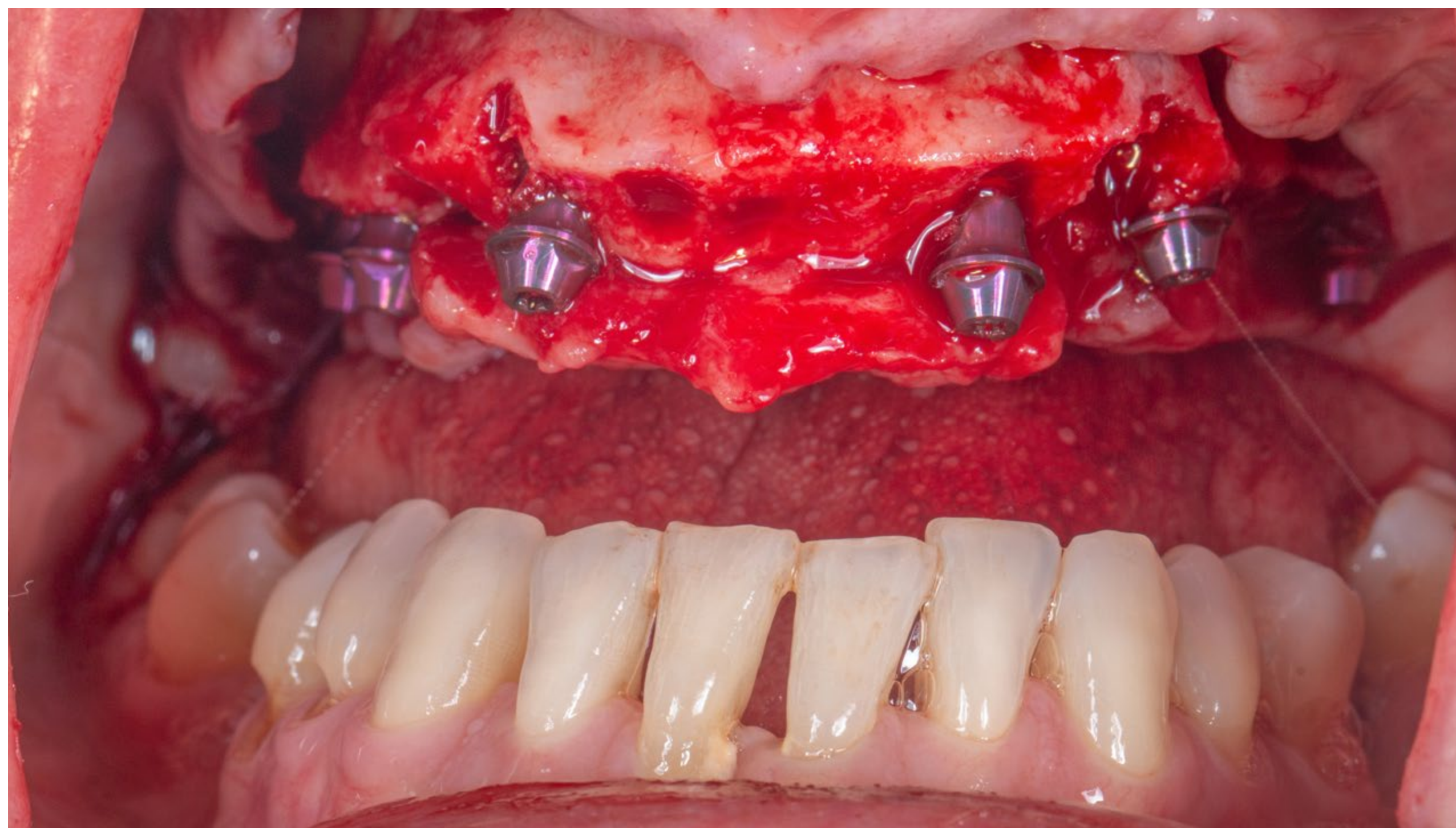
Clinical case



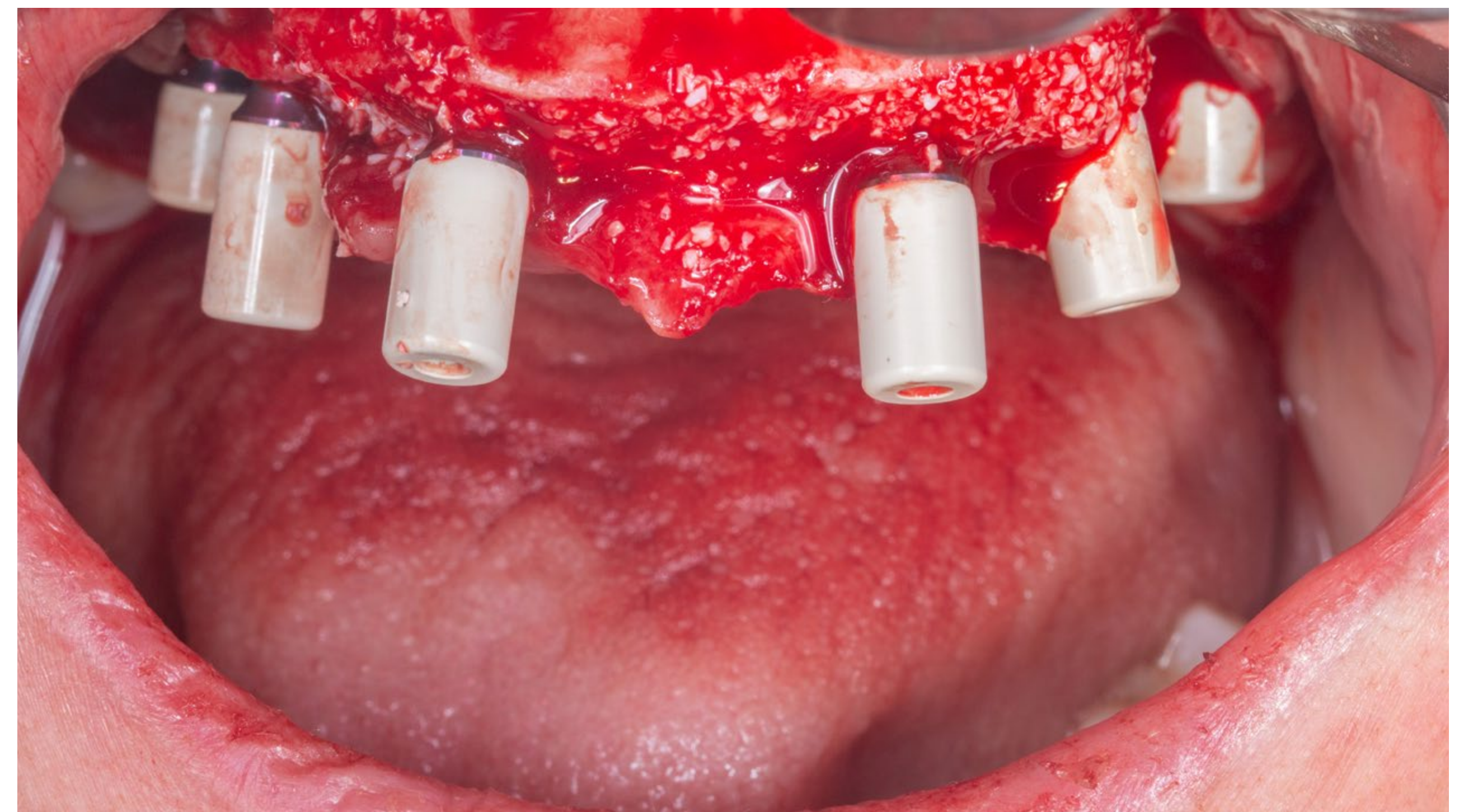
Transparent guide to verify implant position and orientation throughout the procedure



Acrylic denture prepared by dental lab to transfer in to a provisional prosthesis



Screw retained Abutments in place after the implant placement

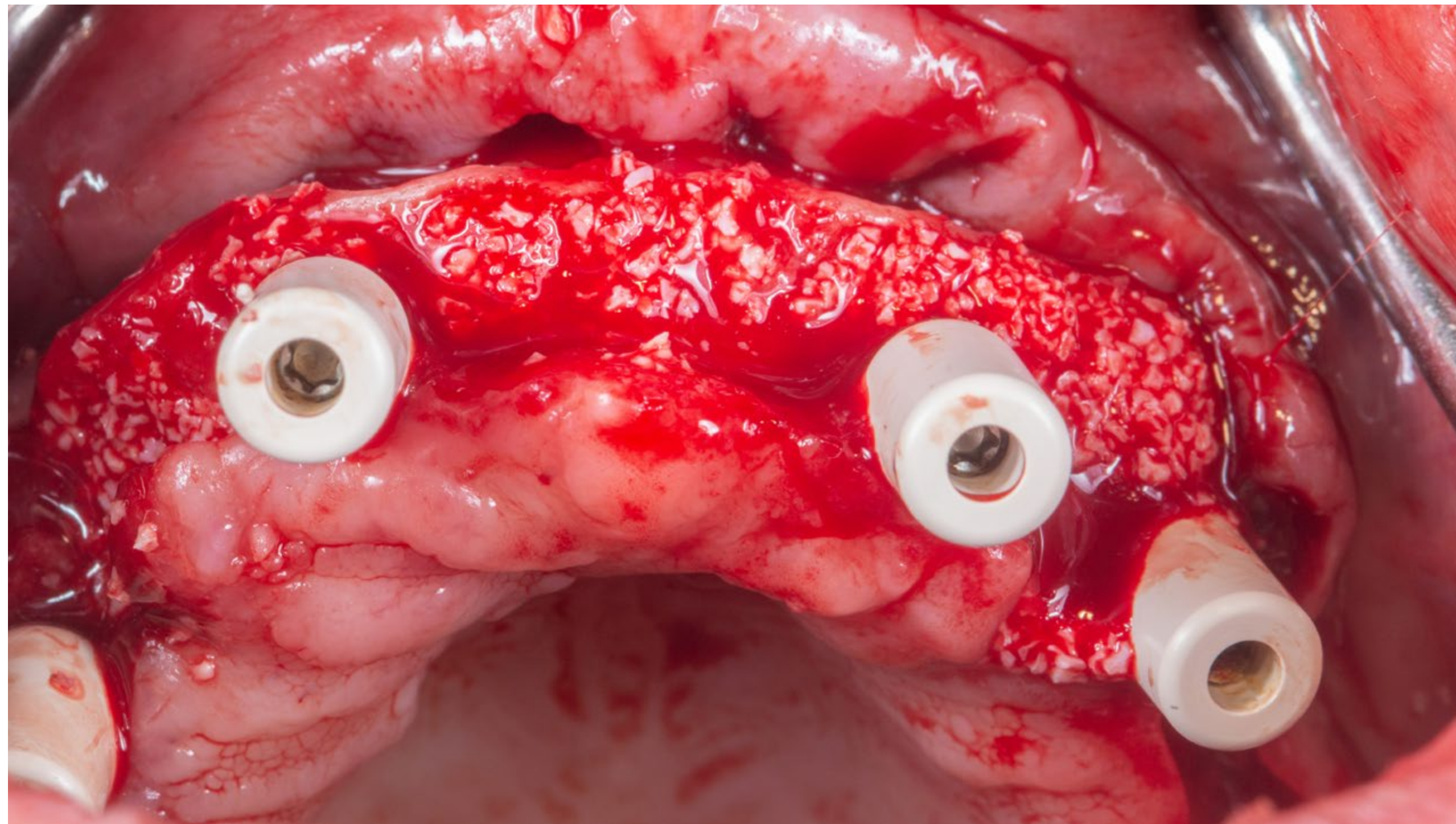


Bone augmentation with Straumann® XenoGraft and Protective Caps Ø 4.6 mm in place

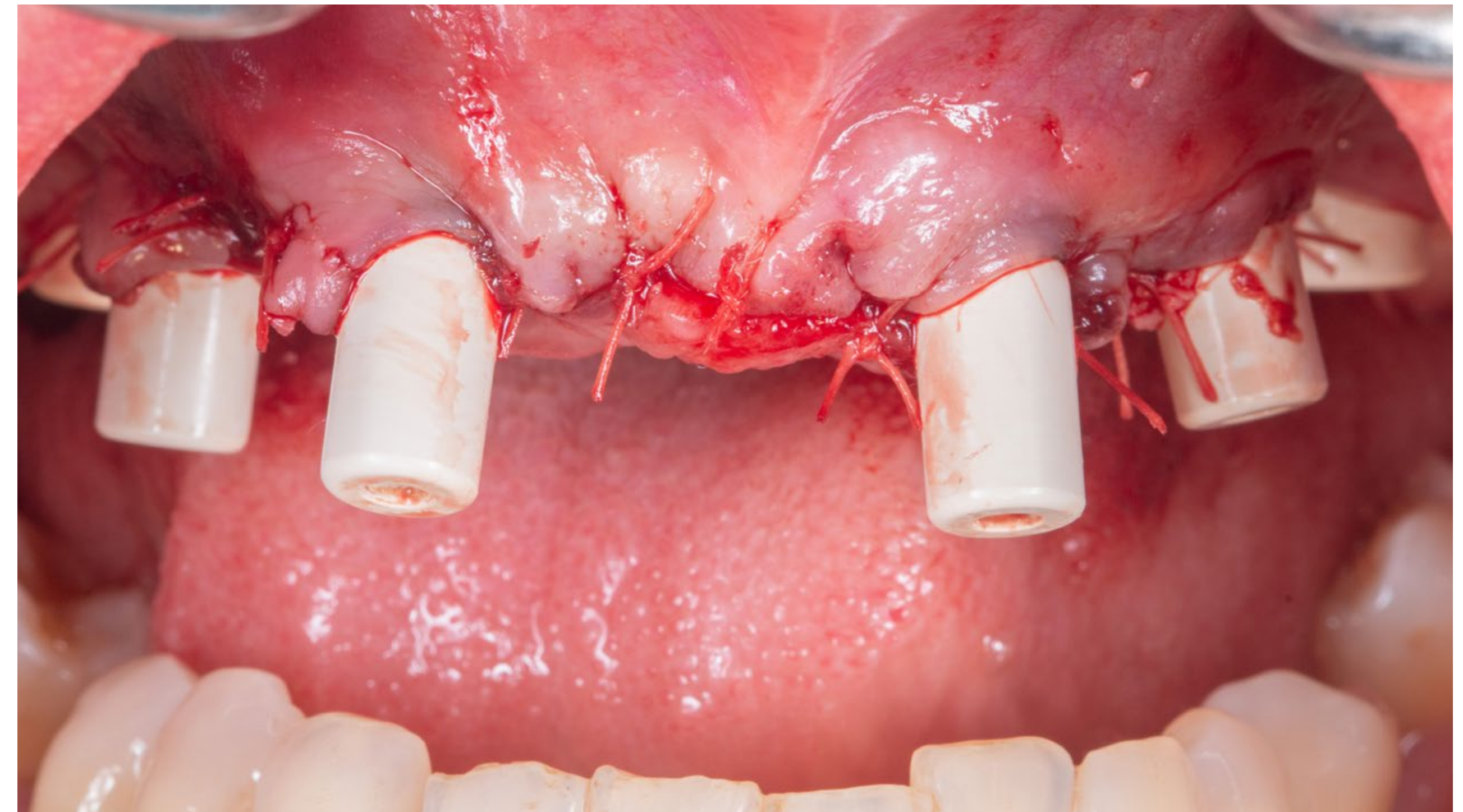

# Challenge 10: Narrow ridge

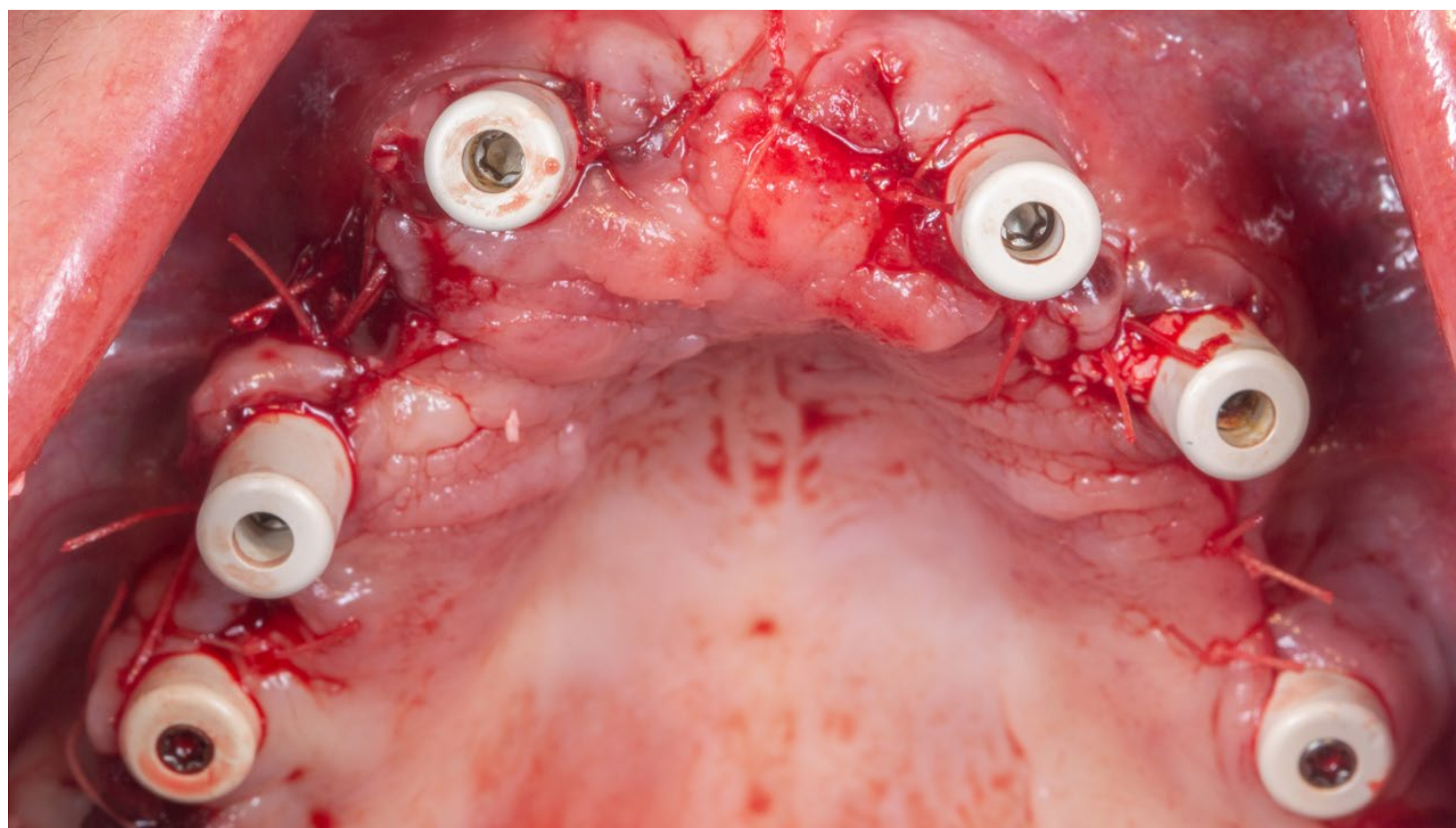
Clinical case



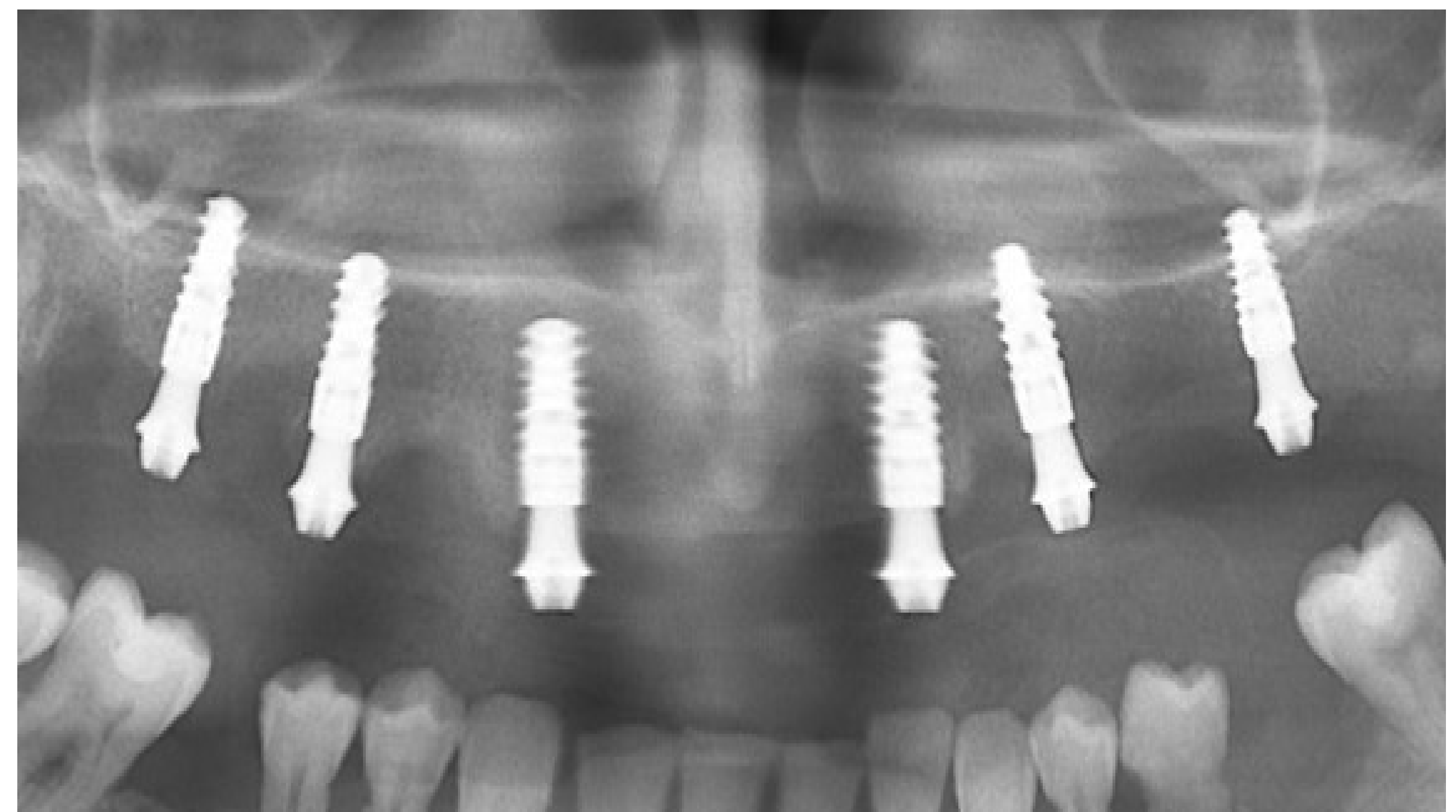
Bone augmentation with Straumann® XenoGraft and Protective Caps Ø 4.6 mm in place



Sutured site



Sutured site

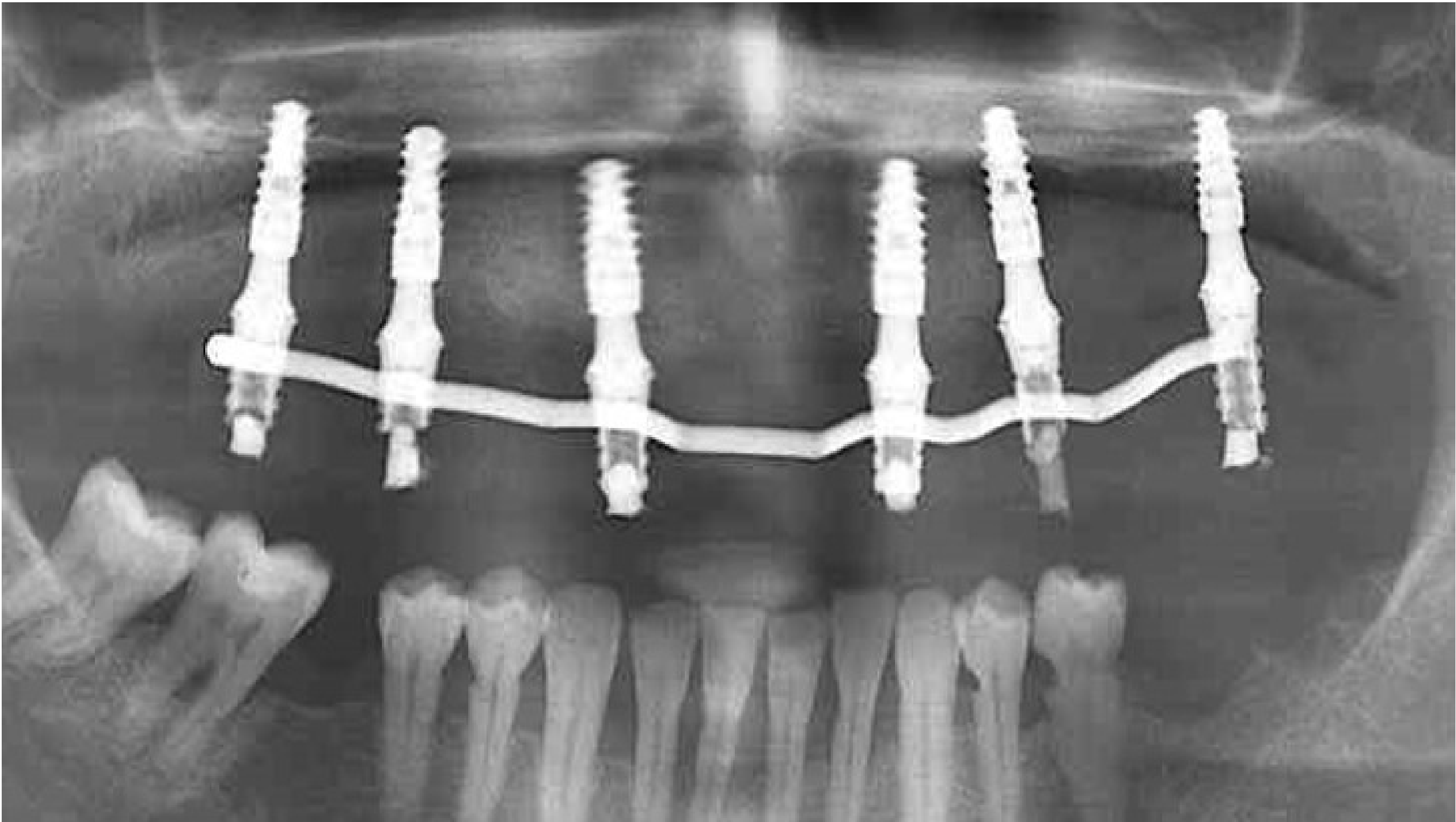


Post-operative x-ray

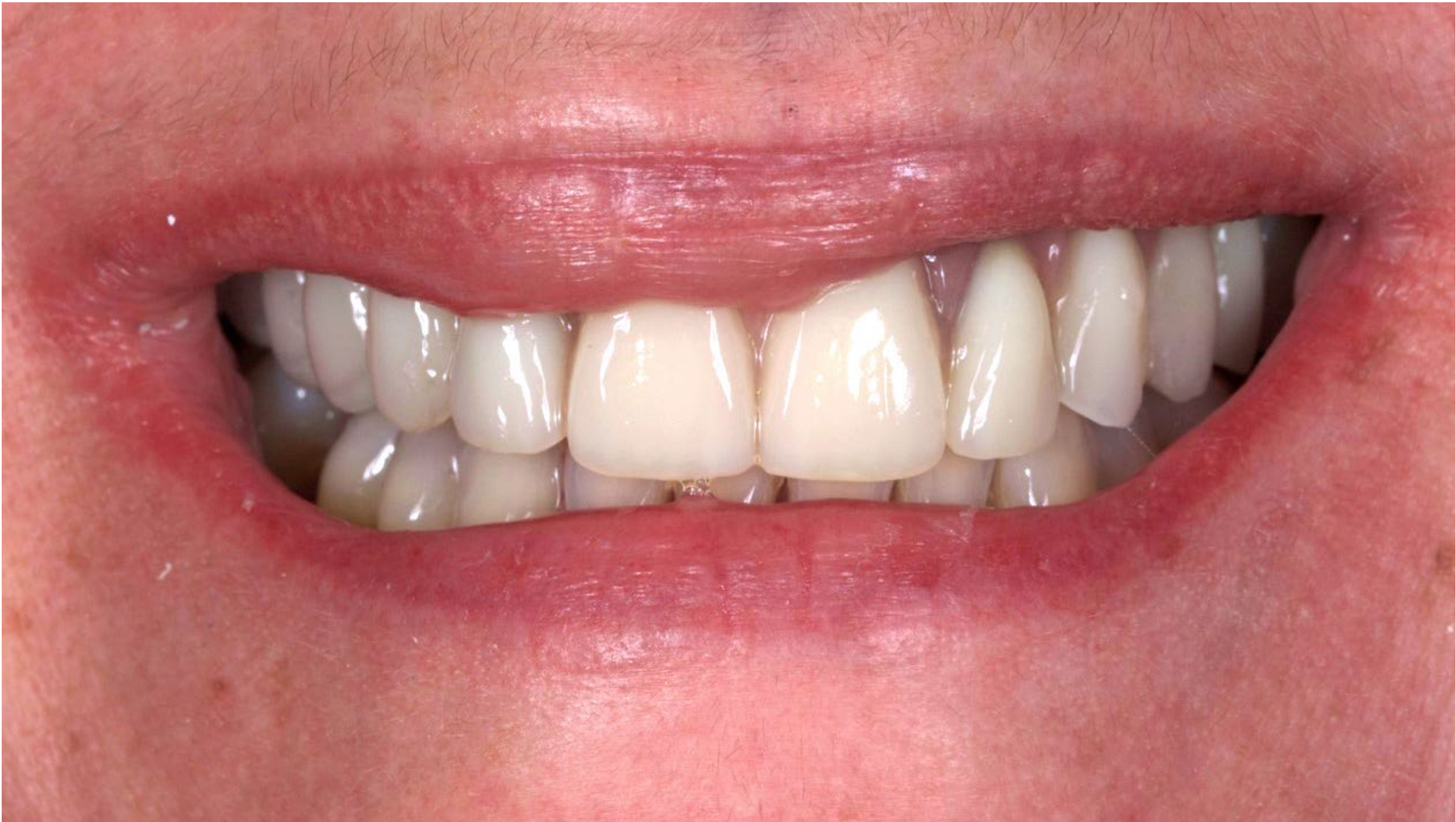

# Challenge 10: Narrow ridge

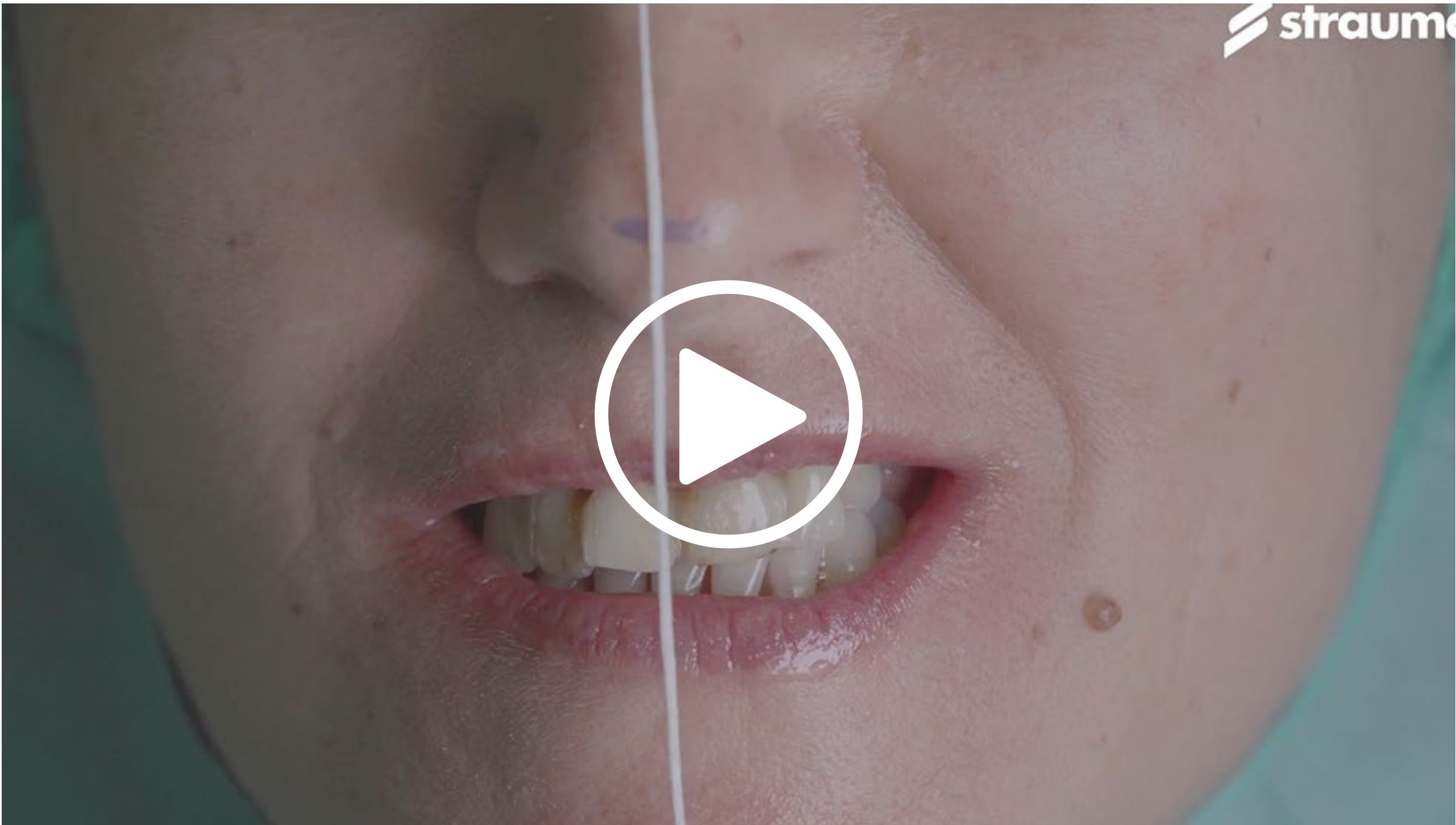Clinical case



Post-operative panoramic  
Reinforced temporary acrylic prosthesis



Provisional prosthesis in place.  
Final prosthesis will be placed in six months later.

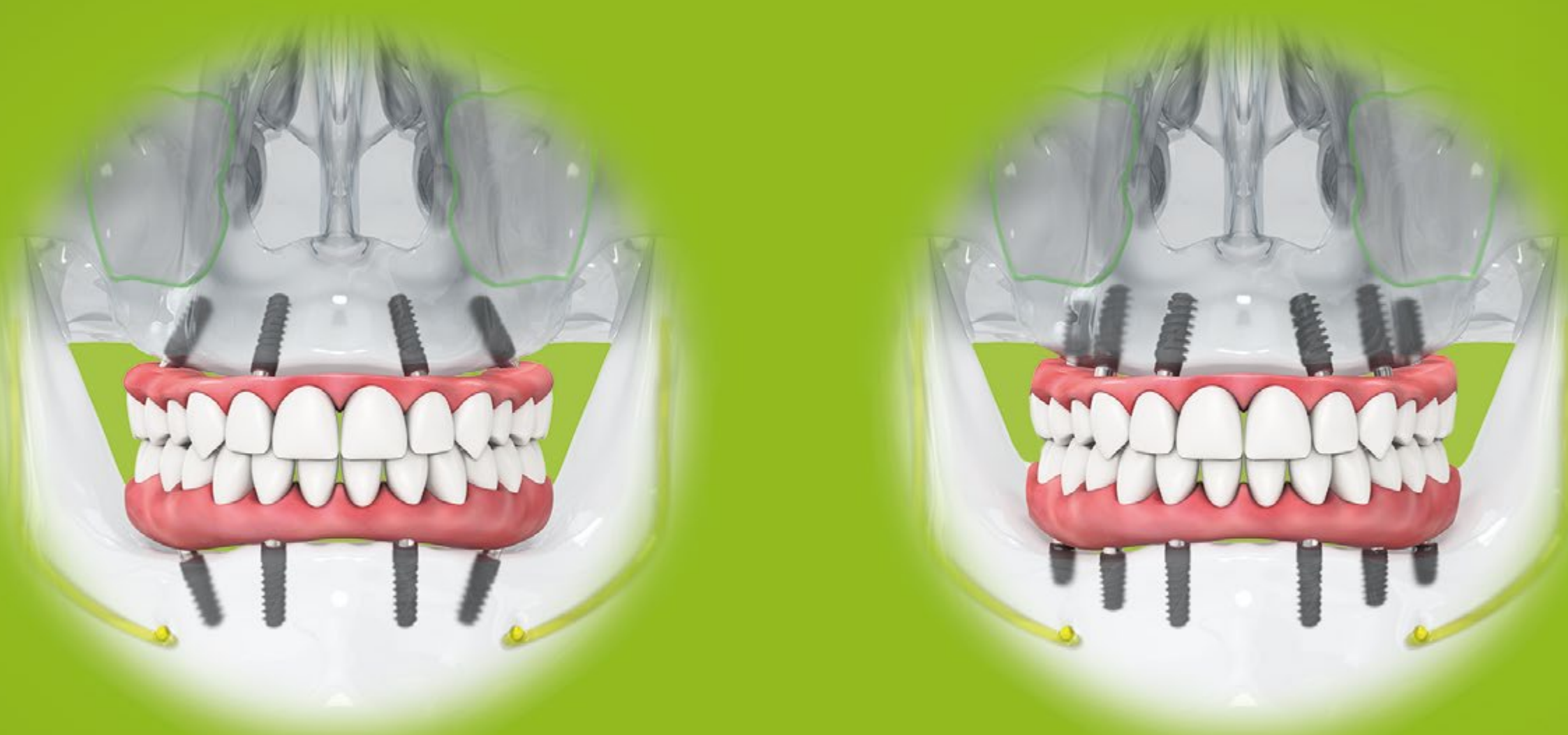

Watch the clinical case video





Straumann® Pro Arch  
Tailored to fit.  
Designed to last.



Straumann® Pro Arch is designed to deliver a life-changing, immediate, esthetic, and reliable treatment and gives patients back confidence and lasting quality of life. Straumann® Pro Arch takes into account that every case is different and every patient has different expectations, medical history, and needs.





## A winning combination of evidence-based technologies

Straumann® Pro Arch allows you to differentiate your practice. With tapered BLT and BLX implants, Roxolid® for strength, SLActive® for enhanced bone regeneration<sup>6-9</sup> and Emdogain® for faster healing<sup>17</sup>, you can deliver high predictability and peace of mind even in challenging situations.



### TREATMENT OPTION

A variety of treatment options to address specific indications and different patient needs.<sup>1-11</sup>



### IMMEDIATE LOADING

BLT and BLX Implants designed for reliable primary stability and immediate loading.<sup>1,2</sup>



### REDUCED INVASIVENES

Roxolid® enables the use of narrow and short implants to preserve bone and avoid grafting.<sup>4,7,12-16</sup>



### COMPROMISED PATIENTS

Peace of mind with SLActive® even when treating compromised patients with diabetes or irradiated patients.<sup>6-9</sup>



### RESTORATIVE FLEXIBILITY

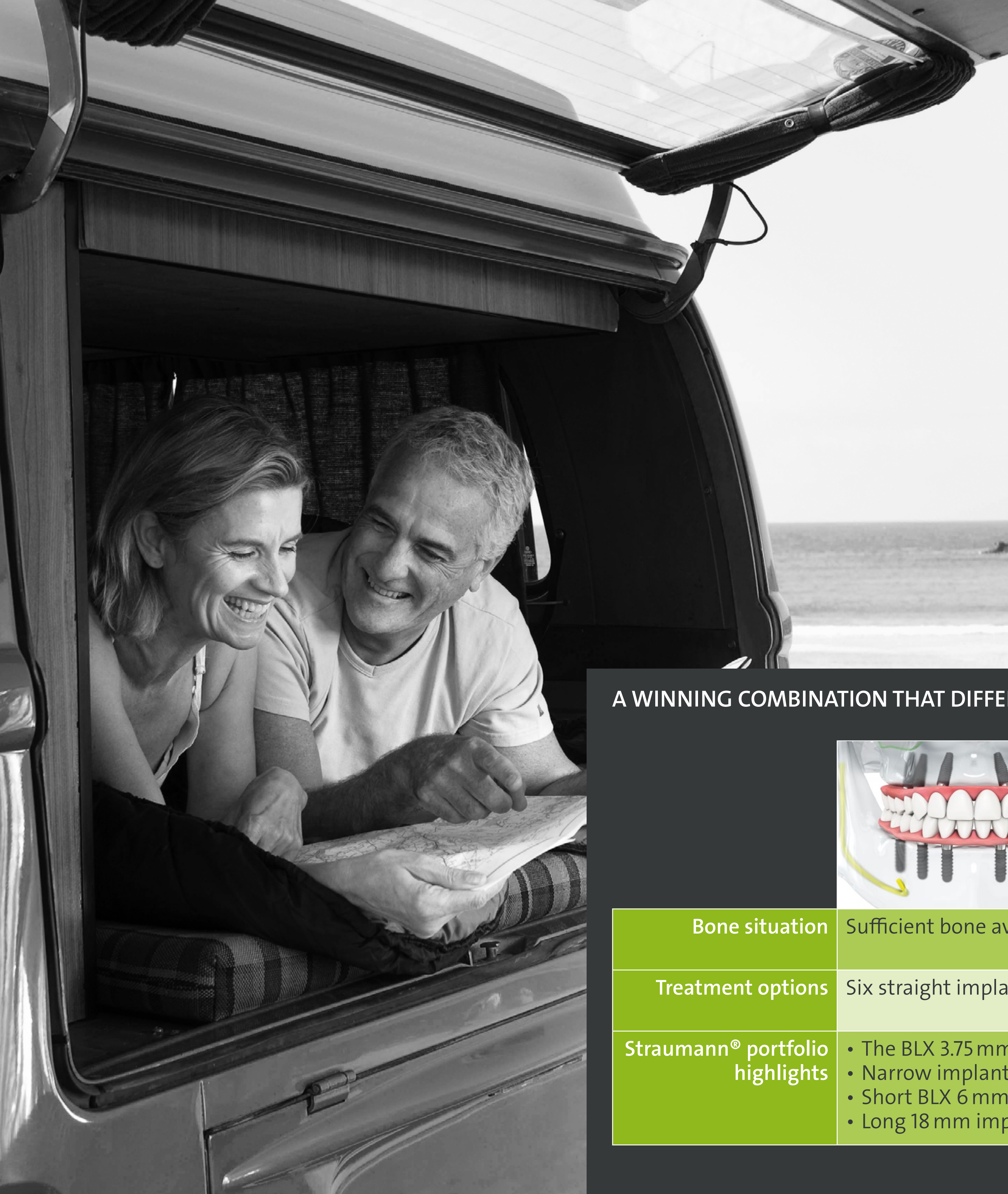Prosthetic portfolio addresses patient's esthetic expectations within their financial resources.



### PRACTICE GROWTH

Practice development and patient communication tools support your practice growth.

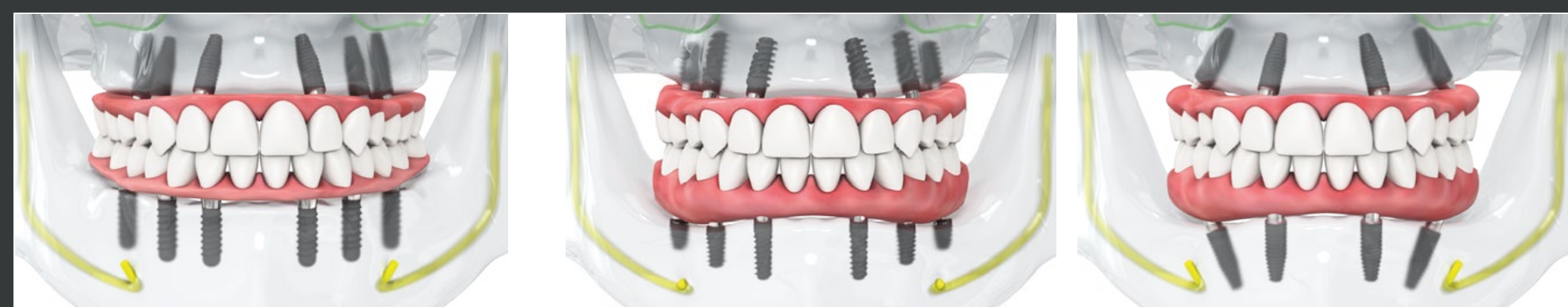




## Flexible treatment options to address even challenging cases

Different treatment options for individual bone situations supported by unique Straumann® BLX portfolio.

### A WINNING COMBINATION THAT DIFFERENTIATES YOUR PRACTICE



<b>Bone situation</b>	Sufficient bone availability	Insufficient posterior bone height	Insufficient posterior bone availability
<b>Treatment options</b>	Six straight implants	Short implants in posterior region	Tilted posterior implants
<b>Straumann® portfolio highlights</b>	<ul style="list-style-type: none"> <li>• The BLX 3.75 mm implant for all indications</li> <li>• Narrow implants: BLT 3.3 mm or BLX 3.5 mm</li> <li>• Short BLX 6 mm implants</li> <li>• Long 18 mm implants</li> </ul>		



# Straumann® Pro Arch with BLX – Confidence beyond Immediacy



With one system and clinically proven Straumann® materials even for challenging cases. Straumann® BLX is designed for immediate protocols in all bone types.

## Optimized thread design

Optimized shallow threads of the narrow Ø 3.5mm and Ø 3.75mm implants. Designed for soft bone, and hard bone applications.

## Slim and smooth

Slim and smooth angulated abutment designed to maximize space for soft tissue. Choice of gingival heights: from 3.5 mm – 5.5 mm. 35 Ncm torque.

## Restorative Flexibility

Prosthetic portfolio addresses patient's esthetic expectations within their financial resources.

## Simplified drill protocol

Less steps and flexible sequence with a new drill design for minimized heat generation.\*

## One Connection

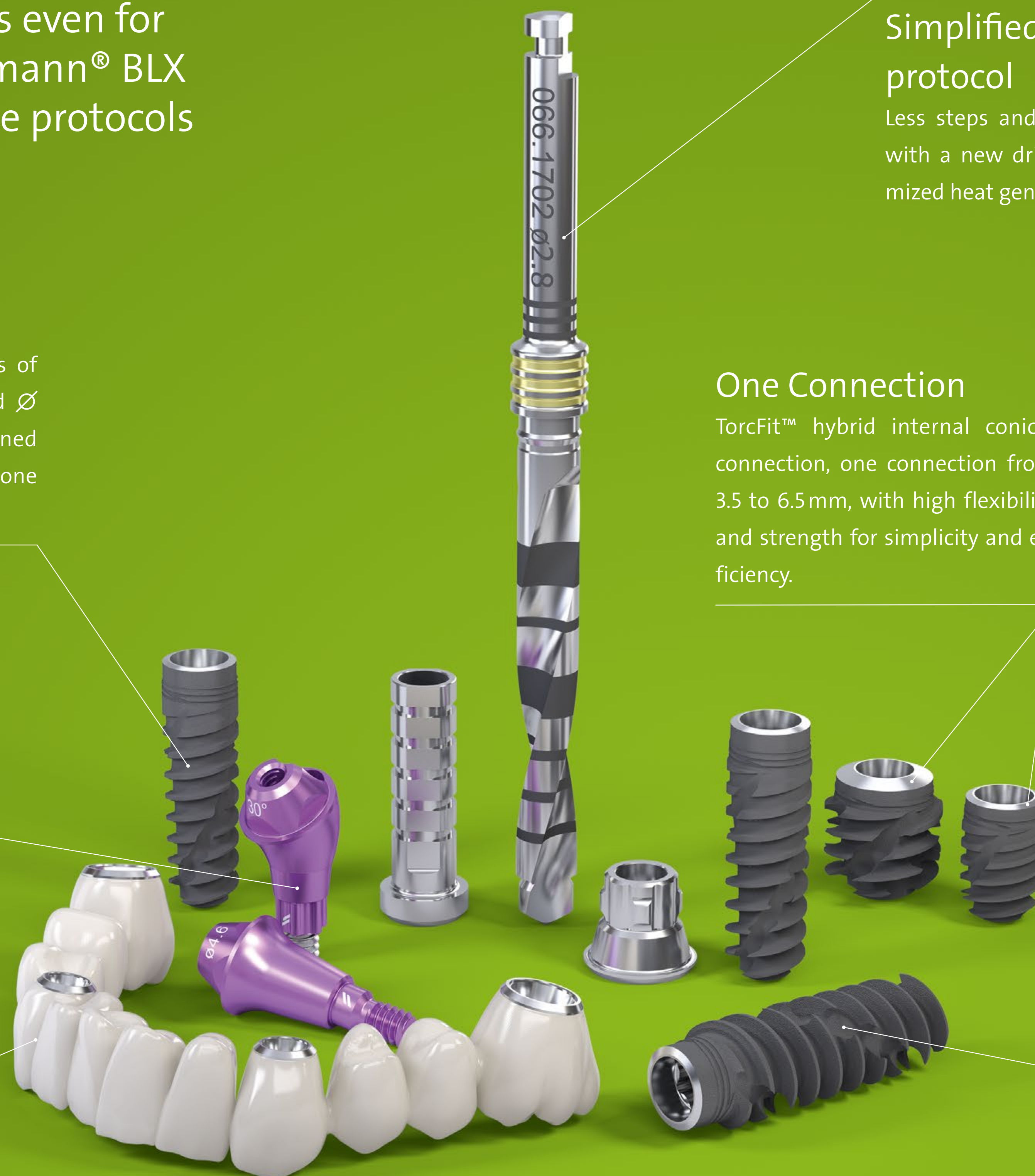TorcFit™ hybrid internal conical connection, one connection from 3.5 to 6.5 mm, with high flexibility and strength for simplicity and efficiency.

## Broad range of implant options

Choose between 42 implant models: from 6 mm to 18 mm implant length and from 3.5 mm to 6.5 mm implant diameter.

## Dynamic Bone Management

Enhanced control over insertion torque to achieve optimal primary stability and ensure confidence in immediate protocols.



\* Data on file for Straumann® VeloDrill™ and Twist Drill PRO